

Chronic Sinusitis: Does It Contraindicate Lateral Maxillary Sinus Lift?

Original Article

Mai A. Haggag¹, Osama M.R. Askar², Amira A.M.M. Attia¹

Assistant Professor of Oral and Maxillofacial Surgery, Faculty of Dentistry, Mansoura University¹, Assistant Professor of Prosthodontics, Faculty of Dentistry, Mansoura University Egypt²

ABSTRACT

Background: Chronic sinusitis can be considered as a relative contraindication for sinus lifting procedure. Sinus lining with 6:9 mm radiographic thickening with or without partial sinus obliteration, is contraindicated for sinus lifting.

Patients and Methods: A prospective comparative clinical study was carried out to evaluate the impact of chronic sinusitis on sinus lifting procedures regarding bone height and infection. Pre-operative and 6-months post-operative CBCT of 12 maxillary sinuses which underwent sinus lifting procedure with grafting and simultaneous implant placement (20 dental implants), were done to evaluate the average gained bone height. Two groups of 6 sinuses each; Group I included patients with healthy sinuses, whereas Group II included patients with chronic sinusitis (identified by the presence of Schneiderian membrane thickening > 6 mm). Also, clinical follow-up was done to report the occurrence of any infection.

Results: Statistically, there was no significant difference in average bone gain between the two groups with very small effect size; in group I: it was 7.241.45± and in group II: it was 7.231.78±. Regarding infection, there was no sinus infection in group I compared to one sinus with one implant (that was lost) in group II showed sinus infection three months postoperatively.

Conclusion: Chronic sinusitis with a thickening of Schneiderian membrane > 6 mm may not be considered as a contraindication for sinus lifting with grafting and simultaneous implant placement.

Key Words: Chronic sinusitis, Lateral Sinus lift, Dental implant, Maxillary sinus, Sinus augmentation.

Received: 29 January 2022, **Accepted:** 25 February 2022

Corresponding Author: Mai Ahmed Haggag, PHD, Assistant Professor of Oral and Maxillofacial Surgery Faculty of Dentistry, Mansoura University **Tel** :050-2258204, **Mobile**: +20 01224646605, **E-mail**: maihaggag@mans.edu.eg
ISSN: 2090-097X, January 2022, Vol. 13, No. 1

INTRODUCTION

Dental implant treatment is needed to restore the function and aesthetics of an edentulous patient. Adequate quality and quantity of bone are necessary for the proper placement of dental implants. After extraction of maxillary posterior teeth, bone atrophy and maxillary sinus pneumatization gradually progress. Thus, insufficient bone for implant placement is frequently observed for a maxillary posterior alveolar bone.^[1] For such cases, maxillary sinus floor elevation (MSFE) could be considered to place dental implants.^[2] For sinus lifting, lateral and crestal techniques were described, depending on the residual alveolar bone height.^[3] Problems post operatively, such as failure of the graft and infection may eventually lead to failure of the surgery, regardless of the method used. Pre-existing sinus disease or susceptibility to sinus disease were thought to be factors in surgery failure.^[4, 5]

Cone-beam computed tomography scans of the maxillary sinus reveal incidental sinus disease in up to half of the individuals. Membrane thickening, polypoid masses or cysts, and acute sinusitis are the most common pathologies.^[6] Environmental pollutants, allergens, smoke, immunological and inflammatory disorders, and

rhinogenic reasons all play a role in the etiology of sinus membrane pathology.^[7]

Patients with chronic sinusitis may suffer acute postoperative sinusitis so it is relatively contraindicated.^[8] If there are no symptoms, sinus lifting can be used effectively.^[9] Membrane perforation, sinusitis, cyst formation, wound dehiscence, sequestration, loss of bone grafts, excessive bleeding, and potentially future implant failure have all been reported as intraoperative and postoperative complications.^[10]

As a guideline, a classification of four categories was proposed for determining when augmentation procedures, such as sinus lift and graft method, should be performed.^[11] The goal of this study was to assess the outcome of subjects with chronic sinusitis [only the subjects that had the criteria of Category 3 were involved] versus those with healthy sinuses who underwent lateral sinus floor augmentation with simultaneous implant placement.

PATIENTS AND METHODS

This prospective comparative clinical study was conducted in accordance with the Guidelines of Helsinki Declaration. It was accepted by the Ethical

Committee of Faculty of Dentistry, Mansoura University (No. A07040122).

Population:

12 Patients seeking prosthetic rehabilitation of posterior maxilla using dental implants were selected from the Outpatient Clinic of Oral and Maxillofacial Surgery Department, Faculty of Dentistry, Mansoura University, Egypt. All participants were educated about their problem, informed about the nature of the treatment procedure, treatment options, and the possible postoperative sequelae. They all signed the required informed consent before treatment. Patients with active sinusitis, sinus obliteration, major bony septa, poor oral hygiene, systemic diseases and/or conditions affecting bone were excluded.

Grouping:

Group I; consisted of 6 healthy maxillary sinuses (where 10 dental implants were placed), Group II; consisted of 6 maxillary sinuses with chronic sinusitis (Category 3) that identified radiographically by the presence of Schneiderian membrane thickening > 6 mm as shown below ^[11] (where 10 dental implants were placed).

Category	Radiographic Criteria	Surgical Augmentation
1	*No Pathology. *Around 2mm Thickening of Sinus Membrane	*Safe.
2	*2-5mm Thickening of Sinus Membrane.	*Not Completely Contraindicated *Should be used with Caution
3	*6-9mm Thickening of Sinus Membrane. * With or without Partial Sinus Obliteration.	* Contraindicated.
4	*6-9mm Thickening of Sinus Membrane. *With Inflammation or Infection e.g., Odontogenic Sinusitis, Mucocele.	* Contraindicated.

Surgical Procedures:

Under aseptic conditions, posterior superior alveolar nerve block and local infiltration were injected using

4% articaine with 1:100,000 epinephrine. All surgical procedures were performed after induction of local anesthesia and all these procedures were performed by the first author.

A para-crestal incision was made with releasing incisions so that a three-line mucoperiosteal flap was obtained to provide adequate access and visualization of the entire ridge crest and lateral wall. A bony window was created using Dentium Advanced Sinus Kit (DASK) (Figure1).

Sinus membrane was gently detached from the boundary of the bony window using a dome-shaped sinus curette. Then membrane elevation was completed till reaching the desired height using the other sinus curettes. The obtained space was grafted by a particulate bone graft, dental implants were placed simultaneously, then completion of bone grafting at the lateral side was done. Finally, all flaps were repositioned and sutured.

Postoperative medications:

For five days; Antibiotic 1g tablet was taken twice daily (Amoxicillin 875 mg and clavulanic acid 125 mg)¹ , Anti-inflammatory tablet was taken three times daily (Chymotrypsin 14 micro Katal and Trypsin 5 micro Katal)² , Decongestant tablet was taken once daily (Paracetamol 650mg, Chlorpheniramine maleate 4mg, Pseudoephedrine hydrochloride 60mg)³ in addition to decongestant nasal drops (Xylometazoline Hydrochloride 0.1% w/v)⁴ .

Clinical Follow-Up: All Patients were recalled two weeks postoperatively for suture removal and evaluation of healing at first and third months for any signs of infection (headache, locoregional pain, cacosmia, inflammation of oral buccal mucosa, rhinorrhea, unilateral nasal discharge or mucosal fistula).

Radiographic Evaluation: CBCT was done preoperatively to measure the bone height sub-antrally (T0). Then 6-months postoperatively another CBCT was done to measure the average of total bone height (T1). At that point the average of Gained Bone Height could be measured by subtracting the two values (T1-T0).

Data Analysis:

Qualitative data were presented as N (%). Chi-Square test was used to compare categorical data. Quantitative data were initially tested for normality using Shapiro-Wilk's test with data being normally distributed if p>0.050. Presence of significant outliers (extreme values) was tested for by inspecting boxplots. Quantitative data were presented as mean ± standard deviation (SD).

1 Augmentin, Glaxo SmithKline Pharmaceuticals Ltd., USA.

2 Alphintern, Amoun. Egypt.

3 Congestal, Sigma, Egypt.

4 Otrivin, NOVARTIS PHARMA S.A.E., Cairo, Egypt.

To compare quantitative data for two groups, Independent-Samples t-test was used. Correlation between a dichotomous and quantitative data was done by Point Biserial test while correlation between two quantitative data was done by Pearson's correlation. One-Way ANCOVA was used to determine whether there are any statistically significant differences between the adjusted population means of two independent groups. For any of the used tests, results were considered as statistically significant if p value ≤ 0.050 . Appropriate charts were used to graphically present the results whenever needed.

CASE PRESENTATION

Male patient aging 38 years old with placement of four dental implants at posterior right maxilla (only the implant that replaced upper second molar was included in the study). (Figure 2)

Statistical analysis:

Data were entered and analyzed using IBM-SPSS software (IBM Corp. Released 2019. IBM SPSS Statistics for Windows, Version 26.0. Armonk, NY: IBM Corp.).

Results

This study involved 12 participants:

Group I: 6 Participants with normal maxillary sinuses in which 10 dental implants were placed (N=10). They were 5 males and one female. Their mean age (years) \pm SD was 34.3 ± 9.4 .

Group II: 6 Participants with chronic sinusitis in which 10 dental implants were placed (N=10). They were also 5 males and one female (sex-matched, $P = 1.000$ by Chi-Square test). Their mean age (years) \pm SD was 33.2 ± 9.4 (age-matched, $P = 0.834$ by Independent-Samples t-test).

I. Clinical Evaluation:

Regarding infection, there was no sinus infection in group I compared to one sinus with one implant (that was lost) in group II that showed sinus infection (unilateral nasal discharge), three months post-operatively. The dental implant and grafting material were removed and the affected sinus was carefully irrigated. In addition to prescription of 300 mg capsule Clindamycin hydrochloride⁵ twice daily and 500 mg tablet metronidazole⁶ three times daily, for 7 days.

⁵ Clindamycin, Rivopharm, Ltd, UK.

⁶ Flagyl, Sanofi-Aventis, Egypt.

II. Radiographic Evaluation:

Thickness of Sinus Membrane (mm) in group II

The mean \pm SD of the thickness of sinus membrane (mm) in chronic sinusitis group was 9.2 ± 2.3 , ranging from 6.1 to 12.3 mm.

Gained Bone Height (Table 1 & Graph.1)

The mean of bone gain in Group I was 7.24 ± 1.45 . Also, Group II: showed mean bone gain of 7.23 ± 1.78 (Figure3). This is represented in table 1 that shows no statistically significant difference in bone gain between the two groups with very small effect size.

One-way ANCOVA test (Table 2 & Graph.2)

An ANCOVA was run to determine the effect of a control group (normal sinuses) and Chronic sinusitis on post-intervention bone height (mm) after controlling for pre-intervention bone height (mm).

Table (2) shows the adjusted and unadjusted means and variability for post-intervention bone height with pre-intervention bone height as a covariate. There was a linear relationship between pre- and post-intervention bone height (mm) for each group, as assessed by visual inspection of a scatterplot.

There was homogeneity of regression slopes as the interaction term was not statistically significant, $F(1,16) = 0.123$, $p = 0.730$. Standardized residuals for the two groups and for the overall model were normally distributed, as assessed by Shapiro-Wilk's test ($p = 0.907$ for group I, 0.825 for group II, and 0.701 for overall model).

There was homoscedasticity and homogeneity of variances, as assessed by visual inspection of a scatterplot and Levene's test of homogeneity of variance ($p = 0.424$), respectively. There were no outliers in the data, as assessed by no cases with standardized residuals greater than ± 3 standard deviations.

After adjustment for pre-intervention bone height (mm), there was no statistically significant difference in post-intervention bone height (mm) between the two groups, $F(1, 17) = 0.014$, $p = 0.908$, partial $\eta^2 = 0.001$.

Bone Gain and Sinus Status (Table 3 & Graph.3)

This table shows no statistically significant association between bone gain and presence of CS and sinus wall thickness in CS patients.

Figure 1: Sinus Elevation Kit (DASK); Drills and Sinus Elevation Instruments




Figure 2: Created bony window with Lateral Sinus Lifting (A), Simultaneous Implant Placement (B), Sinus Grafting using Particulate Bone Graft (C), Membrane Placement (D), Flap Repositioning and Suturing (E), Immediate Postoperative CBCT (F).

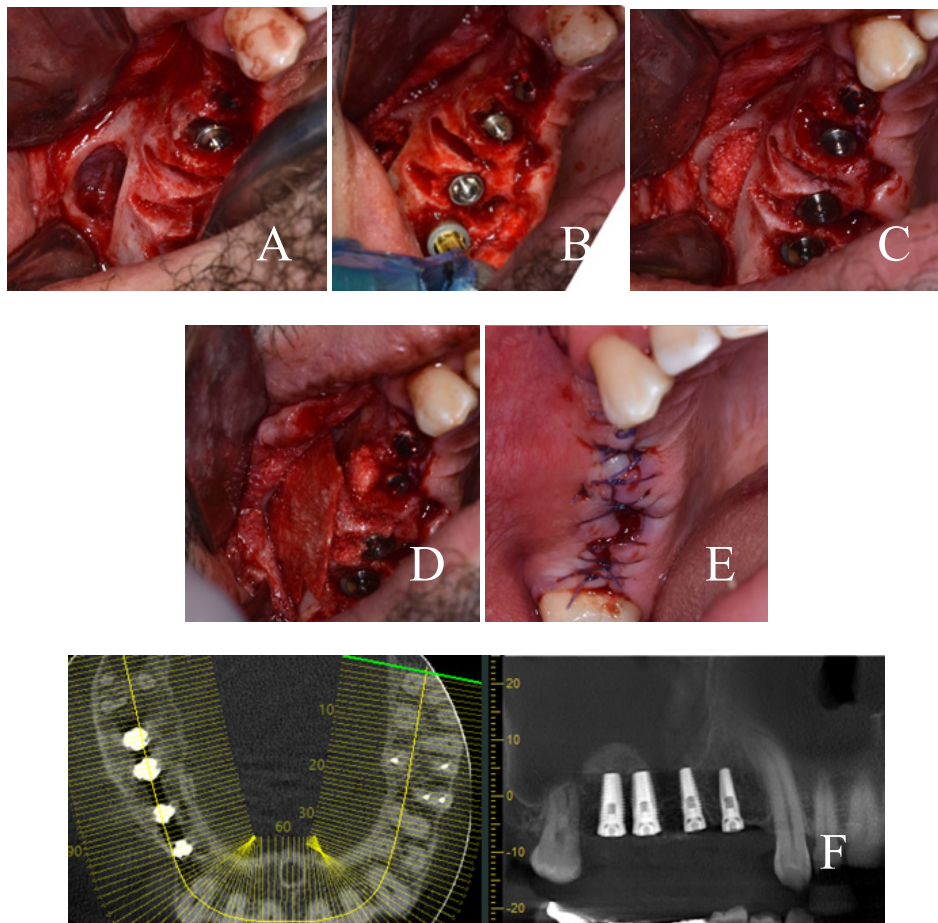


Figure 3: (A) Pre-operative cross-section on CBCT showing chronic sinusitis (mucosal thickening > 6mm) with low subantral bone height, (B) 6-month post-operatively showing increased vertical bone height.

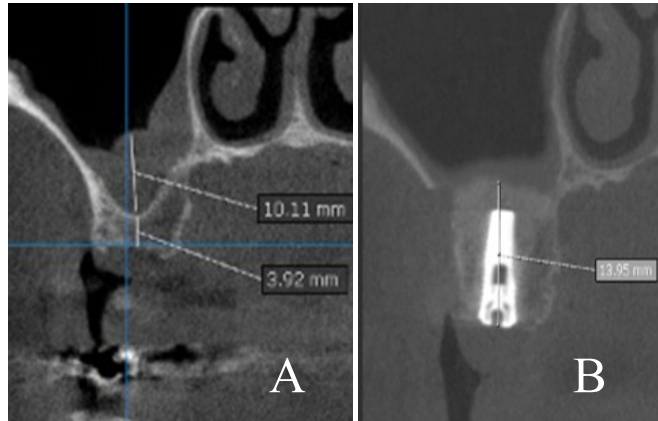
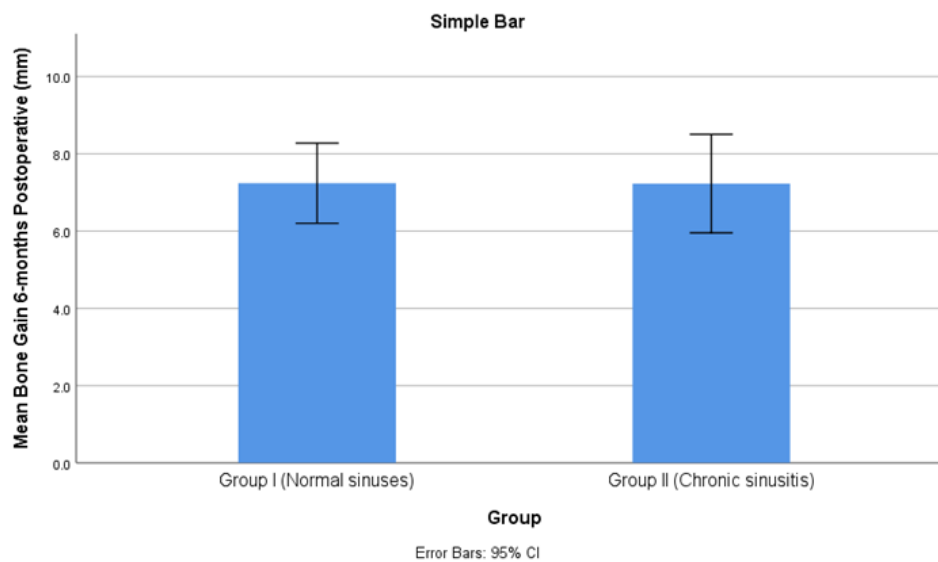


Table (1): Comparison of Gained Bone Height in the two groups

Bone gain (mm)	Group I	Group II	t value	P value
Mean	7.24	7.23	0.014	0.989
SD	1.45	1.78		
SE	0.46	0.56		
Cohen's d	0.0061478			

Notes: SD=standard deviation. SE=standard error of the mean. Cohen's d is an estimate of the effect size. Test of significance is Independent-Samples t-test.

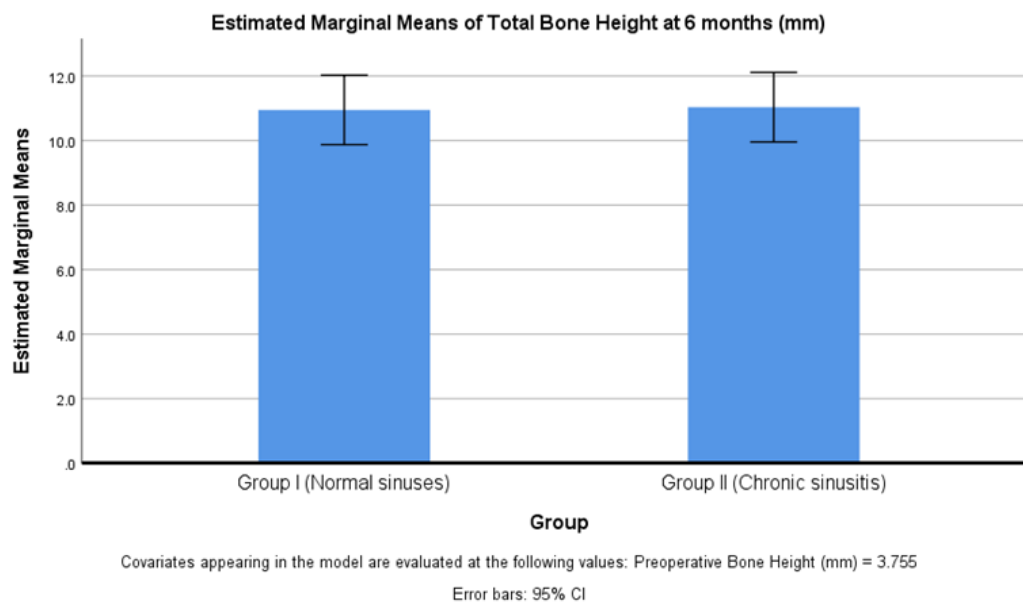


Graph (1): Comparison of Gained Bone Height in the two groups

Table (2): Adjusted and unadjusted means and variability for post-intervention bone height with pre-intervention bone height as a covariate

Group	N	Unadjusted		Adjusted	
		\bar{x}	SD	\bar{x}	SE
Group I	10	10.93	1.34	10.95	0.51
Group II	10	11.05	1.77	11.03	0.51

Notes: N = Number of participants, \bar{x} = mean, SD = standard deviation, SE = standard error. Bone height was measured in mm.

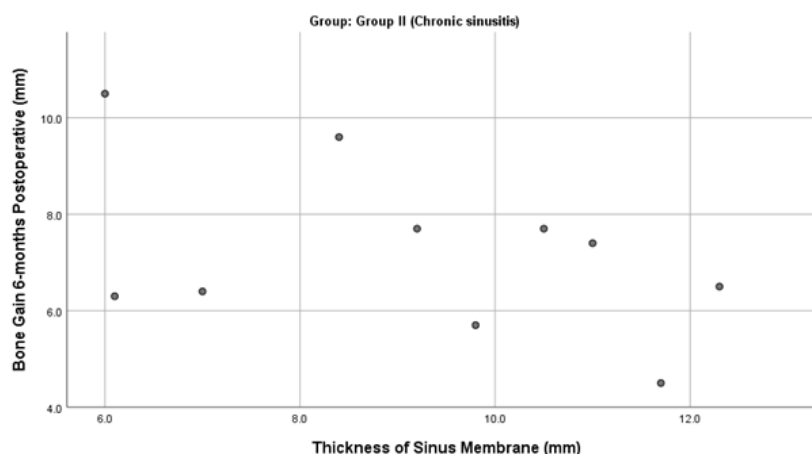


Graph (2): Adjusted and unadjusted means and variability for post-intervention bone height with pre-intervention bone height as a covariate

Table (3): Correlation between Bone Gain and Sinus Status

Sinus status	Correlation coefficient	P value
Presence or absence of CS	-0.003	0.989
Sinus wall thickness in CS	-0.459	0.182

Notes: CS = Chronic Sinusitis. Correlation coefficient is point biserial correlation coefficient (rpb) for presence or absence of CS, and Pearson's correlation coefficient (r) for sinus wall thickness.



Graph (3): Simple Scatter of Bone Gain 6-months Postoperative (mm) by Thickness of Sinus Membrane (mm)

DISCUSSION

The average thickness of the sinus membrane is 0.8 mm; however, with periodontal infection, chronic sinusitis, or both, the membrane thickens. Sinus lifting with a lining of more than 2mm is a relative contraindication; while, sinus lifting with a thickening more than 5mm is contraindicated.^[11, 12, 13]

Several studies have looked into the occurrence of chronic sinusitis in those who are planning for sinus augmentation, with varied outcomes. Beaumont et al stated that, 40 percent of patients with periodontal disease who were scheduled for sinus augmentation had chronic sinusitis.^[14]

Many studies have found that patients with sinusitis pre-operatively are more likely to acquire postoperative sinus complications. Mucosal thickening or polyp-like lesion are the most common CT findings in the maxillary sinus. Patients with maxillary sinus CT imaging had 23.7 %–28.2 % mucosal thickening, and 3.6 %–6.5 % sinusitis. According to their records, mucosal thickening showed the highest percentage.^[9, 15]

In agreement with Hammuda A.A. and Ghoneim M.M.,^[16] who conducted a study on patients having chronic sinusitis with the criteria of Category 2 that showed insignificant difference between the groups. The results of the current study also revealed no significant difference between the two groups in the average gained bone height, that was 7.24 ± 1.45 mm and 7.23 ± 1.78 mm, in groups I and II respectively.

Despite of dealing with Category 3 in the present study, that should be taken into consideration. This finding suggests that Category 3 chronic sinusitis might have just a little impact on sinus augmentation.

In the present study, only one sinus (16.7%) with one dental implant (that was lost) in group II showed postoperative infection three months postoperatively. This result was controversy with Irinakis et al, who reported postoperative graft infection (5%) after maxillary sinus lift.^[17] That higher percentage might be returned to the small sample size in addition to dealing with Category 3 chronic sinusitis.

CONCLUSION

Chronic sinusitis with a thickening of Schneiderian membrane > 6 mm may not be considered as a contraindication of sinus lifting and grafting with simultaneous implant placement.

LIMITATION:

Small sample size that needs to be increased in future studies.

CONFLICT OF INTEREST

The authors declare no conflict of interest.

REFERENCES

1. Sharan A, Madjar D. Maxillary sinus pneumatization following extractions: a radiographic study. *International Journal of Oral & Maxillofacial Implants*. 2008;23(1).
2. Lee S-W, Park Y-W. Minimally Invasive Lateral Approach through Circular Window with a Diameter of 5 to 6 mm for Maxillary Sinus Floor Elevation with Simultaneous Implant Placement: Retrospective Study. *Applied Sciences*. 2021;11(17):8244.

3. Kara İM, Küçük D, Polat S. Experience of maxillary sinus floor augmentation in the presence of antral pseudocysts. *Journal of oral and maxillofacial surgery*. 2010;68(7):1646-50.
4. Tsai C-F, Pan W-L, Pan Y-P, Chan C-P, Ju Y-R, Wang Y-M, et al. Comparison of 4 sinus augmentation techniques for implant placement with residual alveolar bone height \leq 3 mm. *Medicine*. 2020;99(46).
5. Batas L, Tsalikis L, Stavropoulos A. PRGF as adjunct to DBB in maxillary sinus floor augmentation: histological results of a pilot split-mouth study. *International journal of implant dentistry*. 2019;5(1):1-7.
6. Ritter L, Lutz J, Neugebauer J, Scheer M, Dreiseidler T, Zinser MJ, et al. Prevalence of pathologic findings in the maxillary sinus in cone-beam computerized tomography. *Oral Surgery, Oral Medicine, Oral Pathology, Oral Radiology, and Endodontology*. 2011;111(5):634-40.
7. Pazera P, Bornstein M, Pazera A, Sendi P, Katsaros C. Incidental maxillary sinus findings in orthodontic patients: a radiographic analysis using cone-beam computed tomography (CBCT). *Orthodontics & craniofacial research*. 2011;14(1):17-24.
8. Alkan A, Çelebi N, Baş B. Acute maxillary sinusitis associated with internal sinus lifting: report of a case. *European journal of dentistry*. 2008;2(01):69-72.
9. Kfir E, Goldstein M, Abramovitz I, Kfir V, Mazor Z, Kaluski E. The effects of sinus membrane pathology on bone augmentation and procedural outcome using minimal invasive antral membrane balloon elevation. *Journal of Oral Implantology*. 2014;40(3):285-93.
10. Lundgren S, Cricchio G, Hallman M, Jungner M, Rasmusson L, Sennerby L. Sinus floor elevation procedures to enable implant placement and integration: techniques, biological aspects and clinical outcomes. *Periodontology* 2000. 2017;73(1):103-20.
11. Tadinada A, Fung K, Thacker S, Mahdian M, Jadhav A, Schincaglia GP. Radiographic evaluation of the maxillary sinus prior to dental implant therapy: a comparison between two-dimensional and three-dimensional radiographic imaging. *Imaging science in dentistry*. 2015;45(3):169-74.
12. Hudwekar AD, Beldar A, Murkute S, Lendhey SS, Thamke M. Aloe vera on wound healing after periodontal flap surgery in chronic periodontitis patient: A randomized control trial. *Journal of Oral Research and Review*. 2019;11(2):72.
13. Van Den Bergh JP, Ten Bruggenkate CM, Disch FJ, Tuinzing DB. Anatomical aspects of sinus floor elevations. *Clinical Oral Implants Research: Treatment rationale*. 2000;11(3):256-65.
14. Beaumont C, Zafiroopoulos GG, Rohmann K, Tatakis DN. Prevalence of maxillary sinus disease and abnormalities in patients scheduled for sinus lift procedures. *Journal of periodontology*. 2005;76(3):461-7.
15. Kim SW, Lee IH, Kim SW. Points to consider before the insertion of maxillary implants: the otolaryngologist's perspective. *Journal of periodontal & implant science*. 2019;49(6):346-54.
16. Hammuda AA, Ghoneim MM. Assessment of maxillary sinus lifting procedure in the presence of chronic sinusitis, a retrospective comparative study. *Annals of Medicine and Surgery*. 2021;66:102379.
17. Irinakis T, Dabuleanu V, Aldahlawi S. Complications during maxillary sinus augmentation associated with interfering septa: a new classification of septa. *The open dentistry journal*. 2017;11:140.