

Low-level laser biomodulation effect on marginal bone loss around implants supporting mandibular hybrid prosthesis in controlled diabetic patients: A randomized controlled trial

Noha Mohamed Elhusseiny¹, Iman Adel El-asfahani²

Maxillofacial prosthodontic department faculty of dentistry ain shams university,
Egypt¹, Prosthodontics department, faculty of dentistry, Minia university, Minia, Egypt²

ABSTRACT

The biomodulation effect of diode LASER 940 on marginal bone loss (MBL) around implants supporting mandibular hybrid prosthesis in controlled diabetic patients was evaluated. Twenty completely edentulous patients with moderately controlled diabetes mellitus (DM) (glycated hemoglobin (A1c [HbA1c] =8.1%–10.0 %) were selected to participate in this study. All patients received upper and lower complete dentures. Four mandibular straight implants were inserted in all patients then patients were divided randomly into control group (CG) and Laser group (LG). In LG diode LASER biomodulation with 940nm wavelength with energy 30J and 60 sec was applied around each implant. Both groups were immediately loaded with acrylic interim hybrid prosthesis after modifying complete lower denture. Interim prosthesis used during the follow-up period till full patient satisfaction was achieved then a definitive porcelain fused to metal hybrid prosthesis was fabricated. MBL was measured using digital periapical radiographs with standardized long cone paralleling technique at implant loading (0 months or baseline), 6 and 12 months. MBL was calculated at T1 (06- months), T6 (612- months) and T12 (012- months) follow-up periods.

LG showed statistically significant lower marginal bone loss MBL than the CG at T1 and no statistically significant difference in MBL at T6 and T12 follow-up periods. Within the limits of this study, low-level LASER biomodulation (LLL) may significantly decrease the MBL around immediately loaded implants supporting mandibular hybrid prosthesis in controlled diabetic patients at (T1) but has no effect on MBL in the subsequent (T6 and T12) follow-up periods

Key Words: Bio-modulation, LASER, Implant supported mandibular hybrid prosthesis, Diabetes mellitus.

Received: 28 February 2022, **Accepted:** 6 April 2022.

Corresponding Author: Noha M, Elhusseiny, lecturer of Prosthodontics, Faculty of Dentistry, Ain Shams University, Egypt, Tel : 0224958954, Mobile: 01006798501, E-mail: nohafayad@dent.asu.edu.eg

ISSN: 2090-097X, January 2022, Vol. 13, No. 1

INTRODUCTION

Dental implant is considered as one of the most widely employed procedures in dental practice especially for edentulous patients as they improve the quality of life with reasonable cost.^[1] Many factors affect the success rate of dental implants either local or systemic factors. Systemic conditions that negatively influence the success rate of implants include osteoporosis, immune deficiency virus infection and diabetes mellitus^[2,3,4]

Diabetes mellitus (DM) is a metabolic disease with defective insulin secretion resulting in chronic hyperglycemia. Bone is affected by DM, with reduction in osteoblast activity and imbalance between the coupling of bone formation and resorption, resulting in an imbalance in bone turnover. Such imbalance leads to bone mineral density (BMD) reduction that leads to the development of the clinical condition of osteoporosis and increase the incidence of fractures and delayed healing due to the poor bone quality.^[5]

Developing technologies that can prevent bone loss and increase bone mass in DM are essential that includes me

dicaments, physical activity programs and recently, low level laser biomodulation (LLL).^[6] Laser biomodulation has a stimulatory effect on bone tissue that increases bone cell proliferation and accelerate bone metabolism in a series of different pathological conditions including DM^[7] The longevity of dental implants is highly dependent on integration between implant and surrounding bone where osseointegration is becoming the most accepted phenomenon for success in implants' procedures.^[8]

Diode LASER is antibacterial in nature and can be used to varying degrees to disinfect the osteotomy to improve dental implant bone contact either before implant placement or after immediately loaded implant supported prosthesis. Some studies showed the alveolar bone height was preserved while the bone density was increased in the side exposed to low level LASER.^[9,10] Low level LASER application stimulates bone formation and maturation around the implants.

On investigating the effects of applying of low-level LASER on human osteoblastic cell grown on titanium discs, it was found that LLLB stimulates the expression of

osteoblastic phenotype in cells cultured on titanium discs.^[11,12] The Biomodulation mechanism lies in LASER energy which is absorbed by cell mitochondria which increase the release of ATP adenosine triphosphate in the cell which is important for the growth factors and cell proliferation.^[13]

LLLb increases bone repair at early stages of healing. Other research shows that LLLb promoted the osseointegration of implants with poor initial stability, particularly in the initial stages of bone healing. In addition, LLLb enhanced peri implant bone repair, bone implant contact (BIC) and new bone formation when used every 48 hours for 2 weeks.^[14-20]

Owing to the scarcity of research work exploring the effect of LLLb on marginal bone loss (MBL) around dental implants especially in moderately controlled DM patients. The purpose of this study was to evaluate the effect of LLLb on radiographic outcomes (MBL) around implants supporting hybrid mandibular prosthesis in controlled diabetic patients

METHODOLOGY

Twenty edentulous patients with age ranged between 40-60 years old were selected to share in this study from the out-patient clinic of Prosthodontic department, faculty of dentistry, Ain-shams university.

Inclusion criteria

were patients having adequate interarch space, normal maxillomandibular relation, adequate bone height and width (to accommodate a 10 mm height and 4 mm diameter implant) in the edentulous mandible verified by preoperative CBCT, patients with moderately controlled type 2 diabetes mellitus with glycosylated HbA1c ranging from 8.1% to 10.025% on regular 3-month checks, and at least 6 months since last extraction.

Exclusion criteria:

were patients with heavy smoking habits, history of cardiovascular disorders or liver diseases and history of anticoagulant therapy, patients with history of bisphosphonate therapy or with any disease that would prevent healthy osseointegration of dental implants.

Patient's approval:

- The whole surgical and prosthetic protocol was explained to the patients in details before starting the treatment. The patients were informed about the benefits from the research. Patients agreed to be part in the study and signed on an informed consent form. All data were kept confidential.

Surgical and prosthetic procedures

Upper and lower complete dentures were constructed

using the conventional steps for all patients. Dentures were checked for good retention, stability, patient satisfaction, good esthetic, phonetics, proper vertical dimension, occlusion and mastication. Dentures were delivered to the patients 3 months before implant insertion to enhance muscle adaptation.

The lower denture was marked using fiducial markers on seven separate positions on different levels to the occlusal plan on the buccal and labial flanges of the denture in contact area between artificial teeth to aid in planning of the implant sites and markers act as radiopaque markers material, so no scatter occurs during scanning. The implant planning software program allowed the clinicians to study the bone bed in relation to the position of the artificial teeth. Implant planning was done for all patients with same clinician.

CBCT was done while patient wearing the modified lower complete denture and patient biting in centric occlusion. The implant planning software program was used to allow the clinician to study the bone bed in relation to the position of the artificial teeth. Four straight conventional interactive implants (Implant direct conical connection, USA) of height 10mm and diameter 4mm were planned for all patients.

Surgical protocol:

All patients received four straight mandibular implants in the preplanned locations according to the available adequate bone guided by preoperative cone beam computerized tomography (CBCT) in bone density not less than D2 following the standard protocol steps with sequential drilling for each implant then each implant was inserted and screwed with a final torque of 45 N/cm using torque ratchet to the bone level. Same oral and maxillofacial surgeon performed the surgical procedures.

Randomization of patients to be allocated into 2 groups was done using a computer software (Minitab 17, State College, PA), after providing the software with patients information, into two groups; control group (CG) and LASER group (LG).

Low-level laser Biomodulation (LLLb):

For LG, Biomodulation was done using -Semiconductor diode (Medium InGaAsP, Epic Biolase company, class IV LASER, USA) with wavelength 940 nm (0.5mWatt, 30J and 60 sec) in continuous mode. Biomodulation was applied apically from the labial site of the outer cortical plate of bone to increase the area exposed to low level LASER so crestal bone height was preserved and the bone density was increased.^[11]

Also biomodulation was done coronally to the osteotomy around each implant for 60 sec in a non-contact mode (Figure 1). The LLLb was applied by the same clinician (G.R.M.) after training, instruction, and calibration. Both patient and clinician followed laser safety measures by wearing protective eye goggles.

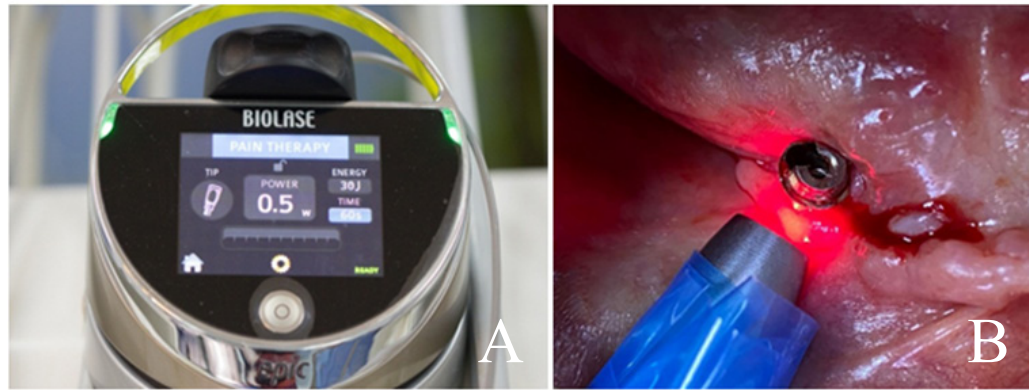


Figure (1): a) Epic diode 940nm device, b) Application of diode laser apically from the labial site of the outer cortical plate of bone

Prosthetic protocol

Multi-unit abutments were screwed to the four implants with torque 25N .

Placement of titanium sleeves

Index position of the abutments was done using bite material (3M ESPE imprint 4 bite VPS bite registration material, Germany) in fitting surface of already presented lower complete denture.

Four holes were made in denture for titanium sleeves, holes were large enough and rechecked intraoral for proper seating. Titanium sleeves were screwed to the abutments and hollowed out denture was placed over the titanium sleeve to check denture passive fit .

Reduction of titanium sleeves height was done by using a marker (red high spot indicator, Arti spot 2, Köln, Germany) to mark proper height of the sleeves to the level of occlusal plan before pick-up step .The sleeves were trimmed of excess height was done by using metallic disc till the previously determined mark. Sleeves were screwed to the abutments and hollowed out denture was resealed, and the patient is asked to bite in centric occlusion.

Rubber dam material (Sanctuary dental dam, Sanctuary health SDN, BHD, Malaysia) was used after being cut into small sized squares and attached around the titanium sleeves. Small piece of cotton was used on the top of the screw access of the titanium sleeves so no pick-up material blocks screw access opening .

Pick up of titanium sleeves -cold curing acrylic resin (Chair side hard denture relining material Promedica dental material GmbH ,Germany) was used to pick up the titanium sleeves in the lower denture .Cold curing acrylic resin was injected around the sleeves and with the holes created in the denture .The denture was seated, excess resin on the top access of the sleeves was removed and the patient was asked to bite in centric occlusion till the resin was totally set .

Cotton pieces positioned on the top of the sleeves was removed with explorer probe and with a unigrip screwdriver the prosthesis was unscrewed. Screws were kept aside till interim hybrid prosthesis is being finished.

Converting lower complete denture to lower interim hybrid prosthesis

The borders, and flanges were trimmed . A sharp angles or edges were removed too. The tissue side of the acrylic interim prosthesis was made convex and polished for better hygiene. (Figure 2).

The acrylic interim hybrid prosthesis was then screwed back to the abutments in the mouth occlusion was rechecked with articulator paper to be adjusted. Simultaneous bilateral point contacts on all teeth, in lateral and protrusive movement , group function was used on all anterior teeth . The screw access was filled with a small piece of cotton and composite resin material was applied (Filtek supreme ultra-universal restoration, GmbH, Germany) to close screw access and avoid food entrapment in it . Acrylic interim prostheses are frequently used as provisional restorations for immediate loading. Conversion of the patient's satisfactory existing denture to a screw-retained implant fixed prosthesis (hybrid prosthesis) was described to splint implants together using acrylic resin denture base and enables the clinician to deliver the prosthesis in a few hours.

All the patients were given strict oral hygiene instructions as it significantly affect bone loss around dental implant. Patients were advised to follow soft, nutritious diet and chew carefully and avoid hard or tough foods during first 4 weeks . In addition, several recall visits every 3 month were scheduled to monitor plaque levels during the course of the study.

At the last follow-up visit, the final hybrid prosthesis was fabricated as patients were already satisfied with the shape and form of interim hybrid prosthesis. Final impression for the four straight implants was taken with implant verification jig and a custom tray were provided for a direct open tray impression technique using polyether impression material (Pentamix, 3M ESPE).

The implant analogues were screwed to the transfer coping. The impression was poured to obtain final stone cast and fabrication of final mandibular hybrid prosthesis porcelain fused to the metal framework (PFM) was done. (Figure 3)

Figure (2): a) Trimmed titanium sleeves , b) Attachment of rubber dam, c) Hollow out space in denture for titanium sleeves, c) Prosthesis was unscrewed after pick- up was done & flanges reduced .

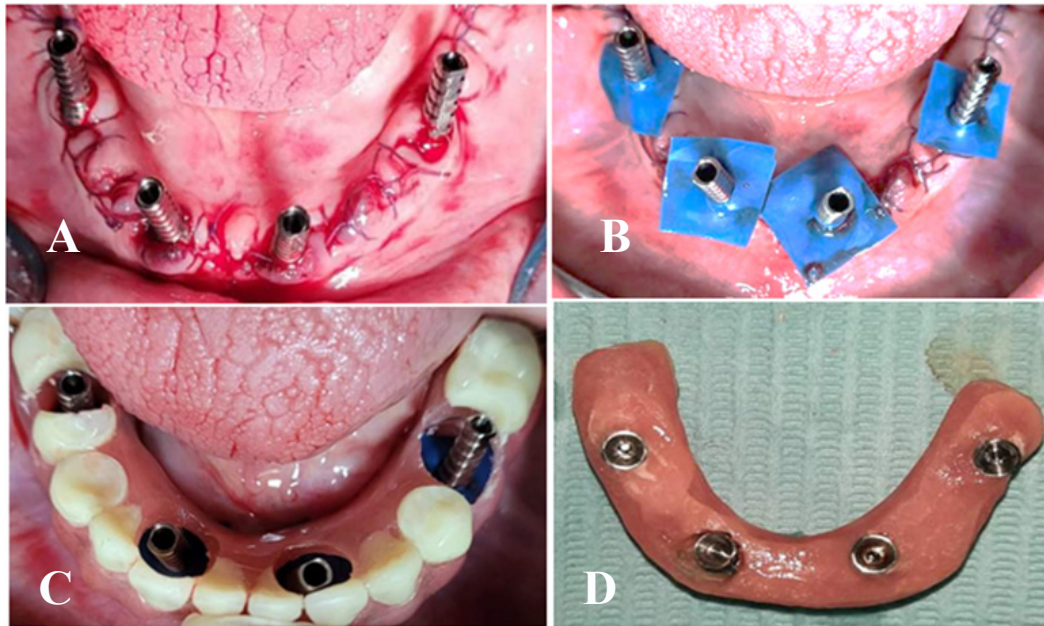
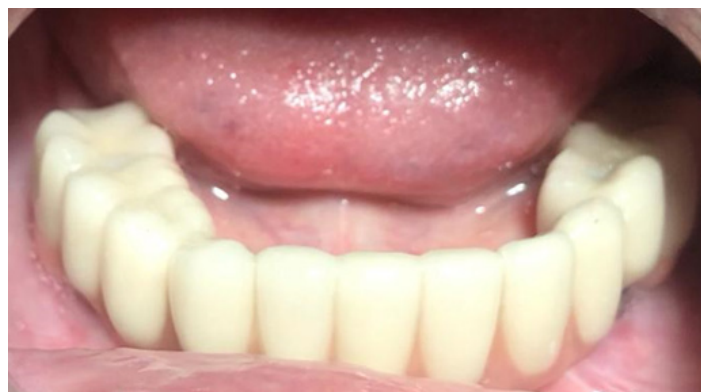

Figure. (3): The definitive PFM hybrid prosthesis post one year follow-up



Radiographic outcomes:

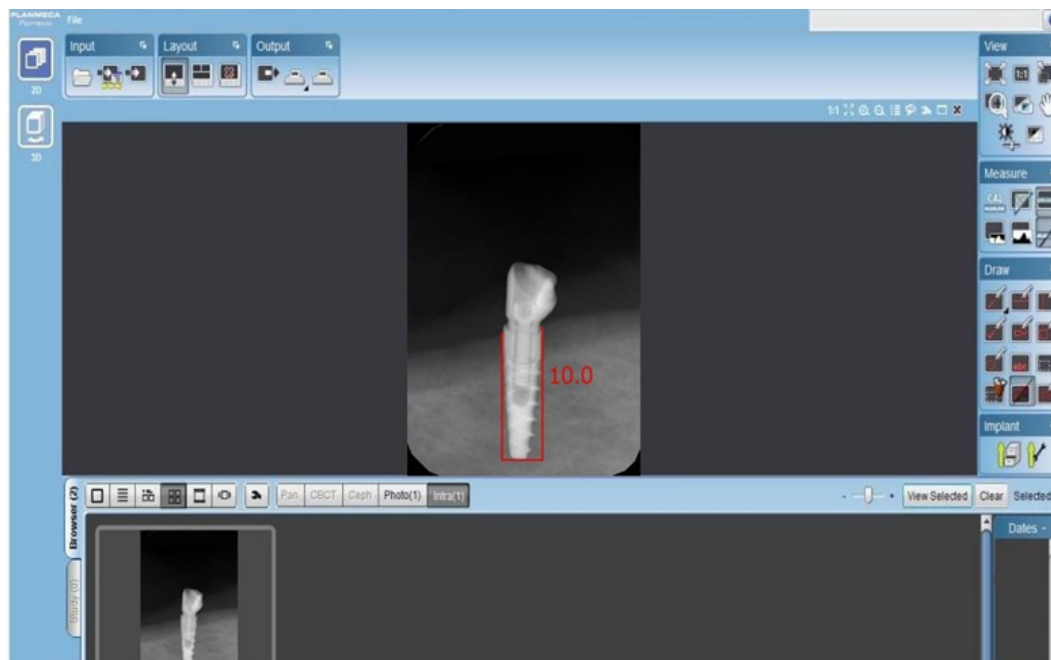
Marginal bone height was radiographically evaluated in both groups CG and LG at time of immediate implant loading, after 6 and 12 months where mesial and distal marginal bone height measures for each implant were assessed. Standardized long cone paralleling technique was used to provide periapical follow up radiographs. Rinn technique (XCP Extension Cone Paralleling, DENTSPLY Rinn Corporation, USA) was followed in all follow up visits by the same clinician blinded by the nature of the study. Rinn tech uses Rinn periapical film holder, XCP instrument for extension long cone to mount x-ray tube and phosphorous x-ray plate to receive image.

Standardization of the phosphorous x-ray plate position in every follow up visit is done by folding a putty rubber base impression material (Express XT VPS, 3M ESPE) around the bite-block then a bite registration was obtained for each plate in closed mouth position, the putty bite-block with the occlusal registration was saved aside for the follow-up recall visits. Same x-ray machine ((Fona XDC, Fona, Assago, Italy) was used with the following exposure parameter for all patient's follow up visits for standardization (8 milliamperes and 70 kilovolts for 0.6 seconds with 35 cm focal film distance).

Image data captured by the phosphorous x-ray plate was read by scanner to give digital image. linear measurements were done on a viewer software (Romexis Viewer software, Planmeca, Helsinki, Finland) for standardization and avoiding human errors or distortion, calibration was done by the visible radiographic implant length of each implant was measured on each image and compared to the actual known length of the implant (10 mm).

Images were imported to the software and a horizontal line was drawn tangential to the implant apex and perpendicular to its long axis. Then two lines were drawn tangential to the implant mesial and distal surfaces starting from the first bone implant contact extending to the horizontal line to give the measure of the mesial and distal marginal bone height (Figure 4). The marginal bone loss follow-up value after 6 months (T1) was calculated by subtracting follow-up visit marginal bone height from the baseline (0 months) marginal bone height. The same was done to calculate the MBL in 12 months (T12) follow-up period. To calculate the MBL in the 6-12 months (T6) follow-up period, marginal bone height at 12 months was subtracted from the marginal bone height at 6 months.

Figure.(4): The linear measurements were obtained by calculation of the radiographic length of the individual implant, length of mesial and distal peri-implant marginal bone height



Statistical analysis:

The data were collected and tabulated to be statistically analyzed. SPSS statistical analysis software (IBM SPSS Statistics version 21, NY USA) was used to analyze the Data. Kolmogorov-Smirnov and Shapiro-Wilk tests were used to detect the normal distribution of data. Two-way analysis of variance test (ANOVA) test was conducted to compare the MBL in both groups (CG and LG). The differences between groups were considered statistically significant if the p-value was less than or equal to 0.05 ($p \leq 0.05$).

RESULTS

Twenty completely edentulous patients (13 males and 7 females) with moderately controlled diabetes were enrolled in this study. Their mean age \pm standard deviation was 52 ± 7.39 years. All implants in the CG were successful except one implant which showed signs of failure at 6 months follow up visit. On the other hand, no implant failure was observed in LG. hence, the survival rates in the CG and LG were 97.5 % and 100 % respectively. On comparing the survival rate in both groups, it did not significantly differ between both groups (log rank test, $P= 0.238$). Kolmogorov-Smirnov and Shapiro-Wilk tests proved that MBL data were normally distributed.

Along the study follow-up periods, the MBL was assessed at the mesial and distal of the implants in the CG and LG. The mean of the mesial and distal MBL around each implant in each group was calculated to provide the mean MBL around the implant in the T1, T6 and T12 follow-up periods. Afterwards the mean and standard deviation of the MBL around all implants in each group at each follow-up period was calculated (table 1). Generally, there was a gradual increase in the values of MBL around implants along the whole study period (from baseline till 12 months) as presented in (Figure 5).

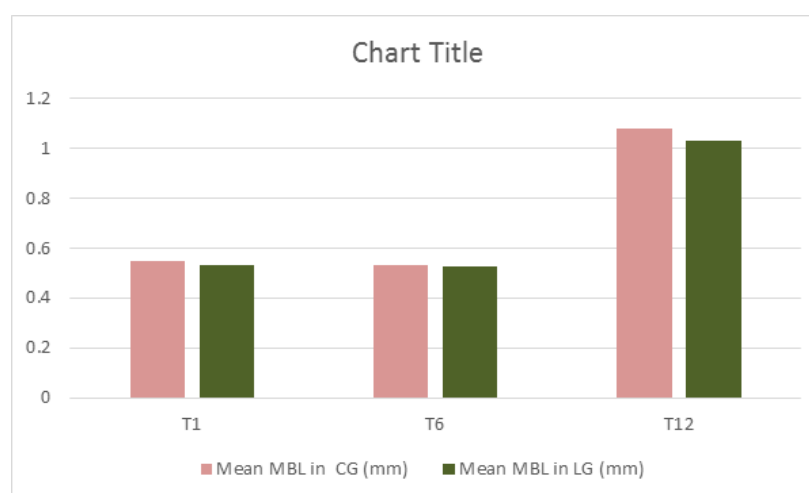The MBL in the CG was 0.55 ± 0.02 , 0.53 ± 0.01 , 1.08 ± 0.01 in T1, T6 and T12 follow-up periods respectively. The MBL in the LG was 0.50 ± 0.01 , 0.52 ± 0.03 , 1.02 ± 0.02 in T1, T6 and T12 follow-up periods respectively. Although the MBL in the LG was less than MBL in the CG in all the study follow up periods, the ANOVA test showed a statistically significant difference between both groups' MBL in the T1 follow up period only ($p \leq 0.05$).

No statistically significant difference was obtained between the MBL in the CG and LG at the T6 or the T12 follow-periods ($p \geq 0.05$).

Table (1): The mean marginal bone loss (in mm) and standard deviation(SD) in the CG and LG at the different follow-up periods

Follow-up Periods	Control group (CG)		Laser group (LG)		ANOVA P-value
	Mean	Standard deviation (SD)	Mean	Standard deviation (SD)	
0-6 months (T1)	0.55	0.02	0.50	0.01	0.014
6-12months (T6)	0.53	0.01	0.52	0.03	0.940
0 -12months (T12)	1.08	0.01	1.02	0.02	0.157

The significance level was set at $P \leq 0.05$

Figure (5) : The mean marginal bone loss in the CG and LG in the T1, T6 and T12 follow-up periods

DISCUSSION

Rehabilitation with dental implant supported prostheses in diabetic patients is considered a valuable treatment modality, nevertheless it can be risky as implants are subjected to failure owing to defects in osseointegration in case of uncontrolled plasma glucose levels. In our study the implant survival rates were high in both groups despite the patients' moderate glycemic control which was reported in several studies with immediately loaded implants if diabetic patients had controlled plasma glucose level [21,22]

The survival rate of implants in the two groups is attributed to the nature of the mandibular bone with increased density and the biomodulation using diode LASER in LG which improved the healing and accelerated bone regeneration [22]. The dose of LLLB used in the study may affect osseointegration of the implant but no standard protocol is reported [16]. The LASER radiation parameter were chosen based on previous studies [23,24]

The MBL in the CG was 0.55 ± 0.02 , 0.53 ± 0.01 , 1.08 ± 0.01 in the T1, T6 and T12 follow-up periods respectively. The MBL in the LG was 0.50 ± 0.01 , 0.52 ± 0.03 , 1.02 ± 0.02 in the T1, T6 and T12 follow-up periods respectively. Although the MBL in the LG was less than MBL in the CG in all the study follow up periods, the ANOVA test showed a statistically significant difference between both groups' MBL in the T1 follow up period only ($p \leq 0.05$). No statistically significant difference was obtained between the MBL in the CG and LG at the T6 or the T12 follow-periods ($p \geq 0.05$) but still successful osseointegration is present as the given values within the normal range of bone resorption 1.2 mm in the first year as been reported in literature [25,26]. The acceptable marginal bone loss in this study was due to implants inserted in the edentulous mandible most of them in anterior area of mandible which has dense bone with less liability to resorption. [27]

No statistically significant difference in MBL between groups after 6 and 12 months due to several causes; First, all implants used were 10 mm in length as permissible by bone anatomy of the selected patients and 4 mm in diameter as it has been reported that diameter is a key parameter for implant integration by increasing the surface area and increasing primary implant stability. [28-30] Second, Implant abutment interface (IAI) is a key point to success as it plays an important role in the survival of implant. Interactive implant was used in this study where its conical connection offers several advantages. Evidence had shown that conical IAI provides resistance to abutment movement, fatigue loading, maximum bending, torque loss and superior bacterial seal compared to other connection systems. [31]

If a gap is present at IAI, it becomes favorable for bacterial colonization which in return cause signs of inflammatory reaction by its by product causing marginal bone loss and finally peri-implantitis. [32] On the other hand, conical IAI geometry makes the gap IAI very narrow for bacterial passage. Third, the immediate loading protocol used decrease the possibility of bone loss that may occurs if implant uncovering and abutment connection [33]

Although there was no significant difference in MBL between groups except in the T1 follow-up period, the LG showed lower MBL than CG in all follow-up periods this may be due to the immediate effect of Biomodulation with diode 940nm LASER which is antibacterial in nature and can be used to varying degrees to disinfect a site. [34] similar research was conducted to study the effect of laser therapy on MBL in implant supported hybrid prostheses. Its results showed that there was no statistically significant difference in MBL between laser and control group along the whole follow-up period. These results are different from the current study results which may be due to the use of different type of laser biomodulation (Er,Cr:YSGG (2790 nm)) and different technique of laser application [35]

Diode LASER stimulates the osseointegration of the implant after irradiation immediately loaded. Some studies showed the alveolar bone height was preserved while the bone density was increased in the side exposed to low level laser.^[10,11,18,36,37]Low level laser application stimulates bone formation and maturation around the implants.^[12,14]

CONCLUSION

Within the limitations of this study, it can be concluded that the low-level LASER biomodulation (LLL) may significantly decrease the MBL around immediately loaded implants supporting mandibular hybrid prosthesis in controlled diabetic patients six months (T1) after implant loading. However, it may have no effect on MBL in the subsequent (T6 and T12) follow-up periods.

CONFLICT OF INTEREST

The authors declare no conflict of interest.

RECOMMENDATIONS:

Regarding the reduced external validity (small sample size, restricted age of the patients and relatively short follow-up period), further clinical studies are needed with larger sample size and longer follow-up periods. It can also be recommended to apply low level LASER biomodulation after 6 and 12 months as a reactivation session specially at marginal bone area around implants as low-level LASER has antibacterial effect that may decrease the further bone loss at this critical area .

ABBREVIATIONS

DM: Diabetes mellitus
CG: control group
LG:LASER group
CBCT: cone beam computerized tomography
HbA1c: glycated hemoglobin A1c
LLL: low-level laser biomodulation
Implant abutment interface(IAI)
MBL: Marginal bone loss
T0: time of loading
T6: 6 months after loading
T12: 12 months after loading

REFERENCES

1- Javed F, Romanos GE. Impact of diabetes mellitus and glycemic control on the osseointegration of dental implants: a systematic literature review. *Journal of periodontology*. 2009;80(11):1719-30.

2- Al-Shamiri HM, Elfaki S, Al-Maweri SA, Alaizari NA,

Tarakji B. Development of Nasopalatine Duct Cyst in Relation to Dental Implant Placement. *North American journal of medical sciences*. 2016;8(1):13-6.

3- Hunaish A, Al-Maweri SA. Dental Implants in Diabetic Patients-A Case Report. *IOSR Journal of Dental and Medical Sciences*. 2016;15:119-22.

4- Sun DC, Li DH, Ji HC, Rao GZ, Liang LH, Ma AJ, Xie C, Zou GK, Song YL. In vitro culture and characterization of alveolar bone osteoblasts isolated from type 2 diabetics. *Braz J Med Biol Res*. 2012 Jun;45:502-9

5- Blakytyn R, Spraul M, Jude EB . Review: the diabetic bone: a cellular and molecular perspective. *Int J Low Extrem Wounds* .2011.10 (1):16–32

6- Bashardoust Tajali S, Macdermid JC, Houghton P, Grewal R. Effects of low power laser irradiation on bone healing in animals: a meta-analysis. *J Orthop Surg Res*. 2010;5:1.

7-Garavento-Freitas I, Baranauskas V, Joazeiro PP, Padovani CR, Dal Pai-Silva M, Da Cruz-Höfling MA. Low-power laser irradiation improves histomorphometrical parameters and bone matrix organization during tibia wound healing in rats. *J Photochem Photobiol* 2003. 70(2):81–89.

8- Awad SM, Mounir RM, Salah El Dine M, Nasry SA . Effect of Laser Irradiation on Bony Implant Sites in Diabetic Patients: A Preliminary Study. *R J Pharm Biolog and Chem Scien* . 2017, 8(2): 1484-1495.

9- El-Kholy KA, El-Shenaway H. Role of diode laser in preservation of the marginal bone around early loaded endosseous implant. *Life Scien J*. 2012, 9(3):940-943.

10- Rizk FN, El-din MS. Radiodensitometric evaluation of the effect of low energy laser irradiation with and without antioxidants therapy on immediately loaded implant supported overdenture. *Egypt Dent J*. 2011, 57(4):2977-2987.

11- Ismaeel SA, Abbas AH. The effect of low-level laser on osseointegration of dental implants. *J Bagh College Dent*, 2011,23(3):112-116.

12- El-Desouky G, Mekky M, El-Din MS, Zikry K, Amer W. Radiodensitometric assessment of the effect of diode laser on bone density following loading of lased endosseous implants. *Egypt Dent J*. 2007, 53(2.2):12-23.

13- van As GA. Lasers in Implant Dentistry, Part I. *Dent Today*. 2015;34(7):134-139.

14- Mohammadi F, Hasheminasab M, Jahandide PP, et al. Effectiveness of low-level laser in minimizing edema and promoting wound healing after third molar surgery: a randomized clinical trial. *J of Cranio maxillofacial Research*,2014,1:58-62.

- 15- Da Silva RV, Camilli JA. Repair of bone defects treated with autogenous bone graft and low-power laser. *J Craniofac Surg.* 2006;17:297–301.
- 16- Campanha BP, Gallina C, Geremia T, et al. Low-level laser therapy for implants without initial stability. *Photomed Laser Surg.* 2010;28:365–369.
- 17- Goyal M, Makkar S, Pasricha S. Low level laser therapy in dentistry. *Int J Laser Dent.* 2013;3:82–88.
- 18- Arakeeb MA, Zaky AA, El-Mofty M. Effect of Application of Growth Factors and Diode Laser Bio-Stimulation on Osseointegration of Dental Implants. *Maced J Med Sci.* 2019; 7(15):2520-27.
- 19- Pinheiro AL, Martinez Gerbi ME, Carneiro Ponzi EA, et al. Infrared laser light further improves bone healing when associated with bone morphogenetic proteins and guided bone regeneration: an in vivo study in a rodent model. *Photomed Laser Surg.* 2008;26:167–174.
- 20- Deppe H, Horch HH. Laser applications in oral surgery and implant dentistry. *Lasers Med Sci.* 2007;22:217–221.
- 21- awil G, Younan R, Azar P, Sleilati G. Conventional and advanced implant treatment in the type II diabetic patient: surgical protocol and longterm clinical results. *Int J Oral Maxillofac Implants.* 2008;23:744–752
- 22- Marchand F, Raskin A, Dionnes-Hornes A, Barry T, Dubois N, Valéro R, Vialettes B. Dental implants and diabetes: conditions for success. *Diabetes Metab.* 2012 ; 38:14-9.
- 23- Garcia-Morales JM, Tortamano-Neto P, Todescan FF, de Andrade JC, Jr., Marotti J, Zezell DM. Stability of dental implants after irradiation with an 830-nm low-level laser: a double-blind randomized clinical study. *Lasers Med Sci.* 2012; 27:703–711.
- 24- ELSyad MA, Abdraboh AE, Aboelnagga MM, Ghali RM, Lebshtien IT. Effect of Low-Level Laser Irradiation on Stability and Marginal Bone of Narrow Implants Retaining Overdentures in Moderately Controlled Diabetic Patients. *J Oral Implantol.* 2019;45(5):391-397.
- 25- Adell R, Eriksson B, Lekholm U, Branemark PI, Jemt T. Long-term follow-up study of osseointegrated implants in the treatment of totally edentulous jaws. *Int J Oral Maxillofac Implants.* 1990;5:347–359.
- 26- Albrektsson T, Zarb G, Worthington P, Eriksson AR. The long-term efficacy of currently used dental implants: a review and proposed criteria of success. *Int J Oral Maxillofac Implants.* 1986;1:11–25.
- 27- Maeda Y, Miura J, Taki I, Sogo M. Biomechanical analysis on platform switching: is there any biomechanical rationale? *Clin Oral Implants Res.* 2007;18:581–584.
- 28- Thomé E, Lee HJ, Sartori IA, Trevisan RL, Luiz J, Tiozzi R. A randomized controlled trial comparing interim acrylic prostheses with and without cast metal base for immediate loading of dental implants in the edentulous mandible. *Clin Oral Implants Res.* 2015;26(12):1414-1420.
- 29- Spiekermann H, Jansen VK, Richter EJ. A 10-year follow-up study of IMZ and TPS implants in the edentulous mandible using bar-retained overdentures. *Int J Oral Maxillofac Implants.* 1995;10(2):231-243.
- 30- Szmukler, S, Piattelli A, Favero GA, Dubrullie, JH. Considerations preliminary to the application of early and immediate loading protocols in dental implantology. *Clin. Oral Impl. Res.* 2000, 11 : 12 - 25.
- 31- Schmitt CM, Nogueira-Filho G, Tenenbaum HC, Lai JY, Brito C, Döring H and Nonhoff J. Performance of conical abutment (Morse Taper) connection implants: a systematic review. *J Biomed Mater Res A* 2014;102(2):552–74
- 32- Passos SP, May LG, Faria R, Ozcan M, Bottino MA. Implant–abutment gap versus microbial colonization: Clinical significance based on a literature review. *Journal of Biomedical Materials Research B: Appl Biomater.* 2013; 10(7): 1321-1328.
- 33- Tettamanti L, Andrisani C, Bassi MA, Vinci R, Silvestre-Rangil J, Tagliabue A. Immediate loading implants: review of the critical aspects. *Oral Implantol (Rome).* 2017;10(2):129-139.
- 34- Gokhale SR, Padhye AM, Byakod G, et al. A comparative evaluation of the efficacy of diode laser as an adjunct to mechanical debridement versus conventional mechanical debridement in periodontal flap surgery: a clinical and microbiological study. *Photomed Laser Surg.* 2012, 30:598-603.
- 35- Aboelnagga MM, Alam eldeen HE, El-sayed AK. Effect of ER,CR:YSGG laser bio-modulation of osteotomy site on peri-implant crestal bone level in lower single fixed detachable prosthesis. *EDJ.* 2022; 68(1): 665-675.
- 36- Kusek ER. Immediate implant placement into infected sites: bacterial studies of the Hydroacoustic effects of the YSGG laser. *J Oral Implantol.* 2011;37:205–211.
- 37- Guzzardella GA, Torricelli P, Nicoli-Aldini N, Giardino R. Osseointegration of endosseous ceramic implants after postoperative low-power laser stimulation: an in vivo comparative study. *Clin Oral Implants Res.* 2003;14: 226–232.
-