

Evaluation of using Piezoelectric device versus Conventional Saw for Osteotomy in Maxillary Orthognathic Surgery

Abdullah hammer , Hamed gad

**Original
Article**

Oral and Maxillofacial surgery , faculty of Dentistry Minia University , Egypt

ABSTRACT

Objectives: to evaluate the effect of piezoelectric surgery in comparison with the conventional surgical saw regarding clinical and histological parameters.

Patients and Methods: 11 patients were included in a prospective comparative study to evaluate the effect of piezoelectric device in maxillary orthognathic surgery in comparison with the conventional regarding clinical and histological parameters. Assessment in this study included intraoperative bleeding, osteotomy time, postoperative facial edema, pain, and osteotomy site coagulative bone necrosis.

Results: Coagulative bone necrosis comparison showed a statistically significant higher mean in the saw group compared to the peizotome group with p-value ($p < 0.001$). There was a statistically significant increase of blood loss in saw group compared to peizotome group p-value ($p = 0.006$). regarding osteotomy time there were a statistically significant increase in peizotome group compared to saw group p-value ($p < 0.001$). There were no significant difference in facial swelling between both groups. A significant differences in postoperative pain between both groups at 1st , 2nd 3rd and 4th week postoperatively (P.value = 0.006), (P.value = 0.001), (P.value = 0.005) and (P.value= 0.002) in contrary to the 1st day postoperative follow up.

Conclusion: Piezoelectric osteotomy device is effectively able to carry out osteotomy, more safe than surgical saw resulting in less blood loss in maxillary orthognathic surgery, less post-operative pain sensation, and obviously decrease marginal bone necrosis than saw. In spite, the saw is superior to piezo in osteotomy time, piezoelectric surgery provide the faster bone repair.

Key Words: orthognathic, peizosurgery, lefort 1, maxilla, operative time

Received: 13 March 2022, **Accepted:** 23 January 2022.

Corresponding Author: Abdullah A , Hammuda , Associate Professor , oral and maxillofacial surgery, faculty of Dentistry Minia University , Egypt , **Tel :** 0862338474, **Mobile:** +201062318895 , **E-mail:** dr.abdullahatef@gmail.com
ISSN: 2090-097X, January 2022, Vol. 13, No. 1

INTRODUCTION

Piezo-surgery was first used in oral and maxillofacial surgery in 2001 by Vercellotti and colleagues to simplify maxillary sinus surgery by avoiding perforation of the schneiderian membrane. Later on ultrasonic bone cutting has been used in orthognathic procedures, extraction of impacted third molars, cyst enucleation, implant site preparation, temporomandibular joint surgery, corticotomy-facilitated orthodontics, and head and neck oncological and reconstructive surgeries.^[1-6]

Diabetes mellitus (DM) is a metabolic disease wPiezoelectric surgery devices use low-frequency ultrasonic vibrations. It minimizes the risk of soft tissues damage. Micrometric vibrations provide precise cutting action and operative control, with a consequent increase in safety in a difficult access anatomic area .^[7]

Developing technologies that can prevent bone loss and it is thought that ultrasonic devices offer the advantages to cut mineralised tissues selectively, and leave soft tissues such as nerves or blood vessels unharmed. Their cavitation effect reduces bleeding and provides better intraoperative

visibility. The low vibration amplitude are thought to cut more precisely with less trauma to the surrounding tissues^[8]

cell proliferation and accelerate bone metabolism in a It was reported in a meta-analysis study of randomized controlled trials (RCTs), patients subjected to piezosurgery for impacted third molars were presented with longer operative times, less postoperative swelling, pain, and trismus than patients who operated with conventional rotary techniques.^[9]

Diode LASER is antibacterial in nature and can be uBecause of these benefits, piezoelectric devices were introduced in orthognathic surgery osteotomies to reduce operative complications and postoperative discomfort. Several studies have compared both techniques, and most of them concluded that piezoelectric surgery is superior to the conventional technique for their reduced bleeding and greater safety.^[10-12]

On investigating the effects of applying of low-level However, few of the studies reported variables such as: swelling, postoperative pain, or sensitivity of the upper and lower lip. And up to our knowledge there is no histological

studies evidence for their effect on bone cutting edges. Consequently, the real impact of piezoelectric surgery is still not clear. For this reason the aim of the current study was to evaluate the effect of piezoelectric surgery in comparison with the conventional surgical saw regarding clinical and histological parameters.

METHODS

Trial Registration:

This clinical trial was performed after approval by the Ethical committee of the faculty of Dentistry, Minia University, Egypt. The trial was registered on clinicaltrials.gov with ID: NCT05202444.

Participants and Study Design:

11 patients indicated for maxillary orthognathic surgery were included in the current study. They were recruited from the Outpatient Clinic of Oral and Maxillofacial Surgery and Orthodontic Departments, Minia University Dental Hospital (MUDH). A comparative split mouth technique and single blind study were utilized to compare between piezoelectric device and surgical saw for bone osteotomy in maxillary orthognathic surgery.

Participants:

Patients included in the current study were selected according to the following inclusion criteria: 1. Age ranged from 18 to 35 years, 2. Patients were not suffering from systemic diseases that compromise wound or bone healing, 3. Patients indicated for leforte I or maxillary subapical osteotomy and 4. Patients agree the informed consent. Exclusion criteria were : 1. Patients suffering from systemic disease that may affect bleeding or bone healing, 2. Syndromic dentofacial deformity patients, and 3. Patients were subjected to previous maxillary orthognathic surgery.

All patients signed an informed consent which was approved by the research ethical committee (REC) of Faculty of Dentistry – Minia University clarifying the surgical procedure, complication, research records and photography. Patient's management was performed according to the principles of the Helsinki Declaration of 1980 for biomedical research involving human subjects, as revised in 2013.

I. Patient evaluation included:-

Medical history of all patients declared that they were not suffering from any chronic diseases and all were fit for surgical procedures of orthognathic surgery.

Dental evaluation of previous dental restoration, occlusion, and oral hygiene measures were carefully reviewed for all patients to establish good oral hygiene measures and occlusal splint fitting.

Periodontal assessment was considered especially during orthodontic stage and post-operative period to prevent

periodontal complications which might harm the final result.

Occlusal and function evaluation assessed for airway, speech, mouth breathing and parafunctional habits.

II. Radiographic analysis:

Cephalometric analysis was performed for each patient with SNA, SNB & ANB detection to gain anteroposterior relationship for both maxilla and mandible.

III. Treatment planning and pre-surgical

preparation: patients images were taken, dento-gingival complex were scanned and cone beam computerized tomography (CBCT) were imported to dolphin software. Planning and maxillary movement were performed on the software to export the surgical wafer.

Sample size:

Sample size calculation was based on procedure time and blood loss when comparing between piezoelectric device and conventional saw for osteotomy in maxillary orthognathic surgery. Regarding procedure time; as reported in previous publication (Romano *et al.*, 2018), the mean \pm SD of procedure time in Piezoelectric device group was approximately 264.4 \pm 23.1 minutes, while in conventional saw group it was approximately 228.7 \pm 29.0 minutes. Accordingly,

we calculated that the minimum proper sample size was 11 procedures in each group to be able to reject the null hypothesis with 80% power at $\alpha = 0.05$ level using Student's t test for independent samples. Sample size calculation was done using PS Power and Sample Size Calculations software, version 3.0.11 for MS Windows (William D. Dupont and Walton D., Vanderbilt University, Nashville, Tennessee, USA). As for blood loss; as reported in previous meta-analysis (Pagotto *et al.*, 2017), the mean \pm SD of blood loss in Piezoelectric device groups was approximately 389.4 \pm 118 ml, while in conventional saw group it was approximately 542.4 \pm 220.1 ml. Accordingly, we calculated that the minimum proper sample size was 33 procedures in each group to be able to reject the null hypothesis with 80% power at $\alpha = 0.05$ level using Student's t test for independent samples. Sample size calculation was done using PS Power and Sample Size Calculations software, version 3.0.11 for MS Windows (William D. Dupont and Walton D., Vanderbilt University, Nashville, Tennessee, USA).

Randomization and Blinding:

All 11 participants were subjected to both procedures: the piezotome group and surgical saw group. Assigning which procedure would be performed on which side, left or right, was based on a randomization process using concealed opaque envelopes where every patient was asked to pick one and the instructions written inside were followed.

This randomization technique resulted in having 5 participants where osteotomy using a peizotome was performed on the right side and the surgical saw on the left side, and 6 participants had the osteotomy using a piezotome performed on the left side and the surgical saw on the right side.

The measurement of intraoperative bleeding, osteotomy time, postoperative pain, and edema were performed by an external assistants and not by the principle investigators.

Surgical procedure:

All cases were operated under general anesthesia using nasotracheal intubation. The procedures performed included a Le Fort I osteotomy for the maxilla or 2 segments Le Fort I. Osteotomies were performed by first authors in all cases. Intravenous prophylactic antibiotic, Ceftriaxone (1 gm IV ceftriaxone sodium, Sandoz, introduced by Novartis, Egypt) and Dexamethazone (Dexamethazone 8mg/2ml ,U.S.P. XXII, Amriya for pharm Ind. Alexandria, Egypt). Scrubbing: The surgical fields were scrubbed starting intraorally followed by extraoral scrubbing using betadine surgical scrub (betadine mundipharma Egypt). Afterward the patients were draped using the standard technique of maxillofacial surgery.

After infiltration of the soft tissue with local anesthesia with a vasoconstrictor (articaine with epinephrine in a concentration of 1:100,000, Artinibsa 40 mg/0.01 mg/ml spain), a vestibular incision was extended to the second premolar area bilaterally. V-shaped incision at the labial frenum was performed to help with alignment in later suturing. Dissection of the buccal periosteum from anterior to posterior around the tuberosity, and placement of the pterygoid retractor subperiosteally. Neat dissection was performed avoiding perforation of the periosteum, especially posteriorly, to prevent herniation of the buccal fat pad through the periosteum. Identification of the piriform rim, and elevation of the nasal periosteum from the rim, nasal floor, and lateral nasal wall.

Osteotomy : bone cutting was performed in one side using a reciprocating saw from (Novage Germany) with 20 mm length blade from the same company connected on surgical motor using 15,000 rpm speed. (Figure 1)

In the other side osteotomy were utilized using piezoelectric from device (Woodpeker US1, China) with its internal irrigation system. We used US2 tip using the maximum bone cutting program and maximum irrigation program for lateral maxillary wall osteotomy and USIR tip for the posterior maxillary wall osteotomy. (Figure 2) The pterygoid osteotome was placed between the tuberosity and pterygoid plates while the hamulus is palpated palatally with the index finger to guide the osteotome direction preventing palatal perforation. With the pterygoid osteotome still in position, we used a thin osteotome to complete the osteotomy of the posterior wall of the maxilla.

A lateral nasal osteotome was placed on the piriform rim and directed slightly laterally. The nasal mucosa was protected to prevent tearing during the osteotomy. Separation of the septal cartilage and vomer from the maxillary bone using a nasal septal osteotome. The osteotome was angled toward the nasal floor to prevent tearing of the nasal mucosa. Maxillary downfracture using Rawe disimpactors to manipulate the maxilla gently. Refining the osteotomy at the posterior maxilla to prevent any bone interference during maxillary reposition at the new position.

Using the maxillary wafer to guide the maxilla to the new position the elastic bands were used for maxillo-mandibular fixation. Using two L-shaped mini plates for each side with four holes for each plate (O&M medical GmbH, Germany) with 4 mini screws. the wound was irrigated copiously with normal saline then sutured continuously with vicryl (Egysorb 4/0 , Egypt). Post-operative medications included : Ceftriaxone 1 gm once per day, Metronidazole 500mg tablets (flagyl, Sanofi aventis, Egypt) 3 times per day, Diclofenac Sodium (Voltaren 75 mg/3ml, Novartis) twice per day, dexamesathone 8mg once per day, xylometazoline 0.1 % nasal drops (Otrivin , GSK Egypt) drops twice per day. Feeding and nutrition patient started to take clear fluid 2 hours after recovery then starting liquid diet for one week after surgery.

Assessment:-

A- Intra operative evaluation:

- Intraoperative bleeding was calculated from the start of each device (saw and piezo) application at the osteotomy which was assessed by measuring the amount of fluid in suction jar with subtraction of the known irrigant solution plus the calculation of the amount of blood saturation by surgical gauze. This was performed for each osteotomy separately.

- Osteotomy time using stopwatch from the beginning of osteotomy at each side using only either saw or piezo without mentioning manual osteotomes.

B- Postoperative evaluation

- Facial edema was measured bilaterally in preoperative , one day postoperatively,1 week, two weeks, three weeks and four weeks in each patient as a summation of the following three lines (1) the line from the tragus of the ear and the ipsilateral labial commissure; (2) the line passing through 1 cm below the eyelid with the open eye from the medial canthus to the tragus ipsilateral; (3) the line passing from the tragus to the nasolabial angle.

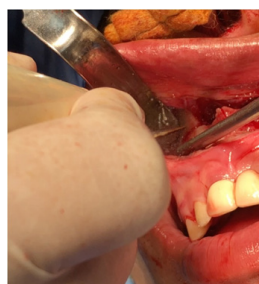- Pain for each side was assessed with VAS scale 1st day postoperative, 1 week, 2 weeks, 3 weeks and 4 weeks postoperative by scoring the pain from 0(no pain) to 10(the worst pain).

C- Osteotomy site Coagulative bone necrosis

was estimated using histo-morpho-metric analysis from bone collected during intraoperative osteotomy.

Statistical Analysis:

Recorded data were statistically analyzed using the package for social sciences, SPSS 20.0 (SPSS Inc., Chicago, Illinois, USA). Quantitative data were expressed as mean± standard deviation (SD). Qualitative variables were expressed as count (n) and percent (%). The confidence interval was set to 95% and the margin of error accepted was set to 5%.



Figure(1) osteotomy cut using peizotome .

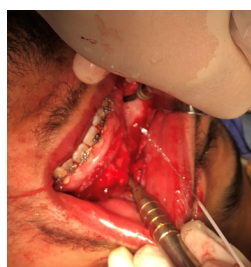

Figure (2) osteotomy cut using surgical saw .

RESULTS

For the assessment of blood loss and bleeding time, z-Mann-Whitney test was used. In regard to blood loss, measured in ml., there was a statistically significant higher mean of blood loss in Saw Group compared to peizotome Group with p-value ($p=0.006$). The Piezotome group revealed a mean and standard deviation of blood loss of 152.91 ± 18.52 ml with the range being 120–180, while the Saw group

227.36 ± 72.64 ml with a 110–390 range. Regarding bleeding time, measured in minutes, the peizotome group also had a statistically significant higher mean than the saw group with p-value ($p<0.001$). The peizotome group showed a mean and standard deviation bleeding time of 12.92 ± 1.16 with a 11.5–15.5 range, while the saw group presented 6.07 ± 1.07 ml and a range of 4.5–7.5.

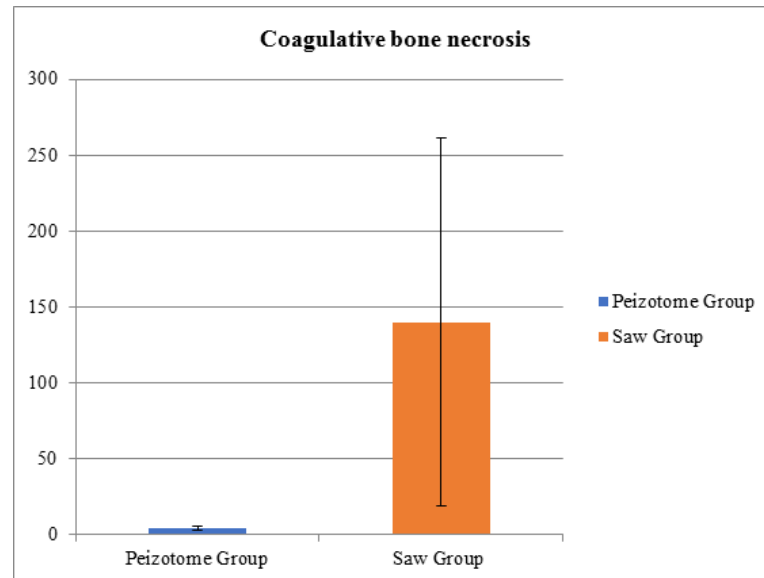
Facial swelling was also assessed using z-Mann-Whitney test to compare between the two groups and no statistically significant difference between them was found with p-value ($p>0.05$ NS)

Pain score between the two groups showed a statistically significant higher mean of pain score in saw group compared to peizotome group with p-value ($p<0.05$) after using the z-Mann-Whitney test. Measurements were taken over the course of four weeks postoperatively; the results are displayed in Table (1).

Pain score	Peizotome Group (n=11)	Saw Group (n=11)	z-test	p-value
1st day postoperative	9 (8–9)	9 (8–9)	0.000	1.000
Median (IQR)	8–10	8–10		
Range				
1st week postoperative	6 (6–7)	7 (7–8)	-2.762	0.006*
Median (IQR)	5–7	6–8		
Range				
2nd weeks postoperative	4 (3–4)	5 (5–6)	-3.185	<0.001**
Median (IQR)	3–5	4–6		
Range				
3rd weeks postoperative	2 (1–2)	3 (2–3)	-2.839	0.005*
Median (IQR)	1–3	2–5		
Range				
4th weeks postoperative	1 (0–1)	2 (1–2)	-3.151	0.002*
Median (IQR)	0–2	1–3		
Range				

Coagulative bone necrosis comparison showed a statistically significant higher mean in the saw group compared to the peizotome group with p-value ($p < 0.001$). (Figure 3) displays the comparison between both groups; the peizotome group had a mean and standard deviation of 4.41 ± 1.11 and range of 1.95-6.54, while the saw group had a mean and standard deviation of 140.56 ± 198.39 and range of 48.98–730.92. The z-Mann-Whitney test was used and displayed a result of -3.974.

Figure 3: Comparison between Peizotome Group and Saw Group according to coagulative bone necrosis.



Using Wilcoxon Signed-Rank Sum test, a statistically significant lower mean of facial swelling at measurements “after 1st day, 1stw, 2ndw, 3rdw and 4th weeks” in each group was observed. The findings of the test are displayed in Table (2).

Table (2): Comparison between facial swelling at 1st day postoperative and other measurements in each group.

Measurements	Peizotome Group (n=11)				Saw Group (n=11)			
	Facial Swelling		Wilcoxon test		Facial Swelling		Wilcoxon test	
	Mean±SD	Mean±SD	z-test	p-value	Mean±SD	Mean±SD	z-test	p-value
1st day postoperative	30.82±4.14				32.18±3.22			
1st week postoperative	28.45±2.54	-2.37	-1.986	0.043*	30.18±2.36	-0.64	-2.409	0.016*
2nd weeks postoperative	25.45±2.25	-5.37	-2.613	0.009*	26.00±2.32	-4.82	-2.955	0.003*
3rd weeks postoperative	23.28±1.40	-7.54	-2.937	0.003*	23.74±1.56	-7.08	-2.938	0.003*
4th weeks postoperative	22.95±1.13	-7.87	-2.937	0.003*	23.45±1.35	-7.37	-2.950	0.003*

Using: Wilcoxon Signed-Rank Sum test
 p-value >0.05 NS; *p-value <0.05 S

Pain score was also assessed using the Wilcoxon Signed-Rank Sum test and a statistically significant lower mean of pain score at measurements “after 1st day, 1stw, 2ndw, 3rdw and 4th weeks” in each group was observed. The findings of this test are displayed in Table (3).

Table (3): Comparison between pain score at 1st day postoperative and other measurements in each group.

Measurements	Peizotome Group (n=11)				Saw Group (n=11)			
	Pain score	Wilcoxon test			Pain score	Wilcoxon test		
		Median (IQR)	Median Diff.	z-test		p-value	Median (IQR)	Median Diff.
1st day postoperative	9 (8–9)				9 (8–9)			
1st week postoperative	6 (6–7)	-3	-3.025	0.002*	7 (7–8)	-2	-3.127	0.002*
2nd weeks postoperative	4 (3–4)	-5	-3.025	0.002*	5 (5–6)	-4	-3.025	0.002*
3rd weeks postoperative	2 (1–2)	-7	-2.994	0.003*	3 (2–3)	-6	-3.020	0.003*
4th weeks postoperative	1 (0–1)	-8	-2.980	0.003*	2 (1–2)	-7	-2.969	0.003*

Using: Wilcoxon Signed-Rank Sum test
p-value >0.05 NS; *p-value <0.05 S

DISCUSSION

In the current prospective comparative study, 11 patients were included to evaluate the effect of piezoelectric device in maxillary orthognathic surgery in comparison with the conventional regarding clinical and histological parameters. medically compromised were exclude which might affect intraoperative assessment (blood loss) or postoperative healing process. In addition, syndromic and cleft patients were excluded because of additional maxillary distraction, augmentation or additional surgical steps which might encounter the aim of the study because of the additional uncontrolled variables.

Pagotto et al, published a systematic review and meta-analysis to compare piezo-surgery and conventional osteotomy in orthognathic surgery. it was reported patients subjected to piezoelectric surgery presented with less intraoperative blood loss and postoperative neurosensory disturbances versus patients who received the conventional technique for osteotomy, but no differences were reported in operative time for bimaxillary osteotomies.^[13] also Jankins et al reported no significant difference between piezo and conventional saw in time of the whole surgery.^[14]

Regarding assessment of blood loss the results of the previous study were in agreement with the results reported in the present study as there was a statistically significant increase of blood loss in saw group compared to peizotome group p-value ($p=0.006$). However, in assessment of osteotomy time there were a statistically significant increase in Peizotome group compared to saw group p-value ($p<0.001$).

In accordance Spinelli et al and Rana et al reported the operating time using piezoelectric device is significantly longer than conventional methods considering the surgical saw.^[11,12] the contrast in results of operating time could be referred to calculation methods as they used the osteotomy technique for each patient in both sides, however in our study we used a split mouth technique to exclude patients variables that might affect the operating time as nine patients with 18 osteotomy sides were divided into 2 groups 9 osteotomies with piezoelectric device and 9 osteotomies with conventional saw and the osteotomy time was calculated for each side separately. Such calculation method would reduce variable factors and provide mor precise records.

piezoelectric surgery which offers some valuable advantages that have been reported in previous studies. Nevertheless, there are also some disadvantages, mainly related to the duration of the osteotomy. The need to stop the cutting action every once in a while to permit the instrument to cool down prolongs the operating time, and some studies have reported a 30%–50%. longer operating time when compared with a conventional bur. This conclusion agrees with the results of the current study as there was significant difference ($p<0.001^{**}$) in operating time between both groups in favour of the saw technique that required less time for osteotomies. Evaluation of facial swelling was performed in the current study using a measurements on a specific points on the face clinically. Others used a method based on photographs taken of the patient before and after the operation, ultrasonographic scanning, MRI imaging or stereophotogrammetry scanning.^[12,15,16]

Records of facial swelling in the current study revealed that, there were no significant difference between both groups. In contrast with the conclusion of Spinelli et al¹² and Rossi et al¹⁶ as they revealed significant decrease in edema with piezo than saw. The contradiction in results may be referred to the measurement technique, operative or/and postoperative management. In addition, there was significant decrease in edema along records (table 5) in both piezo and saw groups which validate the absence of relation between osteotomy tool and edema which is a soft tissue related complication.

As well as the perception of postoperative pain was concerned, there were a significant differences between both groups at 1st, 2nd, 3rd and 4th week postoperatively (P.value = 0.006), (P.value = 0.001), (P.value = 0.005) and (P.value = 0.002) in contrary to the 1st day postoperative follow up as shown in (table 3). These results were in a agreement with Rana et al¹¹ and contrast to D. Rossi et al¹⁷.

The insignificant results in the first day may be attributed to the effect of postoperative analgesics. Accordingly, based on these results, it was suggested that piezoelectric surgery is better for patients regarding postoperative pain perception. Moreover a histomorphological study that carried out by Preti et al evaluated bone morphogenetic proteins (BMP-4), necrosis factor alpha (TNF-alpha), transformer growth factor (TGF-b2), interleucin-1b and interleucin-10 responses in dental implants osteotomy sites. They reported higher quantity of inflammatory cells present in perforations carried out with conventional implant drills rather than in bone sites which had been prepared with piezosurgery^[18]. Also, histomorphological analyses and proteins quantification revealed that Piezosurgery for bone perforation is more efficient in first phases of bone repair, induced to increased levels of BMPs, better controlled inflammation and early stimulated bone remodeling after 56 days postoperatively when compared with conventional bone drilling.^[19]

In accordance with the results of the current study as we evaluated coagulative bone necrosis in osteotomy cuts by histomorphometric analysis of bone, and it was reported that saw technique showed significant increase in coagulative bone necrosis when compared to piezo technique with high statistical significance (P.value < 0.0001) which directly affect bone quality for healing as healing occurs fast, because of limited damage effect on the living osteocytes and it induces an earlier bone morphogenetic protein release.

Comparing the the effect of piezoelectric device versus conventional rotary instrument or saw on bone healing was evaluated separately in diseveral studies only in vitro on cheeps head by Stübinger, Stefan in 2007 20 and on rabbit bone by Ma et al in 2013²¹ and they were in agree with our result. While Esteves et al.^[19] reported no significant difference histomorphometrically between piezo and saw in osteotomized rats tibia although they reported a

slightly higher amount of newly formed bone observed at 30 days after piezosurgery (p < 0.05).

Heiland et al in 2007 reported a seven weeks old patient with Pierre-Robin syndrome subjected to Piezosurgery bone distraction. The authors suggested Piezosurgery usage for the same syndrome cases even in patients with less than 2 months of life because of the success obtained with ultrasound bone surgery in spite of such a tender age and low ossification level.^[22]

In agreement with the current study a recent review presented several studies on bone healing evaluation following different osteotomic techniques in animal models concluded that; piezoelectric osteotomy leaves bone vital more than any other osteotomy tool.^[23]

CONCLUSION

Piezoelectric osteotomy device is effectively able to carry out osteotomy, more safe than surgical saw resulting in less blood loss in maxillary orthognathic surgery, less postoperative pain sensation, and obviously decrease marginal bone necrosis than saw. In spite, the saw is superior to piezo in osteotomy time, piezoelectric surgery provide the faster bone repair.

CONFLICT OF INTEREST

The authors declare no conflict of interest.

FUNDING:

This project is self-funded.

REFERENCES

1. Vercellotti T. Technological characteristics and clinical indications of piezoelectric bone surgery. *Minerva Stomatol* 2004;53:207-14.
2. Beziat J-L, Bera J-C, Lavandier B, Gleizal A: Ultrasonic osteotomy as a new technique in craniomaxillofacial surgery. *Int J Oral Maxillofac Surg* 36: 493-500, 2007
3. Brockmeyer P, Hahn W, Fenge S, Moser N, Schliephake H, Gruber RM: Reduced somatosensory impairment by piezo-surgery during orthognathic surgery of the mandible. *Oral Maxillofac Surg* 19: 301-307, 2015
4. Canullo L, Penarrocha D, Penarrocha M, Rocio A-G, Penarrocha-Diago M: Piezoelectric vs. conventional drilling in implant site preparation: pilot controlled randomized clinical trial with crossover design. *Clin Oral Implant Res* 25: 1336-1343, 2014

5. Farid KA, Mostafa YA, Kaddah MA, El-Sharaby FA: Corticotomy-facilitated orthodontics using piezo-surgery versus rotary instruments: an experimental study. *J Int Acad Periodontol*: 103-108, 2014
6. Hammuda A, Gad, H. Clinical outcome of using a piezo-electric device in comparison with conventional surgical drills in surgical management of the temporomandibular joint ankylosis. *Egyptian Dental Journal*, 2019; 65(Issue 2 - April (Oral Surgery)): 1061-1068.
7. Gonzalez-Lagunas, J. Is the piezoelectric device the new standard for facial osteotomies? *Journal of Stomatology, Oral and Maxillofacial Surgery*. 2017,118; 255–258.
8. Jundt JS, Marchena JM, Hanna I, Dhanda J, Breit MJ, Perry AP. Evolving Technologies for Tissue Cutting. *Oral Maxillofac Surg Clin North Am*. 2019 Nov;31(4):549-559.
9. Jiang Q, Qiu Y, Yang C, Yang J, Chen M, Zhang Z. Piezoelectric Versus Conventional Rotary Techniques for Impacted Third Molar Extraction: A Meta-analysis of Randomized Controlled Trials. *Medicine (Baltimore)*. 2015;94(41):e1685.
10. Bertossi D, Lucchese A, Albanese M, et al. Piezo-surgery versus conventional osteotomy in orthognathic surgery: a paradigm shift in treatment. *J Craniofac Surg* 2013;24:1763–6.
11. Rana M, Gellrich N, Rana M, et al. Evaluation of surgically assisted rapid maxillary expansion with piezosurgery versus oscillating saw and chisel osteotomy – a randomized prospective trial. *Trials* 2013;14:49.
12. Spinelli G, Lazzeri D, Conti M, et al. Comparison of piezosurgery and traditional saw in bimaxillary orthognathic surgery. *J Craniomaxillofac Surg* 2014;42:1211–20.
13. Pagotto LE, Santos T, Vasconcellos SJ, et al. Piezoelectric versus conventional techniques for orthognathic surgery: systematic review and meta-analysis. *J Craniomaxillofac Surg* 2017;45:1607–13.
14. Jenkins, G. and R. Langford, Comparison of the piezo-electric cutter with a conventional cutting technique in orthognathic surgery. *British Journal of Oral and Maxillofacial Surgery*, 2019. 57(10): p. 1058-1062.
15. Shetty V, Mohan A. A prospective, randomized, double-blind, placebocontrolled clinical trial comparing the efficacy of systemic enzyme therapy for edema control in orthognathic surgery using ultrasound scan to measure facial swelling. *J Oral Maxillofac Surg* 2013;71:1261–7.
16. Al-Samman AA, Othman HA (2017) Facial expression drawings and the full cup test: valid tools for the measurement of swelling after dental surgery. *Br J Oral Maxillofac Surg* 55(1):22–25
17. Rossi, D., et al., Bimaxillary orthognathic surgery with a conventional saw compared with the piezoelectric technique: a longitudinal clinical study. *British Journal of Oral and Maxillofacial Surgery*, 2018. 56(8): p. 698-704.
18. Preti, G., et al. “Cytokines and Growth Factors Involved in the Osseointegration of Oral Titanium Implants Positioned Using Piezo-electric Bone Surgery Versus a Drill Technique: A Pilot Study in Minipigs”. *Journal of Periodontology* 78.4 (2007): 716-722. 16.
19. Esteves, J.C., et al., Dynamics of bone healing after osteotomy with piezosurgery or conventional drilling—histomorphometrical, immunohistochemical, and molecular analysis. *Journal of translational medicine*, 2013. 11(1): p. 1-13.
20. Stübinger, S., Bone healing after piezosurgery and its influence on clinical applications. *Journal of Oral and Maxillofacial Surgery*, 2007. 65(9): p. 39. e7-39. e8.
21. Ma, L., et al., Healing of osteotomy sites applying either piezosurgery or two conventional saw blades: a pilot study in rabbits. *International orthopaedics*, 2013. 37(8): p. 1597-1603.
22. Heiland, M., et al. “Intraoral osteotomies using piezosurgery for distraction in an infant with Pierre-Robin sequence”. *Clinical Oral Investigations* 11.3 (2007): 303-306.
23. Anesi, A., et al., Bone Healing Evaluation Following Different Osteotomic Techniques in Animal Models: A Suitable Method for Clinical Insights. *Applied Sciences*, 2020. 10(20): p. 7165.