

## The effect of BioHPP versus Zirconia CAD/CAM-fabricated fixed-detachable prosthesis rehabilitating single maxillary arches on the peri-implant bone level changes

Mona M. Aboelnagga, Omar El Sadat

Prosthodontic Department, Faculty of Dentistry, Ain Shams university, Cairo, Egypt.

### ABSTRACT

**Purpose:** The objective of this study was to compare the use of BioHPP and zirconia CAD/CAM fabricated materials in implant supported maxillary fixed-detachable prosthesis opposing dentate mandibular arch, where peri-implants bone level changes were evaluated for two years.

**Materials and method:** Ten patients with edentulous single maxilla opposing dentate mandibular arch were selected to share in this study. For all patients, proper planning for implant placement was made where the participants were randomly allocated into two groups five patients in each group. Six implants were inserted guided by the sterolithographic surgical guide following flapless surgical approach. Immediate loading protocol was followed, where the milled acrylic temporary prosthesis, which was planned for each patient according to the computer software, was screwed to the implants. After 4 months, the final restoration was placed according to the following grouping. In group I, patients were rehabilitated with fixed-detachable zirconium restoration while in group II patients were rehabilitated with fixed-detachable BioHpp Peek restoration. Peri-implant marginal bone changes were evaluated at loading time, after 6 month, 1 and 2 years follow up visits. Data collected were tabulated and statistically analyzed.

**Results:** In intragroup comparisons, peri implant bone loss was significant. Where in group I, the mean value of peri-implant bone height change measures from implants insertion to 6 month was 0.35 mm, from insertion to 12 months was 0.62 mm while from insertion to 24 months follow up was found to be 0.96 mm. While in group II at same time intervals were 0.39 mm, 0.69 mm and 1.23 mm respectively. On the other hand in intergroup comparison, to compare the mean amount of peri-implant bone height changes in the two studied groups during the follow up intervals, student t test was performed and showed that group II had a non significant higher bone loss.

**Conclusion:** Based on these results and within the limitation of this study. Both Zirconia and BioHpp when used as framework material for fixed-detachable maxillary single prosthesis had successful results on the supporting implants. However, BioHpp fixed-detachable prosthesis had higher effect on the peri-implant marginal bone loss but it was not of statistical significance.

**Key Words:** Dental implant, CAD/CAM, BioHpp, PEEK, Zirconia, fixed- detachable, single Maxillary arch

**Received:** 19 April 2022, **Accepted:** 15 January 2022.

**Corresponding Author:** Mona M. Aboelnagga , Associate Professor , Prosthodontic Department, Faculty of Dentistry, Ain Shams university, Cairo, Egypt , **Tel :** 26710385, **Mobile:** 01114401177 , **E-mail:** maboelnagga@gmail.com

**ISSN:** 2090-097X, January 2022, Vol. 13, No. 1

### INTRODUCTION

Single complete denture (SCD) construction opposed by natural dentition is a very challenging clinical situation for a practitioner due to several problems like repeated denture fracture, dislodgement, difficulty to achieve occlusal balance, and accomplishing satisfactory esthetics because of the fixed positions of the remaining natural dentition. Single complete denture may be opposed by natural teeth, fixed or a removable restoration <sup>[1]</sup>.

Establishing a regular occlusal plane in the opposing arch is a necessity for establishing a balanced occlusion in SCD. An irregular occlusal plane is a common clinical condition in the natural dentition due to one or more factors such as mal-aligned, supra-erupted, drifted or tilted teeth or abrasion and attrition of teeth that should be adjusted to accomplish a balanced occlusion in patients who demand SCD <sup>[2]</sup>. In addition, reaching a regular occlusal plane is the main objective of any restorative procedure to assist normal mandibular movements and facility of

mastication<sup>[3]</sup> When sufficient number of implants is inserted in an arch, a conventional fixed bridge is the prosthetic treatment option of choice. Frequently this is not a preference in the maxillary arch because of the combined vertical and horizontal bone resorption and tilted positions of the implants. In this case, a conventional fixed bridge would not fulfill the patient's requests for esthetics, phonetics, hygiene maintenance and comfort. Furthermore, pink porcelain has less natural-looking and it mostly demands more baking cycles that increase the possibility of porcelain fracture<sup>[4]</sup> .

These complications can be resolved by constructing hybrid prosthesis which can simply substitute the lost soft tissue; an esthetic advantage and because of their shock absorbing properties, it can decrease the mechanical and biological complications like screw loosening, fracture of component and bone resorption. Where it acts as shock absorbent and distributes force thus decreasing the sudden load transmitted to the dental

implants. While, the prosthetic parts substituting the soft tissues develop good oral hygiene; a self-cleansing enhancement by the food being swiped away [5,6].

The esthetic demands are more essential with maxillary prostheses, which require changes in the extension and thickness of labial/buccal flanges. Furthermore the resorption patterns in maxilla directed superiorly, posteriorly, and medially increase the demand for the prosthetic gingival tissues to compensate it [7].

Implant assisted overdentures and hybrid prosthesis can offer support for the soft tissues of the face when compared to the conventional fixed prosthesis, and with the development of computer-aided designs and the improvements in prosthetic materials, soft tissues loss can be certainly substituted where pink interdental papilla can be simulated [8].

Dental implants supporting fixed prostheses are subjected to dynamic and static loading. Mastication exerts dynamic forces on the implants that may reach high magnitudes while static loading can be produced by the tension in locking the screws of the bridge or when placing an ill-fitting framework on the implants [9, 10]. It is essential for implant's success to have controlled loading, where Brånemark [11] stated that the prosthesis precision fit should be at 10 µm level.

The prosthodontist should consider certain factors to reduce stress upon the components of the hybrid prosthesis among which proper positioning of the implants, removal of cantilevers, adequate occlusal adjustments, fabrication of a rigid framework, and the use of stress absorbing materials [8,12].

Some mechanical and biological complications may occur as a result of the exposure to high stresses that lead to loosening of the screw and component fracture, bone resorption, and detachment of the veneering material from the underlying framework [4, 8].

The quick development of computer-aided design and computer-aided manufacturing (CAD-CAM) technology led to the appearance of new different materials which could be accurately milled for the construction of planned dental prosthesis [13]. CAD/CAM systems comprise three components: A digitalization tool/scanner which converts geometry into digital data that can be managed by the computer, software that makes data processing and, according to the application, creates a data set about the product to be fabricated and a production technology that converts the data set into the required product [14, 15].

Dental restorations manufactured using CAD/CAM technology have become widespread recently because of the fact that high-quality restorations can be made in less expected time, thus rising the efficacy by changing the manufacturing procedures to be automated. CAD/CAM allows the use of variety of materials for different types of dental prosthesis [15].

Considering esthetics, metal free restorations are achieving popularity in present dental treatments. Polyether-ether-ketone (PEEK) is among the metal free restorations that have several potential uses in dentistry. It is an organic thermoplastic polymer one of the poly-aryl-ether-ketone (PAEK), poly-ether-ketone-ketone (PEKK) family. It is a semi-crystalline thermoplastic with excellent chemical and mechanical properties that are preserved at higher temperatures. Length, chemical composition, structure (branching of polymer) of PEEK makes it stable at high temperatures making processing of peek implant components easy [16].

PEEK can overcome the previously mentioned problems and can be used as framework for removable and fixed dental prosthesis because of its excellent mechanical and esthetic properties. In addition PEEK can be used as implant material, as a substitute to titanium.

It has elastic modulus that is near to that of human bone resulting in homogeneous stresses distribution to the surrounding tissues and lead to decreasing the rate of bone resorption [17].

The facility to modify PEEK by using a different materials and techniques will increase the possibility of its application in implant dentistry and dentistry in general [18]. BioHPP material is a known high-performance polymer of PEEK that is reinforced with 20% ceramic fillers.

(BioHPP; Bredent GmbH) Their strength is related to this special ceramic filler (having the grain size 0.3- 0.5 µm), which optimized the mechanical properties. Besides, owing to this very small grain size, constant homogeneity can be fabricated [19].

Accepting adjustments, good stability, optimum polish capability and aesthetics of BioHPP make high-quality prosthesis. BioHPP with an excellent potential as framework material, it makes good alternative to Cr-Co frameworks for patients with high esthetic demands [20]. In addition, it can be faced by composite material or bonded to lithium disilicate crowns. It is multipurpose and has revealed advantageous laboratory and clinical features [20, 21].

When crowns are cemented, its radiolucency allows the detection of excess cements around the implant to be easier. It is a light-weight material that can be used when need restoration of large defects [21]. Improving bonding among veneering material and PEEK will allow its use for permanent restoration and may decrease the demand for future repairs. Further studies are looked-for to optimize bonding for long-term performance.

Using lithium disilicate restorations facing over PEEK materials will improve esthetics and afford an excellent surface for oral hygiene measures. Veneering PEEK frameworks with composite materials enhance combining pink esthetics to oral soft tissues compared to conventional complete denture materials. manufactured veneers can be easily attached to BioHPP

Pre-manufactured veneers can be easily attached to BioHPP and shade could be evaluated at the try-in visit<sup>[21]</sup>. Zirconia is one of all-ceramic restorations. It has been presented to dental practice as an alternative to metal-ceramic dental restorations. It is strong, biocompatible and natural looking. Zirconia crown was expensive in the past as it was entirely made by hands, but with the progress of technology, using machines and milling zirconia crowns and bridges is now widely employed<sup>[22]</sup>.

As an alternative treatment option full zirconia restoration is milled from one solid block of zirconia. Then zirconia is custom-stained to look like enamel and gingival tissue to enhance the esthetics<sup>[23]</sup>. Zirconia have better esthetics, compared to the conventional porcelain fused to metal restorations, where their excellent optical properties are recognized particularly with the absence of the black line, made by the metal in the cervical line of the conventional restorations. Among its advantages that it is extremely strong and durable, with least wear and the possibility of chipping or craze lines are minimum<sup>[24]</sup>.

But unfortunately, one of its disadvantages that in some instances a catastrophic fracture of the framework may occur and break in half. This will necessitate the removal of the entire prosthesis and remade. However, as it is a CAD-CAM restoration; the laboratory can use the saved original STL design file and re-mill new restoration thus saving time and steps<sup>[24]</sup>.

Furthermore, to gain benefit of the strength of zirconia and optimize esthetics for the patient, in the full arch prosthesis the posterior regions to be of framework to be full contour zirconia and the use of separate porcelain crowns anteriorly<sup>[24]</sup>.

Zirconia framework with porcelain overlay is used in full arch fixed restorative option. When compared to metal frameworks, the advantages of zirconia are its biocompatibility, superior esthetics and strength. The white-colored base lessens any grey metal showing beneath porcelain and improves its natural esthetic characteristics. Moreover, it is remarkably strong and durable as a base. The use of porcelain over zirconia framework provides translucency and esthetics<sup>[25]</sup>.

It is important to mention that its disadvantage is attributed to the properties of porcelain itself. Because of the way porcelain is processed onto the framework as one unit, if any chipping or fracture of the restoration occurs, the whole prosthesis must be removed, and sent to the laboratory where all porcelain must be remade, in order to reduce this risk the zirconia framework can be designed such that to support the use of separate porcelain crowns<sup>[23, 26]</sup>. The mechanical failure of maxillary dentures under functional masticatory forces, especially in the presence of opposing dentition, is a persistent difficulty and its avoidance is nevertheless a challenge for the practitioners. Here in

this study raised the hypothesis of whether to use a high strength esthetic material (Zirconia) or a resilient reinforced material (BioHpp) where both are manufactured using CAD/CAM technology to evaluate which of these materials will transmit less stresses on the supporting implants for the fixed-detachable prosthesis and has less peri implant marginal bone loss.

## **MATERIALS AND METHOD**

---

In this study, ten patients were selected from outpatient attending to prosthodontic clinic for their complaints regarding their single maxillary dentures their age ranged between 40-65 years old. The inclusion criteria of the participants are; patients who wore maxillary conventional dentures opposed by complete or partial set of natural teeth, complaining from looseness and instability of their single maxillary dentures. Patients had sufficient restorative space for the maxillary prosthesis (at least 12 mm) from the occlusal plane to the oral mucosa to accommodate a fixed implant prosthesis. This was evaluated by making tentative jaw relation where upper and lower well-extended impressions of the patients were made and poured to have study casts that were mounted on the articulator using a face bow transfer and accurate interocclusal records.

The amount of bone in the anterior maxilla between the maxillary sinuses was sufficient allowing insertion of implants (at least 10 mm in length and 3.7 mm in diameter). Patients were non-smokers and had good oral hygiene. The exclusion criteria included any medical conditions that could compromise implant placement as liver, heart, autoimmune diseases, irradiated arches, and uncontrolled systemic or neurologic diseases. All participants were informed about the treatment strategy and the needed steps for its completion and they signed an informed consent.

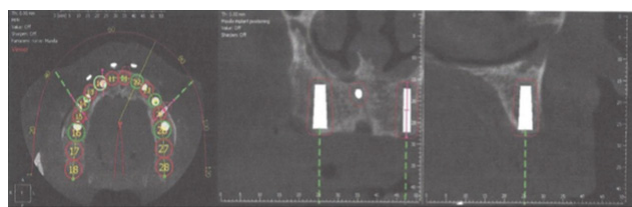
### ***Patients grouping:***

The participants were randomly assigned, using random numbers generated in Excel spread sheet, into two equal groups (five patients in each group). Each patient received six implants placed in the maxillary arch that were immediately loaded with pre-constructed fixed acrylic prosthesis. After 4 months, the temporary maxillary acrylic prosthesis in Group I patients was replaced with fixed-detachable zirconium restoration, and in Group II patients, the prosthesis was replaced with fixed-detachable BioHpp (Peek) restoration.

For all patients, clinical examination of the remaining mandibular teeth was done to ensure its periodontal health and non-carious or defective restorations. And on the mounted diagnostic casts, the occlusal plan of the present mandibular teeth was examined and planning for any corrections was made to be transferred intraorally (guided by the new maxillary denture). Afterwards, new maxillary single dentures were constructed following the conventional steps with bilateral balanced occlusion.

Virtual planning was done with dual scan protocol by adding several spherical radiographic composite markers (Z350 Composite 3M ESPE, Germany) to the patient's upper complete single denture in a staggered pattern at different levels to the occlusal plane on the buccal and labial flanges of the denture.

A dual scan protocol for each patient was made using cone beam computerized tomography while the patient was wearing the maxillary denture and biting in centric occlusion. A second separate scan was made for the maxillary denture alone. Computer software 2guide cyber med software (2guide cyber med software, Seoul, Korea) was used to overlap the two scans on each other where the final file contained reformatted images in 3D bone model, 3D radiological data set and 3D radiographic modified denture guide model to construct a three dimensional image for the edentulous maxilla. Then the bone height and width at the proposed six implant sites (at the canines region, premolars and molars bilaterally) for both groups was evaluated to have the implants at the optimizing position, distribution and angulation. (Figure 1)

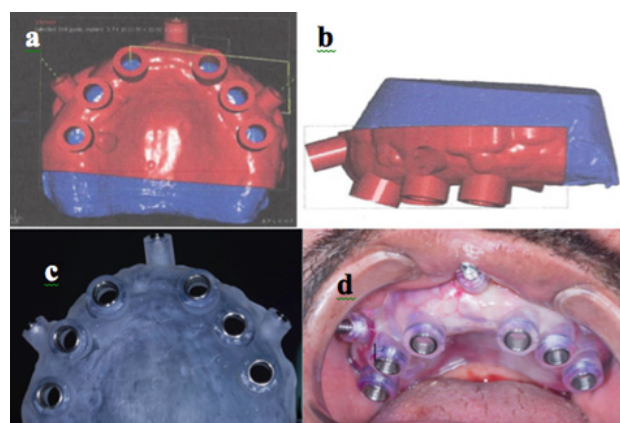


**Figure (1):** Planning the position of the six implants using computer software.

The plan on the virtual model was used to construct for each patient a mucosa supported surgical guide using Stereolithographic apparatus Envision tec. Figure (2 a,b)

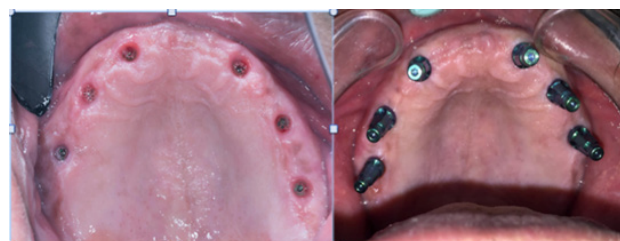The 3D surgical guide was provided with six metal sleeves corresponding to the virtually planned drilling sites with the precise depth, angulation, mesiodistal and buccolingual positioning of each implant as planned during the computer simulation for accurate placement of the implants' osteotomies.

The produced stereolithographic surgical guide with a rapid prototyping machine also contains three or two windows labially for the fixation screws with an adequate distance from the planned implant drilling sites. Figure (2c)



**Figure (2):** Stereolithographic surgical guide. a, b) Virtual planning c) Printed d) Placed intraoral and fixed in place.

At the surgical appointment, all participants administered prophylactic antibiotics (2 gm amoxicillin 1 hour prior to surgery) and mouth rinse 0.12% chlorhexidine digluconate (15 minutes before surgery). The surgical guide was properly placed and fixed to the maxilla using the fixation pins. Fig. (2 d) For each patient, six implants (Implant Direct, USA) were installed using the surgical guide of the patient and the universal surgical kit (In2Guide, Universal Kit Cybermed Inc) following flapless surgical approach. Implants were inserted through the surgical guide to ensure accurate positioning in the bone as planned in the software in all aspects. (Figure 3)



**Figure (3):** Implants inserted according to the planned sites.

Radiofrequency "smart pegs" (Smart Osstell peg, Gothenburg, Sweden) were fixed to the implant fixture and the magnetic resonance frequency was released from the probe, the magnetic peg was activated to check the initial stability for each implant to ensure its suitability for immediate loading. The activated peg starts to vibrate, subsequently the magnet induced electric volt into the probe coil then the electric volt was measured by the magnetic resonance frequency analyzer. Obtaining an immediate placement implant stability quotient (ISQ) value for each implant which were expressed as numbers between 1-100 in ISQ as Osstell (Osstell ISQ device, Gothenburg, Sweden). Average ISQ for immediate loaded implants ranged between 57-60.

After implantation, Open tray impression posts were connected to the multiunit abutments and splinted with auto polymerizing resin to avoid accidental movement during impression making. A special tray, perforated over the transfer copings, was used to allow detaching of the transfer following impression making. Afterwards the abutment analogues were connected to the impression posts and the impression was poured.

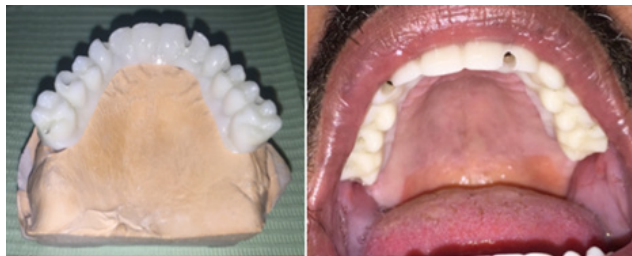Scan abutments were then screwed onto the implant analogues on the stone cast. Desktop extra-oral scanner was then used to scan the transfer abutments to accurately detect, the implants position and depth, in the computer software. Within the computer software, the transfer abutments were then replaced by Titanium bases stored in the library supplied with the software upon which the final prosthesis will be constructed. The prosthesis conforming to the patient's upper single denture was planned and designed.

After the plan was completed, prepolymerized PMMA prosthesis was milled, to be used intraorally in the next day, to check the passive fitting, extensions, pressure areas and high occlusal spots. Passive fit was checked visually by using a probe and by taking peri-apical radiographs at the implant sites to check for any misfits. It was then confirmed by the single screw Sheffield test which involved screwing the terminal abutment on one side and checking the fit on the other terminal abutment.

T scan (Tekscan®, South Boston, U.S) was used for detection of any occlusal premature contacts to be corrected. Where selective grinding is done and then is reused till the contact between posterior teeth is properly distributed and nearly equal intensity, in addition the intensity of the biting force bilaterally to be nearly equal. The same was done at protrusive and lateral eccentric positions.

After the necessary adjustments were done, the PMMA prosthesis was rescanned then delivered to the patient for immediate use throughout the 4 month healing period. After the healing period, the scan of the adjusted PMMA was used by the lab for Monolithic Zirconium milling for group I patients and for BioHpp Peek milling for group II patients.

The surface of zirconia fixed-detachable prosthesis was cut back to provide an even thickness of porcelain veneering to replicate the natural colour of gingiva. The STL file produced after merging and saving the prosthesis was done, from which milling of the prosthesis was implemented. Finally, zirconia fixed-detachable prosthesis was produced. (Figure 4)



**Figure (4):** Zirconia fixed-detachable prosthesis.

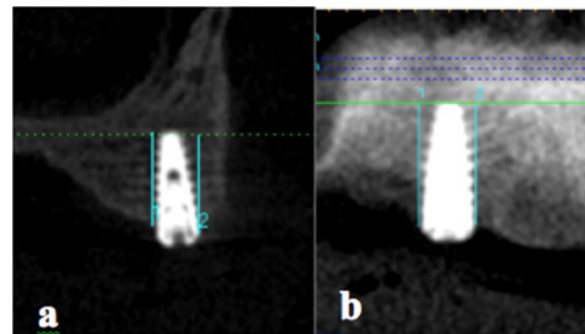
PEEK surfaces are pre-treated and conditioned using adhesive systems containing methylmethac-monomers, such as Visio.link (Visio.link, Bredent, senden, Germany) to bond composite veneering material using light curing. The final prosthesis was screwed in place and the screw access opening was sealed with composite resin for participants of both groups. The patients were instructed in a plaque control protocol, and this was reinforced at the subsequent follow up visits.

#### **Radiographic evaluation:**

Patients were frequently recalled every 3 months for inspection, post insertion adjustments, assess their

hygiene maintenance. CBCT radiographs at the time of implant loading, six month, one and two years post-operatively was taken and evaluated. T-scan was used to identify the needed occlusal adjustments at each follow up visit.

In operating the CBCT, the mid-line laser beam of the CBCT system was set to the mid sagittal plane of the patient's skull. The horizontal laser beam was adjusted parallel to the Frankfort plane. For the CBCT sections, the same cuts were taken in each follow up record by cutting through the mid of the selected implant (at its diameter as reference dimension). The radiographic measurements were taken by the same trained observer in all the records taken. Marginal bone height changes around the implants were evaluated using the measurement software system supplied with the CBCT radiographs. The marginal bone height around each implant (mesial, distal, buccal, lingual) was measured by measuring the distance from the alveolar crest to the line running horizontal through the implant apex. (Figure 5) Afterwards, the average of these measures was calculated for each implant. Data collected were tabulated and statistically analyzed.



**Figure (5):** The peri-implant bone height was measured. a) at buccal and palatal surfaces, b) at mesial and distal surface.

## **RESULTS**

Data were presented as mean difference and standard deviation. Intra and intergroup comparisons were done utilizing paired t-test and independent t-test respectively. The significance level was set at  $P \leq 0.05$  for all tests. Statistical analysis was performed with IBM® SPSS® (SPSS Inc., IBM Corporation, NY, USA) Statistics Version 25 for Windows. The mean of the total amount of bone height change of the installed implants in both groups were evaluated and compared.

Patients expressed satisfaction as regards function, retention and stability of their dentures. Clinically, no pain was elicited with palpation or percussion, no exudates were observed in relation to the implants. The study results are represented in tables (1-3) and (Figures 6-8).

1. Intragroup comparisons of bone loss for all six implants (mm):

A- Group I (patients rehabilitated with fixed-detachable zirconium restoration)

Mean difference and standard deviation (SD) values of bone loss (mm) in group (I) were presented in table (1) and (Figure 6)

The bone loss was significant at all follow-up intervals.

Table (1): Mean difference and standard deviation (SD) values of bone loss (mm) in group (I)

Bone loss in Group (I)			
Follow-up interval	Mean difference	SD	t-value
Baseline-6 months	0.35	± 0.02	3.2*
Baseline-12 months	0.62	± 0.04	3.92*
Baseline-24 months	0.96	± 0.03	4.32*

\*, significant ( $P \leq 0.05$ ) ns; non-significant ( $P > 0.05$ )

The mean value of peri-implant bone height change measures from insertion to six months after implant loading was found to be 0.35 mm and the mean value of peri-implant bone height change measures from insertion to twelve months after implant loading was found to be 0.62 mm. While the mean value of peri-implant bone height change measures from insertion to the end of twenty-four months follow up after implant loading was found to be 0.96 mm

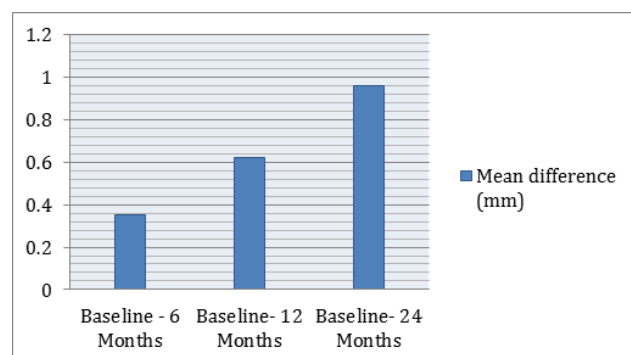


Figure (6): Bar chart showing mean difference of bone loss (mm) in group (I)

B- Group II (patients rehabilitated by with fixed-detachable BioHpp Peek restoration)

Mean difference and standard deviation (SD) values of bone loss (mm) in group (II) were presented in table (2) and (Figure 7)

The bone loss was significant at all follow-up intervals.

Table (2): Mean difference and standard deviation (SD) values of bone loss (mm) in group (II)

Bone loss in Group (II)			
Follow-up interval	Mean difference	SD	t-value
Baseline-6 months	0.39	± 0.12	3.4*
Baseline-12 months	0.69	± 0.09	4.1*
Baseline-24 months	1.23	± 0.08	4.62*

\*, significant ( $P \leq 0.05$ ) ns; non-significant ( $P > 0.05$ )

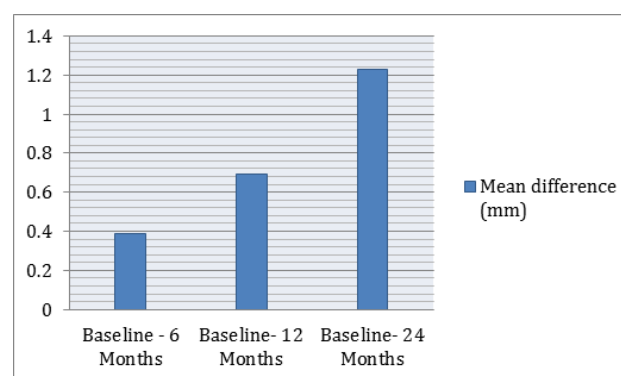


Figure (7): Bar chart showing mean difference of bone loss (mm) in group (II)

The mean value of peri-implant bone height change measures from insertion to six months after implant loading was found to be 0.39 mm.

and the mean value of peri-implant bone height change measures from insertion to twelve months after implant loading was found to be 0.69 mm. While the mean value of peri-implant bone height change measures from insertion to the end of twenty-four months follow up after implant loading was found to be 1.23 mm.

2. Intergroup comparisons of bone loss (mm): Mean, Standard deviation (SD) values of bone loss (mm) in both groups were presented in table (3) and (Figure 8) For all follow-up intervals, Group (II) had a non significant higher bone loss.

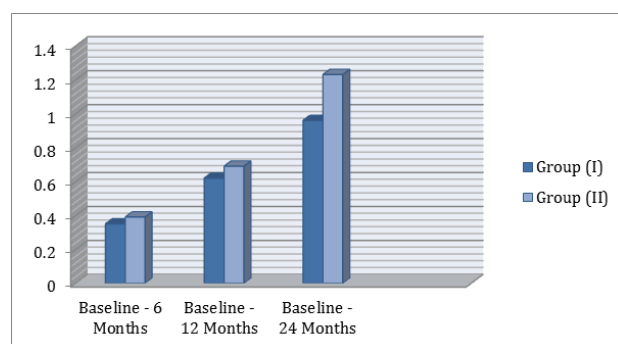
**Table (3):** Mean, Standard deviation (SD) values of bone loss (mm) in both groups

Bone loss in both groups (Mean $\pm$ SD)			
Follow-up interval	Group (I)	Group (II)	t-value
Baseline-6 months	0.35 $\pm$ 0.39	0.39 $\pm$ 0.12	-1.32 ns
Baseline-12 months	0.62 $\pm$ 0.04	0.69 $\pm$ 0.09	-1.95 ns
Baseline-24 months	0.96 $\pm$ 0.03	1.23 $\pm$ 0.08	-2.1 ns

\*; significant ( $p \leq 0.05$ ) ns; non-significant ( $p > 0.05$ )

To compare between the mean amount of peri-implant bone height changes in the two studied groups during the follow up intervals, student t test was performed and the results are shown in table (3) and (Figure 8).

Six months after denture insertion, the mean amount of the detected peri-implant bone loss was 0.35 mm and 0.39 mm for group I and group II respectively and Twelve months after denture insertion, the mean amount of the detected peri-implant bone loss was 0.62 mm and 0.69 mm for group I and group II respectively. While twenty-four months after denture insertion, the mean amount of the detected peri-implant bone loss was 0.96 mm and 1.23 mm for group I and group II respectively as shown in table (3).



**Figure (8):** Bar chart showing mean bone loss (mm) in both groups

## DISCUSSION

Recently the application of CAD/CAM technology and the improvements in ceramic materials as well as denture materials are of profound interest [14, 15]. It was remarkable to evaluate zirconia and BioHpp as framework for the fixed detachable maxillary single prosthesis, where strength and esthetics demands are paramount with maxillary prostheses.

Up-to-date advancements in dental materials, Novel CAD/CAM technology and 3D imaging combined with interactive treatment planning conceptions have provided specialists with new, reliable treatment options for their patients permitting for prosthodontic-driven proper implant placement and best substructure design for optimal aesthetics and biomechanics [15, 27]. A CAD/CAM manufactured prosthesis excludes many of the complications of the prosthetic alternatives since not using the lost-wax casting method aids to resolve any problems with casting distortion [28, 29].

3D surgical guide was provided with six metal sleeves corresponding to the virtually planned drilling sites with the precise depth, angulation, mesiodistal and buccolingual positioning of each implant as their positioning in the available bone and being parallel to each other and the applied masticatory forces would be along the long axis of the supporting implants, besides the appropriate anteroposterior distribution of the implants in the arch. All these factors of paramount importance on the success of the prosthesis and its supporting implants.

In this study the full framework used were Zirconia and BioHpp, and didn't use acrylic or porcelain teeth over it, because of their demerits like the rapid wear of acrylic denture teeth and porcelain teeth are generating stress within the framework which lead to marginal bone loss around implants. Besides using veneer materials has been frequently recognizable in implant prosthesis for their stress absorption and less wear [30, 31].

Veneering with composite-like materials on BioHPP frameworks will assist enhanced merging of pink esthetics to nearby oral soft tissues when compared to conventional complete denture materials [21].

The temporary and final prosthesis were carefully checked for their passive fitting, because in splinted-implant prosthesis, it is likely that the prosthesis itself may transfer strain to the bone-implant interface. Accordingly, the prosthesis was checked to be passively fit without any unnecessary pressure on the supporting dental implants, thus minimizing strain and the associated biological response [32].

Although, natural dentition causes occlusal forces that are 4-5 times more on the single denture than complete dentures, the results appeared favorable for both groups [33]. This may be attributed to the proper occlusal adjustments done with the help of the T scan to maintain the balanced occlusion at treatment planning and in the follow up visits.

T scan is used to digitally evaluate and diagnose occlusion, among its merits sensitivity, reliability and reproducibility [34, 35]. Besides it has the ability to record the first contact of teeth, relative force and timing. Thus the corrective adjustments of occlusion were made by selective grinding the marks detected by T scan. Accordingly several occlusal contacts distributed along the prosthesis, hence allowing distribution of the forces between the supporting implants and less loading will be encountered on them consequently enhance reducing the peri implant bone loss.

Cone Beam Computed Tomography (CBCT) was used for the radiographic evaluation because of its ability to present a fully 3-dimensional model of the maxillary and mandibular arches, CBCT provides a highly sophisticated format for accurately outlining the jaw structure and locating critical anatomic structures. CBCT scans, in combination with the software that renders immediate treatment plans using the most real and accurate records and for the evaluation of patients for dental implants [36, 37].

The advantage of CBCT that it allows the practitioner to measure peri-implant bone heights using standardized measurements at multiple levels over time and also allows evaluation of the marginal bone in the buccopalatal plane alongside with mesio-distal plane [38].

Before radiographic evaluation, in the follow up visit, the hybrid fixed detachable prosthesis was removed to avoid its radio-opacity superimposition on the surrounding tissues. In addition the underlying soft tissue health assessment was made to ensure that there is no signs of inflammation and that the patient followed the hygiene measures. There was found localized redness underneath the prosthesis in two patients in group II (rehabilitated with BioHpp Peek fixed-detachable prosthesis) this may be due to that patients didn't follow strict hygiene measures thus reassuring it was necessary.

Any required serviceability for the prosthesis was done where a male patient in group I (rehabilitated with Zirconia fixed-detachable prosthesis), in 12 month follow up visit, complained of some chipping in the veneering pink porcelain in the canine- premolar region that was sent to the laboratory where required adjustments were done during which the PMMA prosthesis was placed.

Success of dental implant treatment mostly depends on the maintainable long-term health of soft and hard tissues around the implants. Evaluation of pain, inflammation,

infection, mobility and marginal alveolar bone loss are all considered as valuable implant success criteria. Particular consideration has been lead towards post-operative radiographic assessment of marginal alveolar bone loss around dental implants with serial radiographs and monitoring the changes that occur with time. Vertical marginal bone loss at the implant surfaces should not exceed 1-2 mm during the first year of function and 0.2 mm afterwards was recognized as one of the implant successful criteria [39, 40].

The results of this current study revealed that the use of fixed-detachable CAD/CAM-based maxillary single prosthesis (both groups) fulfills the criteria of implant success as denoted by clinical examination and the measured amount of bone loss. Based on the radiographic findings of this study, it appears reasonable to suggest that primary implant stability, maintaining good oral hygiene, passive fit, control of occlusal load and patient compliance are important factors for the long term success of upper fixed-detachable single prosthesis designed by CAD/CAM irrespective of the material used within the follow-up period.

Bone loss appeared to be within the acceptable limits in both groups perhaps due to the prosthesis being constructed as passive as possible by CAD/CAM. Shah et al. [41], in a systematic review, showed that milling has proved to be more advantageous than casting as regards to passive fit and accuracy of the margins. The concept of clinical acceptable fit using CAD/CAM encompasses the purpose of minimizing both biologic and mechanical complications. Clinically acceptable fit in combination with properly directed and tolerated occlusal forces are important for ensuring success of the dental implants and can account for the results of this study.

The marginal bone loss around the implants that occurred during the follow up period, could have taken place owing to the surgical trauma due to drilling, the remodeling process post-implant insertion and/or due to the immediate occlusal loading. This bone loss could be based on the hypothesis that early marginal bone loss is non-infective remodeling process with variable amount occurring during the first year following implant insertion [42]. Moreover, It was explained as an early manifestation of wound healing, which occurs after implants placement, and as a reaction to loading. Crestal bone loss could also be explained by the finding that forces applied on implants are distributed on the crestal bone rather than along the entire bone-implant interface [43].

It was observed that more peri-implant bone height loss was detected for Group II patients (rehabilitated with BioHpp Peek fixed-detachable prosthesis) compared to Group I patients (rehabilitated with Zirconia fixed-detachable prosthesis) throughout the follow up period which was not statistically significant.



That could be explained that Zirconia has high modulus of elasticity which gave its framework rigidity to splint all the six implants with their distribution on the arch and made proper distribution of stresses between them like cross-arch stabilization.

The difference was not statistically difference may also be explained by the fact that when crown material has lower modulus of elasticity, it absorbs more energy from the applied force and less energy will be transmitted to the underlying structures. Thus the occlusal material of BioHPP will decrease the occlusal forces impact, accordingly reduces its effect on the implant-bone interface [44]. Crowns made of composite and acrylic resin materials are more up to absorb shock from occlusal forces than crowns made from zirconia ceramic material, or gold alloy [44, 45]. In addition, it may be attributed that Zirconia prosthesis has higher weights (52 gm) that may lead to more stress on the supporting structures [46].

It was noticed that occlusal stability was kept in group I patients (rehabilitated with Zirconia fixed-detachable prosthesis) where patients in group II (rehabilitated with BioHpp Peek fixed-detachable prosthesis) required more occlusal adjustments in the follow up visits which was detected by the T scan and accordingly were corrected. This can be attributed to its wear as opposed by natural teeth. It is recommended that further clinical trials to be done to provide well understanding of the materials' behavior over long-term under intraoral conditions, especially when opposed by different antagonists.

## **CONCLUSION**

---

Within the limitations of this study it was concluded that

- 1- Both Zirconia and BioHpp when used as framework material for fixed-detachable maxillary single prosthesis had successful results on the supporting implants.
- 2- BioHpp fixed-detachable prosthesis had higher effect on the peri implant marginal bone loss but was not of statistical significance.

## **CONFLICT OF INTEREST**

---

The authors declare no conflict of interest.

## **REFERENCES**

---

- 1- Dhiman R.K. and Chowdhury S.K.R.: Midline fracture in single complete acrylic vs flexible dentures. *MJAFI*. 2009; 65:141 -145.
- 2- Winkler S.: *Essentials of Complete Denture Prosthodontics*. 2nd edition. Ishiyaku Euroamerica; St. Louis: 1994.

3-Foong K. W. and Patil P. G.: Fabrication of maxillary single complete denture in a patient with deranged mandibular occlusal plane: A case report. *Saudi Dent J*. 2019 Jan; 31(1): 148–154.

4- Montero J., de Paula C.M., and Albaladejo A.: The 'Toronto prosthesis', an appealing method for restoring patients candidates for hybrid overdentures: a case report. *Journal of Clinical and Experimental Dentistry*. 2012; 4(5): 309–312.

5- Kwon T., Bain P.A. and Levin L.: Systematic review of short- (5–10 years) and long-term (10 years or more) survival and success of full-arch fixed dental hybrid prostheses and supporting implants. *J of Dent*. 2014; 42(10): 1228–1241.

6- Qamheya A.H.A., Yenyol S., and ArJsan V.: Full mouth oral rehabilitation by maxillary implant supported hybrid denture employing a fiber reinforced material instead of conventional PMMA. *Hindawi Publishing Corporation, Case Reports in Dentistry Volume 2015, Article ID 841745*, <http://dx.doi.org/10.1155/2015/841745>

7- Atwood DA, Coy WA. Clinical, cephalometric, and densitometric study of reduction of residual ridges. *J Prosthet Dent* 1971; 26(3): 280-95. cited from Gonzalez J.: The evolution of dental materials for hybrid prosthesis. *Open Dentistry Journal*. 2014; 8(1):85–94.

8- Gonzalez J.: The evolution of dental materials for hybrid prosthesis. *Open Dentistry Journal*. 2014; 8(1):85–94.

9-Laurell L.: Occlusal forces and chewing ability in dentitions with cross-arch bridges. *Swed Dent J Suppl*. 1985; 26: 160.

10- Jemt T., Carlsson L., Boss A. and Jörneüs L.: In vivo load measurements on osseointegrated implants supporting fixed or removable prostheses: a comparative pilot study. *Int J Oral Maxillofac Implants*. 1991; 6(4): 413-417.

11- Brånemark P.I.: Osseointegration and its experimental background. *The J. of Prosth Dent*. 1983; 50 (3): 399-410.

12- Hahnel S., Behr M., Handel G. and Rosentritt M.: Two-body wear of artificial acrylic and composite resin teeth in relation to antagonist material. *J. of Prosth. Dent*. 2009; 101(4): 269–278.

13- Preis V., Hahnel S., Behr M., Bein L. and Rosentritt M.: In-vitro fatigue and fracture testing of CAD/CAM-materials in implant-supported molar crowns. *Dent Mater*. 2017; 33(4):427–433.

14- Miyazaki T., Hotta Y., Kunii J., Kuriyama S. and Tamaki Y.: A review of dental CAD/CAM: current status and future perspectives from 20 years of experience. *Dent Mater J*. 2009 Jan; 28(1):44-56.

- 15- Brenes C., Duqum I. and Mendonza G.: Materials and systems for all ceramic CAD/CAM restorations. *Dental Tribune. CAD/CAM international magazine of digital dentistry.* 2016; 3:10-5.
- 16- Benakatti V.B., Sajjanar J.A. and Acharya A.: Polyetheretherketone (PEEK) in Dentistry. Review article. *Journal of Clinical and Diagnostic Research.* 2019 Aug; 13(8):10-12.
- 17- Ortega-Martínez J., Farré-Lladós M., Cano-Batalla J and Cabratosa-Termes J.: Polyetheretherketone (PEEK) as a medical and dental material. A literature review. *Arch Med Res.* May 2017; 5(5):01-16.
- 18- Rahmitasari F., Ishida Y., Kurahashi K., Matsuda T., Watanabe M., and Ichikawa T.: PEEK with Reinforced Materials and Modifications for Dental Implant Applications. *Dent J (Basel).* 2017 Dec; 5(4): 35.
- 19- Bredent. The new class of materials. [www.bredent.com](http://www.bredent.com). 2016; 5,6.
- 20- Skirbutis G., Dzingute A., Masiliunaitė V., Sulcaite G. and Zilinskas J.: A review of PEEK polymer's properties and its use in prosthodontics. *J Stomatologia Baltica and Maxillofac.* 2017; 19:19-23.
- 21- AL-Rabab'ah, M., Hamadneh, W., Alsalem, I., Khraisat, A. and Abu Karaky A.: Use of high performance polymers as dental implant abutments and frameworks: a case series report. *J of Prosthodont.* 2019; 28(4): 365–372. <https://doi.org/10.1111/jopr.12639>
- 22- Abd El-Ghany O.S, and Sherief A.H.: Zirconia based ceramics, some clinical and biological aspects: Review. *Future Dental Journal.* 2016; (2):55-64
- 23- Tipton P. Full Arch Implant Restoration. *Implant Practice US:* June 18, 2015.
- 24- Wong N. Future Trends in Implant Dentistry: Digitally Guided Surgery and Prosthetics. *Dent Today* 2016; 35:86-91.
- 25- AlHelal A., AlBader B., Kattadiyil M.T., Garbacea A. and Proussaefs P.: CAD- CAM implant-supported fixed complete dental prosthesis with titanium milled molars: A clinical report. *J Prosthet Dent* 2017; 117:463-469.
- 26- Benetti P., Pelogia F., Valandro L.F., Bottino M.A. and Bona A.D.: The effect of porcelain thickness and surface liner application on the fracture behavior of a ceramic system. *Dent Mater.* 2011 Sep; 27(9):948-53.
- 27- Tekin S., Cangül S., Adıgüzel Ö. and Değer Y.: Areas for use of PEEK material in dentistry. *International Dental Research.* 2018 Aug 27; 8(2):84-92.
- 28- Karl M. and Holst S.: Strain Development of Screw Retained Implant-Supported Fixed Restorations: Procera Implant Bridge versus Conventionally Cast Restorations. *Int J Prosthodont.* 2012; 25(2):166-169.
- 29- Almasri R., Drago C., Crane Siegel S. and Hardigan P.: Volumetric Misfit in CAD/CAM and Cast Implant Frameworks: A University Laboratory Study. *J of Prosthodont.* June 2011; 20(4):267-74. DOI:10.1111/j.1532-849X.2011.00709.x
- 30- Heintze S.D., Zellweger G., Grunert I., Muñoz-Viveros C.A. and Hagenbuch K.: Laboratory methods for evaluating the wear of denture teeth and their correlation with clinical results. *Dent Mater.* 2012; 28(3):261–272.
- 31- Radhi A., Juszczak A.S., Curtis R.V., Sherriff M., Radford D.R. and Clark R.K.F.: Effect of GC METALPRIMER II on bond strength of heat-cured acrylic resin to titanium alloy (Ti- 6Al-4V) with two different surface treatments. *The European Journal of Prosthodontics and Restorative Dentistry.* 2008; 16(3): 132–137.
- 32- Abduo J., Bennani V. and Waddell N.: Assessing the Fit of Implant Fixed Prostheses: A Critical Review. *Int J Oral Maxillofac Implants.* 2010; 25(3):506-515.
- 33- Fontijn-Tekampel F.A., Slagterl A.P., Van Der BiMO A., Van 'T Hof M.A., Witter D.J., Kalk W., and Jansen J.A.: Biting and Chewing in Overdentures, Full Dentures, and Natural Dentitions. *J Dent Res.* 2000; 79(7): 1519-1524.
- 34- Cerna M., Ferreira R., Zaror C., Navarro P. and Sandoval P.: Validity and reliability of the T-Scan III for measuring force under laboratory conditions. *J Oral Rehabil* 2015; 42:544–551.
- 35- Koos B., Godt A., Schille C. and Göz G.: Precision of an instrumentation-based method of analyzing occlusion and its resulting distribution of forces in the dental arch. *J Orofac Orthop* 2010; 71:403–410
- 36- Garg A.K.: Dental implant imaging: TeraRecon's Dental 3D Cone Beam Computed Tomography System. *Dent Implantol Update.* 2007;18(6):41–45.
- 37- Roe P., Kan J.Y.K., Rungcharassaeng K., Caruso J.M., Zimmerman G. and Mesquida J.: Horizontal and vertical dimensional changes of peri-implant facial bone following immediate placement and provisionalization of maxillary anterior single implants: a 1-year cone beam computed tomography study. *Int J Oral Maxillofac Implants.* 2012; 27(2):393–400.
- 38- De Faria Vasconcelos K., Evangelista K.M., Rodrigues C.D., Estrela C., De Sousa T.O. and Silva M.A.G.: Detection of periodontal bone loss using cone beam CT and intraoral radiography. *Dentomaxillofac Radiol.* 2012;41(1):64–69.

- 39- Adell R., Lekholm U., Rockler B. and Brånemark P.I.: A 15-year study of osseointegrated implants in the treatment of the edentulous jaw. *Int J Oral Surg.* 1981 Dec; 10(6):387-416.
- 40- Albrektsson T., Zarb G., Worthington P. and Eriksson A.R.: The long-term efficacy of currently used dental implants: a review and proposed criteria of success. *Int. J. Oral Maxillofac. Implants*, 1986; 1(1):11-25.
- 41- Shah S., Veeraiyan D. N. and Ganapathy D.: Marginal Accuracy of Milled Versus Cast Cobalt Chromium Alloys in Long Span Implant-Supported Frameworks: A Systematic Review and Meta-analysis. *Journal of Advanced Oral Research.* Nov 2020; 11(2):120-127. DOI:10.1177/2320206820952303
- 42- Oh T.J., Yoon J., Misch C.E. and Wang H.L.: The causes of early implant bone loss: myth or science? *J Periodontol.* 2002 Mar; 73(3):322-333.
- 43- Ueda T., Kremer U., Katsoulis J. and Mericske-Stern R.: Long-term results of mandibular implants supporting an overdenture: implant survival, failures, and crestal bone level changes. *Int J Oral Maxillofac Implants.* 2011; 26:365-372.
- 44- Menini M, Conserva E, Tealdo T, Bevilacqua M., Pera F., Signori A. and Pera P.: Shock absorption capacity of restorative materials for dental implant prostheses: an in vitro study. *Int J Prosthodont.* 2013; 26(6):549-556.
- 45- Conserva E., Menini M., Tealdo T., Bevilacqua M., Ravera G., Pera F., Pera P.: The use of a masticatory robot to analyze the shock absorption capacity of different restorative materials for prosthetic implants: a preliminary report. *Int J Prosthodont.* 2009; 22(1):53-55.
- 46- Seemann R., Marincola M., Seay D., Perisanidis C., Barger N. and Ewers R.: Preliminary results of fixed, fiber-reinforced resin bridges on four 4×5-mm ultra short implants in compromised bony sites: a pilot study. *J Oral Maxillofac Surg.* 2015; 73(4):630-640. doi:10.1016/j.joms.2014.10.031.