

Modification of Marking Procedure in Anatomical Subunit Approximation Technique in Treatment of Unilateral Cleft Lip

Original Article

Ahmed O.Sweedan¹, Ziad T. Mahmoud¹, Mohamed Shokry²

Lecturer of Oral and maxillofacial surgery, Department of Oral and maxillofacial surgery, Faculty of Dentistry, Alexandria University, Egypt¹, Associate Professor of Oral and maxillofacial surgery, Department of Oral and maxillofacial surgery, Faculty of Dentistry, Alexandria University, Egypt²

ABSTRACT

Background: Cleft lip repair necessitates the restoration of normal function and form. David M. Fisher presented a novel method for unilateral cleft lip repair called "anatomical component approximation technique" in 2005. It is a "measure twice, cut once" manner of mending as compared to other methods. The design is time-consuming because it relies on 25 landmarks. This article aimed to develop a more clinically based method using a bendable wire rather than measuring lengths by caliper in the original technique described by Fisher

Material and method: This study was carried out as a clinical trial conducted on 18 patients suffering from unilateral cleft lip deformity treated with Fisher's technique but with modified technique in marking procedure

Results: cleft side was compared to non-cleft side in philtral ridge length and nostril width in all patients and no statistical difference was found indicating esthetically acceptable results.

Key Words: cleft lip, Fisher's technique, modification, Anatomical Subunit Approximation Technique

Received: 1 June 2022, **Accepted:** 3 June 2022.

Corresponding Author: Ahmed O.Sweedan, Lecturer of Oral and maxillofacial surgery, Department of Oral and maxillofacial surgery, Faculty of Dentistry, Alexandria University, Egypt, **Mobile:** +20 100 733 1394

E-mail: Drahmed.sweedan@gmail.com.

ISSN: 2090-097X, January 2022, Vol. 13, No. 1

INTRODUCTION

Closing the lip defect, reconstructing the Orbicularis oris muscle with muscle continuity, reconstructing aesthetic lip components (e.g. columella, cupid's bow, white roll, vertical and horizontal lip height, vermilion thickness beneath the cleft), creating a philtral ridge that mimics the none-cleft philtral ridge, developing the labial sulcus, correcting nasal asymmetry, and closing the nasal floor are the primary goals of cleft lip repair.^[1]

Thomson's modification^[2] of the Randall-Tennison^[3,4], and the inferior triangle repair together with Noordhoff's modification^[5] of Millard's rotation-advancement technique were proposed by Fisher^[6] as a hybrid of these two techniques.^[7-9] Mirault^[10] and contemporaries^[3,4] pioneered cleft lip skin advancement with transposition flaps, but the resulting scar spans the philtral dimple noticeably. Millard^[11] originally presented rotation advancement procedures, which were later improved by Mohler^[12] to update cleft healing by retaining the philtral indentation. While excellent results can be achieved using Millard's

technique; there are some drawbacks, such as scars on or under the columella that can lead to hypertrophy,^[13] lip length imbalances,^[14] widened superior upper lips (due to insufficient tissue resection), and a short commissure to Cupid's bow length ratio (due to compromising Noordhoff's point laterally to achieve rotation or in an attempt to create adequate lip height).^[15] The ability of the anatomic subunit approach to place the final line of repair at the seams of aesthetic subunits is of a notable strength.^[6]

Fisher's technique^[6] has been widely adopted and adapted in the 16 years since he first explained it. Tse and Lien^[16] demonstrated that this technique is repeatable and has acceptable early results. Even as recently as a few years ago, most North American surgeons still used a Millard procedure version.^[17] For some, the transition from "cutting as you go" lip skin and muscle advancement to a pre-planned pattern of release and repair may be intimidating. Fisher's original paper's copious markings demonstrate the substantial attention he put into designing a balanced lip and the evolution of his design.^[6]

Jordan et al. [18] had seen that many specific markers and motions appear to be very significant in facilitating knowledge and execution of the Anatomic Subunit approach while teaching other surgeons. These aren't limited to incisional design but also the necessity of the repair sequence, as well as accurate marking procedure to help incision placement at anatomical subunit borders.

One of the challenging points in Fisher's technique was the need to use three calipers in order to determine the place of the triangle base in relation to Noordhoff's point and nasal sill on the lateral element of cleft lip, one can be set to each of these lengths and used as a compass to lay out the optimum fit of the intervening spots.^[18]

According to Tse^[19] It is a "measure twice, cut once" manner of mending as compared to other methods. The design is time-consuming because it relies on 25 landmarks.

This article aimed to develop a more clinically based method using a bendable wire rather than measuring lengths by caliper in the original technique described by Fisher in order to achieve acceptable results and make it easier and more applicable for the surgeon.

MATERIALS AND METHODS:

This study was carried out as a clinical trial conducted on 18 patients suffering from unilateral cleft lip deformity selected from Outpatient Clinics of Oral and Maxillofacial Surgery Department, Faculty of Dentistry- Alexandria university. The patient's parents, as well as all patients whose images were used in this study, gave their written informed consent.

The Inclusion criteria were, presence of unilateral cleft lip deformity either right or left side, range from 3 months to 2 years old, more than ten pounds' weight, and not less than 10 mg/dl hemoglobin level. While the exclusion criteria were, syndromic cleft patients, bilateral cleft lip, presence of other facial clefts and finally, presence of any medical condition contraindicating surgery under general anesthesia.

Materials:

Sterile surgical bendable stainless steel wire 0.5mm in diameter, wire plier, surgical marker, measuring caliper, and cleft lip surgical equipment set including castrviego fine tissue forceps, skin hooks, suture material of 50- vicryl and 60- prolene with non-cutting end needle, ribbon-handled suture scissors, bard parker scalpel handle No.3 and blade No. 15, hemostat, and retractors were used to perform the surgical procedures.

Methods:

All patients were given a medical consultation to ensure that they were medically fit to undergo surgery as part of the pre-surgical assessment and examination. In addition to photographic evidence, a blood test (CBC), bilirubin (direct, indirect, and total), and coagulation profile were all done.

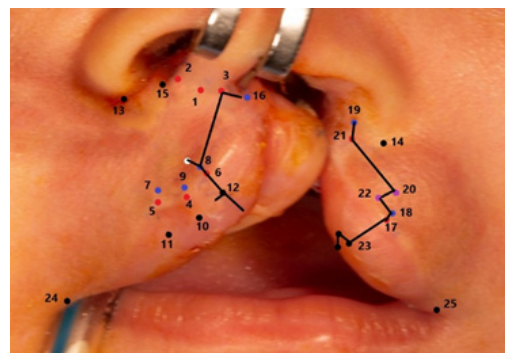
Lip-taping was applied to patients with a wide cleft lip at least one month before surgery. Before the procedure, all patients fasted for at least 6-8 hours. The study's anthropometric measurements in millimeters (philtral ridge height, cleft nostril width, and non-cleft nostril width) were taken directly on patients before surgery and indirectly on a 2D image taken 3 months later.

Surgical phase:

After inducing general anesthesia and placing a fitted oral endotracheal tube, all patients underwent the same surgical procedures. To prevent head movement, the patient was positioned in a supine position with a slightly stretched neck and a minor head roll. The face was swabbed and with betadine solution, the patient's eyes were closed, and a thin coat of Vaseline was applied before being protected and covered with sterile surgical adhesive tapes. As a preliminary step, methylene blue tattooing and a 30-gauge needle were used to outline the flap pattern. To reduce bleeding during incision, superior labial artery pressure is used. The flap was opened with a surgical blade No. 15 on a scalpel No. 3. The surgical flap was then done following our modification for anatomical subunit approximation technique (Fisher) outline.

Fisher landmarks include:^[18] Marks for the medial lip element: (1) midline, (2) height of the non-cleft philtral column, (3) height of the cleft philtral column at the lip-columellar crease (4) lip midline, (5) non-cleft cupid's peak, (6) cleft cupid's peak at vermilion-cutaneous junction Just above the white roll, at the intersection of the white roll and the flat lip area (7,8); (9) is just above point (4) on the flat lip area; (10) is just below point (4) on vermilion (4) Alar bases (13,14) are located at the lip-alar junction. (16) is marked on the nasal sill and represents lip height at the point of closure. (16,15) are arbitrary and identically placed on the nasal sill. (Figure 1)

Figure 1: The 25 anatomical landmarks of fisher technique for cleft lip repair



Lateral lip element landmarks: (17) is at Noordhoff's point; (18) is marked slightly above point (17) on the cutaneous roll; (19) is superomedial to (14) and on the site of nasal sill closure. (20,21,22) are marked using our modification technique where bendable stainless steel wire was used, the length of the wire was cut to be equal to non-cleft side philtral ridge length (2 to 7) then by transferring the wire to the cleft side philtral ridge (3 to 8) we bended the extended part of the wire thus the bended part represented the lesser lip height while the part conforming with cleft side philtral ridge (3 to 8) presented the greater lip height. The bended wire was then transferred to the lateral lip element and the degree of bending angle was changed till the wire started at point 18 and ended at 20 which was medial to 19 so that (19 to 20) was equal to (16 to 3) in length.

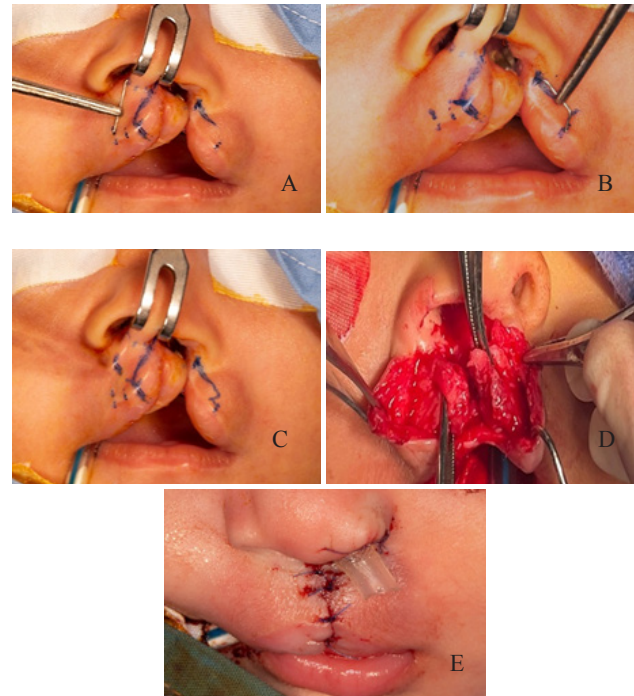
Point 21 was placed at the angle of the bended wire thus 18 to 20 represented the base of the inferior triangle and also the lesser lip height. Point 22 was the tip of the triangle. (Figures 2 a & b)

The incision line then was drawn at the medial lip element starting from point 16 to 3 to 8 till 6 then extended on the vermilion border. At the lateral lip element, the line of incision was drawn from 19 to 20 to 21 then 22 the tip of the triangle then to 18 till 17 then extended on the vermilion border. (Figure 2 c)

Incisions were made with a scalpel and finished with scissors on the medial lip element. Above the cutaneous roll, the incision is made via the skin and subcutaneous tissue rather than the muscle. Cleft margin tissue is removed and discarded. The muscle is dissected from the covering skin and vermilion, as well as the underlying mucosa. To preserve the philtral indentation, dissection between skin and muscle is confined to 1 mm from the cut edge. In the region of the columellar base and upper alveolar cleft margin, the orbicularis is freed from its upturned insertion. The dissection between skin and muscle on the lateral lip element is more extensive, reaching laterally as far as the alar base to relieve the orbicularis muscle bulge. Orbicularis is released from its upturned insertion in the upper alveolar cleft edge and alar base. The alar base is separated from the underlying maxilla by a thorough muscle dissection in a supra-periosteal plane. (Figure 2 d)

Blade No. 11 or surgical scissors were used to remove and eliminate cleft marginal tissue. The tissue tension is then assessed by bringing the flap margins closer together before the final lip closure. The primary wound will be repaired in a layering approach, with the muscle layer being closed with 5-0 vicryl suture and the skin being closed with a basic interrupted technique and 6-0 prolene suture with a non-cutting end needle (Figure 2 e). The surgical site was covered with adhesive tapes (Steri-Strips- 3M™ USA).

Figure 2: A- Application of the stainless-steel wire on none cleft side philtral ridge. B- Application of bended wire on the lateral element of cleft lip side. C- Marking of the incision lines using methylene blue. D- Dissection of skin and muscle layers prior to their approximation. E- Suturing of the cleft immediately postoperatively



Post-operative phase:

A ten-day course of antibiotic ointment (FUCIDIN 2% 30 gm Leo – UK) was prescribed. Breastfeeding is prohibited for two weeks. Scaro gel (Macro Group Pharmaceuticals-Egypt) was also prescribed for a period of three months.

Post-operative assessment and evaluation:

Patients were recalled 7-14 days after surgery. After 14 days, the sutures were removed. At 3 months, patients were recalled for scar evaluation and photographic recording (frontal and lateral views) to assess nasal asymmetry (cleft side and non-cleft side nostril) and nasal profile, including upper lip, using the Asher-McDade aesthetic index.^[20]

Statistical analysis:

Data were fed to the computer and analyzed using IBM SPSS software package version 20.0. (Armonk, NY: IBM Corp). For continuous data, they were tested for normality by the Shapiro-Wilk test. Distributed data were expressed as range (minimum and maximum), mean, standard deviation and median for normally distributed quantitative variables Paired t-test was used to compare between Non-cleft side and cleft side. Significance of the obtained results was judged at the 5% level

RESULTS

Eighteen patients aged one to 14 months met the inclusion criteria (mean \pm SD, 5.0 ± 2.71 months). 62.1% were males and 37.9% were females' participants. Complete unilateral cleft lip was present in 6 patients while incomplete unilateral cleft lip was present in 7 patients and 5 patients had previously repaired unilateral cleft lip but needed lip revision due to ugly scar and imperfect result from the first surgery. All of the operated patients finish the surgery and the follow up period successfully without any complications. The left side cleft was more prevalent (72.2%) and isolated incomplete unilateral cleft lip was the most common type (38.8%).

Nasal dimension:

The cleft side nostril width and non-cleft side nostril width was measured three months postoperatively. The mean nostril width at the none cleft side was 8.61 ± 2.25 , while on the cleft side it was recorded to be 8.56 ± 1.98 . by comparing both results together, it was found that there is none-statistically significant difference $p=0.826$.

(Table 1, Figure 3)

Lip length dimensions:

Philtral ridge height was measured and compared between the cleft side and non-cleft side also at 3 months post-surgically. The philtral ridge height at the none clefted side was 9.33 ± 1.46 and on the clefted side, it was 9.33 ± 1.61 . by comparing both results, none- statistical difference was observed. (Table 1, Figure 4)

Table (1): Comparison between Non-cleft side and Cleft side according to nostril width and philtral ridge height

	Non-cleft side (n = 18)	Cleft side (n = 18)	t	p
Nostril Width				
Mean \pm SD.	8.61 ± 2.25	8.56 ± 1.98	0.223	0.826
Median (Min. – Max.)	8.5 (5 – 13)	9 (5 – 12)		
Philtral ridge height				
Mean \pm SD.	9.33 ± 1.46	9.33 ± 1.61	0.000	1.000
Median (Min. – Max.)	9 (7 – 12)	9 (7 – 13)		

SD: Standard deviation t: Paired t-test

p: p value for comparing between Non-cleft side and Cleft side

Figure 3: Comparison between Non-cleft side and Cleft side according to nostril width

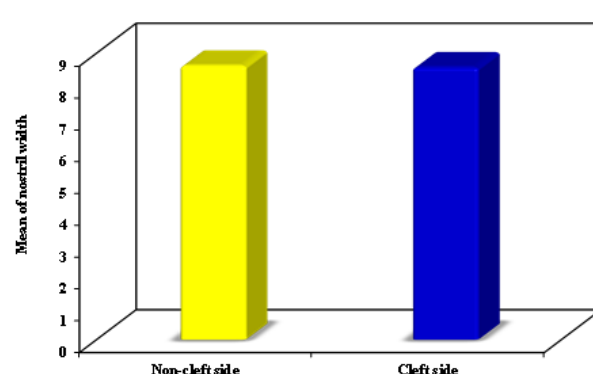
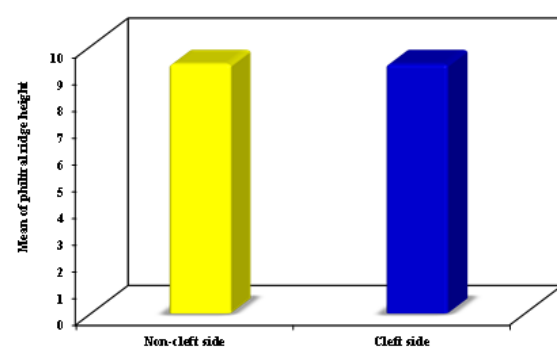



Figure 4: Comparison between Non-cleft side and Cleft side according to philtral ridge height



Nasolabial appearance:

The Asher-McDade aesthetic index (appearance of the patients' nose and lip) was utilized, which is based on a 5-point ordinal scale with four facial structures (nasal form, nasal deviation, vermilion border shape, and nasal profile including upper lip). The nasolabial look was satisfactory, and the nares circumference was symmetrical on both the cleft and non-cleft sides, according to this qualitative examination. The majority of surgical outcomes were regarded as very good or good. (Figure 5)

Figure 5: Three months post-surgical photo showing acceptable aesthetic results of the cleft lip repair.



DISCUSSION

Fisher created the Anatomical Subunit Approximation Technique (Fisher technique) in 2005 as a revision of the straight-line method. It is regarded as a relatively new approach. Fisher technique repair despite its successful clinical results was considered to be technique sensitive as it has precise measurements and a wider number of possible equivalent dimensions of anatomical subunits preoperatively and intraoperatively, Fisher's concept separates cleft into two anatomically separated components; nasal (nasal base, alar rim) and lip (white roll, vermillion, and philtral ridge).^[21,22]

Fisher's postoperative nasolabial results are virtually always predictive, and the scar is created in a more anatomical position from the apex of the cupid's bow to the nasal base, where it is covered behind the base of the columella and within the white roll. Fisher's design, on the other hand, is regarded as a time-consuming and sophisticated procedure due to the utilization of 25 markers and guided lip healing.^[23]

Jordan et al.^[12] stated in his study on Fisher's technique that Anatomical Subunit Approximation lip repair, which uses fewer skin lines, points, and measurements appears to help surgeons achieve symmetrical surgical outcomes. In our study 18 cases of unilateral cleft lip were treated using Fisher technique with our modification focusing on marking the incision line in lateral lip element using bendable wire replacing the regular calipers and ordinary measurements done by Fisher.

However, our modification followed the concept and points of anatomical subunit approximation technique. In the original technique described by Fisher the medial and lateral lip element incision line was measured using calipers so that on the medial lip element under no stress, callipers are used to measure the noncleft philtral column (length "a"). The cleft side is then measured (length "b") with the lip slightly unfurled to simulate the stress of the repair by flattening it out. The columella should not migrate caudally as a result of the stress. A perpendicular to the philtrum inset incision, "c," is noted, with length determined by the equation $a-b=c$.^[18]

While on the lateral lip element The nostril sill mark is superiorly defined, and Noordhoff's point is inferiorly defined, but the two intermediate points are not. The bottom is the triangular flap of length "c," and the middle is philtral column height "b," both measured when the medial lip was measured (above); the top is the medial columellar-nasal sill line, which is equal in length. By using three calipers, one can be set to each of these lengths and used as a compass to lay out the optimum fit of the intervening spots.^[18]

This step makes the original technique by Fisher more sophisticated, while in our modification we utilized bendable 0.5 mm stainless steel wire that was cut to the length of non-cleft side philtral ridge length, then used as a guide for drawing the medial and lateral skin incisions. Simply the wire placed over the cleft side medial element philtral ridge and the excess of it was bended to represent the cut back made at the medial cleft element. Then the bended wire transferred to the lateral side and the small bended end placed over Noordhoff's point and the wire is adjusted so that the other end reach to the nasal sill point at the top of it. The small bended part will be the base of the inferior triangle. This technique made it easier and less technique sensitive.

The esthetic results of this modification in our study was satisfying according to the philtral ridge height when compared the cleft side with the non-cleft side as there was no statistical difference in lip height. Nostril width at the cleft side when compared with the non-cleft side also showed no significant difference which is indicating satisfactory esthetic result.

These results are compatible with other studies made on Fisher's technique without any modification as Zhou et al.^[24] clinical trial on Fishers technique found that the early postsurgical results of those children were satisfactory, as measured by clinical evaluation and anthropometric measurement. At one year after surgery, the differences between measurements of lip height, lip length, nasal floor width, and distance from the bottom midpoint of nasal columella to the point of lip peak on the cleft side and those on the non-cleft side were all significantly reduced

Alex et al.^[25] also had satisfactory esthetic results regarding philtral ridge height and nostril width at the cleft side in evaluation of fisher's technique which is like our results after our modification on the same technique.

CONCLUSION

This modification described throughout this research did not affect the acceptable and satisfactory results of the original fisher's technique, indeed its added value was making the technique less sophisticated and furthermore, it does not need caliber measurements.

CONFLICT OF INTEREST

The authors declare no conflict of interest.

REFERENCES

1. Michael L. Bentz, Bruce S. Bauer, Ronald M. Zuker Principles and Practice of Pediatric Plastic Surgery. 2nd ed. Stuttgart; Germany Thieme; 2018
2. Thomson HG. Unilateral cleft lip repair. Oper Tech Plast Reconstr Surg. 1995;2:175-181.
3. Tennison CW. The repair of the unilateral cleft lip by the stencil method. Plast Reconstr Surg. 1952;9(2):115-120.
4. Randall P. A triangular flap operation for the primary repair of unilateral clefts of the lip. Plast Reconstr Surg Transplant Bull. 1959;23(4):331-347.
5. Noordhoff MS. The Surgical Technique for the Unilateral Cleft Lip-Nasal Deformity. Noordhoff Craniofacial Foundation; 1997.
6. Fisher DM. Unilateral cleft lip repair: an anatomic subunit approximation technique. Plast Recon Surg. 2005;116(1):61-71.
7. Fisher DM. Unilateral cleft lip repair – anatomic subunit approximation technique. In: Losee J and Kirschner RE eds. Comprehensive Cleft Care. 2nd ed. CRC Press; 2015.
8. Millard DR. Complete unilateral clefts of the lip. Plast Reconstr Surg. 1960;25:595-605.
9. Millard DR. Extensions of the rotation-advancement principle for wide unilateral cleft lips. Plast Reconstr Surg. 1968;42:535-544.
10. Millard DR. Cleft Craft. The Evolution of Its Surgery. Vol 1. Lippincott Williams and Wilkins; 1976
11. Millard DR, Jr. A radical rotation in single harelip. Am J Surg. 1958;95(2):318-322.
12. Mohler LR. Unilateral cleft lip repair. Plast Recon Surg. 80(4):511-517.
13. Barbel H, Wray RC. Randomized comparison of triangular and rotation advancement unilateral cleft lip repairs. Plast Reconstr Surg. 1983;71:172.
14. Williams HB. A method of assessing cleft lip repairs: comparison of LeMesurier and Millard techniques. Plast Reconstr Surg. 1968;41:103.
15. Christofides E, Potgieter A, Chait L. A long-term subjective and objective assessment of the scar in unilateral cleft lip repairs using the Millard technique without revisional surgery. J Plast Reconstr Aesthet Surg. 2006;59:380-386.
16. Tse R, Lien S. Unilateral cleft lip repair using the anatomic subunit approximation: modifications and analysis of early results in 100 consecutive cases. Plast Reconstr Surg. 2015;136:119-130.
17. Sitzman TJ, Giroto JA, Marcus JR. Current surgical practices in cleft care: unilateral cleft lip repair. Plast Reconstr Surg. 2008;121:261e-270e
18. Jordan W. Swanson, Aaron C. Van Slyke, David K. Chong. Principalization of the Anatomical Subunit Approximation Technique of Unilateral Cleft Lip Repair. FACE 2021; 2(3): 225–35.
19. Tse R. Unilateral cleft lip: principles and practice of surgical management. Semin Plast Surg. 2012;26(4):145-55.
20. Mosmuller DG, Bijnen CL, Kramer GJ, Disse MA, Prah C, Kuik DJ, Niessen FB, Griot JD. The Asher-McDade aesthetic index in comparison with two scoring systems in nonsyndromic complete unilateral cleft lip and palate patients. Journal of Craniofacial Surgery. 2015 Jun 1;26(4):1242-5.
21. Hakim SG, Aschoff HH, Jacobsen HC, Sieg P. Unilateral cleft lip/nose repair using an equal bows/straight line advancement technique—a preliminary report and postoperative symmetry-based anthropometry. Journal of Cranio-Maxillofacial Surgery. 2014 1;42: e39-45.
22. Vyas RM, Warren SM. Unilateral cleft lip repair. Clin Plast Surg. 2014; 41:165-77.
23. Funayama E, Yamamoto Y, Furukawa H, Murao N, Shichinohe R, Hayashi T, Oyama A. A new primary cleft lip repair technique tailored for Asian patients that combines three surgical concepts: Comparison with rotation-advancement and straight-line methods. J Craniomaxillofac Surg. 2016; 44:27-33.
24. Zhou Jian-Hong, Huang Xin, Xu Zhen-Hua. Fisher's Anatomical Subunit Approximation Technique in Cleft Lip Repair[J]. Journal of Oral and Maxillofacial Surgery, 2017, 27(3): 199-203.
25. Alex J Davies, Nigel SG Mercerab. Unilateral cleft lip repair: A 'cut as you go' approach to the anatomical subunit approximation technique. J Plastic Recon Aesthetic Surg. 2019; 72(7): 1219-43.