

Research Article

A comparison between implant retained mandibular overdenture using Bullard abutments versus Ball and socket abutments (Clinical assessment)

Mohamed S. Faried¹ and Gehan F. Mohamed²

¹Removable Prosthodontics, Faculty of Dentistry, Sinai University- Kantra Branch.

² Removable Prosthodontics, Faculty of Dentistry, Minia University

Abstract

Background: There are different modalities of treatment for mandibular edentulous. This study aimed to evaluate marginal bone loss in implant retained mandibular overdenture using bullard versus ball and socket abutments clinically. **Methods:** twelve completely edentulous patients were selected from the Outpatient Clinic of the Prosthodontic department, Minia University, and were randomly allocated to two equal groups Ball & socket and Bullard abutments mandibular overdenture. All patients received 2 implants, 3.5 mm in diameter and 10 mm in length, were inserted in canine region. In the first group, prosthesis was retained by ball and socket attachments while in the second group, prosthesis was retained by Bullard attachment. For each patient in both groups marginal bone loss was assessed clinically by periodontal probe at time of denture delivery, then six and twelve months later. **Results:** The results showed marginal bone loss in both groups with significant increase in ball and socket group. **Conclusions:** Within the limitations of this study bullard abutments had advantages over ball & socket in terms of marginal bone loss among all follow up periods.

Keywords: implant mandibular overdentures, Ball & socket attachment, bullard attachment, marginal bone loss.

Introduction

There are different modalities of treatment for mandibular edentulous ridge to overcome the problems of edentulism as implant supported overdenture which considered a common treatment modality for mandible which increase support, stability and restore functions with high rate of success. Approximately 60% of implant restorations in completely edentulous patients are restored with the implant overdenture concept due to a lot of advantages as functional, anatomic, economical, or esthetic considerations.

The 2002 McGill consensus conference concluded that within the evidence available at that time, conventional denture is no longer the most appropriately selected prosthodontic treatment for restoring the edentulous mandible⁽¹⁾

A two-implant overdenture is a cost-effective alternative to more complex implant prosthodontic procedures. It provides a strong return for the investment in treatment time and expense and is a treatment suited to the lower socioeconomic status of many edentulous patients. The clinical outcome of this treatment is significantly better than that achieved with conventional mandibular dentures, especially when patients are experiencing technical problems due to compromised prosthesis retention or stability.

To enhance retention and stability of denture, various overdenture attachments systems can be used for mandibular implant overdentures. The most popular attachment systems are telescopic, bar, ball, magnet types, and several individual mechanical attachments similar in size and function to the ball type.⁽²⁾

In recent years, ball attachments have gained popularity over bars, as they are easier to manage in limited prosthetic space, more economical, easily cleansable, and less technique sensitive. ⁽³⁾

The BULLARD (POLLER), a new resilient telescopic attachment employed in implant supported removable dentures was validated clinically in altogether 28 patients with ten upper and 22 lower dentures supported by 68 implants; 18 of these dentures were observed in a prospective trial for at least 36 months. Periimplant parameters were ascertained at time distances of six months each. ⁽⁴⁾

In a study made by Marco et al., in 2010 he found that the amount of bone loss in the new group "Bullard" resilient telescopic overdenture was lower when compared to the conventional telescopic overdenture group. ⁽⁵⁾

Since the late 1990s, cone beam computed tomography (CBCT) has become widely used to qualitatively and quantitatively evaluate alveolar bone conditions. Advantages of (CBCT) include three-dimensional visualization of anatomical structures, greater precision for diagnosis and analysis than with traditional two-dimensional radiography and reduced cost and lower radiation exposure compared with multidetector CT. ⁽⁶⁾

Over the last decade, improvements in (CBCT) technology have yielded much higher spatial resolutions in the maxillo-facial area. ⁽⁷⁾

CBCT is highly accurate in linear measurements. This was proven by a systematic review conducted recently to assess the accuracy of CBCT in the measurements of alveolar bone height and thickness. The results suggested that there is no significant difference between CBCT, and the gold standard references for the measurement of alveolar bone height and thickness. ⁽⁸⁾

This research will try to shed light on the value of using Bullard abutments and its effect on bone loss in comparison with ball and socket abutments.

Material and methods

Patient population

A randomized clinical trial study used to evaluate the marginal bone loss between two independent groups; Ball & socket and Bullard abutments mandibular overdentures with a parallel design, an equivalence frame, and an allocation ratio 1:1.

Surgical and prosthodontic procedures

In this randomized controlled clinical trial twenty completely edentulous patients were included, for whom maxillary and mandibular dentures were constructed. They were selected from the Outpatient Clinic of the Prosthodontic Department, Faculty of Dentistry, Minia University.

All patients whom fulfilled the eligibility criteria were included consecutively (consecutive sampling) till twelve participants were collected

Criteria for their selections were as follows; 1) Completely edentulous patients with a period of edentulism not less than one year. Their ridges should be covered by firm healthy mucosa. 2) Patients with sufficient inter-foraminal bone that allows for the placement of two implants in the canine regions, 3.5 mm in width and 10 mm in length. This was ensured by cone beam computed tomographic scans (CBCT) of the patients' jaws, while wearing customized radiographic templates. These templates were duplicates of their finished mandibular dentures and were supplied with radiographic markers. 3) Patients free of systemic and localized diseases that might contra-indicate implant placement. 4) Patients with inter arch distance ≥ 12 mm, measured from the incisal edge of the putty index of the diagnostic set up till the crest of the ridge on the patient's cast. This space is essential for both attachment groups.

All patients signed an informed written consent after being informed about the nature of the trial. The selected patients were then randomly divided into two parallel groups with an allocation ratio 1:1.

A comparison between implant retained Mandibular overdenture and socket abutments

The surgical stent was placed intra-orally to make the proposed implant site using a pinpoint drill. The osteotomy site was created using a reduction hand piece (1:16) at a speed of 1200 rpm on a physio-dispenser with adequate flow of sterile saline solution.

After initiating the drilling of implant bed using the pilot drill, two subsequent drills were used to widen the implant bed with help of the surgical guide then it removed and final drill was used to ensure the proposed diameter of 3.5 mm and a depth of 10 mm. Implant was initially threaded manually, then it was continued using a ratchet with insertion torque of 45 Ncm until the top of implant flushed with the bone surface. Postoperative medications were prescribed to the patients to avoid infection to implant sites.

Prosthetic phase:

For group I (Bullard attachment)

The bullard attachment housing was snapped on the implant through direct pick-up procedure following the manufacturer's instructions. The implants position in the fitting surface of lower denture to which the silicon (Retention. Sil 600) is applied was prepared to have a round shape. The prepared cavity allows a minimum wall thickness of 1 mm of silicon. Then a sufficient thick coat of bonding agent (Multisil Primer) is applied to the prepared surface and left to dry at air for 3 minutes. Then a thin coat of silicone was applied to the bullard abutment. The cavity was filled with (two thirds) of silicone conditioned in the denture quickly and the denture inserted immediately into the mouth. Patient was instructed to close in centric relation during the cross-linking phase of the silicone until full setting after 1.25 minute.

For group II (Ball and Socket)

The pick-up procedure started by placement of metal housing over the ball abutments. The areas of the fitting surface of the mandibular denture opposite to the implants was inspected and marked. Sufficient relief in the fitting surface or even perforation until there was enough space for the metal housing of ball

attachment and until the denture was properly seated. The metal housings with the nylon caps were attached to the ball attachments then a chair side hard relining material (Cold cure resin) were used for direct pick-up of the metal housing through the perforated area. Then overdenture was inserted into the patient's mouth till completely seated. The patient was instructed to close in the centric occluding relation with gentle biting force until complete polymerization of the materials.

Finally, Overdentures of both groups were removed from the patient's mouth, and excess material were removed, and any roughness or irregularities were smoothed, finished, polished, and delivered to the patient.

Outcome assessment

For each patient in both groups marginal bone loss clinically were assessed at time of denture delivery, then six and twelve months later. It was done by pressure sensitive periodontal

The significance level was set at $P \leq 0.05$. Statistical analysis was performed with IBM® SPSS® Statistics Version 20 for Windows.

Results

The mean and standard deviation values were calculated for each group. Data were explored for normality using Kolmogorov-Smirnov and Shapiro-Wilk tests. Repeated measure ANOVA was used to compare between more than two groups in related samples. Paired sample t-test was used to compare between two groups in related samples. Independent sample t-test was used to compare between two groups in non-related samples. Two-way ANOVA was used to test the interaction between different variables.

i) Effect of time:

A) Ball and socket:

There was a statistically significant difference between (T0-T1), (T1-T2) and (T0-T2) intervals where ($p < 0.001$). A statistically significant difference was found between (T0-T1) both of (T1-T2) and (T0-T2) intervals where ($p < 0.001$). No statistically significant difference was

found between (T1-T2) and (T0-T2) intervals where ($p=1$) as shown in Figure (3) and Table (1)

B) Bullard:

There was a statistically significant difference between (T0-T1), (T1-T2) and (T0-T2) intervals where ($p<0.001$). A statistically significant difference was found between (T0-T1) and both of (T1-T2) and (T0-T2) intervals where ($p=0.039$) and ($p<0.001$). Also, a statistically significant difference was found between (T1-T2) and (T0-T2) intervals where ($p<0.001$) as in figure (3)

ii) Effect of groups:

a) T0-T1:

There was a statistically significant difference between (Ball and socket) and (Bullard) groups where ($p<0.001$).

b) T1-T2:

There was a statistically significant difference between (Ball and socket) and (Bullard) groups where ($p<0.001$).

c) T0-T2:

There was a statistically significant difference between (Ball and socket) and (Bullard) groups where ($p<0.001$).

iii) Two-way ANOVA:

Data in the table (2) shows the results of Two-way ANOVA analysis for the interaction of different variables. The results showed that different groups had a statistically significant effect. Also, time had a statistically significant effect. The interaction between the two variables also had a statistically significant effect.

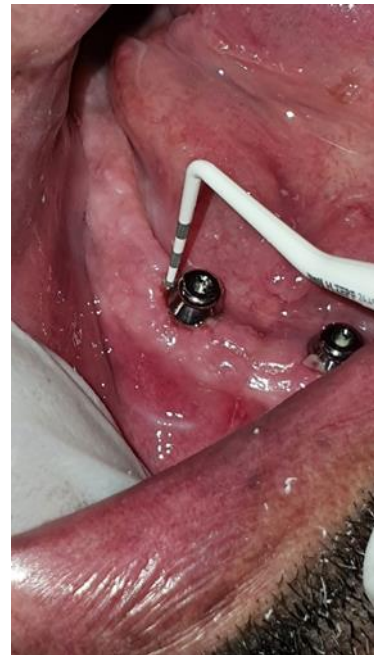
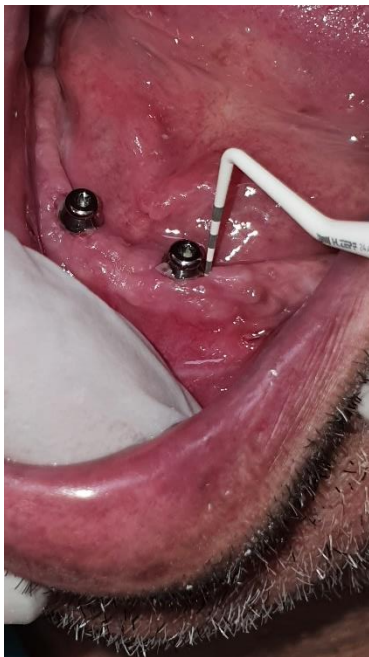
Figure 1: Measurement of marginal bone loss distally

Figure 2: Measurement of marginal bone loss mesially

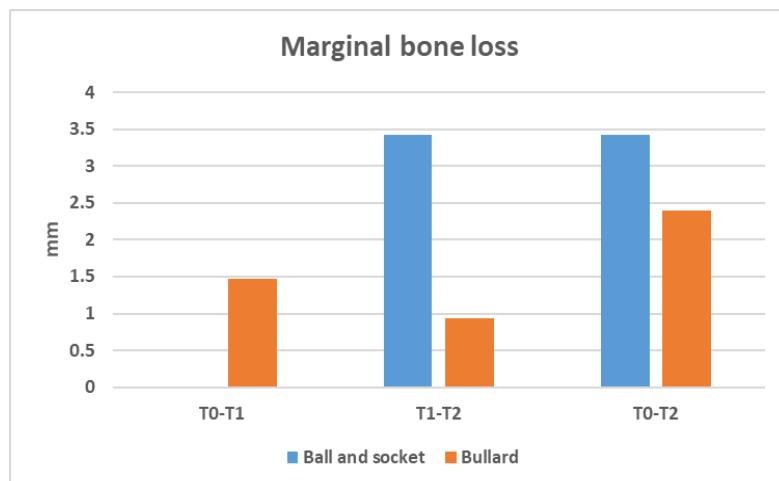


Figure 3: Bar chart showing marginal bone loss in different follow up intervals

Table (1): The mean, standard deviation (SD) values of marginal bone loss of different groups.

Variables	Marginal bone loss						p-value
	T0-T1		T1-T2		T0-T2		
	Mean	SD	Mean	SD	Mean	SD	
Ball and socket	0.00	0.00	3.42	0.15	3.42	0.15	<0.001*
Bullard	1.47	0.41	0.93	0.09	2.40	0.35	<0.001*
p-value	<0.001*		<0.001*		<0.001*		

*; significant (p<0.05)

Table 2: Results of Two-way ANOVA for the effect of different variables.

Source	Type III Sum of Squares	df	Mean Square	F	Sig.
Corrected Model	57.727	5	11.545	201.771	<.001
Intercept	135.956	1	135.956	2376.015	<.001
Groups	4.162	1	4.162	72.73	<.001
Time	29.523	2	14.761	257.974	<.001
Groups * Time	24.043	2	12.021	210.089	<.001
Error	1.717	30	0.057		
Total	195.399	36			
Corrected Total	59.443	35			

df: degrees of freedom = (n-1), * Significant at P ≤ 0.05

Discussion

Patients with healthy well-formed residual ridges were selected to provide adequate and stable tissue support during the study

periods. It was reported that patients with flabbiness and easily displaceable tissues allows excessive lateral displacement of the prosthesis. ⁽⁹⁾

All patients included in the study had sufficient interarch space to allow adequate arrangement of artificial teeth over ball and socket attachments or bullard attachments and to provide adequate bulk of acrylic resin above the attachments to resist fracture.

The interforaminal area of the mandible was selected for implant placement due to absence of vital structures that may be injured during implant insertion. It also has adequate bone height, quality, and favorable bone density.⁽¹⁰⁾

A surgical guide was used, to facilitate initial working at the area of the prospective implant site. Moreover, it was used to help in detection of the location of the implants in the second stage surgery.⁽¹¹⁾

All factors regarding implant selection and surgical procedures were also carefully considered to assure standardization of the results of the study. Therefore, the implants used for both groups were of the same design, length, and diameter (3.5 mm x 10 mm) to standardize the results of the study regarding the rate of osseointegration, as different implant dimensions lead to different surface area contacting the supporting bone that may influence the amount of load transmitted to the supporting bone which may be reflected on the end results.⁽¹²⁾

The direct pick up was performed in this study as it simple, economic, quick, and allow patient to retain prosthesis. The retentive element was attached to the fitting surface of the mandibular overdenture using the direct pick-up technique to assure proper positioning of the cap relative to the supporting ball, and to avoid possible distortion of the cap during heat curing of acrylic resin if they had been fixed to denture before processing (as in the indirect technique) also it assures passive load environment of the attachment.⁽¹³⁻¹⁴⁾ bullard abutments used only with the retention Sil 600 which is also a direct pick-up procedure. On the other hand, Retention Sil 600 silicone bases housing was recently introduced in prosthetic field to overcome

the prosthetics complication of conventional studs abutment systems, The purpose is to decrease visit time and number of follow up visits and allow easily insertion and removal of the denture especially with poor manual dexterity geriatric patients as well as cases of immediate loading to ensure minimal stress transfer to implants.

The application of retention Sil 600 with Bullard abutments is very simple and time saving (in chair side technique and not need great space in the fitting surface of the denture. Also, to decrease the liability of denture fracture and the pink colour of the material improve esthetic.⁽¹⁵⁻¹⁶⁾

Comparing the marginal bone loss among the different follow up periods revealed statistically significant bone changes of both groups. This has been supported by Laurito et al., 2012 who stated that in mandibular implant overdentures bone changes are significant during the first year of implant insertion.⁽¹⁷⁾

In bullard abutments, at 6 and 12 months there was a significant decrease of the amount of bone loss. this can be due to silicone used for retention which gives resiliency and acted as a shock absorber, so a physiologic occlusal force was falling on the implant and bone; leading to bone remodelling and increasing the quantity of bone surrounding the implant and close results were obtained by Marco et al., 2010 who recorded bone loss around Bullard abutments 1.35 mm after 6 months which were matching this study reading of 1.47 mm change between (T0-T1).⁽⁵⁾

Conclusions

Within the limitations of this study bullard abutments had advantages over ball & socket in terms of marginal bone loss among all follow up periods.

References

1. Feine, J. S., Carlsson, G. E., Awad, M. A., Chehade, A., Duncan, W. J., Gizani, S., & Wismeijer, D. The McGill Consensus Statement on Overdentures. Montreal, Quebec, Canada. May 24-25, 2002. The Inter-

- national journal of prosthodontics, 2002; 15(4), 413-414.
2. Raghoobar, GM, Meijer, HJ, Slot, W., James, JR, Slater, H., & Vissink, A. Systematic review article on implant-borne overdentures in the edentulous upper jaw compared to the lower jaw: How many implants?. *EJOI*, 2014; 7 (2), 349.
 3. Branchi, R., Vangi, D., Virga, A., Guertin, G., & Fazi, G. Resistance to wear of four matrices with ball attachments for implant overdentures: a fatigue study. *Journal of Prosthodontics: Implant, Esthetic and Reconstructive Dentistry*, 2010;19(8),614-619
 4. Niedermeier, W. 3-year clinical trial of the Bollard coping. *J Dentl Implantol*, 2003;19, 99-106.
 5. Marco Fouad Khalil: Effect of new design (Bullard) versus conventional telescopic crown on bone level (radiographically) of implant-retained mandibular overdenture 2015 Cairo University Thesis.
 6. González-García, R., & Monje, F. The reliability of cone-beam computed tomography to assess bone density at dental implant recipient sites: a histomorphometric analysis by micro-CT. *Clinical oral implants research*, 2013;24(8), 871-879.
 7. Van Dessel, J., Nicolielo, L. F., Huang, Y., Slagmolen, P., Politis, C., Lambrichts, I., & Jacobs, R. Quantification of bone quality using different cone beam computed tomography devices: Accuracy assessment for edentulous human mandibles. *Eur J Oral Implantol*, 2016;9(4), 411-424.
 8. Li, Y., Deng, S., Mei, L., Li, J., Qi, M., Su, S., & Zheng, W. Accuracy of alveolar bone height and thickness measurements in cone-beam computed tomography: a systematic review and meta-analysis. *Oral surgery, oral medicine, oral pathology and oral radiology*, 2019;128(6), 667-679.
 9. Heckmann SM, Linke JJ, Graef F, Foitzik Ch, Wichmann MG, Weber HP. Stress and inflammation as a detrimental combination for peri-implant bone loss. *J Dent Res*. 2006; 85(8):711-6.doi:10.1177/ 154405910608500805.PMID: 16861287.
 10. J. T. Lambrecht and Y. Hodel. "Long-term results of immediately loaded interforaminal implants.", *Quintessence Int.*, 2007;38(2):111–119
 11. Greenstein G., The relationship between biologic concepts and fabrication of surgical guides for dental implant placement,. *Compend Contin. Educ. Dent*, 2001; 196–203.
 12. F. R. Verri, E. P. Pellizzer, E. P. Rocha, and J. A. Pereira. "Influence of length and diameter of implants associated with distal extension removable partial dentures.", *Implant Dent.*, 2007;16:270–280.
 13. Taddei, M. Metz, E. Waltman, and O. Etienne. "Direct procedure for connecting a mandibular implant-retained overdenture with ball attachments.", *J. Prosthet. Dent.*, 2004; 92(4): 403–404.
 14. N. B. Gittleman and S. Sayek. "A practical and predictable clinical technique to pick up stud attachments for implant-retained overdentures.", *Pract. Proced. Aesthet. Dent.*, 2006;18 (10): 648- 650.
 15. Andreiotelli M, Att W, Strub JR. Prosthodontic complications with implant overdentures: a systematic literature review. *Int J Prosthodont*. 2010;23:195-3.
 16. Doaa A. Rostom; Nora M. Sheta. "Evaluation of the Retention of Two Different Retention Mechanisms (Nylon Caps and Retention Sil) in Locators Retained Implant Mandibular Over-Denture. A Randomized Clinical Trial (Rct)". *Al-Azhar Dental Journal for Girls*, 2021;8(1): 65-70.
 17. Laurito, Domenica, et al. "Tissue-supported dental implant prosthesis (overdenture): the search for the ideal protocol. A literature review." *Annali di stomatologia* 2012;3:1-2.