

## POSSIBLE MULTI-ORGAN TOXICITY IN RATS AFTER CHRONIC ORAL ADMINISTRATION OF TITANIUM DIOXIDE: BIOCHEMICAL AND HISTOPATHOLOGICAL STUDY

Eman S. Shaltout<sup>1</sup>, Rania M.A Makboul<sup>2</sup>, Nora Z. Abdellah<sup>1\*</sup>, Noha E. Ebrahim<sup>1</sup>  
Department of Forensic Medicine and Clinical Toxicology, Faculty of Medicine, Assiut University, Egypt<sup>1</sup>  
Department of Pathology, Faculty of Medicine, Assiut University, Egypt<sup>2</sup>

\*Corresponding author: Nora Z. Abdellah. E-mail: [nora\\_z@aun.edu.eg](mailto:nora_z@aun.edu.eg)

Submit Date 17-06-2021

Revise Date 31-08-2021

Accept Date 02-09-2021

### ABSTRACT

**Introduction:** Titanium dioxide (TiO<sub>2</sub>) is used abundantly as a white pigment with many applications, food coloring agents, additives, tooth whitening paste, pharmaceutical preparations, painting materials, and sunscreen creams. **Objectives:** The present study aimed to explore the possible toxicological effects of orally administered TiO<sub>2</sub>. **Methodology:** Twenty male albino rats were given food-grade TiO<sub>2</sub> in a dose of 20 mg/kg BW via oral gavage at 1 mL daily volume for 120 consecutive days. 20 male rats were used as a control group. Liver enzymes (AST, ALT, and ALP), renal function (urea and creatinine), creatine kinase activity (CK-MB isoenzyme), and serum levels of troponin were measured at the end of the study for each rat. Histopathological analysis of cardiac, hepatic, renal, and gastrointestinal tissue sections was also performed for both groups. **Results:** Increased CK-MB, cardiac Troponin, ALT, ALP, and urea serum levels in TiO<sub>2</sub> treated groups were recorded. Histopathological examination showed focal fibrosis of cardiac tissue. Hepatic sections showed inflammation and fat deposits. Gastrointestinal wall inflammations with blunting of the villi all over the small intestine, active inflammation of the colon and kidney tissues in the renal pelvis were found. **Conclusion:** Prolonged daily oral administration of food-grade TiO<sub>2</sub> can induce cardiovascular, hepatic, intestinal, and renal adverse effects.

**Keywords:** Titanium dioxide, Organ toxicity, Food Additives.

### BACKGROUND

Since 1916, massive consumption of titanium dioxide (TiO<sub>2</sub>), similarly referred to in the European Union as E 171, has been recorded (Jovanović, 2015). Since they have a nanoscale, they have been introduced into many commercial food industries. The upper limit intake of TiO<sub>2</sub> announced by the U.S. government is 1% by weight in food products (Musial et al., 2020). The average adult intake of E171 is estimated to be from 0.2 to 2 mg per kilogram body weight (Jovanović, 2015), while children ingest approximately 32.4 mg/kg. The high exposure level in children is a result of Titanium dioxide being the main component of candy and sweets (Weir et al., 2012). In general, individuals

take E171 orally as a white color added to many industrial food items (gums, candies, dairy products, kinds of toothpaste, and processed foods). Thus, resulting in an enormous intake of E171 (Chazelas et al., 2020).

We are exposed to many environmental and engineered titanium dioxide nanoparticles (NPs) every day by inhalation, and ingestion. Its toxicity has been widely researched and investigated for possible threats to human health (Baranowska-wójcik et al., 2020). Studies have reported that the gastrointestinal tract is constantly exposed to TiO<sub>2</sub> in the diet, studies have shown that TiO<sub>2</sub> can settle in various tissue like liver, kidney, spleen, lung, heart, and brain (Jia et al., 2017).

Most studies have shown toxicity of TiO<sub>2</sub> NPs after acute and chronic administration for up to 90 days (Shi et al., 2013). Yet, few studies have explored the possible toxicological effects on the health effects of orally administered food additive TiO<sub>2</sub> (E171) after daily regular exposure.

To obtain a comprehensive awareness of whether oral consumption of food-grade TiO<sub>2</sub> in experimental studies can cause harmful effects at human-relevant concentrations, the present research was therefore designed to administrate rats E171 orally daily for 120 days in the highest dose prescribed for rats.

Since most of the animals dosed with high levels of TiO<sub>2</sub> NPs reported adverse effects in the liver, heart, kidney, and intestines, we focused on these organs in terms of morphological, biochemical, and structural changes.

## **METHODS**

### **I. Animals and experimental design**

In the 200-230 gm weight range, forty adult male albino rats aged three weeks old were used. The animals were gathered, housed in special cages and maintained in regular laboratory conditions, and fed a standard balanced diet and water ad libitum. Rats were randomized into treated and control groups (20 male rats for each group).

In ultra-pure water, titanium dioxide was dispersed and sonicated for 15 minutes. The suspension was vortexed daily to achieve a homogenized suspension. The intragastric doses were chosen for children based on oral exposure to TiO<sub>2</sub>. It was calculated that the average daily dose was around 1-2 mg of TiO<sub>2</sub> per kilogram of boy weight. The daily oral dose of TiO<sub>2</sub> NPs was estimated at 0.5 mg/kg since about 36 percent of food-grade TiO<sub>2</sub> are in the nano-size (Weir et al., 2012). In this analysis, we used a 100-fold safety factor when

measuring the exposure dose to take account of inter-species observation. Thus, 20 mg/kg BW was chosen to represent the highest dose prescribed in rats, 40 times the dose of the postulated exposure amongst children.

TiO<sub>2</sub> suspension (20 mg/kg BW) was given to rats through oral gavage at 1 mL daily volume for 120 days. Death rates have been reported and documented constantly for up to 120 days for the full period of exposure. Every week, the bodyweight of rats was measured. All Animals were weighed, anesthetized, and sacrificed after 120 days. From the retro-orbital venous plexus sample, blood samples were obtained. The serum was extracted for 10 minutes by vertexing blood at 3000 rpm.

### **II. Chemicals**

A commercial food-grade E171 TiO<sub>2</sub> C.I. 77891 (99% purity) produced by Kamena of Egypt was purchased from an Industrial region distributor. Biochemical Assays

#### ▪ Liver enzymes

Aspartate Aminotransferase (AST), Alanine Aminotransferase (ALT), and alkaline phosphatase (ALP) liver enzymes assay kits were purchased from Spectrum-Diagnostics - Colorimetric kit, made in Germany. According to the methods of Young (1958) , Belfield and Ellis (1970).

▪ Cardiac muscle creatine-kinase and Troponin.

The activity of the creatine kinase cardiac MB isoenzyme (CK-MB) and serum levels of troponin was measured using a commercialized CK-MB Liquiform kit (Labtest, Brazil) following the manufacturer's instructions (Medeiros et al., 2009 and Silverio et al, 2012).

#### ▪ kidney function tests.

Urea and creatinine were measured using kits of German Hitachi (Hitachi Automatic Analyzer, Roche).

**Table (1):** Body weight and biochemical assay results of rats after 120 days of TiO<sub>2</sub> intake

	<b>Control group (Mean ±SD)</b>	<b>Experimental group Mean ±SD</b>	<b>Significance</b>
<b>Body weight</b>	225.2±5.27	198.8±10.59	0.328
<b>CK-MB (U/L)</b>	150.50± 25.008	423.60± 190.365	0.006**
<b>Troponin</b>	53.20± 10.727	194.10± 193.204	0.001***
<b>AST (U/L)</b>	98.96±6.34	109.35±14.75	0.102
<b>ALT(U/L)</b>	31.67± 2.35	41.56±5.15	0.04*
<b>ALP (U/L)</b>	112.62± 6.5	118.01±12.6	0.006**
<b>Urea (mg/dl)</b>	22.43±3.766	25.56±1.991	0.048*
<b>Creatinine (mg/dl)</b>	0.707±0.192	0.874±0.105	0.159

Significant difference compared to the control group (\*p< 0.05, \*\*p< 0.01, p< 0.001). CK-MB: Creatine kinase-MB, AST: Aspartate Aminotransferase ALT: Alanine Aminotransferase ALP: Alkaline Phosphatase

### III. Histopathological Examination

Histopathological preparation of tissue sections was performed using standard techniques. Paraffin blocks of tissues were prepared after fixation in 10% paraformaldehyde solution. Slices of 5mm thickness were cut and stained with hematoxylin-eosin (HE). Masson trichrome stain was used to demonstrate fibrosis.

### IV. Statistics

Analysis was done using SPSS version 16.0. Data were expressed as means ± SD. The independent sample t-test was used to compare the experimental group and the control group. A p-value less than 0.05 was statistically significant.

#### Ethical considerations:

The research experiment was conducted after approval of the ethics committee according to the Guidelines of the National Institute of Health for Animal Care followed (ILAR, 2011).

## **RESULTS**

### Mortality and body weight:

Food-grade TiO<sub>2</sub> showed no lethal effect on rats in concentration 20 mg. The mean weight of rats treated with TiO<sub>2</sub> showed no statistically significant difference in companion to control group. Table (1)

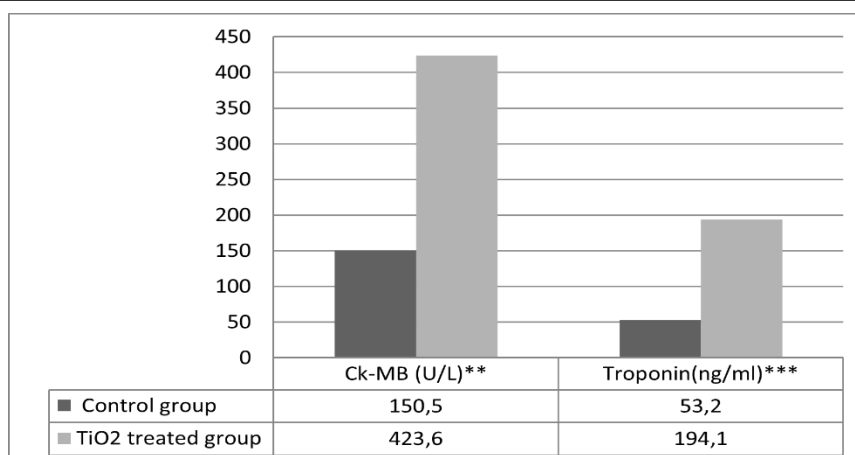
Biochemical Tests: As shown in Table (1).

### Assay of cardiac function

As shown in Table (1), significant changes in cardiac parameters in the TiO<sub>2</sub> treated group were recorded compared to the control group, increased serum activities of CK-MB and cardiac Troponin in the TiO<sub>2</sub> treated group was observed (Fig.1).

### Assay of liver function

Alanine Aminotransferase and alkaline phosphatase serum levels were significantly higher in the treated group when compared to the control group (P <0.05, P< 0.001) respectively (Table 1, fig.2)



**Figure (1):** Cardiac parameters of the control and TiO<sub>2</sub> treated groups. Values were expressed as mean  $\pm$  SD for 10 rats. \* P <0.05, \*\* P <0.001, \*\*\*P <0.0001. CK-MB: Creatine kinase-MB

#### Assay of Renal function

Urea level was significantly higher in TiO<sub>2</sub> treated group compared to the control group (P <0.05), while creatine level did not show any significant difference between the two groups. (Table 1, fig.3)

#### Histopathological changes

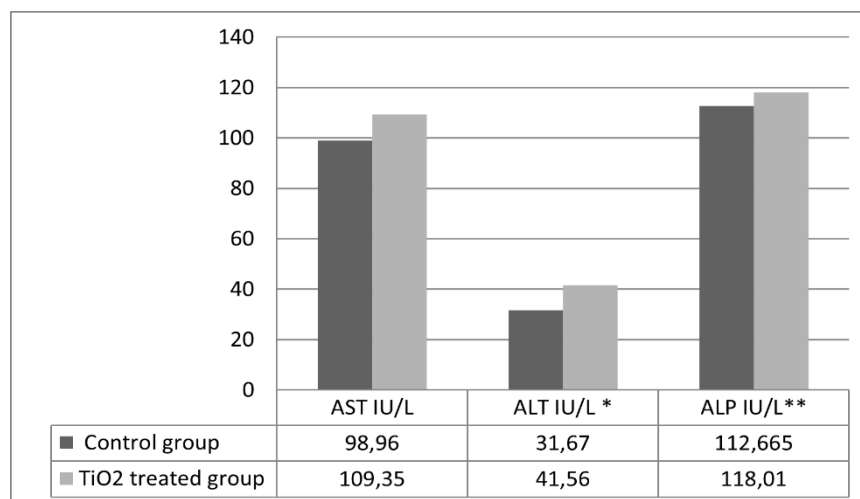
##### Cardiac tissue

Histopathological examination of cardiac tissue sections demonstrated by Masson's trichrome stain revealed mild to moderate focal fibrosis, congestion of

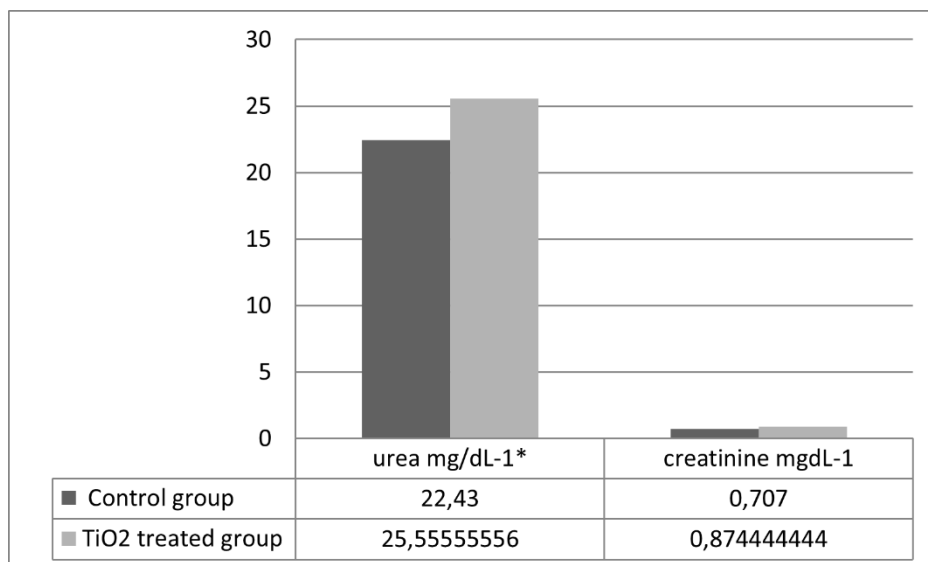
blood vessels, and areas of hemorrhage were also seen in the group treated with food-grade TiO<sub>2</sub> (as shown in Figs. 4D & F).

##### Hepatic tissues

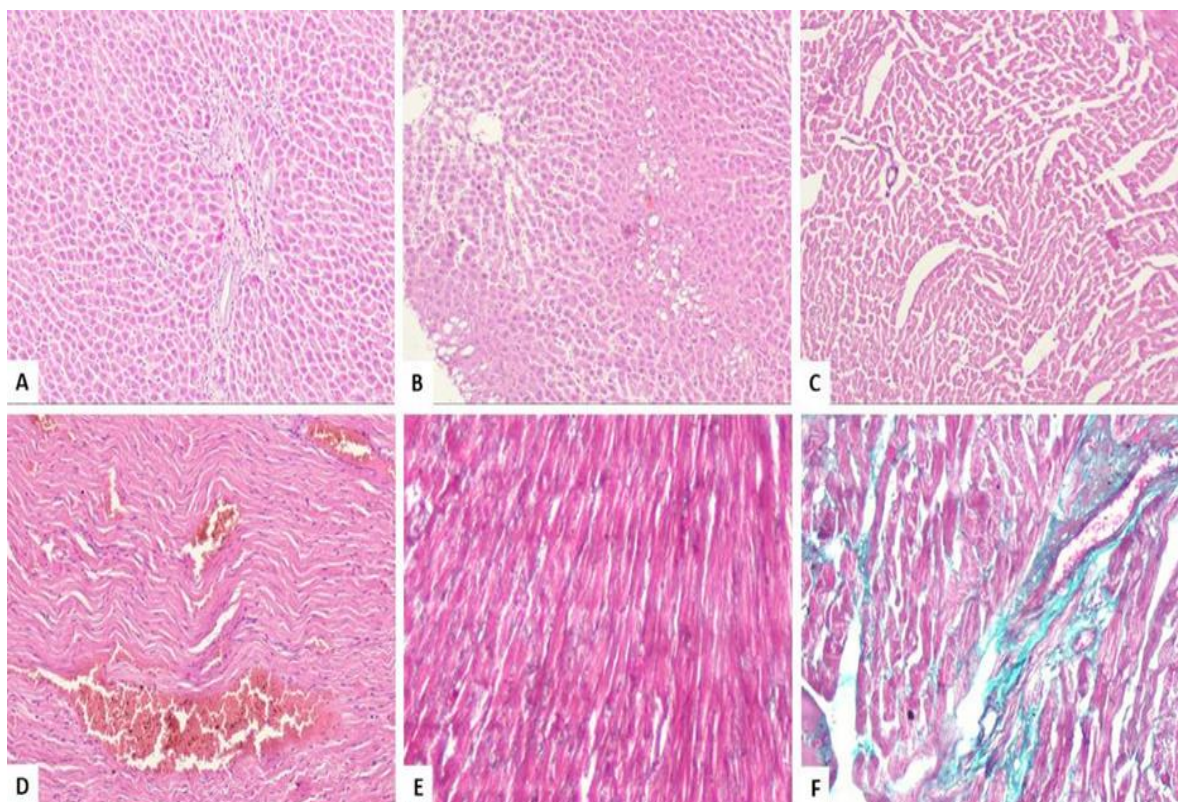
In food-grade, TiO<sub>2</sub> treated rats, liver sections showed congestion of sinuses and central vein. Mild inflammatory cell infiltration and hepatocytes steatosis were observed in zone 1 (Fig. 4B).



**Figure (2):** Liver function tests of the control and TiO<sub>2</sub> treated groups. Values were expressed as mean  $\pm$  SD for 10 rats. \* P <0.05, \*\* P <0.001, \*\*\*P <0.0001. AST: Aspartate Aminotransferase, ALT: Alanine Aminotransferase, ALP: Alkaline Phosphatase.



**Figure (3):** Renal function tests of the control and TiO<sub>2</sub> treated groups. Values were expressed as mean  $\pm$  SD for 10 rats. \* P <0.05, \*\* P <0.001, \*\*\*P <0.0001



**Figure (4):** A: Hematoxylin and eosin-stained section of liver of control group (100x). B: Hematoxylin and eosin-stained section of liver of group treated by TiO<sub>2</sub> showing congestion of central vein and sinusoids, also fatty change (steatosis) is evident in zone 1 (100x). C: Hematoxylin and eosin-stained section of the cardiac muscle of control group (100x). D: Hematoxylin and eosin-stained section of heart of treated group by TiO<sub>2</sub> showing congestion and hemorrhage (100x). E: Masson trichrome stained section of the cardiac muscle of control group (200x). F: Masson trichrome stained section of by TiO<sub>2</sub> treated group's heart showing mild to moderate fibrosis between the cardiac muscles (200x).

### Gastrointestinal tissue

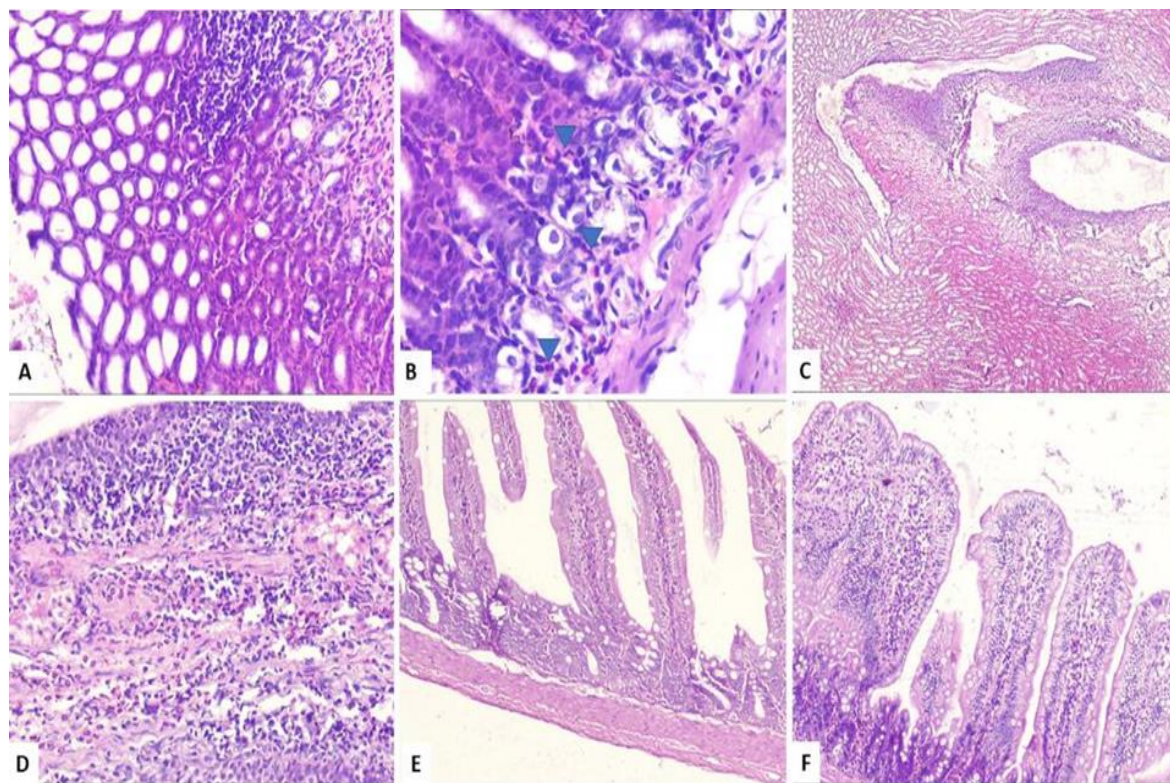
Sections from the small intestine of rats treated with food-grade TiO<sub>2</sub> showed mixed inflammation of the lamina propria and blunting of intestinal villi. Inflammation and blunting of villi were documented in the duodenum, jejunum, and ileum (Fig. 5F).

The colon of rats treated with food-grade TiO<sub>2</sub> showed mixed acute and

chronic inflammation of the lamina propria with mild activity (neutrophils attacking colonic glands) (Figs. 5 A&B).

### Renal tissue

Numerous acute with some chronic inflammatory cells infiltrating the renal pelvis was seen (pyelonephritis) (Figs. 5C&D).



**Figure (5):** A: Hematoxylin and eosin-stained section of colon of treated group by TiO<sub>2</sub> showing mixed acute and chronic inflammation of the mucosa (200x). B: Higher power of the previous slide showing neutrophils attacking the glands (arrowhead) (400x). C: Hematoxylin and eosin-stained section of kidney of treated group by TiO<sub>2</sub> showing mixed chronic and many acute inflammatory cells of renal pelvis (pyelonephritis) (40x). D: Higher power view of the previous picture showing plenty of neutrophilic infiltrate in the renal pelvis (200x). E: Hematoxylin and eosin-stained section of small intestine of control group showing normal intestinal villi (100x). F: Hematoxylin and eosin-stained section of small intestine of the treated group by TiO<sub>2</sub> showing mixed inflammation of the lamina propria causing blunting and broadening of intestinal villi (100x).

### DISCUSSION

Food grade titanium oxide is a commonly used food additive consumed by humans daily. TiO<sub>2</sub> nanoparticles influence different body systems, this effect differs according to the dose, duration, route of exposure, and the affected organs (Shabbir et al., 2021). In humans, the toxic effects of

TiO<sub>2</sub> nanoparticles are mainly long-term effects resulting from repeated exposure through different pathways (inhalation, ingestion, and dermal) or internal production from titanium prostheses (Skocaj et al., 2014). It is very hard to reproduce these prolonged exposures in animal models with a short lifespan (not

exceeding 2 years). The studies conducted on these nanoparticles use varying doses given once or for a relatively short duration (**Bahadar et al., 2016**).

In the current study, rats were exposed to TiO<sub>2</sub> NPs at 20 mg/kg BW for 120 days to observe the toxicological effects of TiO<sub>2</sub>. Given the fact that the oral route is more suitable when determining the dangers of food additives, we have therefore chosen to use this route of administration. Wang and coauthors (**2007**) have mentioned deposition of TiO<sub>2</sub> NPs in the liver, kidneys after oral administration. Furthermore, it has been shown that within 30 days of exposure, TiO<sub>2</sub> NPs can also harm the heart (**Chen et al., 2015**).

In the present study, no significant decrease in the means of body weight of rats treated with TiO<sub>2</sub>. Similarly, previous studies didn't find significant changes in the body weight of rats after oral administration of 5mg TiO<sub>2</sub> NPs/Kg BW (**Warheit et al., 2007**). Weight loss in mice given TiO<sub>2</sub> intragastric demonstrated by **Li et al., (2010)** at higher doses (125 and 250 mg/kg). Previous studies stated that TiO<sub>2</sub> nanoparticles hinder digestion and absorption of nutrients with subsequent deficiency of both macro and micronutrients in the body. They explained weight loss to the effect of TiO<sub>2</sub> NPs on the absorbent surface of the intestine with a decrease in the number of villi. TiO<sub>2</sub> particle absorption has also been reported to evoke inflammatory responses as TiO<sub>2</sub> nanoparticles induce in vitro inflammation (**Ruiz et al., 2017**). These effects have been suggested that may trigger or intensify intestinal inflammatory disorders (**Hummel et al., 2014**). In this study, histopathological examination of the intestine and colon showed blunting of the intestinal surface with a reduction in the number of villi with inflammation to both intestine & colon. TiO<sub>2</sub> was reported to alter the nutrient absorptive surface of the intestine with a marked effect on absorption and transport of important micronutrients as Fe, Zn fatty acids, with a reduction in microvilli (**Guo et**

**al. 2017**).

The present study showed that TiO<sub>2</sub> food-grade exerts toxic damage on myocardial tissues after daily administration for 120 days resulting in loss of myocardial cell membrane integrity and release of Cardiac enzymes to the blood Stream. The authors found a significant increase in the diagnostic Cardiac parameters CK-MB and cardiac Troponin protein in TiO<sub>2</sub> treated group compared to the control group, these results are consistent with the previous results of researchers who evaluated the toxic effect on the heart function after chronic oral intake of TiO<sub>2</sub> for 90 days and reported a significant elevation in Serum cardiac enzymes (**Chen et al., 2015**).

Swelling of mitochondrial cardiac cells was also reported in rats that received TiO<sub>2</sub> orally for 14 days (**Bu et al., 2010**). TiO<sub>2</sub> NPs trigger inflammatory response with increased inflammatory cytokines (TNF $\alpha$  and IL8), they play a major role in the mechanism of the injurious effect of TiO<sub>2</sub> NPs on the cardiovascular system (**Elsabahy and Wooley, 2013**).

As stated in the results of our research, food-grade TiO<sub>2</sub> caused a hepatic injury. This injury was demonstrated as inflammatory infiltration, fat deposition, and congestion. In addition to the increased levels of ALT and ALP. These results mean injury of hepatocytes and release of transaminases into the bloodstream. An elevated ALT blood level reflects the inflammatory condition of the hepatocytes while ALP reflects deteriorating function off the liver (**Giannini et al., 2005**). TiO<sub>2</sub> was reported to cause oxidative stress in hepatic cells and induce inflammatory process in the liver causing hepatocyte damage and release of intracellular enzymes such as ALT, AST, and ALP (**Jia et al., 2017**). In agreement with the results of this study, food-grade TiO<sub>2</sub> increases fat deposits in hepatocytes. Furthermore, TiO<sub>2</sub> induced congestion, enhanced leukocyte infiltration, and increased nuclear pyknosis percentages in liver cells (**Shirani et al.,**

2020). The hepatic and cardiac damage caused by TiO<sub>2</sub> in rats was assumed to be a consequent disturbance in energy and metabolism of amino acids (Shi et al., 2013).

Concerning the adverse sequelae of exposure to titanium dioxide nanoparticles on the kidney, this study assumes that food-grade TiO<sub>2</sub> has triggered pathological changes and inflammatory changes in the renal pelvis. The serum urea level was also substantially increased by particles in the treated group compared to the control group. It is believed that TiO<sub>2</sub> nanoparticles accumulate in kidney cells and cause nephrotoxicity in the form of inflammation in the glomerulus, furthermore, TiO<sub>2</sub> particles of 25 nm greatly enhanced the urea level of the serum as compared to the control (Wang et al., 2007). Although there are still limited studies documenting mechanisms of TiO<sub>2</sub> toxicity, some indicate that smaller particles produce a higher inflammatory response (Kobayashi et al., 2009).

### CONCLUSION

Globally, the use of the daily human intake of products containing TiO<sub>2</sub> is growing. The evaluation of E 171 delivered orally is a critical model of exposure to humans. The present results demonstrated significantly altered biochemical and histopathological changes. Those changes were demonstrated as altered normal gut mucosa, cardiac, hepatic, and renal tissues. In addition to elevation of ALT, ALP, CK-MB, cardiac troponin, and urea blood levels, that might lead in the future to many diseases and tumors. The mechanism is obscured.

### RECOMMENDATION

The study of nanotoxicity remains a field for potential research. There is demand for more research to demonstrate the effects of TiO<sub>2</sub> and other nanoparticles on organs and other blood factors. Additionally, it is necessary to perform more studies over various periods.

### REFERENCES:

- Bahadar, H. Maqbool, F., Niaz, K. and Abdollahi, M. (2016).** ‘Toxicity of nanoparticles and an overview of current experimental models’, *Iranian Biomedical Journal*, 20(1), pp. 1–11. doi: 10.7508/ibj.2016.01.001.
- Baranowska-wójcik, E., Szwajgier, D., Oleszczuk, P. and Winiarska-mieczan A. (2020).** Effects of Titanium Dioxide Nanoparticles Exposure on Human Health—a Review. *Biol Trace Elem Res.* 193: 118–129.
- Belfield, A. and Ellis, G.D. (1970).** A specific colorimetric 5'-nucleotidase assay utilizing the Berthelot reaction. *Clin Chem.*;16:396–401.
- Bu, Q., Yan, G., Deng, P., Peng, F., Lin, H., Xu, Y., et al. (2010).** NMR-based metabonomic study of the sub-acute toxicity of titanium dioxide nanoparticles in rats after oral administration. *Nanotechnology.* 26;21(12): 125105
- Chazelas, E., Deschasaux, M., Srour, B., Kesse-Guyot, E., Julia C., Alles, B., et al. (2020).** Food additives: distribution and co-occurrence in 126,000 food products of the French market. *Sci Rep.*10(1):1-15
- Chen, Z., Wang, Y., Zhuo, L., Chen, S., Zhao, L., Luan, X., et al. (2015).** ‘Effect of titanium dioxide nanoparticles on the cardiovascular system after oral administration’, *Toxicology Letters*, 239(2), pp. 123–130. doi: 10.1016/j.toxlet.2015.09.013.
- Elsabahy, M. and Wooley, K.L. (2013):** Cytokines as biomarkers of nanoparticle immunotoxicity. *Chem Soc Rev.* 2013 Jun 21;42(12):5552-5576.
- Giannini, E.G., Testa, R. and Savarino V., (2005):** Liver enzyme alteration: A guide for clinicians. *Cmaj.* 172 (3): 367–379.
- Guo, Z., Martucci, N.J., Moreno-Olivas, F., Tako, E. and Mahler, G.J. (2017):** Titanium dioxide nanoparticle



- ingestion alters nutrient absorption in an in vitro model of the small intestine. *NanoImpact.*;5:70-82.
- Hummel, T.Z., Kindermann, A., Stokkers, P.F., Benninga, M.A. and Ten Kate, F.J. (2014).** Exogenous pigment in peyer patches of children suspected of having IBD. *J Pediatr Gastroenterol Nutr.*58(4):477-480.
- Institute of Laboratory Animal Resources (ILAR) (2011).** Guide for the Care and Use of Laboratory Animals. 8th ed. National Academies Press, Washington, D.C., P.P. 41-103.
- Jia, X., Wang, S., Zhou, L. and Sun, L. (2017):** The Potential Liver, Brain, and Embryo Toxicity of Titanium Dioxide Nanoparticles on Mice. *Nanoscale Res Lett.* 12 (478):1-14.
- Jovanović, B. (2015).** Critical review of public health regulations of titanium dioxide, a human food additive. *Integrated environmental assessment and management*, 11(1): 10–20.
- Kobayashi, N., Naya, M., Endoh, S., Maru, J., Yamamoto, K. and Nakanishi, J. (2009):** Comparative pulmonary toxicity study of nano-TiO<sub>2</sub> particles of different sizes and agglomerations in rats: Different short- and long-term post-instillation results. *Toxicology.* 264(1-2):110-118
- Li, N., Ma, L., Wang, J., Zheng, L., Liu, J., Duan, Y., et al. (2010).** Interaction Between Nano-Anatase TiO<sub>2</sub> and Liver DNA from Mice In Vivo. *Nanoscale Res Lett.* 5(1):108-115.
- Medeiros, D.M., Jiang, Y., Klaahsen, D. and Lin, D. (2009).** Mitochondrial and sarcoplasmic protein changes in hearts from copper-deficient rats: up-regulation of PGC-1 $\alpha$  transcript and protein as a cause for mitochondrial biogenesis in copper deficiency. *J Nutr Biochem.* 20(10):823-830.
- Musial, J., Krakowiak, R., Mlynarczyk, D.T., Goslinski T. and Stanisz B.J. (2020).** Titanium dioxide nanoparticles in food and personal care products—what do we know about their safety? *Nanomaterials.* 10(6):1-23.
- Ruiz, P.A., Morón, B., Becker, H.M., Lang, S., Atrott, K., Spalinger, M.R., et al (2017).** Titanium dioxide nanoparticles exacerbate DSS-induced colitis: role of the NLRP3 inflammasome. *Gut.* 66(7):1216-1224.
- Silverio, J.C., Pereira, I.R., Cipitelli M.C., Vinagre, N.F., Rodrigues, M.M., Gazzinelli, R.T. and Lannes-Vieira, J. (2012).** CD8<sup>+</sup> T-cells expressing interferon gamma or perforin play antagonistic roles in heart injury in experimental trypanosoma cruzi-elicited cardiomyopathy. *PLOS Pathogen*, 8 (4): e1002645: 1-20.
- Shabbir, S., Kulyar, M.F., Bhutta, Z.A., Boruah, P. and Asif, M. (2021):** Toxicological Consequences of Titanium Dioxide Nanoparticles (TiO<sub>2</sub>NPs) and Their Jeopardy to Human Population. *Bionanoscience.*26:1-12.
- Shi, H., Magaye, R., Castranova, V. and Zhao, J. (2013).** Titanium dioxide nanoparticles: A review of current toxicological data. *Part Fibre Toxicol.*10(1):10-15
- Shirani, M., Khorsandi, L. and Alidadi, H. (2020):** Quercetin Effects on Hepatotoxicity Induced by Titanium Dioxide Nanoparticles in Rats. *Jundishapur J. Nat. Pharm. Prod.* 15 (3): 1–7.
- Skocaj, M., Filipic, M., Petkovic, J. and Novak, S. (2011):** Titanium dioxide in our everyday life; Is it safe? *Radiol Oncol.* 45(4):227-247.
- Wang, J., Zhou, G., Chen, C., Yu, H., Wang, T., Ma, Y., Jia, J. et al. (2007).** Acute toxicity and biodistribution of different sized titanium dioxide particles in mice after oral administration. *Toxicol Lett.*;168(2):176-185.
- Warheit, D.B., Hoke, R.A., Finlay, C., Donner, E.M., Reed, K.L. and Sayes, C.M. (2007).** Development of a base set of toxicity tests using ultrafine TiO<sub>2</sub> particles as a component of

---

nanoparticle risk management. *Toxicol Lett.* 171(3):99-110.

**Weir, A., Westerhoff, P., Fabricius, L., Hristovski, K. and Von Goetz, N. (2012).** Titanium dioxide nanoparticles in food and personal care products. *Environ Sci Technol.* 46(4):2242–2250.

**Young, I. (1958):** Serum 5-nucleotidase; characterization and evaluation in disease states. *Ann N Y Acad Sci.* 75(1):357-362.

## المخلص العربي

## السمية المحتملة على أعضاء متعددة في الجرذان بعد تناول المزمّن لثاني أكسيد التيتانيوم عن طريق الفم: دراسة بيوكيميائية وهستوباثولوجية

<sup>1</sup>، نها إسماعيل إبراهيم<sup>1</sup>، نوره زيدان عبداللاه<sup>2</sup> إيمان صلاح الدين شلتوت<sup>1</sup>، رانيا مقبول أحمد مقبول<sup>1</sup>، قسم الطب الشرعي و السموم الكلينيكية، كلية الطب البشري، جامعة اسيوط<sup>1</sup>  
قسم الباثولوجي، كلية الطب البشري، جامعة اسيوط<sup>2</sup>

**المقدمة:** يستخدم ثاني أكسيد التيتانيوم (TiO<sub>2</sub>) بكثرة كصبغة بيضاء في العديد من التطبيقات، كتلوين وإضافات الطعام، معجون تبييض الأسنان، المستحضرات الصيدلانية، مواد الطلاء، والكريمات الواقية من الشمس. **الأهداف:** هدفت الدراسة الحالية إلى استكشاف التأثيرات السمية المحتملة لثاني أكسيد التيتانيوم المتعاطي عن طريق الفم. **الطرق:** تم إعطاء ثاني أكسيد التيتانيوم لعشرين جرذاً من ذكور الجرذان بجرعة 20 مجم / كجم عن طريق الفم بحجم 1 مل يوميًا لمدة 120 يومًا متتاليًا. تم استخدام 20 من الجرذان كمجموعة ضابطة. في نهاية الدراسة تم قياس إنزيمات الكبد (AST، ALT، ALP)، وظائف الكلى (اليوريا والكرياتينين)، نشاط كيناز الكرياتين (CK-MB isoenzyme)، ومستوى التروبونين لكل جرذ. كما تم إجراء فحص هستوباثولوجي لأنسجة القلب والكبد والكلى والقناة الهضمية لكلا المجموعتين. **النتائج:** تم ملاحظة زيادة مستويات كيناز الكرياتين CK-MB، والتروبونين، وإنزيمات الكبد (ALT، ALP)، و اليوريا في الجرذان التي تلقت ثاني أكسيد التيتانيوم. أظهر فحص الأنسجة تليف بؤري لأنسجة القلب. أظهرت أنسجة الكبد التهابات ورواسب دهنية. تم العثور على التهابات بجدار القناة الهضمية مع انثلام الزغابات المعوية للأمعاء الدقيقة، والتهاب نشط في أنسجة القولون و الحوض الكلوي. **الخلاصة:** يمكن أن يؤدي تناول ثاني أكسيد التيتانيوم لفترات طويلة إلى تأثيرات ضارة على القلب والكبد والأمعاء والكلى.