

GEOMETRIC ROOT CHANGES FOLLOWING TWO DIFFERENT TECHNIQUES FOR IMMATURE PERMANENT INCISORS

Ahmed Ezat Dawoud ^{*ID} and Mohamed Omar Elboraey ^{**ID}

ABSTRACT

Aim: for evaluation and comparison of pulp revascularization and apexification in immature non-vital permanent incisors by CBCT.

Material and methods: 15 immature permanent incisors of children (7-9 years old) had irreversible pulpitis or necrotic pulp were selected and randomly divided into 2 groups; Group I: 7 teeth were treated with Pulp revascularization and group II: 7 teeth were treated with MTA apexification. Each tooth was completely isolated with a rubber dam then access opening was done. Irrigation of the pulp chamber with 2.5% NaOCl then sterile saline and water. The root canal was then dried with paper points, triple antibiotic paste (TAP) was administered, and it was removed two weeks later with saline irrigation. In group I (revascularization) bleeding enhancement was done and MTA material was performed over the formed blood clot while in group II (apexification) the whole root canal space was filled with MTA. Finally, pulp chamber was filled with GIC filling in both groups.

Conclusions: Both groups are resemble in all CBCT criteria except in dentin volume and root length in mesiodistal direction which significant in Revascularization group.

KEYWORDS: Apexification, Cone beam computed tomography, immature non-vital teeth, Mineral trioxide aggregate, Revascularization.

INTRODUCTION

Traumatic injury to young permanent anterior teeth outnumbers dental caries and periodontal disease ¹. Pulp tissue is irritated by a variety of germs,

trauma, dental procedures that generate thermal stimulation, and chemical agents^{2,3}. Irritation of pulp tissue alters the microcirculation of the pulp, which may result in pulp necrosis and root development

* Pediatric Dentistry, Oral Health and Preventive Dentistry Department, Faculty of Dentistry, Tanta University, Tanta, Egypt.

* Oral Medicine, Periodontology, Oral Diagnosis and Oral Radiology Department, Faculty of Dentistry, Tanta University, Tanta, Egypt.

arrest.⁴ The therapy of these teeth presents a significant challenge to the physician, since inappropriate treatment during trauma might exacerbate the problem, result in the development of periapical lesions, and result in the cessation of tooth growth.^{5,6}

There are several challenges associated with root canal treatment of non-vital immature teeth for example, the apical width of the canal is often greater than the coronal diameter, making debridement challenging. Additionally, the absence of an apical stop results in root canal filling material extrusion, rendering the seal of obturation extremely unachievable in all dimensions. Finally, due to the root canal's thin, weak walls' proclivity for fracture, surgical treatment is often not a viable option⁷⁻⁹.

Apexification is described as a technique used by the American Association of Endodontists (AAE) in 2003 to generate a calcified barrier in a root with an open apex and can be done by Calcium hydroxide or mineral trioxide aggregate (MTA) may be used to stimulate the creation of an apical calcified barrier and to create an artificial apical barrier respectively^{10,11}.

Revascularization is the process through which stem cells from the apical area of immature teeth. After passive decontamination, which eliminates some or all of the pulp tissue and or necrotic tissue, tissue ingrowth is guided into the root canal space¹². This is accomplished by filling the root canal space with blood clots derived from periapical tissues, which aid in the movement of stem cells inside the root canal area.¹³

Cone beam computed tomography (CBCT) is a widely utilized modality for radiographic examination of bone at the head and neck region, showing high accuracy and the provided programs with CBCT allow easy, rapid radiographic interpretation¹⁴. Recently CBCT was widely replace conventional computed tomography (CT) due to the newly high advances in image quality that become very close to CT images, lower exposure doses, rapid and easy exposure for the patient and easy images interpretation and planning thanks to many available interpretation software¹⁵⁻¹⁶.

Increasingly, three dimensions (3D) radiographic modalities can be used for extraction of accurate quantitative measures such as 3D volume measurement and reconstruction. Several programs can be used for 3D volume measurement using Digital Imaging and Communications in Medicine (DICOM) files from CBCT, CT, and MRI, which has become widely used in different dental research as a reliable, reproducible, and valid method for radiographic assessment.¹⁷⁻¹⁸

ITK-SNAP software is an easy-to-use, cost-effective, and dependable package for measuring radiographic volumes by importing DICOM files from various imaging modalities such as MRI, CT, CBCT, and ultrasonography. It has been validated for measuring nasopharyngeal volumes and the dimension of the bony defect in patients with cleft palate prior to alveolar bone grafting to avoid unnecessary donor site morbidity due to unnecessary excessive harvesting.¹⁹

MATERIALS AND METHODS:

Study design: This study employed a randomized controlled clinical trial design.

Study setting: The study was done in Pediatric Dentistry Department outpatient clinic, Faculty of Dentistry, Tanta University, Egypt.

Study sample:

The sample size was calculated using power analysis by Epi-Info software package created by world organization (WHO) and central for disease prevention and control (CDC) version 2007. The confidence limit was 95%, power of the study was 80%, case to control ratio was 1:1 and the sample size was found to be N=14 (7 in group 1 and 7 in group 2) with extra 4 teeth to avoid sample attrition. The children (7-9 years old) incisors teeth having irreversible pulpitis or necrotic immature permanent incisors. The youngsters were chosen from the Pediatric Dentistry Department's outpatient clinic, Faculty of Dentistry, Tanta University, Egypt. Teeth were examined clinically and radiographically using

standardized parallel cone technique* of periapical x-ray (XCP: extension cone paralling)** at the start of the study then randomly divided into two groups.

Patient's rights:

The Faculty of Dentistry's Research Ethics Committee granted approval for this investigation (REC). The goal of this study was described to patients, and informed consent was obtained from parents as well as their children over the age of eight, in compliance with the research ethics rules issued by Tanta University's Faculty of Dentistry's Research Ethics Committee.

Group assignment:

- **Group I:** "Study group" 7 teeth were treated with Pulp revascularization.
- **Group II:** "Positive control group" 7 teeth were treated with MTA apexification.

Inclusion criteria:

- Carious or fractured non vital or necrotic immature permanent incisors.
- Irreversible pulpitis (with or without apical periodontitis/abscess) even with previous intervention.
- Restorable tooth.
- Cooperative child.

Exclusion criteria¹³

- Simple carious lesions.
- Splited crown fracture.
- Children having any systemic diseases as cardiac and blood disorders or history of allergy to any of the antibiotics used in tri-mix.
- Disabled and special needs children.
- Severe luxation injury.

After history taken from the child and parents, clinical examination was done to evaluate traumatized or fractured incisors for presence or absence of the following parameters:

1. Pain or discomfort.
2. Tenderness to percussion
3. Mobility Score²⁰ 0 = normal mobility, 1 = slight mobility, 2=sever mobility.
4. Swelling and fistula.

Cone beam computed tomography limited field of view CBCT taken to measure the following criteria once at the start and the end of follow up period after 18 months:

1. Dentin volume.
 2. Pulp space volume.
 3. Root length (at mesiodistal direction).
 4. Root length (at buccolingual direction).
- Dentin and pulp space volume measurement:

Using ITK-SNAP*** software, both volumes were measured from fixed reference point to the most apical point of the root using the axial view depending on semi-automated option of self and isotropic voxel recognition of ITK-SNAP. Dentin and pulp space were identified separately using two different colored labels. Rechecking from coronal and sagittal view was done for dentin and pulp respectively.

Automatic calculation of the dentin and pulp space volume was done by the software.

- Root length measurement.

The mean of root length was measured twice, one at mesiodistal view and the other one at buccolingual view from the cemento-enamel junction (CEJ) to the most apical point of the root at mesial and distal line angles, also at buccal and lingual line angle respectively as the root lengths were not always with a uniform length.

* De Gotzen Varese Italy, 70 kVp.

** Dentsply Rinn, made in USA.

*** ITK-SNAP version 3.8.0, Supported by the U.S. National Institute of Biomedical Imaging and Bioengineering.

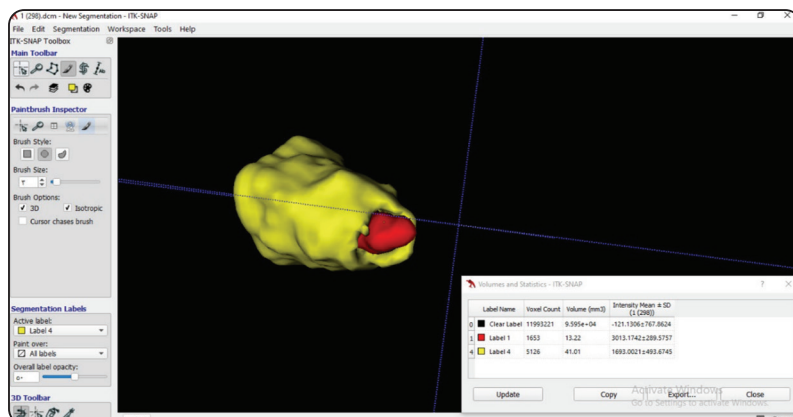


Fig. (1) Dentin and pulp space volume measurement and calculation using ITK-SNAP software

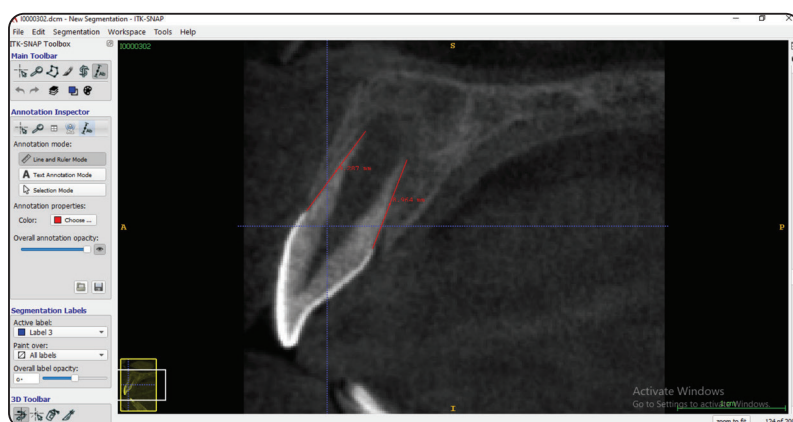

Fig. (2) Mean of root length measurement in buccolingual direction.

Treatment Procedures:

First appointment

- Local anesthesia was given using 2% Mepivacaine* with 1:20,000 Levonordefrin local vasoconstrictor agent.

The tooth was isolated with a rubber dam.

A cavity for access was made using an Endo-Z bur held in a high-speed hand piece sprayed with sufficient amounts of water.

- Initial debridement of coronal 1/3 of the root canal was done using hand stainless steel H-files²¹.

* Alexandria Co. for pharmaceutical & chemical industries, Alex., Egypt.

- The pulp chamber and root canal were freely irrigated with a 10ml. solution of 2.5 percent sodium hypochlorite (NaOCl) for 2-5 minutes²² followed by sterile saline. Throughout irrigation, the needle should be injected into the root canal to a point 2 mm shorter than the apical foramen. The root canal was then dried with the use of paper points.
- Modified triple antibiotic paste "TAP" was used as canal disinfectant (Mixture of equal proportion of three antibiotics: (250mg Metronidazole, 250mg ciprofloxacin and 250mg Amoxicillin) bonded with propylene glycol and Macrogol to form a creamy paste then inserted into the pulp chamber and coronal (third or half) of root canal with a hand K- file and cotton pellet. The ac-

cess cavity's walls were cleansed with a sterile cotton pellet and then filled with Cavit temporary filling paste lifting for 2 weeks.

Second appointment

The patient was scheduled for a follow-up appointment two weeks later. Prior to advancing to the next step of treatment, the tooth remained asymptomatic throughout the postoperative period and the temporary filling remained intact. If clinical indications or symptoms continue, the first appointment's procedures should be repeated.

When proceeding with the second appointment, the tooth was anaesthetized using anesthetic solution without vasoconstrictor²².

- After that if the tooth is asymptomatic, a rubber dam isolation of the tooth was done and gentle removing of the cavit temporary restoration. The TAP paste was washed out by copious irrigation of root canal with 2.5% sodium hypochlorite²³, rinsing the canal with sterile saline and water. Then root canal was dried using sterile paper point size 80.

- In this group apical bleeding was induced by inserting a disinfected #15 K-file into the apical tissues 2 mm beyond the apical foramen to begin root canal bleeding . Blood level must be at least 2-3mm below the cement-enamel junction².
- Bleeding should be limited to a location roughly 2-3 mm apical to the CEJ. This is performed by exerting pressure to the intra-canal with a sterile saline-soaked cotton pellet until a clot forms. The estimated mean time required to form a stable blood clot is 5-10 minutes ²⁴. To ensure the clot's stability, gently contact it with the reverse end of a big sterile paper point.
- White MTA* was mixed in powder-distilled water ratio of 3:1 according to the manufacturer's instructions. MTA paste was placed using Amalgam carrier on the formed blood clot below the CEJ to form hermetic seal then wet cotton pellet was placed on MTA paste until the initial setting occurred¹⁷.

Group II: MTA Apexification: Fig.3

- In this group MTA paste was carried inside the canal to reach 2mm. shorter than the root end²⁵ using the applicator or hand K-file instrument covered with cotton for condensation.

Group I: Pulp revascularization: Fig.3

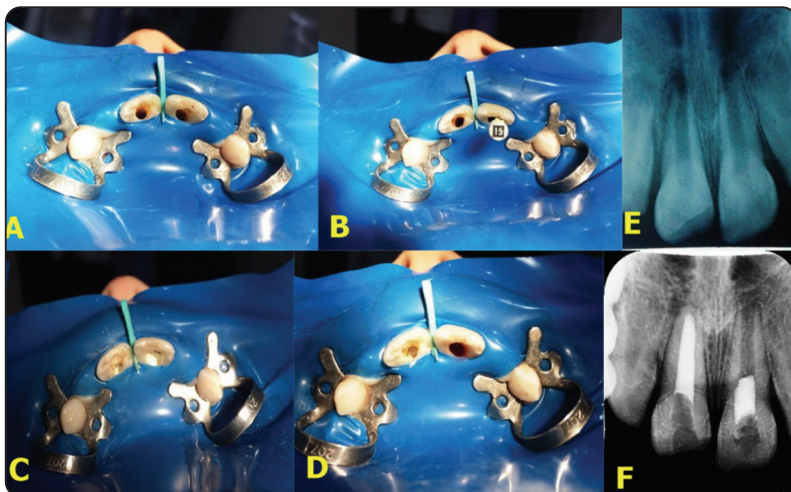


Fig. (3) A: Access opening done in upper bilateral traumatized immature centrals incisors. B: Bleeding enhancement by K File # 15 in upper left central incisor. C: Blood clot formed in upper left incisor and MTA apexification done for upper right central incisor. D: MTA condensed over the blood clot in upper left central incisor. E: Preoperative x-ray film. F: Postoperative MTA filling.

* Pro-Root MTA; Dentsply Tulsa Dental Specialties, Tulsa, OK, USA

- MTA was carried in small increments inside the canal as filling material to reach a level below the CEJ²⁵, each increment was vertically compacted using hand plugger*. Then wet cotton pellet was placed on MTA paste until initial setting occurs after filling.

Finally, the teeth of both groups were restored using reinforced Fuji GIC filling after the initial setting of MTA then peri-apical radiographic x-ray film was taken at the end of second appointment while CBCT was taken before and after 18 months follow up period.

RESULTS

The present study evaluated and compared pulp revascularization and apexification in immature non-vital permanent incisors radiographically by CBCT.

The computer was fed the data and the IBM SPSS software programmer version 20.0 was used to analyses it. (Armonk, New York: IBM Corporation). The Shapiro-Wilk test was used to determine the normality of continuous data. The range (minimum and maximum values), mean, standard deviation, and median were used to express the distributed data. The student t-test was used to compare two groups with normally distributed quantitative data, whereas the Paired t-test was used to compare pre- and post-treatment groups with normally distributed quantitative variables. On the other hand, the Mann Whitney test was used to compare two groups for quantitative variables that were not normally distributed, whilst the Wilcoxon signed ranks test was used to compare two periods. The significance

of the obtained data was determined at the 5% level.

At baseline the two treatment groups showed nonsignificant differences regarding the parameters namely, dentin volume, pulp space volume, MD root length, and BL root length. This was evidenced by their baseline values as shown in table (1) as $p > 0.05$.

Group I (Revascularization):

Results presented substantial elevation in the mean value of dentin volume and root length in mesiodistal direction from $40 \pm 14 \text{ mm}^3$ and $10.6 \pm 1.7 \text{ mm}$ to $73.5 \pm 40.2 \text{ mm}^3$ and $12.4 \pm 1.4 \text{ mm}$ respectively as $p < 0.05$, while the root length increase in buccolingual direction but not statically significant increase. It was found also a significant decrease in pulp space volume from $16 \pm 14.6 \text{ mm}^3$ to $9.3 \pm 7.7 \text{ mm}^3$ as shown in table (1).

Group II (Apexification):

Results showed non-significant increase in the mean value of dentin volume, pulp space volume, root length in mesiodistal direction, and root length in buccolingual direction from $38.2 \pm 8.8 \text{ mm}^3$, $8.6 \pm 4.3 \text{ mm}^3$, $11.9 \pm 1.3 \text{ mm}$, and $12.8 \pm 1.8 \text{ mm}$ to $48.5 \pm 11.4 \text{ mm}^3$, $11.2 \pm 3.5 \text{ mm}^3$, $12.3 \pm 1.7 \text{ mm}$, and $13.2 \pm 1.7 \text{ mm}$ respectively as shown in table (1).

Intergroup comparison:

The differences between the two groups for the mean of dentin volume and pulp space volume were statistically significant at post treatment study interval in favor of group I as $p < 0.05$. However, for the root length in both mesiodistal and buccolingual directions were non-statistically significant difference as $p > 0.05$ as shown in table 1.

* Dentsply, USA.

TABLE (1): Comparison between the two studied groups according to dentin and pulp space volumes and root length parameters

		Group 1 (n = 9)	Group 2 (n = 6)	Test of Sig.	p
Dentin volume (mm ³)	Pretreatment				
	Mean ± SD.	40 ± 14	38.2 ± 8.8	t=	0.785
	Median (Min. – Max.)	34.5 (22.9 – 66.5)	36.5 (25.6 – 51.2)	0.279	
	Post treatment				
	Mean ± SD.	73.5 ± 40.2	48.5 ± 11.4	t=	0.016*
	Median (Min. – Max.)	70.3 (32.2 – 157)	46.5 (36.4 – 68)	1.469	
	t₀ (p₀)	2.300* (0.049*)	2.399 (0.062)		
Pulp volume (mm ³)	Pretreatment				
	Mean ± SD.	16 ± 14.6	8.6 ± 4.3	U=	0.456
	Median (Min. – Max.)	8.71 (4.7 – 44.82)	7.2 (3.9 – 14.1)	20.0	
	Post treatment				
	Mean ± SD.	9.3 ± 7.7	11.2 ± 3.5	U=	0.048*
	Median (Min. – Max.)	7.6 (2.8 – 27)	9.4 (8.7 – 17.7)	12.0	
	Z (p₀)	2.490* (0.013*)	1.363 (0.173)		
MD Root length	Pretreatment				
	Mean ± SD.	10.6 ± 1.7	11.9 ± 1.3	t=	0.132
	Median (Min. – Max.)	11.1 (7.8 – 13.7)	12 (10.43 – 13.9)	1.606	
	Post treatment				
	Mean ± SD.	12.4 ± 1.4	12.3 ± 1.7	t=	0.862
	Median (Min. – Max.)	12.7 (9.8 – 14)	11.9 (10.5 – 14.7)	0.178	
	t₀ (p₀)	3.362* (0.010*)	1.036 (0.348)		
BL Root length	Pretreatment				
	Mean ± SD.	11.8 ± 2.1	12.8 ± 1.8	t=	0.374
	Median (Min. – Max.)	11.4 (9.1 – 15.1)	12.7 (10.5– 15.4)	0.920	
	Post treatment				
	Mean ± SD.	12.9 ± 1.8	13.2 ± 1.7	t=	0.770
	Median (Min. – Max.)	13.2 (10.1– 15.5)	13.1 (11 – 15.3)	0.298	
	t₀ (p₀)	1.996 (0.081)	1.780 (0.135)		

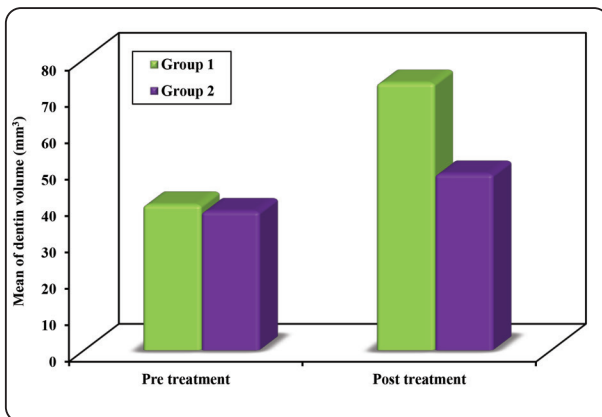


Fig. (1) Comparison between the two studied groups according to dentin volume

DISCUSSION

Pulp revascularization is a relatively novel and promising treatment option for immature teeth but until now not enough data that recommend it as an alternative to apexification in permanent teeth in their adolescent years with irreversible pulpitis and pulp necrosis. So, radiographic comparisons were necessary in the present study to detect the best technique in the treatment of permanent immaturityteeth²⁶.

Root canal management of the non-vital immature permanent teeth is a difficulty to clinicians.

Their primary concerns when treating teeth with “blunderbuss” canals are with the appropriateness of canal space disinfection and obturation issues, particularly in managing working length¹. Apexification with calcium hydroxide is the most often used treatment for controlling such teeth. Traditionally, the usage of MTA to generate calcific apical barrier then location of a bonded core within the canal for strength of the weakened roots which was standard for non-vital teeth with open apices²⁷.

MTA offers a higher long-term success rate because it avoids several of the disadvantages of standard calcium hydroxide apexification methods, such as reduced treatment time and patient visits, and prompt restoration of the tooth, which results in a decreased risk of fracture²⁸ and a boost in patient compliance²⁹ as a result, this material was incorporated into this research.

The success rate of endodontic regeneration operations as proposed by the American Association of Endodontists (AAE), is largely measured by the extent to which it is possible to attain several goals³⁰. The major objective is to eliminate symptoms and to demonstrate bone repair. The secondary goal is to enhance the thickness of the root wall and/or the length of the roots. The tertiary objective entails a favorable response to vitality testing (which could indicate a more organized and vital pulp tissue).

Controlling infection with chemical agents and mechanical instrumentation is critical for successful endodontic treatment of infected root canals. Both the pulp cavity and dentinal walls must be properly cleaned prior to the ingrowth of important tissue during pulp regeneration.³¹ However, mechanical eradication of germs is not suggested in young teeth owing to the fragility of the thin root walls. Additionally, mechanical cleaning may exacerbate the fragility of the root canal walls³² Then eliminate any critical tissue remains that may remain in the canal’s apical portions allowing subsequent further root development, and hence should be avoided during this procedure³³. Therefore, minimal initial instrumentation is used in the present study.

Root canal disinfectant in immature non-vital teeth is mainly restricted to irritant solution and intra-canal medicaments³⁴. The AAE recommends the use of as low a concentration of sodium hypochlorite irrigant as possible due to the possibility of its extrusion through the open apex causing cytotoxicity to the apical stem cells³⁵. Therefore, NaOCl irrigant solution was used in concentration of 2.5% in the present study to avoid the cytotoxic effect of higher concentration on periapical stem cells³⁶. Then NaOCl was then flushed from root canal using 20 ml saline or distilled water to minimize any extended toxicity that may impair regeneration responses, minimize the possibility of precipitation, and eliminate residual debris and irrigant remains³⁴.

Pulp revascularization is more advantageous in a bacteria-free environment, which demands that the root canal system be cleansed prior to cell colonisation³³. As in recent investigations, canal decontamination is accomplished by applying disinfecting solutions without the use of typical mechanical instrumentation.^{9,37,38} On the other hand, the present study disagreed with Alobaid et al³⁷ who suggested that passive disinfection with NaOCl may not be sufficient to eliminate contamination which they used only (TAP) for 2 weeks.

Because root canal infection is caused by numerous species of bacteria, it is improbable that a single antibiotic will be able to eradicate all these pathogens and maintain a sterile environment³⁶. However, Hoshino et al³⁹ observed that Three antibiotics (Metronidazole, Ciprofloxacin, and Minocycline) were used in TAP to eradicate microorganisms populating the dentin. Additionally, this paste eliminated germs within the deep layers of dentin, preventing infection within root canals while allowing ingrowth of new tissue necessary for root development.⁴⁰

Despite the promising results of TAP, there are Some adverse effects, such as darkening of the crown, are caused by the presence of minocycline³⁶. Some authors suggested replacement of the minocy-

cline with amoxicillin, cefaclor or clindam⁴¹. Therefore, modified TAP consisted of metronidazole, ciprofloxacin and amoxicillin was used in this study⁴². Dressing with TAP intra canal medication left for two - three weeks to complete canal disinfection and maintain stem cells vitality³⁶. Therefore, intracanal modified TAP was applied for three weeks in the recent research.

Inducing bleeding inside the root canal by mechanical irritation of periapical tissues is easier when an anesthetic solution does not contain a vasoconstrictor³³. Therefore, local anesthesia without vasoconstrictor was used in this study. The bleeding should be allowed to reach a level of 2-3 mm below the cement-enamel junction to avoid dentin pigmentation by blood clot⁴³.

Inducing bleeding into the canal may result in the production of stem cells capable of initiating dentin development³³. The blood clot is intended to operate as a matrix for migratory responsive cells to adhere and differentiate to repair the pulp-physiological dentine's functions complex^{9,33}. So, this treatment protocol was followed in revascularization group.

MTA barrier over the formed blood clot was used because the material possesses an excellent sealing ability^{43,44}. The coronal edge of the MTA should be placed 1-2 mm apical to the cement-enamel junction to allow more root development rather than 3-4 mm as described by Banchs and Trope⁴⁵. Therefore, MTA was placed 1-2mm apical to cement-enamel junction in the present study. Then pulp chamber was finally sealed using GIC filling to avoid any bacterial contamination to blood clot and MTA inside the canal during its setting time⁴³.

On the other hand, in apexification, ortho-grade MTA obturation in immature non-vital teeth apexification represents "primary monoblock" with successful outcome²⁵ and aimed to strengthen the remaining thin dentinal walls. Therefore, complete canal obturation with MTA was followed in apexification group.

CBCT showed very high accuracy in dental diagnosis with extremely high sensitivity and specificity results that reach 100% for both⁴⁶. Different radiographic measures can be obtained from CBCT, most of these radiographic assessments are linear measures, the transforming from linear measures to quantitative measures has a strong interest. At research conducted by Elborae et al.,⁴⁶ the 3D volume assessment of CBCT was evaluated. The study showed accurate and promising results for using 3D volume measurement instead of linear measurement, which may be of value especially for the reproducible assessment of bone defect topography for research purposes.

Problem of image segmentation is a very challenging problem during obtaining quantitative measures from 3D radiographic modalities. Because of segmentation challenges, there is no definite strategy or algorithm for object segmentation was used by different software⁴⁷.

Numerous software packages are available for analysing the three-dimensional data collected during the CT or CBCT scan procedure used for volumetric measurement. ITK-SNAP software is a easy-use, free, with reliable package for measuring and extracting radiographic volumes, ITK-SNAP depending on artificial intelligent allows different modalities for identifying and outlining for the structure of interest depending on automatic segmentation or semiautomatic segmentation or self-expert outlining of the radiographic object with the option of isotropic identification for the voxels from pixels selection, in turn these allow an accurate measurement of the volume of interest⁴⁸⁻⁴⁹.

Although MTA apexification had been used successfully, many documented drawbacks, such as, lack of continued root development and it does not strengthen the remaining root structure. Revascularization allows continued root growth, which may reduce the risk of fracture and the permanent tooth loss associated with traditional apexification, thus the potential of regenerative

endodontic as the treatment of necrotic immature teeth is strongly recognized⁵⁰.

The size of the apical foramen is critical, particularly for regenerative endodontic treatment of permanent teeth prior to completion root growth⁴³. In the present study, the younger age patients (7-7.5 years old) had wider incisors apical canal ends that allowing the more numbers of periapical stem cells for better success results of revascularization. Immature teeth's root structure (e.g., open apex, large root canal, and thin radicular dentin walls) may facilitate connection between canal space and periodontal tissue in order to accomplish apical healing with periodontal tissue. The results of this study agreed with Fang et al⁵¹. Revascularization seems more predictable when the apical diameter exceeds 1 mm and is unlikely to occur in apical apertures less than 0.3 mm in diameter⁵².

In the present study, group I (revascularization) showed significant increase in dentin volume and decrease in pulp space volume from $40 \pm 14 \text{ mm}^3$ and $16 \pm 14.6 \text{ mm}^3$ to $73.5 \pm 40.2 \text{ mm}^3$ and $9.3 \pm 7.7 \text{ mm}^3$ respectively. The results of intergroup comparison were in favor of group I over group II (Apexification) which showed non-significant increase in both dentin volume and pulp space volume, these reflect optimal regenerative response from MTA at revascularization cases over the apexification, proved by closure of apical foramen, increase in the dentine and decrease of pulp space, while for apexification regeneration was showed by apical foramen closure and increase of the root length, and these may be the explanation for non-significant increase of both dentin and pulp space volumes.

The present study findings agreed with Bose et al⁵³ in which regenerative endodontic treatment with MTA and TAP produced significantly greater increases in root length and dentin wall thickness than (MTA) apexification group. Moreover, the present study results was in agreement with Chen et al⁵⁴, Jeruphan et al⁵⁵, Sarris et al⁵⁶ and Jung et al⁵⁷ reported a high success rate root canal revascularization with

increased root lengthening and narrowing of the canals (apical closure), cure of apical periodontitis, and lack of clinical signs and symptoms.

The effect of periapical stem cells in enhancing the proliferation of cementoblast, odontoblast and osteoblast cells to form new deposited tissue inside and outside the root rather than resorption. Another explanation for this MTA is that it not only meets the ideal requirement of being bacteriostatic, but also creates a challenging environment for bacterial survival, resulting in less persistent disease. This was in agreement with these studies^{6,58,59}. On the other hand, it was in disagreement with Alobaid et al³⁷ and Chueh⁶⁰. This difference may be attributed to the use of CaOH paste medication and short follow-up periods (3, 6 months).

CONCLUSION

Both apexification and revascularization techniques showed significant root apex closure and root regeneration for immature permanent incisors with a preference to revascularization as it showed better results and was also easily and rapidly applied when compared to apexification.

REFERENCES

1. El-Kenany MH, Awad SM, Hegazy SAs. Prevalence and risk factors of traumatic dental injuries to permanent anterior teeth among 8–12 years old school children in Egypt. *Pedi Dent J* 2016; 26: 67-73.
2. Corporation. HPs. Pulp Revascularization of Immature Permanent Teeth: A Review of the Literature and a Proposal of a New Clinical Protocol. *Scie World J.* 2014; 10: 1-9.
3. Mohammadi Zs. Strategies to manage permanent non-vital teeth with open apices: a clinical update. *Int Dent J* 2011; 61: 25-30.
4. Kareem K, Rasha M. Managements of Immature Apex: a Review. *Mod Res Dent J* 2017; 1: 1-21.
5. Farhad A , Mohammadi Zs. Calcium hydroxide: a review. *Int Dent J* 2005; 55: 293-301.
6. Fouad AF ,Nosrat As. Pulp regeneration in previously infected root canal space. *Endod Topics* 2013; 28: 24-37.

7. Cohen S, Hargreaves KM. Pathways of the Pulp. St Louis: Mosby Inc. 2006: 610–649.
8. Keswani D ,Pandey RKs. Revascularization of an immature tooth with a necrotic pulp using platelet-rich fibrin: a case report. *Int Endod J* 2013; 46: 1096-104.
9. Wigler R, Kaufman AY, Lin S, Steinbock N, Hazan-Molina H, Torneck CDs. Revascularization: a treatment for permanent teeth with necrotic pulp and incomplete root development. *J Endod* 2013; 39: 319-26.
10. Garcia-Godoy F ,Murray PEs. Recommendations for using regenerative endodontic procedures in permanent immature traumatized teeth. *Dent Traumatol* 2012; 28:33-41.
11. American Association of Endod, Glossary of endodontic terms. 2003, Chicago, Ill.: American Association of Endodontists.
12. Trope Ms. Root resorption of dental and traumatic origin: classification based on etiology. *Pract Periodontics Aesthet Dent* 1998; 10: 515-22.
13. Asgary S, Eghbal MJ, Bagheban AAs. Long-term outcomes of pulpotomy in permanent teeth with irreversible pulpitis: A multi-center randomized controlled trial. *Am J Dent* 2017; 30: 151-155.
14. White, S.C. and M.J. Pharoah, White and Pharoah's Oral Radiology E-Book: Principles and Interpretation. 2018: Elsevier Health Sciences.
15. Dawood, A., S. Patel, and J. Brown, Cone beam CT in dental practice. *British dental journal*, 2009. 207(1): p.23-28.
16. Scarfe, W. and A. Farman, Soft tissue calcifications in the neck: Maxillofacial CBCT presentation and significance. *AADMRT Currents*, 2010. 2(2): p. 3-15.
17. Karatas, O.H. and E. Toy, Three-dimensional imaging techniques: A literature review. *European journal of dentistry*, 2014. 8(1): p. 132.
18. Ye, N., F. Jian, and W. Lai, Effect of voxel size and partial volume effect on accuracy of tooth volumetric measurements with cone beam CT. *Dentomaxillofacial Radiology*, 2013. 42(5).
19. Almuzian, M., H.M. Al Ghatam, and L. Al-Muzian, Assessing the validity of ITK-SNAP software package in measuring the volume of upper airway spaces secondary to rapid maxillary expansion. *Journal of orthodontic science*, 2018. 7.
20. Millers. A classification of tooth mobility *Int J Perio Rest Dent* 1985; 5: 9-13.
21. Silvana B Z, Clovis M, Graham R, Anthony J and Jacques E.s. Tooth slice-based models for the study of human dental pulp angiogenesis. *J Endod* 2007; 33: 811–814.
22. Sachdeva G SL, Goel M and Bala S,s. Regenerative endodontic treatment of an immature tooth with a necrotic pulp and apical periodontitis using platelet-rich plasma (PRP) and mineral trioxide aggregate (MTA): a case report. *Inter Endod J* 2015; 48: 902–910.
23. Zehnder Ms. Root Canal Irrigants. *Journal of Endodontics* 2006; 32: 389-398.
24. Nazzal H, Kenny K, Altimimi A, Kang J, Duggal MSs. A prospective clinical study of regenerative endodontic treatment of traumatized immature teeth with necrotic pulps using bi-antibiotic paste. *International Endodontic Journal* 2018; 51: 204-215.
25. Iqbal Z ,Qureshi AHs. MTA monoblock obturation technique in endodontic retreatment. *J Coll Physicians Surg Pak* 2014; 24: 180-182.
26. Moodley D, Peck C, Moodley T, Patel Ns. Management of necrotic pulp of immature permanent incisor tooth: A regenerative endodontic treatment protocol: case report. *South African Dental Journal* 2017; 72: 122-125.
27. Chandran V, Chacko V, Sivadas Gs. Management of a nonvital young permanent tooth by pulp revascularization. *International journal of clinical pediatric dentistry* 2014; 7: 213-216.
28. Cehreli ZC, Sara S, Aksoy Bs. Revascularization of immature permanent incisors after severe extrusive luxation injury. *J Can Dent Assoc* 2012; 78: 4-11.
29. Rudagi KB ,Rudagi Bs. One-step apexification in immature tooth using grey mineral trioxide aggregate as an apical barrier and autologous platelet rich fibrin membrane as an internal matrix. *J Conserv Dent* 2012; 15: 196-199.
30. AAEs. Clinical Considerations for a Regenerative Procedure. American Association of Endodontics 2014.
31. Bystrom A, Sundqvist Gs. Bacteriologic evaluation of the efficacy of mechanical root canal instrumentation in endodontic therapy. *Scand J Dent Res* 1981; 89: 321-328.
32. Moodley D, Peck C, Moodley T, Patel Ns. Management of necrotic pulp of immature permanent incisor tooth: A regenerative endodontic treatment protocol: case report. *South African Dental Journal* 2017; 72: 122-125.
33. Aly MM, Taha SEE, El Sayed MA, Youssef R, Omar HMs. Clinical and radiographic evaluation of Biodentine and Mineral Trioxide Aggregate in revascularization of non-vital immature permanent anterior teeth (randomized clinical study). *Int J Paediatr Dent* 2019;29:464-473.
34. Clarkson RM ,Moule AJs. Sodium hypochlorite and its use as an endodontic irrigant. *Aust Dent J* 1998; 43: 250-256.

35. Siqueira JF, Jr., Rocas IN, Favieri A, Lima KCs. Chemo-mechanical reduction of the bacterial population in the root canal after instrumentation and irrigation with 1%, 2.5%, and 5.25% sodium hypochlorite. *J Endod* 2000; 26: 331-334.
36. Maria T JY, Adriana J and Alexandre A,s. Pulp revascularization: an alternative treatment to the apexification of immature teeth. *RGO - Revista Gaúcha de Odontologia* 2014; 62: 401-410.
37. Alobaid AS, Cortes LM, Lo J, Nguyen TT, Albert J, Abu-Melha AS, et al.s. Radiographic and clinical outcomes of the treatment of immature permanent teeth by revascularization or apexification: a pilot retrospective cohort study. *J Endod* 2014; 40: 1063-70.
38. Jeeruphan T, Jantarat J, Yanpiset K, Suwannapan L, Khew-sawai P, Hargreaves KMs. Mahidol study 1: comparison of radiographic and survival outcomes of immature teeth treated with either regenerative endodontic or apexification methods: a retrospective study. *J Endod* 2012; 38: 1330-6.
39. Hoshino E, Kurihara-Ando N, Sato I, Uematsu H, Sato M, Kota K, et al.s. In-vitro antibacterial susceptibility of bacteria taken from infected root dentine to a mixture of ciprofloxacin, metronidazole and minocycline. *Int Endod J* 1996; 29: 125-30.
40. Sato I, Ando-Kurihara N, Kota K, Iwaku M, Hoshino Es. Sterilization of infected root-canal dentine by topical application of a mixture of ciprofloxacin, metronidazole and minocycline in situ. *Int Endod J* 1996; 29: 118-124.
41. Vijayaraghavan R, Mathian VM, Sundaram AM, Karunakaran R, Vinodh Ss. Triple antibiotic paste in root canal therapy. *Journal of pharmacy & bioallied sciences* 2012; 4: 230-233.
42. Conde MCM, Chisini LA, Sarkis-Onofre R, Schuch HS, Nor JE, Demarco FFs. A scoping review of root canal revascularization: relevant aspects for clinical success and tissue formation. *Int Endod J* 2017; 50: 860-874.
43. Aksel H ,Serper As. Recent considerations in regenerative endodontic treatment approaches. *Journal of Dental Sciences* 2014; 9: 207-213.
44. Fridland M ,Rosado Rs. Mineral trioxide aggregate (MTA) solubility and porosity with different water-to-powder ratios. *J Endod* 2003; 29: 814-7.
45. Banchs F ,Trope Ms. Revascularization of Immature Permanent Teeth With Apical Periodontitis: New Treatment Protocol? *Journal of Endodontics* 2004; 30: 196-200.
46. Momamed Omar Elboraey, H.I.S., Samia A. Darwish, Mona Yehia Abd El Razzak The Effectiveness of Chitosan Collagen Membrane with and without Hydroxyapatite Particles in the Treatment of Class II Mandibular Furcation Defects in Humans: A Randomized Clinical and Radiographic Evaluation. *EGYPTIAN DENTAL JOURNAL*, 2018. 4(july): p. 160-175.
47. Iglesias, J.E. and M.R. Sabuncu, Multi-atlas segmentation of biomedical images: a survey. *Medical image analysis*, 2015. 24(1): p. 205-219.
48. Almuzian, M., H.M. Al Ghatam, and L. Al-Muzian, Assessing the validity of ITK-SNAP software package in measuring the volume of upper airway spaces secondary to rapid maxillary expansion. *journal of orthodontic science*, 2018. 7.
49. El, H. and J.M. Palomo, Measuring the airway in 3 dimensions: a reliability and accuracy study. *American Journal of Orthodontics and Dentofacial Orthopedics*, 2010. 137(4): p. S50. e1-S50. e9.
50. Santiago CN, Pinto SS, Sassone LM, Hirata R, Jr., Fidel SRs. Revascularization Technique for the Treatment of External Inflammatory Root Resorption: A Report of 3 Cases. *J Endod* 2015; 41: 1560-4.
51. Fang Y, Wang X, Zhu J, Su C, Yang Y, Meng Ls. Influence of Apical Diameter on the Outcome of Regenerative Endodontic Treatment in Teeth with Pulp Necrosis: A Review. *J Endod* 2018; 44: 414-431.
52. Diogenes A, Ruparel NB, Shiloah Y, Hargreaves KMs. Regenerative endodontics: A way forward. *J Am Dent Assoc* 2016; 147: 372-380.
53. Bose R, Nummikoski P, Hargreaves Ks. A retrospective evaluation of radiographic outcomes in immature teeth with necrotic root canal systems treated with regenerative endodontic procedures. *J Endod* 2009; 35: 1343-9.
54. Chen MY, Chen KL, Chen CA, Tayebaty F, Rosenberg PA, Lin LMs. Responses of immature permanent teeth with infected necrotic pulp tissue and apical periodontitis/ abscess to revascularization procedures. *Int Endod J* 2012; 45: 294-305.
55. Jeeruphan T, Jantarat J, Yanpiset K, Suwannapan L, Khew-sawai P, Hargreaves KMs. Mahidol study 1: comparison of radiographic and survival outcomes of immature teeth treated with either regenerative endodontic or apexification methods: a retrospective study. *J Endod* 2012; 38: 1330-6.

56. Sarris S, Tahmassebi JF, Duggal MS, Cross IAs. A clinical evaluation of mineral trioxide aggregate for root-end closure of non-vital immature permanent incisors in children- a pilot study. *Dent Traumatol* 2008; 24: 79-85.
57. Jung C, Kim S, Sun T, Cho Y-B, Song Ms. Pulp-dentin regeneration: current approaches and challenges. *Journal of tissue engineering* 2019; 10:20-41.
58. Santiago CN, Pinto SS, Sassone LM, Hirata R, Jr., Fidel SRs. Revascularization Technique for the Treatment of External Inflammatory Root Resorption: A Report of 3 Cases. *J Endod* 2015; 41: 1560-4.
59. Araujo PRS, Silva LB, Neto A, Almeida de Arruda JA, Alvares PR, Sobral APV, et al.s. Pulp Revascularization: A Literature Review. *Open Dent J* 2017; 10: 48-56.
60. Chueh LH, Ho YC, Kuo TC, Lai WH, Chen YH, Chiang CPs. Regenerative endodontic treatment for necrotic immature permanent teeth. *J Endod* 2009; 35: 160-4.