

Clinical and Radiological Evaluation of Minimal Invasive Fixation of Sander's Type II, III Calcaneal Fracture

Ahmed El-sayed El-Malt, Ali Tawfiq El-Alfi, Mohamed Magdy M. El-sayed*, Ahmed Mohamed Nahla
Orthopedic Surgery Department, Faculty of Medicine, Zagazig University, Egypt

*Corresponding author: Mohamed Magdy El-sayed, **Mobile:** (+2):010907437854, **Email:** drmohamedmagdy660@gmail.com

ABSTRACT

Background: Calcaneal fractures continue to be one of the most complicated injuries of the lower extremity. The aim of the present study was to evaluate the clinical and radiological results of minimal invasive fixation in management of sanders type II, III calcaneal fractures.

Patients and methods: This study was carried out in Zagazig University Hospital and Damietta Specialized Hospital. Eighteen cases were included as a comprehensive sample with sander's type II, III closed fracture.

Results: The mean age of the studied cases is 45.33 (SD 9.8) years; 83.3% are males, 83.3% are working and 50% are smokers. About 66.7% of the included cases have fracture due to fall from height, 16.7% road traffic accidents and 16.7% direct trauma. Of the studied cases, 66.7% have right side fracture. About 66.7% of the cases have joint depression by Essex classification, 33.3% Sanders classification III, and 66.7% Sanders classification II. Only 33.3% of the cases have positive subtalar arthritis. The mean range of movement is 85.83 (ranged from 70 to 100), and mean AOFOS score is 87.83 (ranged from 77 to 95). The American Orthopaedic Foot & Ankle Society (AOFAS) score shows statistically significant positive correlation with PIFA pre-treatment, PIFA post treatment and negative correlation with HT pre and post treatment.

Conclusion: Treatment of calcaneal fractures using a minimally invasive internal fixation method with a thin plate and bone grafting can provide excellent or good clinical outcomes with few soft tissue complications.

Keywords: Essex classification, Sander's Types, Calcaneal fracture, Invasive fixation, road traffic accidents

INTRODUCTION

About 60% of all tarsal fractures in adults are calcaneal fractures, which account for 2% of all adult fractures. These fractures typically result from car accidents and falls from great heights⁽¹⁾. There is no one treatment method that can be used to treat all calcaneus fractures, which makes them a source of possible handicap for the patient, a financial burden on society, and a treatment challenge for the typical orthopaedic surgeon⁽²⁾.

Physical examination, followed by X-rays and/or CT scans, can be used to identify calcaneal fractures. Fractures of the calcaneus can be quite serious. Surgery is frequently used as a kind of treatment to recreate the heel's natural structure and to regain mobility so that the patient may resume regular activities. But even with the right care, certain fractures can lead to long-term consequences including arthritis, discomfort, swelling, and loss of mobility⁽³⁾.

Several factors are considered in treatment of calcaneal fractures such as (the injury cause, the severity of the injury, the extent of soft tissue damage, if the patient is fit for surgery or not)⁽⁴⁾.

Many treatment modalities are present including a conservative method when there is no impingement of the peroneal tendons and the fracture segments are not displaced (or are displaced less than 2 mm). Non-operative care is also recommended when, despite the presence of a fracture, proper weight-bearing alignment has been adequately maintained and articulating surfaces are not disturbed. Extra-articular fractures are generally treated conservatively. Finally, non-operative care is also recommended for patients who are unfit for operative⁽⁵⁾.

Surgical methods include either minimal invasive or extensile lateral approach. Minimal invasive fixation has many advantages than extensile lateral approach⁽⁶⁾. The advantages of minimal invasive fixation such as, less soft tissue complications, early mobilization is generally possible, minimization of surgery time, reduced cost, removal of implant is possible in local anesthesia and through stab incisions⁽⁷⁾. In extensile lateral approach, wound healing problems occur roughly as skin necrosis, soft tissue infection and neurovascular complications⁽⁸⁾.

Therefore, this study aimed to evaluate the clinical and radiological results of minimal invasive fixation in management of sanders type II, III calcaneal fractures.

PATIENTS AND METHODS

This study was carried out in Zagazig University Hospital and Damietta Specialized Hospital. Only 18 cases fulfilled the inclusion and exclusion criteria, recruited as 3 cases per month during the 6 months of the study period.

Inclusion criteria: Patients with sander's types II and III closed fracture, and skeletally mature patients.

Exclusion criteria: Patients with sander's types I and IV, open or pathological fracture, patients not reaching maturity and infection (osteomyelitis).

Operational Design: All studied patients were subjected to complete history taking, clinical and physical examination. Investigation included x-Ray and CT were done. Pre-operative laboratory examination was also performed.

Technique: Patient was stabilized on a radiolucent operating table in the lateral decubitus position under

general or spinal anesthesia. C- Arm was properly placed in the imaging setup for obtaining x-rays in the sagittal and axial directions.

Steps: (1) Distraction of the posterior talocalcaneal joint using a transverse Steinmann pin inserted in the calcaneum. (2) Reduction by elevation of the displaced tongue fragment using the modified Essex-Lopresti maneuver under image intensifier control. Heel varus valgus was corrected using the transverse Steinmann pin. The reduction was assessed intra operatively using the lateral, axial and Broden's views. (3) Fixation of the fragments was done using screws through stab incisions completing the fixation or fixation can be achieved by percutaneous k-wires. Generally, 3 to 6 screws were required for fixation according to the fracture pattern. Each major fragment was fixed to another fragment using screws improving the fixation construct. (4) Fixation and subtalar motion were screened under fluoroscopy confirming the stability and quality of reduction of the fracture.

Post-operative care: The patients were given a below knee plaster for a period of 4 weeks after which they were allowed ankle and foot mobilizing exercises. All patients are kept non - weight bearing in the injured limb for a period of 8 weeks following which gradual progression to unassisted full weight bearing gait was allowed

Follow up: Clinical and radiological follow up is recommended after 1, 2, 4, 6, and 12 months. They are evaluated for union and loss of reduction as well as for the Bohler and Gissane angles.

Ethical consideration:

The study was approved by the Ethical Committee of Zagazig, Faculty of Medicine. An informed consent was obtained from all patients in

this research. Every patient received an explanation for the purpose of the study. All given data were used for the current medical research only. This work has been carried out in accordance with The Code of Ethics of the World Medical Association (Declaration of Helsinki) for studies involving humans.

Statistical analysis:

Data were analyzed using IBM SPSS Corp. Released 2013. IBM SPSS Statistics for Windows, Version 22.0. Armonk, NY: IBM Corp. Qualitative data were described using number and percent. Quantitative data were described using mean, standard deviation for parametric data after testing normality using Shapiro–Wilk test. Wilcoxon Signed-Rank test was used to compare between 2 studied periods. Chi square test (χ^2) and Fisher's exact test to calculate difference between two or more groups of qualitative variables. Spearman's correlation test was used. P-value ≤ 0.05 was considered significant, P-value < 0.01 was considered as highly significant, and P-value > 0.05 was considered insignificant.

RESULTS

The present study is longitudinal descriptive study that is carried out on 18 cases with calcaneal fractures to evaluate the clinical and radiological results of minimal invasive fixation in management of sanders type II, III calcaneal fractures and to assess rate of complications especially in elderly patients and diabetic patient. The mean age of the studied cases is 45.33, with 83.3% are males, 83.3% are working and 50% smokers. About 66.7% of the studied cases have fracture due to fall from height, 16.7% RTA and 16.7% direct trauma. Of the studied cases; 66.7% have right side fracture (Table 1).

Table (1): Demographic & Clinical characteristics of the studied cases.

Variable	N=18	%
Age in years (mean±SD)	45.33±9.76	
Sex		
Male	15	83.3
Female	3	16.7
Occupation		
Not working	3	16.7
Working	15	83.3
Smoking		
Non-smoker	9	50.0
Smoker	9	50.0
Mode of fracture		
Fall from height	12	66.7
Road traffic accidents	3	16.7
Direct trauma	3	16.7
Side		
Right	12	66.7
Left	6	33.3

As regards 66.7% of the studied cases have joint depression by Essex classification, 33.3% Sanders classification III and 66.7% Sanders classification II of the studied cases; 33.3% have positive subtalar arthritis (**Table 2**).

Table (2): Essex classification, sanders classification and shoulder joint arthritis distribution among studied cases.

Variable	N=18	%
Essex classification		
Joint depression	12	66.7
Tongue type	6	33.3
Sanders classification		
II	12	66.7
III	6	33.3
Subtalar arthritis		
Negative	12	66.7
Positive	6	33.3

The mean range of movement is 85.83 (ranged from 70 to 100) and mean American Orthopaedic Foot & Ankle Society (AOFOS) score is 87.83 (ranged from 77 to 95) (**Table 3**).

Table (3): Range of movement and AOFOS score

Variable	N=18
Range of movement	
Mean±SD	85.83±10.47
Min-max	70-100
AOFOS score	
Mean±SD	87.83±6.35
Min-max	77-95

There is no statistically significant difference between pre and post treatment as regard Bohler score and Gissan score (**Figures 1, 2**).

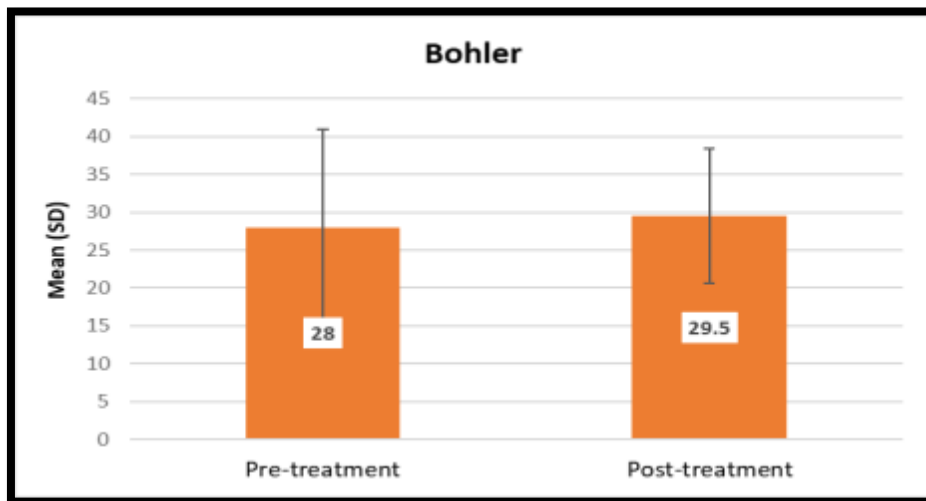


Figure (1): Bohler score change between pre and post treatment

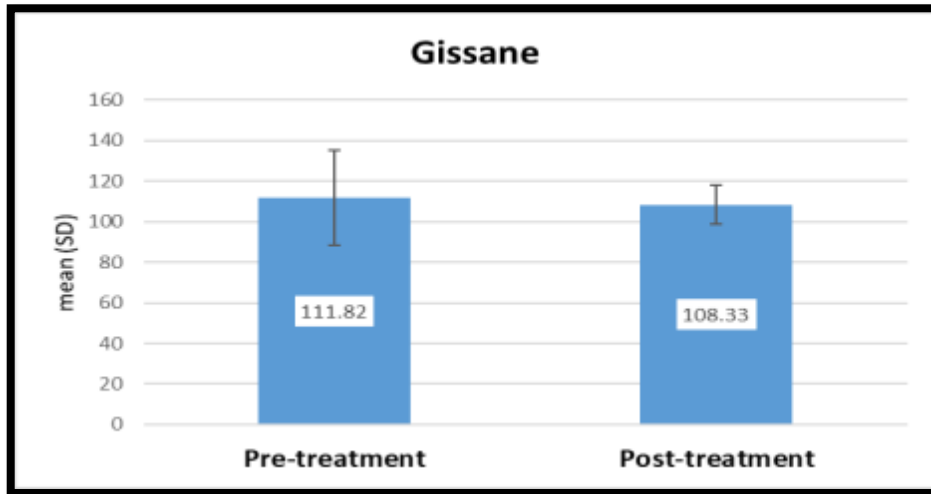


Figure (2): Gissane score change between pre and post treatment

There is statistically significant negative correlation between **range of movement (ROM)** and the following; HT post ($r=-0.742$) and Gissane pre-treatment ($r=-0.832$) and post-treatment ($r=-0.820$). AOFOS score shows statistically significant positive correlation with PIFA pre-treatment ($r=0.691$), PIFA post treatment ($r=0.746$) and negative correlation with HT pre ($r=-0.632$) and HT post treatment ($r=-0.524$) (Table 4).

Table (4): Correlation between studied scores and range of movement and AOFOS score among studied cases.

Variable	Correlation	ROM	AOFOS score
Bohler pre-treatment	r	.091	.435
	p-value	.719	.071
Bohler post-treatment	r	-.334	.029
	p-value	.176	.909
Gissane pre-treatment	r	-.832*	.103
	p-value	<.001	.684
Gissane post-treatment	r	-.820*	.087
	p-value	<.001	.732
PFIA pre-treatment	r	.092	.691*
	p-value	.715	.001
PFIA post-treatment	r	-.250	.746*
	p-value	.317	<.001
HT pre-treatment	r	-.277	-.632*
	p-value	.265	.005
HT post-treatment	r	-.742*	-.524*
	p-value	<.001	.026
Length pre-treatment	r	-.277	-.162
	p-value	.265	.521
Length post-treatment	r	-.219	-.030
	p-value	.383	.906

r: Pearson correlation coefficient, *statistically significant if $p < 0.05$

Regarding complications, Subtalar joint arthritis was encountered in 6 patients with grade II arthritis according to Paly and Hall system. Symptomatic hardware occurred in 4 patients (22.2%). In 2 patients of them; the prominent screws were removed after 3 to 5 months, symptoms were resolved after removal. Wound infection occurred in 1 patient (5.5%). The patient started to walk after 45 days and right side infected after 75 days. Debridement was done and screw was removed (Table 5).

Table (5): Complications distribution among studied cases.

Complications	N	%
Subtalar arthritis (Grad II)	6	33.3
Symptomatic hardware	4	22.2
Wound infection	1	5.5

There were 13 patients of 13 cases had excellent and good functional end results (100%) were done at 2-3 days versus 60% excellent - good for cases done >14 days with statistically significant association (**Table 6**).

Table (6): Time of surgery and functional end results

AOFAS Score	Time of surgery		Test of significance
	2-3 days N=13	>14 days N=5	
Excellent	7 (53.8)	0	X ² =8.03 p=0.04*
Good	6 (46.2)	3 (60)	
Fair	0	1 (20)	
Poor	0	1 (20)	

A case of 45 years old female falling from height was admitted to Damietta Specialized Hospital 2 days following the trauma. She had right calcaneus fracture with associated lumbar spine fissure fracture L5# with no other associated injuries. On examination, she was neurologically intact. Local examination was done. Skin condition was good with mild oedema.

Plain X ray radiography and CT scan was obtained. Minimal invasive fixation was done 8 days after trauma (sinus tarsi technique. The lumbar spine fracture was treated conservatively and Below knee cast was done for 2 weeks with foot elevation. During follow up, full active range of motion exercises of the ankle joint started after the second post-operative week. Non weight bearing with crutches was started after 3rd post-operative week. Assisted weight bearing started after 12 weeks. After completing 12 months, radiological evaluation showed a significant improvement of all measurements (Bohler angle, angle of Gissane, posterior facet of inclination angle, calcaneal width, height and length). Final clinical evaluation revealed that patient was graded excellent with functional score (90) (**Figure 3**).

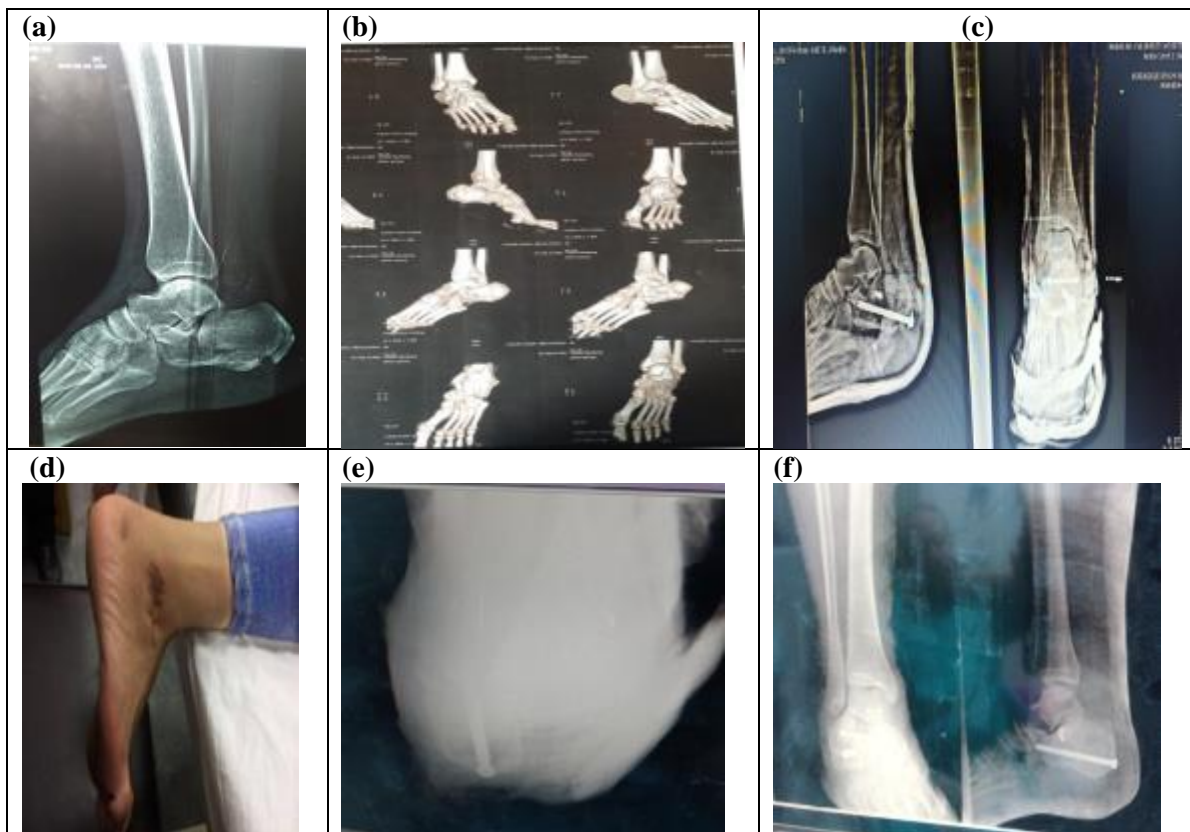


Figure (3): A 45 years old female falling from height was admitted to Hospital 2 days following the trauma; (a,b) pre-operative radiographs; (c) Immediate post-operative; (d) Non weight bearing with crutches was started after 3rd post-operative week and (e, f) final radiographs. Final clinical evaluation revealed that patient was graded excellent with functional score (90).

DISCUSSION

Calcaneus fractures represent a source of potential disability to the patient, economic burden to the society and a treatment challenge to the average orthopedic surgeon. Calcaneal fractures occur mostly in motor vehicle accidents and fall from height⁽⁹⁾. According to **Bibbo et al.**⁽¹⁰⁾ patients with a poor soft tissue condition, contraindications for open surgery, and a simple type of calcaneal fracture are treated by minimally invasive operations involving a new concept around fracture treatment.

Our study was a prospective study was conducted in Zagazig University Hospital and Damietta Specialized Hospital among 18 skeletally mature patients with calcaneal closed fracture Sander's type II and III only to evaluate the clinical and radiological results of minimal invasive fixation in management of sanders type II, III calcaneal fractures and to assess rate of complications especially in elderly patients and diabetic patient will not occur.

Regarding the demographic data in our study, the mean age was nearly 45 years with majority of males (83.3%). Most of our studied patients and half of them were smokers. Regarding the causes of calcaneal fracture, there were 12 had fracture as a result of falling from height, 3 as a result of road traffic accidents and 3 as a result of direct trauma. The fracture was in left side among 6 and right among 12. In a similar study conducted by **Jin et al.**⁽¹¹⁾ revealed the mean age was nearly 40 years with majority of females. Falling represented the mechanism of injury in most cases.

The results of **Abouelsoud**⁽¹²⁾ cleared that the mean age was 34.83 (range, 22-46) years old. There was male predominance as male: female ratio was 19:4. Majority of patients (65%) had fracture calcaneus on the right side and fall from height was the commonest cause of fractures.

In our study conducted among patients with calcaneal fracture, the operative treatment aimed to restore the smooth articular position of calcaneus and improve the motor dysfunction caused by trauma. We found no statistically significant difference between Bohler and Gissane angles pre and post treatment.

In contrast with **Amani et al.**⁽¹³⁾ showed a comparison of pre-operation and post-operation values of these angles showed a significant increase in Bohler's angle and a significant decrease in Gissane angle but the differences between the two groups were not statistically significant.

In our study all patients are kept non weight bearing in the injured limb for a period of 8 weeks following which gradual progression to unassisted full weight bearing gait is allowed. Recent studies have encouraged early mobilization, with partial weight-bearing during the first 6 weeks or 12 weeks postoperatively and for 12 weeks in conservatively treated patients^(1,14,15).

Shariatzadeh et al.⁽¹⁶⁾ allowed progressive weight-bearing in a walking boot after a mean duration

of 4.8 weeks postoperatively. Many studies recently reported that early ROM exercises and early weight-bearing led to better functional outcomes, with higher patient satisfaction. The early ROM group exhibited less muscle atrophy, less tendon adhesion, and higher rate of patients returning to previous levels of physical activity^(16,17,18).

However, several limitations of our study had been noted. The foremost limitation is the low number of cases (n= 18), the relatively short follow-up period (6–12 months) a longer follow-up period is needed to adequately assess the arthritic changes in the subtalar joint, which are among the most common complications. Despite these limitations, we believe that the results of this study can be useful in the future development of prospective cohort studies and randomized controlled trials regarding the effectiveness of treatment for calcaneal fractures

CONCLUSION

Treatment of calcaneal fractures using a minimally invasive internal fixation method with a thin plate and bone grafting can provide excellent or good clinical outcomes with few soft tissue complications.

Conflict of interest: The authors declare no conflict of interest.

Sources of funding: This research did not receive any specific grant from funding agencies in the public, commercial, or not-for-profit sectors.

Author contribution: Authors contributed equally in the study.

REFERENCES

1. **Palmersheim K, Hines B, Olsen B (2012):** Calcaneal fractures: update on current treatments. Clinics in Podiatric Medicine and Surgery, 29(2):205-20.
2. **Dhillon M, Prabhakar S (2017):** Treatment of displaced intra-articular calcaneus fractures: a current concepts review. SICOT J., 3:9-63.
3. **Park E, Choi Y, Lee J et al. (2021):** Calcaneal fracture: results of earlier rehabilitation after open reduction and internal fixation. Archives of Orthopaedic and Trauma Surgery, 141(6):929-36.
4. **Ågren P, Mukka S, Tullberg T et al. (2014):** Factors affecting long-term treatment results of displaced intraarticular calcaneal fractures: a post hoc analysis of a prospective, randomized, controlled multicenter trial. Journal of Orthopaedic Trauma, 28(10):564-8.
5. **Pesce V, Speciale D, Sammarco G et al. (2009):** Surgical approach to bone healing in osteoporosis. Clinical Cases in Mineral and Bone Metabolism, 6(2):131-34.
6. **Chotikkakamthorn N, Chanajit A, Tharmviboonsri T et al. (2020):** Minimal invasive surgery in the management of intra-articular calcaneal fractures: A retrospective comparison of screw fixation alone versus screw with small locking plate fixation techniques. Acta Orthop Traumatol Turc., 55(3):258-64.
7. **Zhou H, Yu T, Ren H et al. (2017):** Clinical comparison of extensile lateral approach and sinus tarsi

- approach combined with medial distraction technique for intra-articular calcaneal fractures. *Orthopaedic Surgery*, 9(1):77-85.
8. **Wang C, Huang S, Sun X *et al.* (2015):** Abductor digiti minimi muscle flap transfer to prevent wound healing complications after ORIF of calcaneal fractures. *International Journal of Clinical and Experimental Medicine*, 8(8):13001-5.
 9. **Giannini S, Cadossi M, Mosca M *et al.* (2016):** Minimally-invasive treatment of calcaneal fractures: A review of the literature and our experience. *Injury*, 47:138-46.
 10. **Bibbo C, Ehrlich D, Nguyen H *et al.* (2014):** Low wound complication rates for the lateral extensile approach for calcaneal ORIF when the lateral calcaneal artery is patent. *Foot & Ankle International*, 35(7):650-6.
 11. **Jin C, Weng D, Yang W *et al.* (2017):** Minimally invasive percutaneous osteosynthesis versus ORIF for Sanders type II and III calcaneal fractures: a prospective, randomized intervention trial. *Journal of Orthopaedic Surgery and Research*, 12(1):1-9.
 12. **Abou Elsoud A, Salama A, Al Adawy A (2021):** Limited Invasive Techniques in Management of Sander's Type II, III Calcaneal Fractures. *The Egyptian Journal of Hospital Medicine*, 85(2):3561-4.
 13. **Amani A, Shakeri V, Kamali A (2018):** Comparison of calcaneus joint internal and external fractures in open surgery and minimal invasive methods in patients. *European Journal of Translational Myology*, 28(2):7352-6.
 14. **Rammelt S, Sangeorzan B, Swords M (2018):** Calcaneal fractures—should we or should we not operate? *Indian journal of Orthopaedics*, 52(3):220-30.
 15. **Meng Q, Wang Q, Wu X *et al.* (2018):** Clinical application of the sinus tarsi approach in the treatment of intra-articular calcaneal fracture. *Medicine*, 97(13):e0175.
 16. **Shariatzadeh H, Valiollahi B, Mohammadpour M *et al.* (2020):** Outcomes of Minimally-Invasive Sinus Tarsi Approach for the Treatment of Intra-articular Calcaneal Fracture. *Journal of Research in Orthopedic Science*, 7(2):47-54.
 17. **Saß M, Rotter R, Mittlmeier T (2019):** Minimally invasive internal fixation of calcaneal fractures or subtalar joint arthrodesis using the Calcanail®. *Operative Orthopädie und Traumatologie*, 31(2):149-64.
 18. **Zhang G, Ding S, Ruan Z (2019):** Minimally invasive treatment of calcaneal fracture. *Journal of International Medical Research*, 47(8):3946-54.