

Alveolar Capillary Dysplasia in a Tertiary Center: A Case Report

Elaf Junainah*¹, Ela Alturkistani¹, Talal Almaghamsi¹, Mohammed Zuhdi Alimam¹,
Hamdi Alsufiani², Mohammed Junainah³, Ahmed Jamal³, Rotana Hammad⁴

¹Department of Pediatric Pulmonary Medicine, King Faisal Specialist Hospital and Research Center, Jeddah, KSA

²Department of Pediatric Pulmonary Medicine, Children Hospital at King Salman Medical City,
Al-Madinah Al-Monawarah, KSA

³Department of Pediatric Pulmonary Medicine, King Abdulaziz Hospital, Jeddah, KSA

⁴Department of Pediatric Pulmonary Medicine, King Fahd Armed Forces Hospital, Jeddah, KSA

*Corresponding author: Elaf Junainah, Mobile: 00966555096619, Email: elaf.junainah@hotmail.com

ABSTRACT

Background: Alveolar Capillary Dysplasia (ACD) is an exceedingly rare fatal and lethal developmental lung disorder mainly involving the major pulmonary vasculature, with a dismal prognosis. It usually presents in full term infants who develop respiratory distress on their first days of life as persistent pulmonary hypertension of the newborn (PPHN) that is unresponsive to treatment, and produces respiratory failure early in life. The majority of reported cases were found to be associated with other systemic anomalies, more frequently involving gastrointestinal system, as well as cardiovascular, urogenital, musculoskeletal, and right-left laterality anomalies. Since its first description, significant achievements in research have led to better understanding of the underlying molecular mechanism of ACD, and genetic studies have identified association with genomic alteration in the locus of the transcription factor FOXF1.

Objective: Here we present a case of female newborn who was referred to our tertiary center at the age of 5 months due to chronic hypoxia and failure to gain weight. Eventually, she was diagnosed as ACD.

Conclusion: ACD/MPV is a rare and lethal developmental disorder. Patients suffer from severe hypoxemia that progresses over time, although awareness is growing among physicians it can still be confused with idiopathic pulmonary hypertension as the presentation can be similar. This usually delays the diagnosis and leads to unnecessary suffering of patients and waste of hospitals resources. As soon as the diagnosis is suspected. Genetic testing should be done or histological exam should be performed, ideally before ECMO or even surgeries for CO occurring anomalies.

Keywords: Alveolar capillary dysplasia, Respiratory failure, Chronic hypoxia.

INTRODUCTION

Alveolar capillary dysplasia (ACD) is an exceedingly rare pathology involving the major pulmonary vasculature, with a dismal prognosis.

It usually presents in full term infants who develop respiratory distress on their first days of life. Most case reports are associated with other systemic anomalies, more frequently involving gastrointestinal system, as well as cardiovascular, urogenital, and musculoskeletal system^(1,2).

We present a case of female newborn who was referred to our tertiary center at the age of 5 months due to chronic hypoxia and failure to gain weight. Eventually, she was diagnosed as ACD.

CASE REPORT

Our patient is a 5 months old baby girl product of full-term pregnancy by spontaneous vaginal delivery (SVD) at another hospital, she had unremarkable antenatal history and normal pregnancy and maternal history, following her birth she was immediately admitted to neonatal intensive care unit (NICU) due to decreased oxygen saturation where she stayed in for 4 days on supportive therapy and did not require ventilation, she was discharged in stable condition by the end of 4th day.

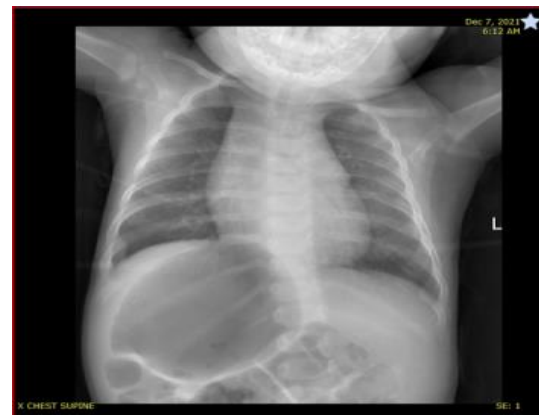

Fig. (1): Normal lung field bilaterally, dilated bowel in the left side, no pneumothorax.

The patient was stable until her mother noticed cyanosis while crying by the age of 2 months, which was described as bluish discoloration of lips, face and extremities when crying, and it would persist for at least 30 minutes after settling. Eventually, her mother opted to have a medical advice, where she was admitted for investigation of hypoxia and failure to gain weight, as she had gained only 0.5 kg since birth, after failing to reach to a diagnosis she was referred to our tertiary hospital to investigate the reason she is failing to thrive as a case of severe pulmonary hypertension on 1L oxygen and incomplete bowel obstruction.

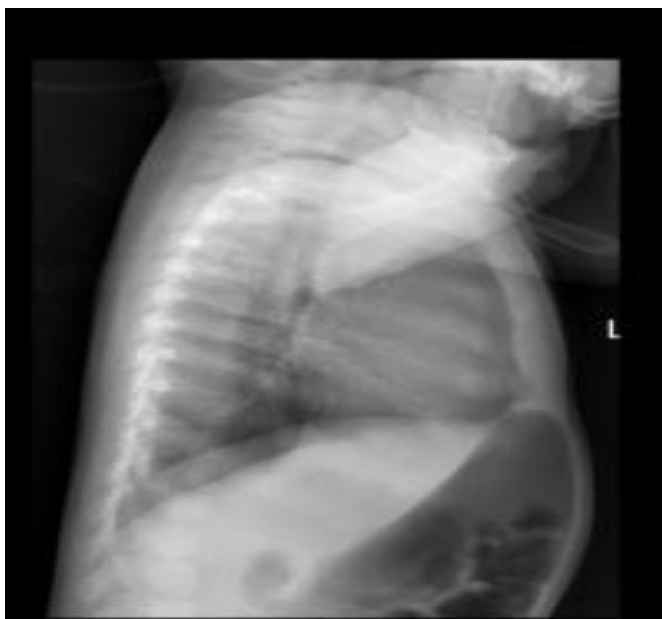

Fig. (2): Normal lung field, dilated bowel in the left side, no pneumothorax.

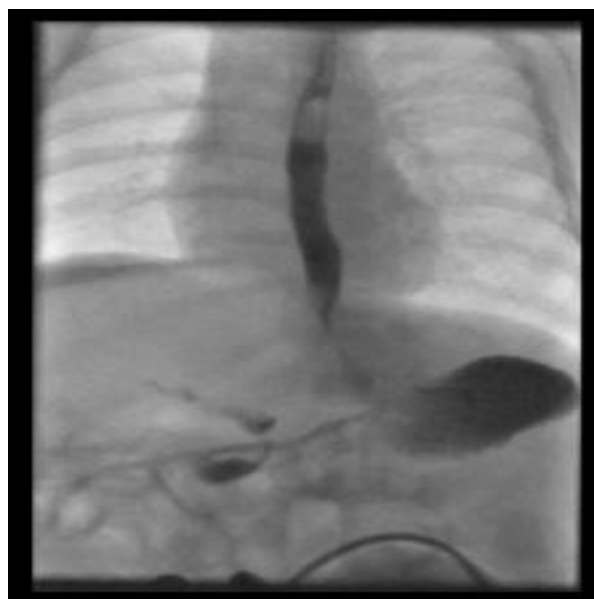


Fig. (3): Mild gastroesophageal reflux and evidence of malrotation with right-sided location of the proximal small bowel loops.

So, in our hospital X-rays and barium study was done, that showed mild gastroesophageal reflux and evidence of malrotation with right-sided location of the proximal small bowel loops. Markedly dilated bowel loop seen in the right upper quadrant most in keeping with a dilated third/fourth part of the duodenum, could be related to proximal jejunal or distal duodenal stenosis vs possibly annular pancreas. Surgical intervention could not be done as the patient went into pulmonary hypertension crisis and was started on nitrous oxide, diuretics, sildenafil and bosentan to control her condition.

During that time high resolution CT chest was done that showed bilateral diffuse ground-glass opacification, and a dilated air-filled bowel on the right side. By this time, Whole Exome sequence that was sent earlier came to be Positive for Alveolar capillary dysplasia FOXF1 exon 1 (c.841_862del) heterozygous mutation. Echo reported as severe pulmonary hypertension with aneurysmal atrial septum with fenestrated ASD shunting bidirectional mostly right to left with intact ventricular septum. Swallowing assessment was also done that showed aspiration with thin fluid

Declaration of patient consent:

An approval of the study was obtained from King Faisal Specialist Hospital and Research Center, Jeddah (Saudi Arabia) Academic and Ethical Committee. The parents of all children participants were informed that the case would be published as case report and this was accepted. This work has been carried out in accordance with The Code of Ethics of the World Medical Association (Declaration of Helsinki) for studies involving humans.

DISCUSSION

Since the first description of ACD in 1981 by Slot *et al.* ⁽³⁾ as a rare cause of persistent pulmonary hypertension, around 200 cases have been described so far in literature.

It presents as respiratory distress and cyanosis with pulmonary hypertension that is resistant to usual measures within the first day of life, with a mortality rate reaching 100%. Most important differential diagnosis includes pulmonary hypoplasia, idiopathic persistent pulmonary hypertension of the newborn (PPHN), and surfactant deficiency.

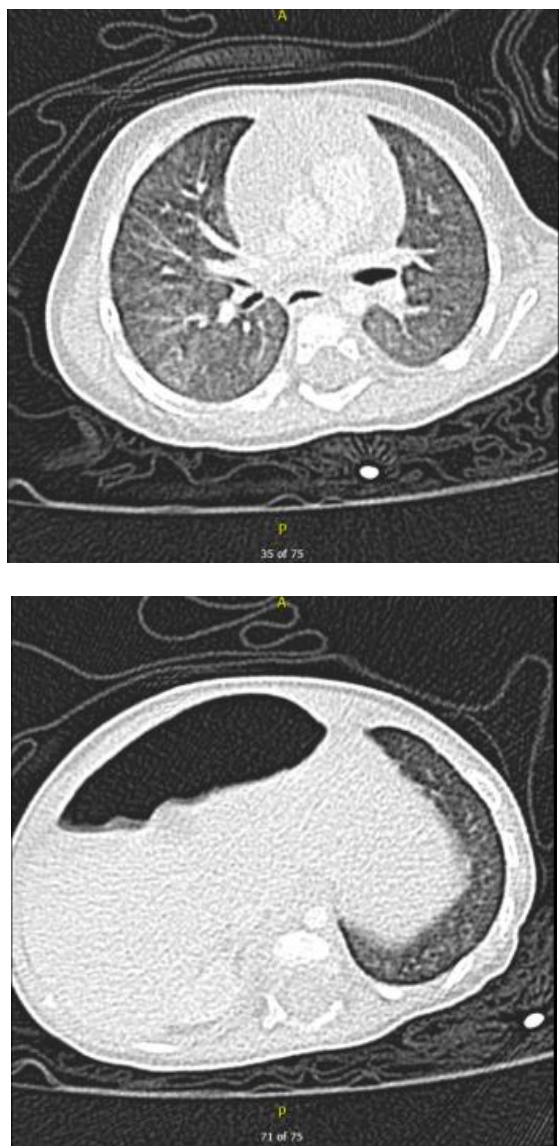


Fig. (4): Bilateral diffuse ground-glass opacification, and a dilated air-filled bowel on the right side.

In 2000, *Al-Hathlol et al.* ⁽⁴⁾ estimated the incidence of ACD to be 1/100,000 to 1/200,000, although the condition maybe underestimated as a diagnosis maybe done only on autopsy, and autopsies are not routinely done.

Patients with ACD are approached in a manner similar to other cases presenting with persistent pulmonary hypertension (PPHN) such as nebulized iloprost, nitric oxide, and inotropic support, however, ACD is characterized with a minimal to no response to all these measures, which should prompt clinical suspicion towards ACD ⁽⁵⁾. Echocardiography is usually utilized to exclude major cardio-vascular anomalies, and to confirm the diagnosis of pulmonary hypertension ⁽⁶⁾.

However, definitive and gold standard for diagnosis is achieved by histopathological examination of lung biopsy, which in most cases is done post mortem autopsy ⁽⁷⁾.

On gross pathological examination, due to the increased interstitial tissue, lungs appeared strikingly bulky with a significant increase in the lungs weight.

Histological features classically showed reduced number of alveolar capillaries, immature alveolar development, and hypertrophic smooth muscle cells in the pulmonary arterioles. Additionally, in normal histology the peripheral veins in the broncho-vascular bundle were positioned within the interlobular septa, while in majority of ACD cases they were located outside the interlobular septa adjacent to pulmonary arteries, which comprises a phenomena called “misalignment of the pulmonary veins” ⁽³⁾.

Currently, there is no specific treatment for ACD, and management is usually aimed to target the PPHN. As with other cases of persistent pulmonary hypertension, the management of ACD is usually supportive, consisting of clinical respiratory and cardiovascular support with the use of vasodilating medications to control the pulmonary hypertension. In majority of cases, immediate intubation and mechanical ventilation are required at the time of presentation due to the significantly low oxygen saturation levels ⁽⁸⁾.

Extra-Corporeal Membrane Oxygenation (ECMO) therapy may be used to stabilize patients in critical conditions and when diagnosis is not made yet. However, ECMO may lead to some unwanted outcomes, as most patients of ACD are unable to wean off ECMO once placed on it with the addition of its invasiveness and high cost ⁽⁹⁾.

FOXF1 and ACD/MPV first described in 1994, FOXF1 is a member of the Forkhead box transcription factors (TFs) and carries an important role in embryologic lung development ⁽¹⁰⁾.

A link between ACD and FOXF1 was suggested by *Stanckiewicz and Shaw-Smith* ⁽¹¹⁾, and in their sample of 141 patients they clearly identified 86 pathogenic variants that were involving FOXF1 gene. In addition, heterozygous genomic variants in the FOXF1 locus of ACD patients have been reported by many other research groups as well.

CONCLUSION

ACD/MPV is a rare and lethal developmental disorder. Patients suffer from severe hypoxemia that progresses over time, although awareness is growing among physicians it can still be confused with idiopathic pulmonary hypertension as the presentation can be similar. This usually delays the diagnosis and leads to unnecessary suffering of patients and waist of hospitals resources. As soon as the diagnosis is suspected. Genetic testing should be done or histological exam should be performed, ideally before ECMO or even surgeries for CO occurring anomalies. Although, survival rates are low there are case reports for patients surviving up to 39 months without transplant, prenatal and postnatal genetic testing could contribute to earlier detection, which may allow adequate consultation about prognosis and decision making

Financial support and sponsorship: Nil.

Conflict of interest: Nil.

REFERENCES

1. **Miranda J (2013):** Alveolar Capillary Dysplasia with Misalignment of Pulmonary Veins (ACD/MPV): A Case Series. <https://doi.org/10.1155/2013/327250>
2. **Roy G (2007):** Alveolar capillary dysplasia presenting as pneumothorax: a case report and review of literature. *Pediatric Surgery International*, 23: 915-917.
3. **Slot E (2018):** Alveolar capillary dysplasia with misalignment of the pulmonary veins: clinical, histological, and genetic aspects. *Pulmonary Circulation*, 8 (3): 1-8.
4. **Al-Hathlol K (2000):** Alveolar capillary dysplasia Report of a case of prolonged life without extracorporeal membrane oxygenation (ECMO) and a review of the literature. *Early Human Development*, 57: 85-94.
5. **Bishop N, Stankiewicz P, Steinhorn R (2011):** Alveolar Capillary dysplasia. *American Journal of Respiratory and Critical Care Medicine*, 184 (2): 172–179.
6. **Miranda J, Rocha G, Soares H et al. (2013):** Alveolar capillary dysplasia with misalignment of pulmonary veins (ACD/MPV): a case series. *Case Rep Crit Care*, 13: 327250.
7. **Sen P, Thakur N, Stockton D et al. (2004):** Expanding the phenotype of alveolar capillary dysplasia (ACD). *J Pediatr.*, 145: 646–651.
8. **Cullinane C, Cox P, Silver M (1992):** Persistent pulmonary hypertension of the newborn due to alveolar capillary dysplasia. *Pediatr Pathol.*, 12: 499–514.
9. **Ng P, Lewindon P, Siu Y et al. (1995):** Congenital misalignment of pulmonary vessels: an unusual syndrome associated with PPHN. *Acta Paediatr.*, 84: 349–353.
10. **Stankiewicz P, Sen P, Bhatt S et al. (2009):** Genomic and genic deletions of the FOX gene cluster on 16q24.1 and inactivating mutations of FOXF1 cause alveolar capillary dysplasia and other malformations. *Am J Hum Genet.*, 84: 780–791.
11. **Prothro S, Plosa E, Markham M et al. (2016):** Prenatal diagnosis of alveolar capillary dysplasia with misalignment of pulmonary veins. *J Pediatr.*, 170: 317–318.