

Endovascular Embolization of Ruptured Intracranial Arteriovenous Malformation: A Retrospective Analytic Study

Adel Saad Ismaeil, Ahmed Mohamed Alawamry, Mohamed Salah Mohamed, Abdulaziz Salim Sultan*, Mohamed Ezzat Alsayed

Department of Neurosurgery, Faculty of Medicine, Zagazig University, Egypt

*Corresponding author: Abdulaziz Salim Sultan, Mobile: (+20) 01552084004, Email: azizsaleem43@gmail.com

ABSTRACT

Background: Endovascular embolization is one of the main modalities in the treatment of ruptured intracranial arteriovenous malformations (AVMs). The endovascular approach to AVM using different embolizing agents is a well-established treatment strategy.

Objective: This study aimed at evaluating of the efficacy of endovascular embolization of AVM using detachable-tip microcatheters and Onyx 18®.

Patients and methods: This retrospective study was conducted at the Department of Neurosurgery Zagazig University on 40 patients suffering from ruptured AVMs and underwent procedural intervention during the period from 2018 to 2020 for evaluation of the efficacy of endovascular embolization of AVM using detachable-tip microcatheters and Onyx 18®. The interventional procedures for treatment of cerebral AVMs included the following procedures either in solitary or combined fashions; endovascular embolization and stereotactic radiosurgery.

Results: AVM patients were 28 males (70.0%) and 12 females (30.0%), the mean age of all patients was 27 ± 0.4 years; all of them presented with spontaneous intracranial hemorrhage, 40.0% had associated neurological problem. About 65.0% of patients presented with bad grade by modified Rankin Scale (mRS). MVA were graded according to Buffalo score ranged from 1 to 4 with median 2 and about 47.5 % of patients had Buffalo 2. While Spetzler-Martin's grading ranged from 2 to 5 with median 3 and about 47.5% of patients had SMG 3. Obliteration percent was 90 ranged from 70% to 100% with median 90%.

Conclusion: The application of Onyx in ruptured intracranial arteriovenous malformations is flexible, effective and safe. Onyx provides the opportunity to adjust the treatment to each individual patient.

Keywords: Endovascular embolization, Intracranial Arteriovenous, Microcatheters.

INTRODUCTION

Direct contact between one or more arteries and veins causes a variety of issues in cerebral arteriovenous malformations (AVMs). The fact that veins often have weak walls and cannot sustain prolonged high-pressure blood flow is the most critical issue. As a result, AVMs may burst and cause brain bleeding ⁽¹⁾.

The risk of further bleeding after an AVM ruptures rises to 6 to 18 percent during the first year before falling to 2 to 4 percent annually, which is the hemorrhage rate of previously identified, unruptured AVMs. There is a higher risk of bleeding when an AVM is connected to an aneurysm, according to earlier research. It is commonly known that cerebral aneurysms and AVMs are related. Depending on the case series, 3-58 percent of individuals with AVMs had aneurysms ⁽²⁾. AVM treatment includes medical management, surgical, endovascular, and radiosurgical modalities ⁽³⁾.

In low-grade AVMs, embolization alone may be a curative and safe alternative to neurosurgical or radiosurgical methods. Embolization is often performed to lower the size of big AVMs, to improve the safety of surgery, or to make the AVM receptive to radiosurgery ⁽⁴⁾.

For the majority of patients, endovascular embolization is typically sufficient to cure dural arteriovenous fistulas (DAVF). During endovascular embolization, a catheter is passed through the groin up into the arteries in the brain that lead to the DAVF to

inject a material into these arteries. This injection shuts off that artery and reduces the flow of blood through the DAVF ⁽¹⁾.

Onyx (ethylene-vinyl alcohol copolymer) is a lava-like, non-adhesive embolic agent and has several advantages over acrylic glue. It permits theoretically slower filling, better penetration, and obliteration of the nidus, providing a solid nidus cast due to its longer polymerization time and lack of adherence ⁽⁵⁾.

Several individual predictors of a poor outcome after intracranial AVM rupture have been reported ⁽⁶⁾. The study of **Shotar et al.** ⁽⁷⁾ reported that, intracranial AVM rupture is associated with high morbidity and mortality. After 139 hemorrhagic events, the authors observed a 43.2% rate of poor outcome, defined as an mRS score ≥ 3 beyond 1 year after admission. Comparable rates of death and dependence (40%) after AVM rupture have been reported by the Scottish Intracranial Vascular Malformation Study ⁽⁸⁾.

Therefore, this study aimed to evaluate the efficacy of endovascular embolization of AVM using detachable-tip microcatheters and Onyx 18®.

PATIENTS AND METHODS

This retrospective study was conducted on 40 patients that underwent procedural intervention (using one or more of the aforementioned procedures) for treatment of cerebral AVMs at Zagazig University Hospitals with standard indications. The mean age of the

patients at the time of intervention was 27 ± 10.4 years and it ranged (11-60) years. We categorized patients according to age into three groups; young aged (<18 years), middle aged (18 - 50 years) and old aged (>50 years) patients, (30 %) were female and (70 %) were male.

AVM data:

As regard AVM data, the ruptured cerebral AVMs involved in our study were categorized according to the size of the nidus into **3 groups**: Small (<3 cm), Medium (3-6 cm) and Large (>6 cm).

Inclusion criteria: were specified for each procedural intervention independently.

i. Endovascular embolization:

- 1-AVM has an appropriate endovascular access to the nidus.
- 2-Patient is not fit for surgery.
- 3-Patient refusing other modalities.
- 4-Presence of clinical indicator for embolization treatment: Reduction of neurological deficit due to steal, and decrease the intensity of headache.
- 5-AVM is not surgically accessible.

ii. Stereotactic radiosurgery:

- 1- Patient is not fit for surgery.
- 2- Patient refusing other modalities.
- 3- AVM is not surgically accessible.
- 4- AVM size is appropriate for radiosurgery.
- 5- AVM is considered low risk of hemorrhage during the latency period radiosurgery.
- 6- AVM nidus is diffuse.

iii. Combined approach (Embolization followed by radiosurgery):

- 1- Patient is not fit for management by single modality.
- 2- Need for preoperative obliteration of deep feeding vessels.
- 3- Need for reduction in the volume of the AVM nidus before radiosurgery.
- 4- Need for obliteration of external carotid feeders before radiosurgery.

Exclusion criteria:

- 1- Extremes of age (younger than 2 years and older than 80 years)
- 2- Poor medical condition
- 3- Unruptured intracranial AVM.

i. Endovascular embolization:

- 1- Patient is fit for another single modality.
- 2- Patient declined embolization.
- 3- Complicated vascular anatomy.

ii. Stereotactic radiosurgery:

- 1-AVM is surgically accessible.
- 2-Need for rapid eradication of the risk of hemorrhage.
- 3-AVM nidus is too large for radiosurgery.

iii. Combined approach:

- 1-Patient is fit for single modality management.
- 2-Patient is designated for conservative management.

Ethical consent:

An approval of the study was obtained from Zagazig University Academic and Ethical Committee. Every adult patient and caregiver of child patient signed an informed written consent for acceptance of participation in the study. This work has been carried out in accordance with The Code of Ethics of the World Medical Association (Declaration of Helsinki) for studies involving humans.

All patients were assessed clinically before treatment by history taking as well as general and neurological examination. Data were collected in a standardized patient's sheet.

History taking: with special focus on the presenting symptom.

General examination: with special attention to the manifestation of systemic disease.

Neurological examination: motor power assessment, cranial nerves and speech.

The modified Rankin Score (mRS) was recorded for each patient before intervention. This translates the preinterventional neurological condition of the AVM patients.

Laboratory investigations: Routine laboratory investigations were done to all patients including complete blood count (CBC), prothrombin time (PT), partial thrombin time (PTT), liver function test (LFT), renal function test (RFT), and serum electrolytes. In addition some extra investigations were done when needed.

Radiological evaluation: Computerized tomography, CT scan was done for all patients, **MRI, MRA and MRV** were done for all patients, **3D-CT Angiography.**

Clinical outcome:

Early postinterventional neurological status (after recovery) was assessed and the early modified Rankin Score (mRS) was recorded for each patient. Outcomes were analyzed in terms of change between preoperative and final postoperative by Glasgow outcome score into: 1) excellent and good outcome. 2) moderate disability, severe disability, dead or by mRS scores into 2 categories: 1) favorable outcome (improvement and no or minor deterioration), 2) unfavorable outcome (moderate deterioration, major deterioration and death).

Statistical analysis

The collected data were coded, processed and analyzed using the SPSS (Statistical Package for the

Social Sciences) version 22 for Windows® (IBM SPSS Inc, Chicago, IL, USA). Qualitative data were represented as frequencies and relative percentages. Quantitative data were expressed as mean ± SD (Standard deviation), range, and median.

RESULTS

The studied AVM patients were 28 males and 12 females, the mean age of all patients was 27± 10.4 years (Table 1).

Table (1): Demographic characteristics of AVM patients (n= 40)

Variables	n= 40	
Age per years:		
• Mean ±SD	27± 10.4	
• (Range)	(11—60)	
	N	%
Sex:		
• Male	28	70.0
• Female	12	30.0
• Males/females ratio	2.3:1	

All arteriovenous malformation patients presented with spontaneous intracranial hemorrhage and 16 patients had associated neurological problem (Table 2).

Table (2): Clinical characteristics of AVM patients (n=40)

	Number	Percent
Clinical presentation		
Spontaneous intracranial hemorrhage	40	100.0
Associated neurological problem		
No	24	60.0
Neuro deficit	6	15.0
Seizure	10	25.0
Previous history of cranial hemorrhage		
No	37	92.5
Yes	3	7.5
Previous treatment modality		
Yes (Endovascular Embolization)	3	7.5
Comorbidities		
No	36	90.0
Yes	4	10.0
Types		
DM	1	2.5
HTN	2	5.0
HTN and DM	1	2.5

Neurological conditions of all the patients were assessed pretreatment and scaled according to Glasgow coma scale (GCS). 85% of patients were of mild grade. In addition: median modified Rankin Scale (mRS) was 3; 65% of patients were with bad grade (Table 3).

Table (3): Neurological assessment of AVM patients (n=40)

	Number	Percent
GCS		
Mild	34	85.0
Moderate	6	15.0
Median (range)	14 (12-15)	
Grades of modified Rankin Scale (mRS) pre treatment		
Favorable	14	35.0
Bad	26	65.0
Median (range)	3 (1-4)	

About 10 patients had parietal AVMs and 8 patients had occipital AVMs. As regard AVMs size the majority (62.5%) had medium size (Figures 1 and 2).

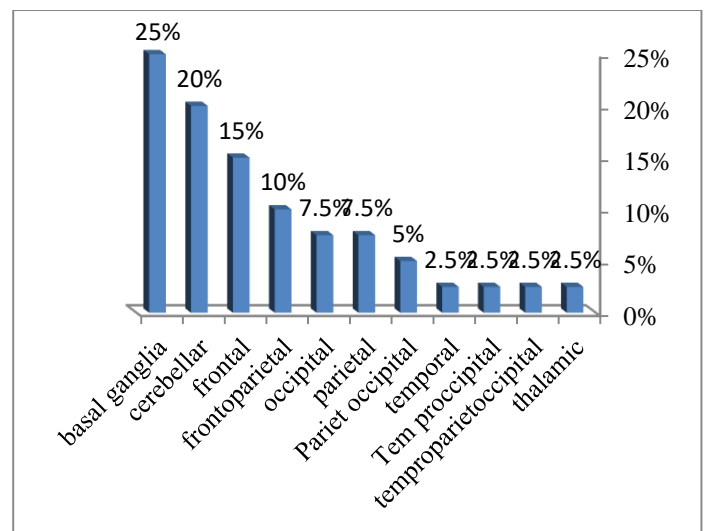


Fig. (1): Bar chart showing distribution of the studied patients according to site of arteriovenous malformation (n=40).

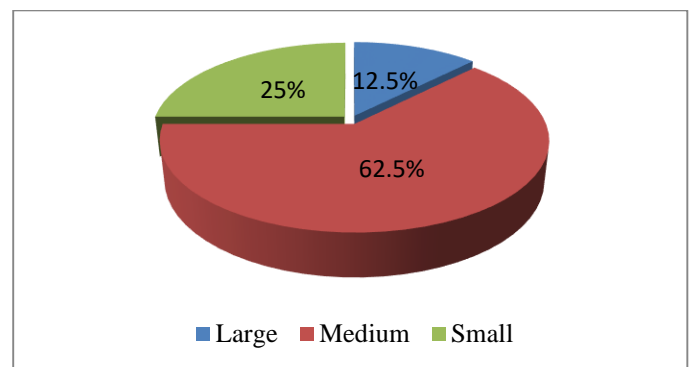


Fig. (2): Pie chart showing distribution of the studied patients according to size of arteriovenous malformation (n=40)

Regarding arteriovenous malformation patients grading, AVM were graded according to Buffalo score, about 47.5 % of patients had Buffalo 2. While regarding Spetzler-Martin's grading about 47.5% of patients had SMG 3 (Table 4).

Table (4): distribution of patients according to Buffalo score and Spetzler-Martin grading (SMG) (n=40)

	Number	Percent
Buffalo score		
1.00	5	5.0
2.00	19	47.5
3.00	13	27.5
4.00	3	15.0
Median (range)	2 (1-4)	
Spetzler-Martin's grading (SMG)		
2.00	7	5.0
3.00	20	47.5
4.00	8	27.5
5.00	5	15.0
Median (range)	3 (2-5)	

The outcome of interventional procedure being used for the management of the cerebral AVMs; was complete occluded among 82.5% of patients. Median obliteration percent was 90 (Table 5).

Table (5): Outcome of endovascular embolization for arteriovenous malformation patients (n=40)

	Number	Percent
Radiological outcome		
Complete	33	82.5
Residual	7	17.5
Obliteration percent		
70.00	5	12.5
80.00	10	25.0
90.00	11	27.5
100.0	13	32.5
Median (range)	90 (70-100)	

DISCUSSION

Congenital vascular lesions known as intracranial arteriovenous malformations (AVMs) have a high risk of long-term morbidity, chiefly from the possibility of bleeding and seizures. A danger of iatrogenic harm to deep or expressive brain areas exists with treatment of these lesions. According to meta-analyses of extensive AVM case series, up to 7.4% of patients having microsurgery for AVM excision may experience serious side effects (9).

Endovascular embolization could serve as a curative option for AVM treatment with accepted morbidity and mortality (10). Procedural safety was evaluated by assessing the periprocedural complications occurring within 1 month after embolization. Any deficit that resolved within the first 30 days was characterized as transient. Any deficit that persisted beyond 30 days was considered permanent. An mRS score of ≤ 2 indicated a non-disabling deficit. An mRS score of ≥ 3 indicated a disabling deficit. Periprocedural-related death was defined as any death occurring within 30 days after the procedure (11, 12).

The current study showed that arteriovenous malformation patients were 28 males (70.0%) and 12 females (30.0%), the mean age of all patients was 27±

10.4 years and ranged from 11 to 60 years, while the **Alshehri et al.** (13) reported that among the 29 patients, 21 (72.4%) were males and 8 (27.6%) were females with a mean age of 40 years.

The current was a study on 40 patients suffering from ruptured arteriovenous malformation presented with spontaneous intracranial hemorrhage patients. 16 patients (40.0%) had associated neurological problem (6 neurological deficit, and 10 seizure). Previous history of treatment by endovascular embolization was for 3 patients (7.5%). Comorbidity was mainly HTN among 2 patients (5%). In comparing with **Alshehri et al.** (13), they reported that 13.8% of the patients were hypertensive, 3.4% were diabetic, 6.9% were smokers, 3.4% were hypertensive and smokers, 13.8% were diabetic and hypertensive, and 3.4% had coronary artery disease (CAD) with diabetes. The remaining 55.2% had no significant risk factors. At the time of diagnosis, 51.7% of the patients presented with headache, 17.2% with seizure, and 31% with sensorimotor defects. **Sato et al.** (12) reported that there were 548 patients (69.5%) had hemorrhage, 130 patients (16.5%) had nonhemorrhagic neurologic deficit (NHND) and 110 (14.0%) were asymptomatic. While **Hartmann et al.** (14) reported that arteriovenous malformation patients represented with intracranial hemorrhage in 93 patients (40%), 74 patients (30%) had seizure, 40 patients (17%) had headache, 11 patients (5%) had focal deficit and other/asymptomatic in 15 patients (6%).

The current study showed that neurological conditions of all the patients were assessed pretreatment and scaled according to Glasgow coma scale (GCS), which ranged from 12-15 with median 14 (85% of patients of mild grade). In addition: modified Rankin Scale (mRS): ranged from (1-4) with median 3 (65.0% of patients with bad grade), comparing with **Hartmann et al.** (14) who reported that by baseline Rankin score, 89% of the patients had no functionally relevant neurological deficit (Rankin score=0 or 1), and 94% were nondisabled (Rankin score ≤ 2). A total of 33 patients showed treatment-related new neurological deficits, including 5 with disabling deficits. By Rankin scale, 200 patients experienced no change in neurological status after treatment, and 92% were non-disabled. Of the 200 patients who experienced no change in functional status, 41 (18%) had a preexisting neurological deficit that remained unchanged after endovascular therapy. **Mohram et al.** (15) reported that modified Rankin Scale (mRS) ranged from 0 to 4, 9 patients (36.0%) had grade 0, 8 patients (32.0%) had grade 1, 4 patients (16.0%) had grade 2, 3 patients (12.0%) had grade 3 and one patient (4.0%) had grade 4. While **Elewa** (10) reported that regarding modified Rankin Scale, 16 patients (76.2%) were at grade 1, 4 patients (19.0%) were at grade 2, and 1 patient (4.8%) was at grade 3.

The current study showed that AVM location was parietal in 25.0% and occipital in 20.0% patients and the size was distributed as follow; 12.5%, 62.5%, 25.0%

had large, medium and small size respectively. Comparing with **Mohram et al.** ⁽¹⁵⁾ they reported that 10 patients (40%) had frontal AVMs, 2 patients (8%) had parietal AVMs, 5 (20%) had occipital, 2 patients (8%) had frontoparietal, one patient (4%) had frontotemporal, 2 patients (8%) had occipitoparietal, 3 patients (12%) had cerebellar. **Sato et al.** ⁽¹²⁾ reported that there were 443 patients (56.2%) had size < 3 cm, 278 (35.3%) had size 3-6 cm and 38 (3.8%) had size > 6 cm. The current study showed that arteriovenous malformation were graded according to Buffalo score ranged from 1 to 4 with median 2 and about 47.5 % of patients had Buffalo 2. While Spetzler-Martin's grading ranged from 2 to 5 with median 3 and about 47.5% of patients had SMG 3. While **Mohram et al.** ⁽¹⁵⁾ reported that Buffalo score ranged from 1 to 4, where 9 patients (36%) had grade 1, 7 patients (28%) had grade 2, 7 patients (28%) had grade 3, 2 patients (8%) had grade 4. While Spetzler-Martin's grading ranged from I to V, where 17 patients (68%) had grade I-II, 5 patients (20%) had grade III, and 3 patients (12%) had grade IV- V.

CONCLUSION

Cerebral arteriovenous malformations are considered a significant risk factor for hemorrhagic stroke in young adults. Management strategies for cerebral arteriovenous malformations include single or combined therapy applying endovascular techniques alone or followed by radiosurgery. The aim of treatment is total obliteration of the malformation, because subtotal therapy does not confer protection from hemorrhage.

Several factors are considered in the decision to treat an AVM, such as symptoms, medical condition, age of the patient, history of HTN, the history of hemorrhage, the size and location of the AVM, the type of venous drainage, and the natural history of lesion in general.

Endovascular embolization used as a curative tool alone or followed by stereotactic radiosurgery. Endovascular approach should be considered for ruptured AVMs or symptomatic AVMs with higher hemorrhagic risk. The endovascular treatment of the cerebral AVMs is safe, effective and can achieve high rates of total and near total occlusion.

Conflict of interest: The authors declare no conflict of interest.

Sources of funding: This research did not receive any specific grant from funding agencies in the public, commercial, or not-for-profit sectors.

Author contribution: Authors contributed equally in the study.

REFERENCES

1. **Consoli A, Renieri L, Nappini S et al. (2013):** Endovascular treatment of deep hemorrhagic brain

arteriovenous malformations with transvenous onyx embolization. *American Journal of Neuroradiology*, 34(9):1805-1811.

2. **Flores B, Klinger D, Rickert K et al. (2014):** Management of intracranial aneurysms associated with arteriovenous malformations. *Neurosurg Focus*, 23: 4-15.
3. **Derdeyn C, Zipfel G, Albuquerque F et al. (2017):** American Heart Association Stroke Council. Management of brain arteriovenous malformations: A scientific statement for healthcare professionals from the American Heart Association/American Stroke Association. *Stroke*, 48(8): 200-224.
4. **Wu E, El Ahmadih T, McDougall C et al. (2019):** Embolization of brain arteriovenous malformations with intent to cure: a systematic review. *J Neurosurg.*, 132(2):388-399.
5. **Aoude A, Ghanaati H, Faghih Jouibari M et al. (2017):** Embolization of intracranial arteriovenous malformations using Onyx in 53 patients. *Iran J Radiol.*, 14(3):696-99.
6. **Lv X, Liu J, Hu X et al. (2015):** Patient age, hemorrhage patterns, and outcomes of arteriovenous malformation. *World Neurosurg.*, 84:1039-1044.
7. **Shotar E, Debarre M, Sourour N et al. (2018):** Retrospective study of long-term outcome after brain arteriovenous malformation rupture: the RAP score. *JNS.*, 128: 78-85.
8. **Van Beijnum J, Lovelock C, Cordonnier C et al. (2009):** Outcome after spontaneous and arteriovenous malformation-related intracerebral haemorrhage: population-based studies. *Brain*, 132: 537-543.
9. **Feng A, Sussman E, Jin M et al. (2021):** Intraoperative neuromonitoring for cerebral arteriovenous malformation embolization: a propensity-score matched retrospective database study. *Cureus*, 13(1): 1-4.
10. **Elewa M (2018):** Cerebral arteriovenous malformations in the era of embolization for angiographic cure: a single-center experience in Egypt. *The Egyptian Journal of Neurology, Psychiatry and Neurosurgery*, 54(1): 1-8.
11. **He Y, Ding Y, Bai W et al. (2019):** Safety and efficacy of transvenous embolization of ruptured brain arteriovenous malformations as a last resort: A prospective single-arm study. *American Journal of Neuroradiology*, 40 (10): 1744-175.
12. **Sato K, Matsumoto Y, Tominaga T et al. (2020):** Complications of endovascular treatments for brain arteriovenous malformations: A nationwide surveillance. *American Journal of Neuroradiology*, 41(4): 669-675.
13. **Alshehri F, Mail N, Okal F et al. (2020):** Assessment of different modalities and their impact on patients with ruptured intracranial arteriovenous malformation treated in King Abdulaiziz Medical City in Jeddah, Saudi Arabia. *Cureus*, 12(2): 124-129.
14. **Hartmann A, Pile-Spellman J, Stapf C et al. (2002):** Risk of endovascular treatment of brain arteriovenous malformations. *Stroke*, 33(7): 1816-1820.
15. **Mohram H, Habib M, Mourad S et al. (2018):** Outcome of endovascular treatment of cerebral arteriovenous malformations with ethylene vinyl alcohol copolymer. *The Egyptian Journal of Hospital Medicine*, 73(3): 6283-6290.