

DIAGNOSTIC ACCURACY OF WIDTH-TO-LENGTH RATIO IN DIFFERENTIATING BETWEEN MANDIBULAR AMELOBLASTOMAS AND ODONTOGENIC KERATOCYSTS

Sally S. Awad ^{*}, Mohamed A. Tawfik ^{**}, Heba Tawfik ^{***},
Amir M. Zaid ^{****} and Amira A.M.M. Attia ^{*****}

ABSTRACT

Background: Odontogenic tumors and cysts are benign lesions that can arise in any site of the jaws, with Ameloblastomas (ABs) and odontogenic keratocysts (OKCs) being the lesions characterized by local aggressiveness and a high recurrence rate.

Aim of the study: The current study aimed to validate the efficacy of using the width-to-length ratio as a diagnostic radiographic feature to distinguish mandibular ameloblastomas and odontogenic keratocysts.

Patients and methods: Twenty cases were selected for each lesion type. The axial views from cone-beam computed tomography (CBCT) were retrospectively reviewed to determine the width-to-length ratio, which was calculated by determining the ratio between the utmost buccolingual width and the utmost perpendicular anteroposterior length of the lesion. Student's *t*-test (unpaired) was used to compare the mean ratios of the two lesion types. Statistical significance was set at $P < 0.05$.

Results: The mean width-to-length ratios of ameloblastomas and keratocysts were 0.74 and 0.42, respectively. The cutoff point for discriminating the two lesion types was 0.50. The ratios for ameloblastomas were significantly greater than for odontogenic keratocysts ($P < 0.001$).

Conclusion: The width-to-length ratio is a valid imaging feature that can be used for the differentiation of ABs and OKCs in the body of the mandible.

KEYWORDS: Cone-Beam Computed Tomography. Mandible. Odontogenic tumors. Odontogenic Keratocysts. Diagnostic Imaging.

* Associate professor, Oral & Maxillofacial Surgery Department, Faculty of Dentistry, Mansoura University, Egypt.

** Professor, Oral & Maxillofacial Surgery Department, Faculty of Dentistry, Mansoura University, Egypt.

*** Associate professor, Oral & Maxillofacial Surgery Department, Faculty of Dentistry, Hours University, Egypt.

**** Assistant professor, Surgical Oncology Department, Faculty of Medicine, and Oncology center, Mansoura University, Egypt.

***** Assistant professor, Oral & Maxillofacial Surgery Department, Faculty of Dentistry, Mansoura University, Egypt.

INTRODUCTION

Ameloblastomas and odontogenic keratocysts are benign odontogenic lesions that can arise in any site of the jaws, but they are mainly observed in the posterior part of the mandibular body and ramus.¹ The two lesion types are characterized by local aggressiveness and a high recurrence rate.^{2,3}

ABs represent approximately 11%–18% of all odontogenic tumors and they are the second most common after odontomas.⁴ OKCs represent the third most common oral cysts. In 2005, the World Health Organization (WHO) classified this lesion type as a keratocystic odontogenic tumor (KCOT) due to its destructive behavior. In 2017, the WHO returned the KCOT classification back to classification as a cystic lesion known as the odontogenic keratocyst.³

The two lesion types have several radiologic features that make it difficult to distinguish them on diagnostic images. The difference in bone expansion patterns was reported by MacDonald-Jankowsky.⁵ OKCs have a fusiform growth pattern, where ABs have a ballooning pattern. This difference can be used as a radiographic feature for the differentiation of the two lesion types.⁶ Many previous studies have specified some radiographic features as useful in the diagnosis of ABs and OKCs, such as buccolingual expansion, internal density, and root resorption of neighboring teeth.⁷⁻⁹

Omami and Adel¹⁰ is the only study that analyzed buccolingual expansion in relation to the anteroposterior dimension of a lesion and proposed a width-to-length ratio as a measure from CBCT that can be used to distinguish between the two lesion types in the mandibular body. They compared the ratios of the two lesions types and set a cutoff point at 0.5 with which the two lesions could be distinguished so that lesions with a ratio < 0.5 (i.e., in which the buccolingual width was $< 50\%$ of the anteroposterior length) were mostly OKCs, whereas lesions with a ratio > 0.5 were in all probability ABs.

To evaluate the accuracy of a prediction model, external validation is required. A model or formula is designed using development data and it may show excellent results for the development population but could perform poorly for an external cohort.¹¹

Therefore, the purpose of this study was to validate the efficacy of measuring the width-to-length ratio and using a cutoff value of 0.5 in a patient cohort to distinguish between mandibular ABs and OKCs with axial CBCT.

PATIENTS AND METHODS:

DICOM data from the patients with ABs (conventional) and OKCs in the mandible were retrospectively retrieved from the Department of Oral and Maxillofacial Surgery, Faculty of Dentistry between 2012 and 2020. Data from 40 patients were included in the study (20 patients had ABs and 20 had OKCs) according to the following inclusion criteria: 1) presence of high-quality images with no artifacts and complete clinical records of the patients; 2) histological confirmation of the lesions; and 3) lesions in the mandibular body not extending to the ramus. Recurrent lesions were excluded from this study.

A Dell monitor [LED full HD 27 inch, 1920 × 1080 pixels (Dell E2720HS; Dell Inc., Round Rock, TX, USA)] was used to view all images. The software On-Demand 3D (Cybermed Inc.; Seoul, Republic of Korea) was used to visualize CBCT Digital Imaging.

A single examiner (an oral and maxillofacial surgeon) recorded quantitative measurements twice in 4-week intervals, and the mean measurements were used for analysis. The width-to-length ratio, as described by Omami and Adel,¹⁰ was used to assess the expansion difference between the lesions. It was calculated by measuring the ratio between the utmost width of the lesion and the utmost perpendicular length to this width on an axial view from CBCT (Figure1). The study followed the

principles of the Declaration of Helsinki on medical research protocols and ethics and was approved by the Institutional Review Board. A waiver of consent was requested because this was a retrospective study, and data were anonymous and coded.

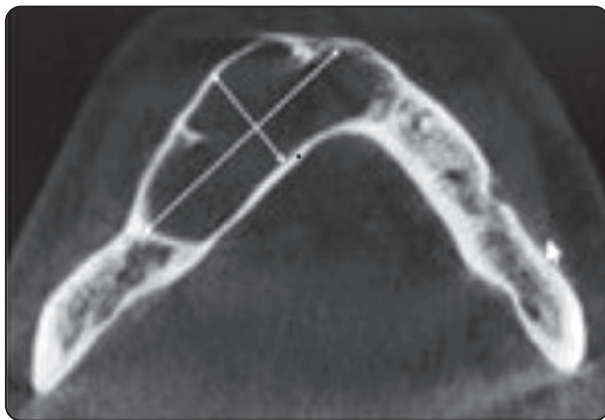


Fig (1) Keratocyst. Axial view of cone-beam computed tomography image showing a width-to-length ratio of $1.5/3.92 = 0.38$.

Statistical analysis

Data were analyzed with the Statistical Package for Social Science software computer program version 26 (SPSS, Inc., Chicago, IL, USA) and were presented as the mean and standard deviation. The two groups were compared with Student’s t-test (unpaired). *P*-values of ≤ 0.05 were considered statistically significant.

Measures of diagnostic performance using the cutoff point 0.5 were done by using an online calculator (Online Confusion Matrix) (<https://onlineconfusionmatrix.com>) where Sensitivity = $TP / (TP + FN)$, Specificity = $TN / (FP + TN)$, PPV = $TP / (TP + FP)$, NPV = $TN / (TN + FN)$, Accuracy = $(TP + TN) / (TP + FP + TN + FN)$, F1 score = $2TP / (2TP + FP + FN)$, and MCC = $(TP * TN - FP * FN) / \sqrt{[(TP+FP) * (TP+FN) * (TN+FP) * (TN+FN)]}$. Clinical utility was determined with the Clinical Utility Index Calculator¹² where CUI+ = Sensitivity * PPV, and CUI- = Specificity * NPV. Clinical utility was considered excellent, good, fair,

poor, and very poor if the index was ≥ 0.81 , ≥ 0.64 and < 0.81 , ≥ 0.49 and < 0.64 , ≥ 0.36 and < 0.49 , and < 0.36 , respectively.

RESULTS

The study included 40 cases: 20 cases of ABs, with a mean age of 30.95 ± 13.62 years and a male: female ratio of 11:9; and 20 cases of OKCs with a mean age of 31.40 ± 11.55 years and male: female ratio of 14:6.

The ABs and OKCs had a mean width-to-length ratio of 0.74 and 0.42, respectively, as shown in (Figure 2). The ratio of ABs was significantly higher than that of OKCs (*P* < 0.001, Table 1).

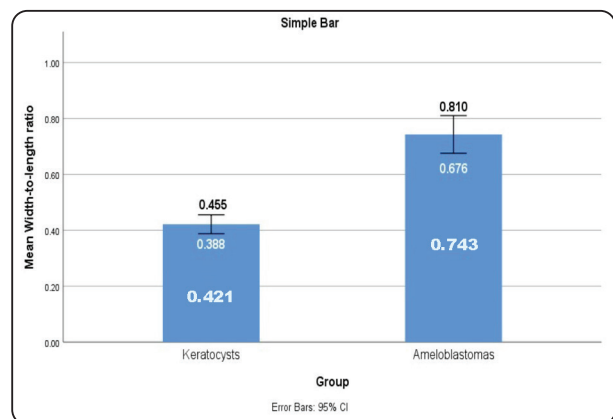


Fig (2) Error bar showing the mean width-to-length ratio of ameloblastomas and odontogenic keratocysts with upper and lower 95% confidence intervals.

TABLE (1): Comparison of age and ratio values between ameloblastomas and odontogenic keratocysts.

Characteristic	Ameloblastomas	Keratocysts	P-value*
	(n = 20)	(n = 20)	
Age	30.95 ± 13.62	31.40 ± 11.55	0.91
Width-to-length ratio	0.743 ± 0.144	0.421 ± 0.072	<0.001**

Data expressed as the mean ±SD SD: standard deviation Test: Student’s t-test (unpaired)

*P: Probability

** : significance $P \leq 0.05$

TABLE (2): Diagnostic performance of width-to-length ratio in discriminating ameloblastomas from odontogenic keratocysts.

Cutoff point	Ameloblastoma	Keratocyst	Sensitivity	Specificity	PPV*	NPV**	Accuracy	F1 score	MCC***
<0.5	0 (0%)	18 (90%)	100%	90%	90.9%	100%	95%	95.2%	90.5%
≥0.5	20 (100%)	2 (10%)							

*PPV = positive predictive value. **NPV = negative predictive value. ***MCC = Matthews correlation coefficient.

Table 2 shows the results of validating the previously published cutoff point of 0.5.¹⁰ The true positive (TP), true negative (TN), false positive (FP), and false negative (FN) cases were 20, 18, 2, and 0, respectively. This yielded a sensitivity, specificity, PPV, and NPV of 100%, 90%, 90.9%, and 100%, respectively. The test had excellent overall performance with accuracy, F1 score, and MCC at 95%, 95.2%, and 90.5%, respectively. Both positive test results (width-to-length ratio ≥ 0.5) and negative test results (width-to-length ratio < 0.5) had excellent clinical utility with a clinical utility index for a positive result (CUI+) of 0.952% and a clinical utility index for a negative result (CUI-) of 0.950%.

DISCUSSION

OKCs are some of the most aggressive odontogenic cysts of the oral cavity. They are known for their rapid growth and propensity to penetrate the neighboring tissues. Phillipsen in 1956 was the first to describe and name OKCs.¹³ The WHO classified the lesion in 1971 as one of the developmental odontogenic cyst groups. In 2005, these lesions were classified as keratocystic odontogenic tumors (KCOT) due to their neoplastic behavior. Recently, the WHO classification of 2017 was reclassified to its original term, that is, OKC.^{3,14} These lesions represent about 12% of all jaw cysts.¹⁵

ABs and OKCs may present as a unilocular or multilocular expansion. Keratocyst buccolingual expansions were reported to a lesser extent (62%) when compared with ABs (91%). Likewise, root resorption occurred less often with keratocysts.¹⁶⁻¹⁸

OKCs within the body of the mandible mainly grow in an anteroposterior dimension and the lesions may reach a significant size without causing deformation of the jaw. This pattern of growth is less frequently observed in the vertical ramus and is very infrequent in the posterior maxilla,¹⁹ whereas ABs have a balloon-like pattern of expansion.⁶

All ABs included in the study displayed buccolingual cortical expansion and 11 had a ballooning pattern of expansion while one keratocyst showed this pattern of expansion, which is in agreement with many studies.^{5,19,20}

In the current study, we measured the width-to-length ratio in axial CBCT images. The results showed that AB ratios were significantly greater than the OKC ratios ($P < 0.001$), which was similar to the results of Omami and Adel.¹⁰ The cutoff point calculated in their study to differentiate the two types of lesions was employed in our patient cohort and we found a sensitivity and specificity of 100% and 90%, respectively. The test showed excellent overall performance with accuracy of 95%.

Our results were also comparable with the results of Arijji et al.⁷ who compared the ratios of the buccolingual expansion on both affected and opposite sides and found a significant difference in the degree of expansion between ABs and OKCs.

CONCLUSION

The width-to-length ratio is a valid imaging feature that can be used for differentiation of ABs and OKCs in the body of the mandible.

ACKNOWLEDGMENTS

We would like to express our appreciation to Dr. Monir H. Bahgat, Professor of Internal Medicine, Faculty of Dentistry, Mansoura University, for his assistance with the statistical analysis of this study.

Funding

This research did not receive any specific grant from funding agencies in the public, commercial, or not-for-profit sectors.

REFERENCES

1. Wright JM, Vered M. Update from the 4th edition of the World Health Organization classification of head and neck tumors: odontogenic and maxillofacial bone tumors. *Head Neck Pathol.* 2017;11(1):68-77.
2. Wright JM, Odell EW, Speight PM, Takata T. Odontogenic tumors, WHO 2005: where do we go from here? *Head Neck Pathol.* 2014;8(4):373-82.
3. El-Naggar AK, Chan JK, Grandis JR, Takata T, Slootweg PJ. WHO classification of head and neck tumors. IARC. 2017.
4. Siar CH, Lau SH, Ng KH. Ameloblastoma of the jaws: a retrospective analysis of 340 cases in a Malaysian population. *J Oral Maxillofac Surg.* 2012;70(3):608-15.
5. Macdonald-Jankowski D. Orthokeratinized odontogenic cyst: a systematic review. *Dentomaxillofac Radiol.* 2010; 39(8):455-67.
6. Kitisubkanchana J, Reduwan NH, Poomsawat S, Pornprasertsuk-Damrongsri S, Wongchuensoontorn C. Odontogenic keratocyst and ameloblastoma: radiographic evaluation. *Oral Radiol.* 2021;37(1):55-65.
7. Arijji Y, Morita M, Katsumata A, Sugita Y, Naitoh M, Goto M, et al. Imaging features contributing to the diagnosis of ameloblastomas and keratocystic odontogenic tumors: logistic regression analysis. *Dentomaxillofac Radiol.* 2011; 40(3):133-40.
8. Alves DB, Tuji FM, Alves FA, Rocha AC, Santos-Silva AR, Vargas PA, et al. Evaluation of mandibular odontogenic keratocyst and ameloblastoma by panoramic radiograph and computed tomography. *Dentomaxillofac Radiol.* 2018;47(7):20170288.
9. Meng Y, Zhao YN, Zhang YQ, Liu DG, Gao Y. Three-dimensional radiographic features of ameloblastoma and cystic lesions in the maxilla. *Dentomaxillofac Radiol.* 2019;48(6):20190066.
10. Galal Omami MA. Width-to-length ratio comparison between ameloblastomas and odontogenic keratocysts in the body of the mandible: a preliminary study. *Imaging Sci Dent.* 2020;50(4):319.
11. Siontis GC, Tzoulaki I, Castaldi PJ, Ioannidis JP. External validation of new risk prediction models is infrequent and reveals worse prognostic discrimination. *J Clin Epidemiol.* 2015;68(1):25-34.
12. Mitchell AJ. Sensitivity × PPV is a recognized test called the clinical utility index (CUI+). *Eur J Epidemiol.* 2011;26(3):251-2.
13. Philipsen HP. Om keratocysts (kolesteatomer) *Kaerberne Tandlaegebladet.* 1956;60:963-80.
14. Passi D, Singhal D, Singh M, Mishra V, Panwar Y, Sahni A. Odontogenic keratocyst (OKC) or keratocystic odontogenic tumor (KCOT). Journey of OKC from cyst to tumor to cyst again: comprehensive review with recent updates on WHO classification. *Int J Curr Res.* 2017; 9(7):54080-6.
15. Johnson NR, Gannon OM, Savage NW, Batstone MD. Frequency of odontogenic cysts and tumors: a systematic review. *J Investig Clin Dent.* 2014;5(1):9-14.
16. Johnson NR, Batstone MD, Savage NW. Management and recurrence of keratocystic odontogenic tumor: a systematic review. *Oral Surg Oral Med Oral Pathol Oral Radiol.* 2013;116(4):e271-e6.
17. MacDonald-Jankowski D, Yeung R, Lee K, Li T. Ameloblastoma in the Hong Kong Chinese. Part 2: systematic review and radiological presentation. *Dentomaxillofac Radiol.* 2004;33(3):141-51.
18. MacDonald-Jankowski D. Keratocystic odontogenic tumor: systematic review. *Dentomaxillofac Radiol.* 2011; 40(1):1-23.
19. Macdonald-Jankowski DS, Li TK. Keratocystic odontogenic tumor in a Hong Kong community: the clinical and radiological features. *Dentomaxillofac Radiol.* 2010; 39(3):167-75.
20. Min JH, Huh KH, Heo MS, Choi SC, Yi WJ, Lee SS, et al. The relationship between radiological features and clinical manifestation and dental expenses of keratocystic odontogenic tumor. *Imaging Sci Dent.* 2013;43(2):91-8.