

MANAGEMENT OF GAP DISTANCE AROUND IMMEDIATE IMPLANTS WITH TOPICAL MELATONIN GEL AND HYALURONIC ACID (A RANDOMIZED CLINICAL TRIAL)

Sherif Abdelrahman Amer* 

ABSTRACT

Background: Immediate post extraction implants are currently widely used; with this surgical technique a dental implant is placed after extraction of teeth in a fresh socket without waiting for any bone or soft tissue healing to reduce the treatment periods. Melatonin is physiologically existing in saliva, and it was found to influence both bone regeneration and fibroblast activation as well as hyaluronic acid which distributed widely throughout neural, connective, and epithelial tissues.

Aim: The aim of the present study was to evaluate the effect of topically delivered melatonin gel and hyaluronic acid on dental implants placed into fresh extraction sockets clinically and radiographically.

Subjects and Methods: Patients were eligible for the present study if they needed one immediate implant placement (IIP) replacing a tooth to be extracted within the maxillary premolar area. Thirty two adult patients were randomly allocated into four equal groups **Group (A):** Each patient in this group received immediate implant placement (IIP) with no filling material around the implant. **Group (B) :** Each patient in this group received IIP simultaneously with topical hyaluronic acid as a filling material into bone gaps around implant. **Group (C) :** Each patient in this group received IIP with topical melatonin gel plus topical hyaluronic acid to fill the bone gaps around implant. **Group (D) :** Each patient in this group received IIP with melatonin gel to fill the bone gaps around implant. Clinical and radiographic assessments were performed before IIP (baseline) and 6 months after implant placement. Clinical assessment includes bleeding index (BI), gingival index (GI) and probing depth (PD) while the radiographic assessment were performed using CBCT.

Results: The results of this present study showed that local delivery of 1.2% hyaluronic acid and melatonin gel improve the clinical parameters around immediate implants but did not prevent bone loss as assessed by cone beam computed tomography analysis (CBCT).

Conclusions: The short term follow up of 6 months of IIP in the maxillary premolar area showed successful clinical outcomes as assessed by clinical parameters and CBCT. IIP with or without simultaneous topical melatonin gel application and hyaluronic acid in the gap distance around the immediate implants did not prevent bone loss.

* Lecturer of Oral Medicine, Diagnosis and Periodontology, Faculty of Oral and Dental Medicine Future University.

INTRODUCTION

Immediate implant placement has many advantages including preserving the alveolar bone, decreasing treatment time and providing superior aesthetics and it was approved that following tooth removal the extraction socket is subjected to physiological remodeling with up to 50% reduction in the buccal dimension⁽¹⁾

It was authorized that there is a correlation between the soft tissue thickness on the degree of crestal bone remodeling as almost 85% of the implants with thick mucosal tissue showed no bone loss or a loss no more than 0.5 mm after one year follow-up and in contrast almost 70% of implants in thin soft tissue showed more than 1.00 mm of bone loss after one year follow-up.^(2,3)

The immediate implant placement must possess sufficient primary stability which is ensured by exceeding the apex by 3-5 mm or by using an implant of greater diameter than the socket.⁽⁴⁾

Melatonin is produced in several organs and melatonin-forming enzymes are found in many tissues including the retina, ovaries, gastrointestinal tract and immune system cells⁽⁵⁻⁷⁾

Melatonin has numerous physiological functions in different parts of the body such as the control of cardiac rhythms, regulation of sexual development, the reproductive cycle and activation of the immune system⁽⁸⁻¹⁰⁾

Melatonin can interfere and inhibit bone resorption by inhibiting osteoclast activity by means of receptor activator of nuclear factor-kappa B (RANK) as it decrease the messenger ribonucleic acid (mRNA) expression of this type I membrane protein on the surface of osteoclasts so inhibiting osteoclastogenesis^(11,12)

Hyaluronic acid is a linear macromolecular mucopolysaccharide that is mainly composed of alternatingly linked two saccharide units of

glucuronic acid and N-acetylglucose- amine^(13,14)

Recent scientific studies approved the effects of hyaluronic acid on the healing of different parts of the body in particular the jaw, tibia , femoral knee and treatment of gingival recession⁽¹⁵⁾⁽¹⁶⁾⁽¹⁷⁾⁽¹⁸⁾

Hyaluronic acid is non immunogenic and has been successfully utilized as a scaffold for BMP-2 delivery both in preclinical and clinical trial⁽¹⁹⁾⁽²⁰⁾

Recently CBCT scans have been widely used in the dental and implant field due to the accuracy and capability to view a three dimensional image (3D) of teeth and the important vital structures⁽²¹⁾

To our knowledge, there is no human study that compared the effect of both melatonin and hyaluronic acid in management of gap distance around immediate implant placement. Therefore, the aim of the present study was to evaluate the effect of topically delivered melatonin gel and hyaluronic acid on dental implants placed into fresh extraction sockets clinically and radiographically.

SUBJECTS AND METHODS

Selection of patients:

This study was carried out on 32 patients from the out patients clinic of oral medicine, diagnosis and periodontology department, Faculty of oral and dental medicine (Future University in Egypt)

Inclusion criteria:

- 1- Patients ages more than 18 years old.
- 2- Patients requiring extraction of maxillary teeth in the premolar region with consequent immediate implant placement.
- 3- Indications for extraction included: non restorable teeth (upper premolars), untreatable caries, endodontic failures, remaining roots, vertical fracture of the roots.
- 4- Natural teeth adjacent to the tooth to be extracted

were required to have complete occlusal surfaces and be free from infections.

- 5- The decision of the immediate implant placement was made after tooth extraction and examination of the extraction socket which displayed intact labial and palatal bone and at least a 3 mm of bone beyond the root apex to guarantee primary fixture stability.

Exclusion criteria:

- 1- Pathologies or drugs that alter tissue integration with dental implants.
- 2- Head and neck radiation therapy.
- 3- Renal disease, bleeding disorders and anticoagulant therapy.
- 4- Pregnant females.
- 5- Patients with severe para-functional habits and unfavorable occlusion
- 6- Smokers.
- 7- Malaligned teeth and teeth with acute periapical pathosis.

The study protocol was explained in detail to all the patients and the patients were informed with the complications and risks of the surgery such as pain, inflammation, infection, and a signed informed consent was obtained from all the patients.

The data obtained from patients as well as the results of the follow-up were kept confidential.

Pre-surgical procedure:

After assessment of the patient's general health, local visual examination, and palpation to examine the entire oral and peri-oral tissues was carried out. All the patients received standardized diagnosis and treatment planning procedures.

Maxillary and mandibular impressions were made and poured into stone casts to check the occlusion and direction of forces with respect to future implant site.

Pre-surgical radiographic evaluation with peri-apical radiographs were taken to detect the presence of any clinically undetectable pathology.

All patients received initial periodontal therapy including scaling and root planning and were instructed about oral hygiene measures as brushing, flossing and immediate implant surgery was performed when patients showed good plaque control.

Study design and patient grouping:

After patients' selection according to the inclusion and exclusion criteria they were randomly divided into four equal groups.

No attempt was done to control the distribution of patients to the groups to maintain randomization.

Each patient was randomly assigned by choosing a letter from an envelope to be either in Group A, Group B, Group C or Group D.

- **Group (A) control group:** Each patient in this group received one implant that was placed immediately following tooth extraction with no filling material around the implant.
- **Group (B):** Each patient in this group received one implant that was placed immediately following tooth extraction simultaneously with 1.2% topical hyaluronic acid gel as a filling material into bone gaps around implant.
- **Group (C):** Each patient in this group received one implant that was placed immediately following tooth extraction with 1.2% hyaluronic acid gel plus melatonin gel to fill the bone gaps around implant.
- **Group (D):** Each patient in this group received one implant that was placed immediately following tooth extraction with melatonin gel to fill the bone gaps around implant.

Steps of gel preparation:

The melatonin gel was prepared using melatonin drug 2% w/w that was isolated uniformly in double

distilled water and added to the gel with stirring till homogenous distribution. The weight of gel was adjusted to 100 gm and then packed in sterile and dry glass containers until used.

Methylcellulose in situ gel was prepared by adding the required amount of biocompatible solvent to an accurately weighed amount of methylcellulose. The vial was heated to 50°C to 60°C and agitated using a mechanical shaker to obtain a clear solution. A weighed amount of hyaluronic acid was added to the above solution and dissolved completely to obtain a homogeneous phase of polymer, solvent and drug thus the hyaluronic acid in situ gel was prepared with a concentration 1.2% which provides a flowable gel that could easily pass through the syringe.

Surgical procedures:

- 1- Surgical procedures were performed under local infiltration anesthesia that was given to the site of the extraction buccally and palatally.
- 2- The tooth to be extracted was removed a traumatically to preserve as much of the socket profile as possible and to prevent fracture of the socket walls and a peristome was used in a circumferential manner to create an access point for the subsequent use of elevators and the final tooth delivery was done with premolar forceps or bayonet forceps in case of remaining roots.
- 3- Following successful removal of the tooth or root, any inflammatory /granulation tissue was curetted from the socket and any inflamed periodontal pocket tissue was excised and irrigation with sterile saline was done with a plastic syringe.
- 4- A standardized periodontal probe was used to detect the buccal bone level and the presence of bone fenestration or dehiscence.
- 5- The site was prepared for an implant (NeoBiotech)* following the manufacturer

instructions with adequate cooling during drilling to prevent thermal injury that may lead to osteonecrosis.

- 6- The dimensions of osteotomy and the dental implant were determined based on that of the extracted root and the dental implant was manually installed into the prepared osteotomy using the implant driver and ratchet.
- 7- According to the respective group the osteotomy site and the jumping distance around the immediately placed dental implant was left unfilled in group(A) or filled with 1.2% topical hyaluronic acid for group(B) or 1.2% topical hyaluronic acid plus melatonin gel for group (C) or melatonin gel for group (D).
- 8- Healing abutments was screwed to the implants and cross mattress and interrupted sutures were done for complete closure.
- 9- Sutures were removed 14 days postoperatively and the patients were recalled for prophylaxis.

Follow up and criteria of evaluation:

Each patient was examined at baseline before (IIP) and after 6 months postoperatively and the clinical parameters which include bleeding index (BI), gingival index (GI) and probing depth (PD) were used to clinically evaluate the cases during the follow-up period in addition to the radiographic evaluation.

Patients were asked to give their comments and feedback about pain, discomfort or swelling.

1) Clinical parameters:

1-a) Bleeding on probing:

Bleeding on probing was evaluated using a periodontal probe inserted into the gingival sulcus at the base of the papilla on the mesial aspect and then moved coronally to the papilla tip. This is repeated on the distal aspect of the papilla, The intensity of

any bleeding is recorded as:

- Score 0 = No bleeding.
- Score 1 = A single discreet bleeding point.
- Score 2 = Several isolated bleeding points or a single line of blood appears.
- Score 3 = The interdental triangle fills with blood shortly after probing.
- Score 4 = Profuse bleeding occurs after probing, blood flows immediately into the marginal sulcus.

The sum of recorded scores gave the bleeding number, Papillary bleeding index (PBI) was calculated by dividing the bleeding number by the total number of papillae examined and the net result is the (PBI) score(22)

1-b) Gingival index (GI):

The peri-implant mucosa was evaluated visually as:

- **0=** No inflammation - (normal gingival).
- **1=** Mild inflammation – slight change in color and slight edema but no bleeding on probing.
- **2=** Moderate inflammation – redness, edema and glazing, bleeding on probing.

NeoBiotic dental implants co. Ltd, Seoul, Korea*

- **3=** Severe inflammation – marked redness and edema, ulceration with tendency to spontaneous bleeding.

GI scores for the area were obtained by totaling the four gingival scores per implant and the sum of GI scores per implant was divided by four ; the GI score for the implant was obtained(23)

1-c) Probing depth (PD):

The probing pocket depth around the implant at the 4 aspects of the implant facial, palatal and proximal surfaces were measured and recorded according to the standard procedure using a

periodontal probe with Williams 'calibrations(24)

2) Radiographic evaluation:

Cone beam computed tomography (CBCT) using i-CAT™** machine was taken at (baseline) before (IIP) to assess the thickness of the labial plate of bone and the patients were exposed to another CBCT after 6 months after implant placement for evaluation of the changes in the thickness of the labial plate of bone. Readings of bone thickness were measured at three different levels: implant platform(T0), 2mm (T1) and (T2) 4mm.

Prosthetic phase:

Four months after implant placement, impressions were taken for the fabrication of permanent porcelain fused metal crown.

STATISTICAL ANALYSIS:

The evaluated clinical and radiographic parameters were subjected to statistical evaluation using SPSS software (SPSS version 24). The descriptive statistics were generated for all variables. The paired **t test** was performed to evaluate the differences between the baseline and the different observation periods in each group.

For comparison between the groups, the unpaired **t test** was used. The level of significance was < 0.05 . Analysis of variance (ANOVA) tests (f): according to the computer program SPSS for windows. ANOVA test was used for comparison among different times in the same group in quantitative data, **Chi-Square** test was used for comparison between two groups as regards qualitative data.

RESULTS

1) Clinical evaluation results

1-a) Bleeding on probing

At baseline before extraction the mean and standard deviation (SD) values of papillary

bleeding index (**BPI**) was (1.61±0.71) for group **A**, (1.72 ±0.73) for group **B**, (1.60±0.70) for group **C** and **D**. **One-way ANOVA** test showed that there was no statistically significant difference between the groups with (**P value=0.979**)^{NS} while **After 6 months** the mean and standard deviation values of (**BPI**) were (0.49 ±0.71) for group **A** , (0.33± 0.73) for group **B** , (0.27± 0.49) for group **C** and **D** .

Paired (t-test) showed statistically significant decrease in the mean and standard deviation (SD) values of papillary bleeding index (**PBI**) for all groups compared with baseline (**P value < 0.05**) * **Table (1) & Fig (1)**

1-b) Gingival index (GI):

At baseline before extraction the mean and standard deviation (SD) values of (**GI**) were (1.65± 0.37) for group **A**, (1.70±0.27) for group **B**, (1.70± 0.38) for group **C** and (1.74±0.29) for group **D**. **One-way ANOVA** test showed that there was no statistically significant difference between the four groups with (**P value =0.889**)^{NS}

iCAT Next Generation Cone Beam 3D System by Imaging Sciences International LLC, Hatfield, PA, USA.**

After 6 months the mean and standard deviation (SD) values of (**GI**) were (1.23±0.69) for group **A**, (1±0.52) for group **B**, (0.35±0.54) for group **C** and (0.5± 0.55) for group **D**. **Paired(t-test)** showed that all groups except group **A** recorded statistically significant decrease in the mean values of (**GI**) compared with baseline records (**P value <0.05**)* **Table(2) & Fig(2)** .

1-c) Probing depth (PD)

At baseline before extraction the mean and standard deviation values (SD) of (**PD**) were (3.71± 0.61) for group **A**, (3.64±0.67) for group **B**, (3.73±0.64) for group **C** and (3.79±0.63) for group **D**. **One-way ANOVA** test showed that there was no statistically significant difference between groups

with (**P value=0.949**)^{NS}

After 6 months the mean and standard deviation (SD) values of (**PD**) were (3.54±0.41) for group **A**, (3.61±0.31) for group **B**, (2.67±0.24) for group **C** and (2.61±0.21) for group **D**. **Paired(t-test)** showed that only group **C** and **D** recorded statistically significant decrease in the mean values of (**PD**) compared with baseline. **Table (3) & Fig (3)**

2-Radiographic evaluation:

Changes in the thickness of the labial plate of bone was measured at 3 points; implant platform **T (0)**, **T (1)** 2mm and **T (2)** 4 mm from the implant platform across the time and compared between the four groups.

The mean and standard deviation (SD) values of the the labial plate of bone thickness at **T (0)** were (1.00 ± 0.16) for group **A**, (1.01 ± 0.15) for group **B**, (1.05 ± 0.17) for group **C** and (1.12 ± 0.21) for group **D**.

One-way ANOVA test showed that there was no statistically significant difference between groups with (**P value=0.593**)^{NS} while **after 6 months** the mean and standard deviation (SD) values of the labial plate of bone thickness at **T(0)** were (0.55±0.13) for group **A** , (0.81±0.12) for group **B** , (0.82±0.12) for group **C** and (0.66±0.19) for group **D** . **One-way ANOVA** test showed that there was statistically significant difference among the four groups with (**P value=0.001**) * **Table (4) & Fig (4)**.

At baseline the mean and standard deviation (SD) values of the labial plate of bone thickness at **T (1)** were (1.18±0.18) for group **A**, (1.21±0.17) for group **B**, (1.23±0.23) for group **C** and (1.29±0.27) for group **D**. **One-way ANOVA** test showed that there was no statistically significant difference between groups with (**P value=0.764**)^{NS} while **after 6 months** the mean and standard deviation (SD) values of labial plate of bone thickness at **T(1)** were (0.68±0.15) for group **A**, (0.91±0.14) for group **B**, (0.95±0.13) for group **C** and (0.78±0.15) for group **D**.

One-way ANOVA test showed that there was statistically significant difference among groups with (**P value=0.004***). **Table (5)**

At baseline the mean and standard deviation (SD) values of the labial plate of bone thickness at **T (2)** were (1.29±0.15) for group **A**, (1.36±0.16) for group **B**, (1.36±0.25) for group **C** and (1.36±0.26) for group **D**. **One-way ANOVA** test showed that there was no statistically significant difference between groups with (**P value=0.882**)^{NS} **while after 6 months** the mean and standard deviation (SD) values of labial plate of bone thickness at **T(2)** after 6 months ; group **A** values were (0.82±0.12), (1.00±0.17) for group **B** , (1.03±0.13) for group **C** and (0.86±0.17) for group **D** . **One-way ANOVA** test showed that there was statistically significant difference between the groups with (**P value=0.04***). **Table (6)**. **Post Hoc** test showed that there was statistically significant difference between group

A and B (P1=0.002)*, group **A and C (P2=0.001)*** and group **C and D (P6=0.014)*** , but there was no statistically significant difference between group **A and D (P3=0.14)**^{NS} , group **B and C (P4=0.47)**^{NS} and group **B and D (P5=0.014)**^{NS} . **Table (7)**.

Post Hoc test showed that there was statistically significant difference between group **A and B (P1=0.005)***, group **A and C (P2=0.001)*** and group **C and D (P6=0.032)*** , but there was no statistically significant difference between group **A and D (P3=0.179)**^{NS} , group **B and C (P4=0.59)**^{NS} and group **B and D (P5=0.032)**^{NS} . **Table (8)**. **Post Hoc** test showed that there was statistically significant difference between group **A and B (P1=0.023)*** and group **A and C (P2=0.014)*** , but there was no statistically significant difference between group **A and D (P3=0.379)**^{NS} ,group **B and C (P4=0.813)**^{NS} , group **B and D(P5=0.143)**^{NS} and group **C and D (P6=0.093)**^{NS}

TABLE (1) The mean and standard deviation values of papillary bleeding index (PBI) for all groups over the study follow up period:

	Group	Range	Mean± S.D	T.test	P.value
A	(PBI) Baseline	1_3	1.61±0.71	9.000	0.010*
	6 months	0_2	0.49±0.71		
B	(PBI) Baseline	1_3	1.72±0.73	14.34	0.002*
	6months	0_2	0.33±0.73		
C	(PBI) Baseline	1_3	1.60±0.70	19.62	0.001*
	6 months	0_1	0.27±0.49		
D	(PBI) Baseline	1_3	1.60±0.70	19.62	0.001*
	6 months	0_1	0.27±0.49		

TABLE (2) The mean and standard deviation values of gingival index (GI) for all groups over the study follow up period:

	Group	Range	Mean± S.D	T.test	P.value
A	GI Baseline	1_2	1.65±0.37	1.79	0.204 ^{NS}
	6 months	0_2	1.23±0.69		
B	GI Baseline	1.5_2	1.70±0.27	10.71	0.006*
	6 months	0_2	1.00±0.52		
C	GI Baseline	1_2	1.70±0.38	33.88	0.001*
	6 months	0_1	0.35±0.54		
D	GI Baseline	1.5_2	1.74±0.29	34.93	0.001*
	6 months	0_1	0.50±0.55		

TABLE (3) The mean and standard deviation values of (PD) for all groups over the study follow up period:

	Group	Range	Mean± S.D	T.test	P.value
A	(PD) Baseline	3_5	3.71±0.61	0.465	0.50^{NS}
	6 months	3_4	3.54±0.41		
B	(PD) Baseline	3_5	3.64±0.67	0.001	1.000^{NS}
	6 months	3_4	3.61±0.31		
C	(PD) Baseline	3_5	3.73±0.64	18.221	0.001*
	6 months	2.5_3	2.67±0.24		
D	(PD) Baseline	3_5	3.79±0.63	23.69	0.001*
	6 months	2.5_3	2.61±0.21		

TABLE (4) The mean and standard deviation values of bone thickness at T (0) for all groups over the study follow up period:

Bone thickness T (0)	Group	Range	Mean± S. D	F.test	P.value
Baseline	A	0.89_1.23	1.00±0.16	0.631	0.593^{NS}
	B	0.81_1.24	1.01±0.15		
	C	0.84_1.34	1.05±0.17		
	D	0.81_1.56	1.12±0.21		
After 6 months	A	0.41_0.88	0.55±0.13	7.01	0.001*
	B	0.63_0.92	0.81±0.12		
	C	0.66_1.02	0.82±0.12		
	D	0.45_0.92	0.66±0.19		

TABLE (5) The mean and standard deviation values of bone thickness at T (1) for all groups over the study follow up period:

Bone thickness T (1)	Group	Range	Mean±S.D	F.test	P.value
Baseline	A	0.93_1.37	1.18±0.18	0.382	0.764^{NS}
	B	0.89_1.31	1.21±0.17		
	C	0.91_1.59	1.23±0.23		
	D	0.88_1.69	1.29±0.27		
After 6 months	A	0.51_0.93	0.68±0.15	5.462	0.004*
	B	0.68_1.22	0.91±0.14		
	C	0.71_1.19	0.95±0.13		
	D	0.53_0.96	0.78±0.15		

TABLE (6) The mean and standard deviation values of bone thickness at T(2) for all groups over the study follow up period:

Bone thickness 6months T (2)	Group	Range	Mean±S.D	F.test	P.value
Baseline	A	1.02_1.43	1.29±0.15	0.208	0.882 ^{NS}
	B	1.17_1.65	1.36±0.16		
	C	1.06_1.70	1.36±0.25		
	D	0.94_1.81	1.36±0.26		
After 6 months	A	0.62_1.03	0.82±0.12	3.149	0.040*
	B	0.78_1.28	1.00±0.17		
	C	0.82_1.22	1.03±0.13		
	D	0.61_1.22	0.86±0.17		

TABLE (7) Multiple comparisons of bone thickness at T (0) for all groups after 6 months.

6 Months	Group	F.test	P.value	Post hoc test			
Bone thickness T (0)	A	7.015	0.001*	P1	0.002*	P4	0.47 NS
	B			P2	0.001*	P5	0.06 NS
	C			P3	0.14 NS	P6	0.014*
	D						

TABLE (8) Multiple comparisons of bone thickness at T (1) for all groups after 6 months.

6 Months	Group	F.test	P.value	Post Hoc test			
Bone Thickness T (1)	A	5.463	0.004*	P1	0.005*	P4	0.59 ^{NS}
	B			P2	0.001*	P5	0.032 ^{NS}
	C			P3	0.179 ^{NS}	P6	0.031*
	D						

TABLE (9) Multiple comparisons of bone thickness at T(2)for all groups after 6 months .

6 Months	Group	F.test	P.value	Post Hoc test			
Bone Thickness T (2)	A	3.15	0.04*	P1	0.023*	P4	0.813 ^{NS}
	B			P2	0.014*	P5	0.143 ^{NS}
	C			P3	0.379 ^{NS}	P6	0.093 ^{NS}
	D						

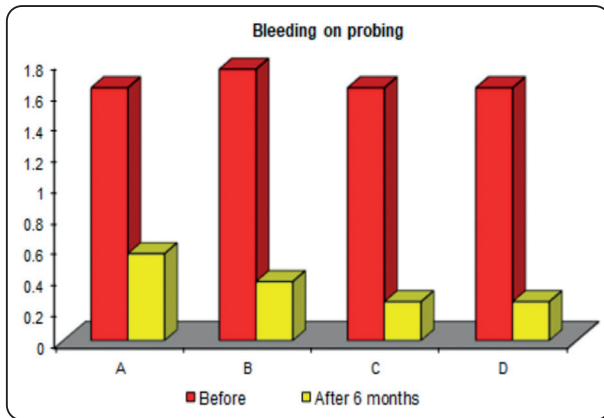


Fig. (1) Bar chart showing the mean values of (PBI) for all groups over the study follow up period.

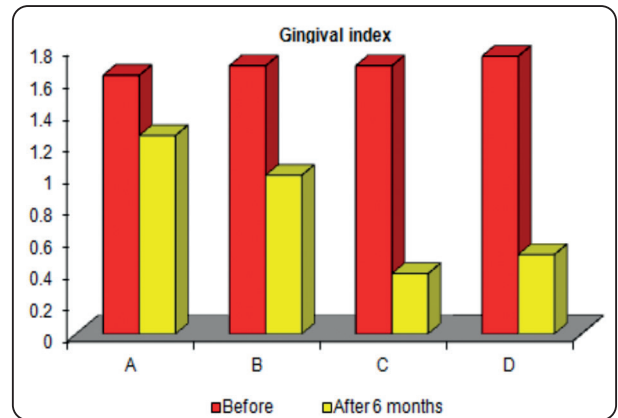


Fig. (2) Bar chart showing the mean values of gingival index (GI) for all groups over the study follow up period.

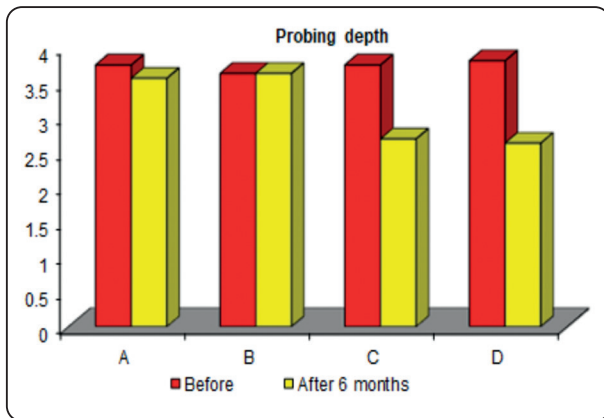


Fig. (3) Bar chart showing the mean and standard deviation values of probing depth (PD) for all groups over the study follow up period.

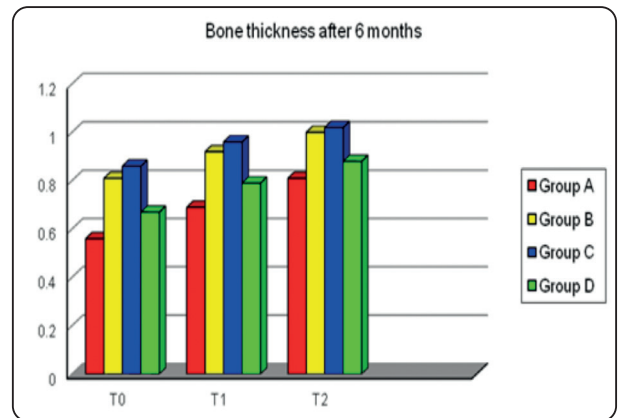


Fig. (4) Bar chart showing the mean values of bone thickness for all groups after 6 months.

DISCUSSION

Immediate placement of implants has many advantages such as preservation of alveolar bone , better implant orientation , esthetics and psychosocial benefits in addition to it overcomes the drawbacks of delayed implants such as prolonged treatment time, multiple appointments, reduction in alveolar bone dimensions and migration of teeth into the edentulous space⁽²⁵⁾

The distance between the socket walls and the implant surface may justify augmentation to predictably achieve bone implant contact (BIC) and prevent soft tissue collapse and many preclinical and clinical studies have documented the regeneration of

horizontal gaps smaller than 2 mm in the presence of a stable blood clot but when the peri-implant gap distance was more than 2mm the bone graft should be used to seal this bony defect⁽²⁶⁻²⁸⁾

It was postulated that topical application of melatonin has osteoconductive capacity, stimulate new bone formation and reduce the resorption of bone by inhibiting osteoclastogenesis⁽²⁹⁾

Hyaluronic acid play a key role during bone repair by stimulating cell migration, adhesion, and proliferation of undifferentiated mesenchymal cells inducing their differentiation into osteoblastic cells⁽³⁰⁾

IIP in the esthetic zone represents one of the major challenges in dentistry as it implies a multidisciplinary approach involving prosthetic and periodontal aspects to gain long term stability and functional results furthermore the postextraction morphology of the maxillary premolar sockets presents a number of challenges to clinicians seeking ideal implant position, including the morphology of the lateral walls of the extraction socket and the presence of the interradicular septum in addition to thin tissue biotypes which showed greater recession than thick tissue biotypes⁽³¹⁾⁽³²⁾

According to the previous studies, the role of topical melatonin and hyaluronic acid in establishment of high success osseointegration of immediate implants and minimizing crestal bone loss needs to be investigated.

The aim of the present study was to evaluate the effect of topically delivered melatonin gel and 1.2% hyaluronic acid on dental implants placed into fresh extraction sockets clinically and radiographically

This study showed 100% survival rate of the immediate implants and this results was in accordance with Kan et al. who showed a survival rate of 100% for 35 implants that were placed immediately after extraction of teeth⁽³³⁾

Concerning the papillary bleeding index (PBI) and gingival index (GI), all the groups demonstrated regression in the PBI and GI values throughout the study periods which may be explained by the motivation of the patients for proper and continuous oral hygiene measures. The results of the present study agreed with the findings of other investigators who reported that marginal tissue around titanium implants in most patients had no gingivitis throughout the study period⁽³⁴⁾

Regarding the results of the present study , group C and D (melatonin groups) recorded less mean values of gingival index and probing depth compared with the other groups with statistically

significant difference (**P value<0.001***) which may be explained by the pleiotropic effects of the topically applied melatonin gel due to the anti-inflammatory and anti-oxidant properties⁽³⁵⁾

The results of the present investigation are in accordance with other studies which showed the beneficial effect of topical melatonin in treatment of periodontal diseases , reducing osteoblast apoptosis and improving implant osseointegration⁽³⁶⁾⁽³⁷⁾

In the current study complete gap fill was found in the four groups after the follow up periods and these results were in accordance with **Tarnow and Chu** who reported in a case report in which an immediate dental implant was placed with buccal jumping distance about 4mm and allowed to heal by secondary intention with no bone graft or barrier membranes , then histologic examination showed osseointegration of the implant to the bone⁽³⁸⁾

In the present study the mean thickness of the buccal bone after extraction of teeth was found to be 1.2 ± 0.62 mm and these results were in consistency with many studies which measured the thickness of buccal bone in maxillary premolar region and found that the mean thickness of labial bone at 1 mm apical to the crest was 1.1 ± 0.5 mm⁽³⁹⁾⁽⁴⁰⁾

For all the study groups there was statistically significant decrease in the mean and standard deviation values of buccal bone thickness between baseline and 6 months which could be explained by the large remodeling with horizontal bone reduction due to alterations of the buccal-lingual dimension of the alveolar ridge after extraction and this was explained in many studies which documented that the crest of the buccal bone was formed solely of bundle bone that would resorb if the tooth was extracted due to loss of periodontal ligament blood supply that is why the buccal wall is more susceptible to bone loss than the lingual counterpart⁽⁴¹⁾⁽⁴²⁾

After 6 months measurements for bone thickness

changes for group **A** at 2 mm from the implant platform showed a mean loss of 0.5 mm , group **B** recorded changes of 0.30mm , group **C** had a mean loss of 0.28mm and 0.51 mm for group **D** and these records are in agreement with clinical trials which demonstrated a mean change in thickness at 2mm from the implant platform of $0.46\text{mm}\pm 0.27$ and horizontal buccal bone reduction 29.3% after one year follow up period (43)(44)

CONCLUSIONS

Within the limitations of this study it was concluded that

- Immediate implant placement in the maxillary premolar area showed successful clinical outcomes through the follow up periods .
- Local delivery of melatonin improves the clinical parameters around immediate implants
- Immediate implant placement with simultaneous topical melatonin gel and hyaluronic acid did not prevent bone loss as assessed by cone beam computed tomography analysis .
- The long-term safety profile of topical melatonin makes it a promising agent for improving osseointegration of dental implant.

REFERENCES

1. Weigl P, Strangio A. The impact of immediately placed and restored single-tooth implants on hard and soft tissues in the anterior maxilla. 2016;9:89–107.
2. Linkevicius T, Pros D, Puisys A, Steigmann M. Influence of Vertical Soft Tissue Thickness on Crestal Bone Changes Around Implants with Platform Switching : A Comparative Clinical Study. 2014;10(12).
3. Tarnow DP. Human Histologic Verification of Osseointegration of an Immediate Implant Placed into a Fresh Extraction Socket With Excessive Gap Distance Without Primary Flap Closure , Graft , or Membrane : A Case Report. 2011; 9:89-102.
4. Muhamad A, Azzaldeen A, Aspasia SA, Nikos K. Implants into fresh extraction site : A literature review , case immediate placement report. 2013;160–5.
5. Moussa SG. Evaluation of locally delivered 1 . 2 % Atorvastatin gel versus 2 % melatonin gel as adjunctive to non-surgical periodontal therapy on GCF osteocalcin level in stage II periodontitis patients : a randomized controlled trial as adjunctive to non-surgical p. 2021;7(1):1–7.
6. Montero J, López-Valverde N, Ferrera MJ, López-Valverde A. Changes in crevicular cytokines after application of melatonin in patients with periodontal disease. J Clin Exp Dent. 2017;9(9):e1081–7.
7. Talib WH, Alsayed AR, Abuawad A, Daoud S, Mahmod AI. Melatonin in cancer treatment: Current knowledge and future opportunities. Molecules. 2021;26(9):1–46.
8. Permuy M, López-Peña M, González-Cantalapiedra A, Muñoz F. Melatonin: A review of its potential functions and effects on dental diseases. Int J Mol Sci. 2017;18(4):1–13.
9. Acikan I, Gul M, Artas G, Yaman F, Deniz G, Bulmus O, et al. Systemic Melatonin Application Increases Bone Formation In Mandibular Distraction Osteogenesis. Braz Oral Res. 2018;32:1–8.
10. Hu W, Liang J-W, Liao S, Zhao Z-D, Wang Y-X, Mao X-F, et al. Melatonin attenuates radiation-induced cortical bone-derived stem cells injury and enhances bone repair in postradiation femoral defect model. Mil Med Res 2021;8(1):1–13.
11. Solá-Ruiz MF, Pérez-Martínez C, Martín-del-Llano JJ, Carda-Batalla C, Labaig-Rueda C. In vitro preliminary study of osteoblast response to surface roughness of titanium discs and topical application of melatonin. Med Oral Patol Oral Cir Bucal. 2015;20(1):e88–93.
12. Yang M, Li L, Chen S, Li S, Wang B, Zhang C, et al. Melatonin protects against apoptosis of megakaryocytic cells via its receptors and the AKT/mitochondrial/caspase pathway. Aging (Albany NY). 2020;12(13):13633–46.
13. Huang G, Huang H. Application of hyaluronic acid as carriers in drug delivery. Drug Deliv 2018;25(1):766–72.
14. Juncan AM, Moisă DG, Santini A, Morgovan C, Rus LL, Vonica-țincu AL, et al. Advantages of hyaluronic acid and its combination with other bioactive ingredients in cosmeceuticals. Molecules. 2021;26(15):1–43.
15. Cervino G, Meto A, Fiorillo L, Odorici A, Meto A, D'amico C, et al. Surface treatment of the dental implant with hyaluronic acid: An overview of recent data. Int J

- Environ Res Public Health. 2021;18(9).
16. Kim S Bin, Cho J, Jue SS, Park JH, Kim JY. Effect of hyaluronic acid filler injection on the interdental papilla in a mouse model of open gingival embrasure. *Int J Environ Res Public Health*. 2020;17(14):1–13.
 17. Shirakata Y, Nakamura T, Kawakami Y, Imafuji T, Shinohara Y, Noguchi K, et al. Healing of buccal gingival recessions following treatment with coronally advanced flap alone or combined with a cross-linked hyaluronic acid gel. An experimental study in dogs. *J Clin Periodontol*. 2021;48(4):570–80.
 18. Pilloni A, Rojas MA, Marini L, Russo P, Shirakata Y, Sculean A, et al. Healing of intrabony defects following regenerative surgery by means of single-flap approach in conjunction with either hyaluronic acid or an enamel matrix derivative: a 24-month randomized controlled clinical trial. *Clin Oral Investig*. 2021;25(8):5095–107.
 19. Kisiel M, Klar AS, Ventura M, Buijs J, Mafina MK, Cool SM, et al. Complexation and Sequestration of BMP-2 from an ECM Mimetic Hyaluronan Gel for Improved Bone Formation. *PLoS One*. 2013;8(10):1–13.
 20. Agrali OB, Yildirim S, Ozener HO, Köse KN, Ozbeyli D, Soluk-Tekkesin M, et al. Evaluation of the effectiveness of esterified hyaluronic acid fibers on bone regeneration in rat calvarial defects. *Biomed Res Int*. 2018;(20)1–18.
 21. Ryu JH, Park JH, Vu Thi Thu T, Bayome M, Kim Y, Kook YA. Palatal bone thickness compared with cone-beam computed tomography in adolescents and adults for mini-implant placement. *Am J Orthod Dentofac Ortho*. 2012;142(2):207–12.
 22. Checchi L, Montevicchi M, Checchi V, Zappulla F. The Relationship Between Bleeding on Probing and Subgingival Deposits. An Endoscopical Evaluation. *Open Dent J*. 2009;3(1):154–60.
 23. Benamghar L, Penaud J, Kaminsky P, Abt F, Martin J. Comparison of gingival index and sulcus bleeding index as indicators of periodontal status. *Bull World Health Organ*. 1982;60(1):147–51.
 24. Schätzle M. The Role of gingivitis in the loss of periodontal attachment and teeth. [Internet]. *Journal of Clinical Periodontology*. 2005. 1–77
 25. Pan YH, Lin HK, Lin JCY, Hsu YS, Wu YF, Salamanca E, et al. Evaluation of the peri-implant bone level around platform-switched dental implants: A retrospective 3-year radiographic study. *Int J Environ Res Public Health*. 2019;16(14):1–12.
 26. Kadkhodazadeh M, Amid R, Moscowchi A, Khoshkam V. Clinical and radiographic evaluation of jumping distance management using a collagen matrix in flapless immediate implant placement. *Dent Med Probl*. 2021;58(2):173–8.
 27. Le Thieu MK, Homayouni A, Hæren LR, Tiainen H, Verket A, Ellingsen JE, et al. Impact of simultaneous placement of implant and block bone graft substitute: an in vivo peri-implant defect model. *Biomater Res*. 2021;25(1):1–10.
 28. Franchi M, Orsini E, Trire A, Quaranta M, Martini D, Piccari GG, et al. Osteogenesis and morphology of the peri-implant bone facing dental implants. *ScientificWorldJournal*. 2004;4:1083–95.
 29. Shino H, Hasuie A, Arai Y, Honda M, Isokawa K, Sato S. Melatonin enhances vertical bone augmentation in rat calvaria secluded spaces. *Med Oral Patol Oral Cir Bucal*. 2016;21(1):e122–6.
 30. Alcântara CEP, Castro MAA, de Noronha MS, Martins-Junior PA, de Melo Mendes R, Caliari MV, et al. Hyaluronic acid accelerates bone repair in human dental sockets: a randomized triple-blind clinical trial. *Braz Oral Res*. 2018;32:1–10.
 31. Fugazzotto PA. Implant Placement in Maxillary First Premolar Fresh Extraction Sockets: Description of Technique and Report of Preliminary Results. *J Periodontol*. 2002;73(6):669–74.
 32. Pluemsakunthai W, Le B, Kasugai S. Effect of buccal gap distance on alveolar ridge alteration after immediate implant placement: A microcomputed tomographic and morphometric analysis in dogs. *Implant Dent*. 2015;24(1):70–6.
 33. Kan JYK, Rungcharassaeng K, Deflorian M, Weinstein T, Wang HL, Testori T. Immediate implant placement and provisionalization of maxillary anterior single implants. *Periodontol 2000*. 2018;77(1):197–212.
 34. French D, Grandin HM, Ofec R. Retrospective cohort study of 4,591 dental implants: Analysis of risk indicators for bone loss and prevalence of peri-implant mucositis and peri-implantitis. *J Periodontol*. 2019;90(7):691–700.
 35. Chitimus DM, Popescu MR, Voiculescu SE, Panaitescu AM, Pavel B, Zagrean L, et al. Melatonin's impact on antioxidative and anti-inflammatory reprogramming in homeostasis and disease. *Biomolecules*. 2020;10(9):1–28.

36. Xiao L, Lin J, Chen R, Huang Y, Liu Y, Bai J, et al. Sustained Release of Melatonin from GelMA Liposomes Reduced Osteoblast Apoptosis and Improved Implant Osseointegration in Osteoporosis. *Oxid Med Cell.* 2020;21(5)-21.
37. Cengiz MI, Cengiz S, Wang HL. Melatonin and oral cavity. *Int J Dent.* 2012;4(20)-12.
38. Tarnow DP, Chu SJ. Human histologic verification of osseointegration of an immediate implant placed into a fresh extraction socket with excessive gap distance without primary flap closure, graft, or membrane: a case report. *Int J Periodontics Restorative Dent.* 2011;31(5):515–21.
39. Jung RE, Benic GI, Scherrer D, Hämmerle CHF. Cone beam computed tomography evaluation of regenerated buccal bone 5 years after simultaneous implant placement and guided bone regeneration procedures - a randomized, controlled clinical trial. *Clin Oral Implants Res.* 2015;26(1):28–34.
40. Han JY, Jung GU. Labial and lingual/palatal bone thickness of maxillary and mandibular anteriors in human cadavers in Koreans. *J Periodontal Implant Sci.* 2011;41(2):60–6.
41. Chappuis V, Araújo MG, Buser D. Clinical relevance of dimensional bone and soft tissue alterations post-extraction in esthetic sites. *Periodontol 2000.* 2017;73(1):73–83.
42. Thoma DS, Bienz SP, Lim HC, Lee WZ, Hämmerle CHF, Jung RE. Explorative randomized controlled study comparing soft tissue thickness, contour changes, and soft tissue handling of two ridge preservation techniques and spontaneous healing two months after tooth extraction. *Clin Oral Implants Res.* 2020;31(6):565–74.
43. Roe P, Kan JYK, Rungcharassaeng K, Caruso JM, Zimmerman G, Mesquida J. Horizontal and vertical dimensional changes of peri-implant facial bone following immediate placement and provisionalization of maxillary anterior single implants: a 1-year cone beam computed tomography study. *Int J Oral Maxillofac Implants.* 27(2):393–400.
44. Degidi M, Daprile G, Nardi D, Piattelli A. Immediate Provisionalization of Implants Placed in Fresh Extraction Sockets Using a Definitive Abutment: The Chamber Concept. *Int J Periodontics Restor Dent.* 2013;33(5):559–65.