

PROTECTIVE ROLE OF FOLIC ACID AND ZINC CHLORIDE ON ARSENIC INDUCED PULPAL TISSUE TOXICITY OF RATS (HISTOLOGICAL AND IMMUNOHISTOCHEMICAL STUDY)

Maii I. Sholqamy^{*}, Saher Sayed Mohammed^{**} and Mary Moheb Ramzy^{***}

ABSTRACT

Background: Arsenic was used in medicine, cosmetics industry, and agriculture. Nowadays, using arsenic in endodontics has greatly declined due to the severe damage to vital pulp tissue, and periodontium. Folic acid is one of the forms of vitamin B9 and it possesses a significant antioxidant effect. Zinc performs proapoptotic, anti-inflammatory and protective antioxidant activities.

Objective: Evaluation of effect of folic acid and zinc chloride (ZnCl₂) on arsenic treated pulp tissue of rats.

Methodology: Twenty-five rats were divided into five groups; each group consisted of 5 rats: Group (1); served as a control without any treatments. Experimental groups (2,3 and 4); arsenic treated group, folic acid treating in arsenic treated group and ZnCl₂ treating in arsenic treated group sequentially. After 24 hours from the last dose, specimens were taken and processed for H&E, and immunohistochemical stains: Nrf2 and TNF- α , morphometric analysis and statistical analysis.

Results: Groups 1,3 and 4 showed mostly Nrf2 negative immunoreactivity in odontoblastic cell layer and faint Nrf2 immunoreactivity in pulp tissue. But group 2 had strong Nrf2 positive immunoreactivity in cytoplasm and nucleus of disorganized odontoblastic cell layer and in pulp tissue. Groups 1 and 3 showed very weak TNF- α immunoreactivity in pulp tissue. But group 2 had very strong positive TNF- α immunoreactivity in pulp tissue. While group 4 showed TNF- α negative immunoreactivity in pulp tissue.

Conclusion: As₂O₃ has a toxic effect on pulp tissue through increasing the reactive oxygen species. ZnCl₂ has a powerful detoxification effect more than folic acid in arsenic treated pulp tissue.

KEYWORDS: Arsenic, folic acid, zinc chloride, Nrf2 and TNF- α

* Lecturer of Oral and Maxillofacial Pathology – Faculty of Dentistry, Minia University, Egypt

** Assistant professor of Oral Biology – Faculty of Dentistry, Minia University, Egypt

*** Lecturer of Oral Biology – Faculty of Dentistry, Minia University, Egypt

INTRODUCTION

Arsenic (As) is a natural element found in air, soil, food, and water. Arsenic was found to cause many adverse effects including gastro-intestinal, cardiac, renal, bone marrow, central nervous system and hepatic damage and several types of cancer in both human and animal populations (**Korany, Ahmed, Halawany, & Ahmed, 2019; Noman et al., 2015**).

Concerning oral tissues, high levels of arsenic exposure was associated with increased arsenic-induced lesions of the tongue, gingiva, and buccal mucosa (**Syed et al., 2013**). Arsenic is toxic to vital pulp, which can cause severe damage to osteomyelitis of the jaw. Arsenic has remarkable toxic effect on rat pulpal cells as well as in human cells due to production of reactive oxygen species (ROS) (**Nassar et al., 2021**).

Folic acid is one of the forms of the water-soluble vitamin B9. It is also one of the constituents of vitamin B complex. Folic acid is required during periods of rapid cell division and growth. It is involved in protein and DNA synthesis. It is essential in cellular division and new cell production. It is required for production of healthy red blood cells and prevention of anemia. Moreover, it possesses a significant antioxidant effect and reduces oxidative stress. Concerning oral tissues, folic acid is essential for the maintenance of intact oral mucosa (**George, Shobha, & Lazarus, 2013; N. Li et al., 2021**).

Zinc is a trace element present in the Earth's crust as well as in the human body, essential for a broad range of biological processes. It is also present in foods like meat, seafood, cereals, milk, and milk products. In the oral cavity, it is naturally found in saliva, dental plaque, and tooth enamel and dentin. It is vital for maintaining oral and general health (**Lynch, 2011; Uwitonze, Ojeh, Murererehe, Atfi, & Razaque, 2020**). It has a significant role in basic cellular functions including enzyme activation, cell signaling and metabolism of many enzymes and

proteins. It is also a component of many DNA repair proteins and enzymes. Zinc performs proapoptotic, anti-inflammatory and protective antioxidant activities as it decreases the production of toxic agents such as hydrogen peroxide (H₂O₂) and ROS (**Uwitonze et al., 2020**).

Nuclear factor-erythroid factor 2-related factor 2 (Nrf2) is considered as an essential transcription factor that controls the expression of many genes in the cell in normal and stressed situations as inflammatory response, antioxidative defense, autophagic mechanism and detoxification. The main function of Nrf2 is an antioxidant regulator (**Zang, Mathew, & Cui, 2020**).

One of the primary indicator genes for antioxidant condition is Nrf2. In most types of cancer, there is an increase in Nrf2 amounts (**HINTSALA et al., 2016**). Translocation of Nrf2 to the nucleus starts the transcription of many genes that function as antioxidizing agents, detoxifying enzymes, and stress response proteins (**Fuse & Kobayashi, 2017**).

Tumor necrosis factor alpha (TNF- α) is a potent pro-inflammatory cytokine. TNF- α participates in vasodilatation and edema formation, and leukocyte adhesion to epithelium through expression of adhesion molecules; it regulates blood coagulation and contributes to oxidative stress in sites of inflammation (**Zelová & Hošek, 2013**).

MATERIALS AND METHODS

Drugs and animals

Arsenic trioxide (As₂O₃) was purchased from Sigma-Aldrich, ST. USA. A stock solution of As₂O₃ was prepared by dissolving it in 0.12 N HCL (0.5 mg/kg body weight). Folic acid was purchased from Alpha Chemika Company and zinc chloride (ZnCl₂) was purchased from Piochem. Twenty-five male Wistar albino rats (200-250 gm) were bought from Assiut University Joint Animal Breeding Unit. Rats were kept in 23±2 °C and a lighting cycle of 12

hours light / dark. The procedures of the experiment were conducted in strict compliance with ethics prepared by INSA and (WHO/UNESCO).

Experimental Design

Twenty-five rats were divided into five groups, each group consisted of 5 rats: Group (1); served as a control without any treatments. Experimental groups (2,3 and 4); received a daily oral dose of 3 mg/kg body weight of As₂O₃ for 15 days. Group (3); received a daily oral dose of 0.1 mg/kg of folic acid for 2 months after first 15 days of As₂O₃. Group (4); received a daily oral dose of 2 mg/kg of ZnCl₂ for 2 months after first 15 days of As₂O₃. After 24 hours from the last dose, rats were anesthetized using ether inhalation, sacrificed, carefully dissected and specimens from the mandible were processed for Hematoxylin and eosin (H&E), immunohistochemical stains and morphometric analysis. Perfusion fixation was used, and the specimens were fixed in 10% neutral buffered formalin and processed for light microscopic study (Atia, 2021).

Hematoxylin and Eosin (H&E) staining

The fixed slides were rehydrated in descending concentrations of alcohol, washed in distilled water for 5 minutes. The slides were immersed in filtered hematoxylin stain for 3 minutes and then washed with distilled water twice. The slides were immersed in filtered eosin stain for 5 seconds and then washed with distilled water. Dried slides were immersed in xylene, mounted with Canada balsam then cover slips were placed and left to dry (Llewellyn, 2009).

Immunohistochemical Staining

For all specimens, 4-microns thick paraffin embedded tissue sections were prepared and mounted on positively charged glass slides. The sections were deparaffinized by warm xylene, rehydrated in descending concentrations of alcohol and immersed in phosphate buffered saline (PBS). The slides were

completely immersed in a bath of antigen retrieval solution (pH 9). Then slides were incubated by PBS and treated by 0.3% H₂O₂. The primary Anti-Nrf2 antibody (GTX103322) Genetex Co.-(1:500) was applied to cover the sections completely followed by incubation at room temperature for overnight. Then the slides were washed by PBS. The slides were completely covered with secondary antibody HRP Envision kit (DAKO) for 20 mins; the slides were washed by PBS and incubated with diaminobenzidine (DAB) for 10 mins. Washed by PBS then counter staining with Hematoxylin Harris, dehydration of sections in ascending concentration of alcohol and cleared in xylene. Then cover slipped for microscopic examination and quantification. All steps were repeated with the primary antibody tumor necrosis factor alpha Anti-TNF α (Kabiraj, Gupta, Khaitan, & Bhattacharya, 2015).

Photomicrography analysis

H&E slides were photographed using a digital video camera LEICA DFC295 which was mounted on a light microscope in histopathological laboratory in Minia University Dental Hospital. Then images were transferred to the computer system for analysis. Morphometric analysis: All the steps performed for immunohistochemical evaluation were carried out using image analysis software (ImageJ, version 1.41). Phase analysis was calculated automatically to give the percentage of immunopositivity area to the total area of microscopic field. Image analysis was performed at the Oral Pathology Department, Minia University Dental Hospital.

Statistical analysis

The collected data were tabulated using Microsoft Excel (Microsoft Office 2019). The mean area fraction for each case was then calculated and used for statistical analysis. The data was stored and analyzed by SPSS 20 for Windows. For immunostaining data, ANOVA test and paired sample t-test were used for continuous parametric data. Significance level was set as ≤ 0.05 .

RESULTS

H&E results

- **Control group:** H&E-stained sections of pulp in control rats showed pulp tissue with peripherally arranged columnar odontoblasts. Pulp tissue appeared as loose normal connective tissue with numerous fibroblasts and small blood vessels (**Fig.1a**).
- **Arsenic treated group:** H&E-stained sections of pulp in arsenic treated rats showed disorganized odontoblasts on pulpal surface of dentin. Pulp tissue presented degeneration with numerous edematous spaces and extravasated blood. Blood vessels appeared widely dilated and engorged with red blood cells (**Fig.1b**).
- **Folic acid treating in arsenic treated group:** H&E-stained sections in this group presented odontoblasts with normal morphology and arrangement on pulpal surface of dentin. Pulp tissue appeared loose with numerous fibroblasts. Absence of extravasated blood was noted while blood vessels manifested congestion (**Fig.1c**).
- **Zinc chloride treating in arsenic treated group:** H&E-stained sections in this group showed slightly disorganized odontoblasts with slightly congested pulp. Like folic acid group no evidence of extravasated blood was noted (**Fig.1d**).

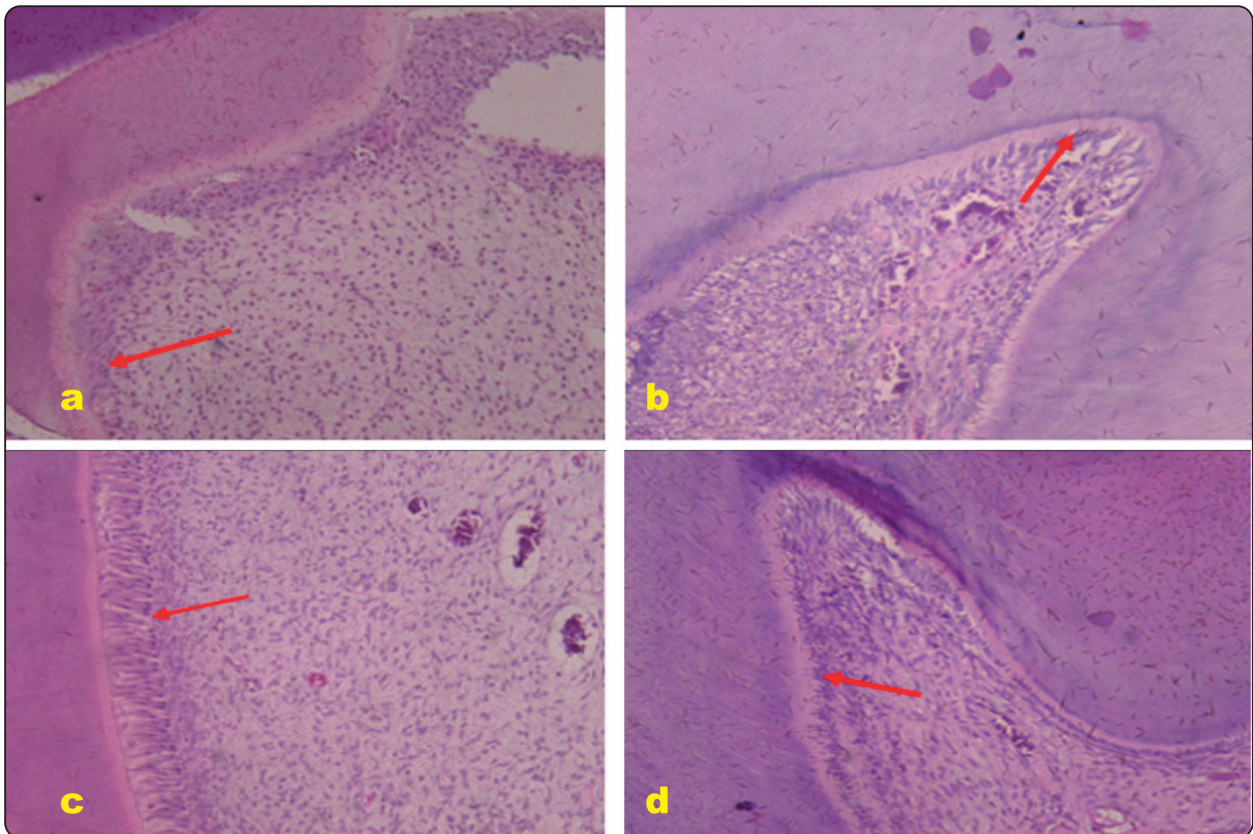


Fig. (1) : H&E staining for: a. Control group showing normal pulp tissue with small blood vessel, columnar odontoblasts arranged on the pulpal surface of dentin (red arrow) and numerous normal pulpal fibroblasts b. Arsenic treated group showing disorganized odontoblasts (red arrow), dilated and congested blood vessels, extravasated RBCs and degenerated pulp with edematous spaces. c. Folic acid treating in arsenic treated group showing columnar and regularly arranged odontoblastic layer (red arrow) and congested blood vessels with no extravasated blood. d. Zinc chloride treating in arsenic treated group showing pulp tissue with slightly ill-defined odontoblasts (red arrow) and congested blood vessels with no extravasated RBCs (20x).

Nrf2 Immunohistochemical staining Results:

- **Control untreated group:** Odontoblastic cell layer showed mostly a negative immunoreactivity of Nrf2. Also, pulp tissue showed weak expression of Nrf2 (**Fig.2a**).
- **Arsenic treated group:** Nrf2 had strong positive immunoreactivity in cytoplasm and nucleus of disorganized odontoblast cell layer. Moreover, there was positive immunoreactivity in pulp tissue cells (**Fig.2b**).
- **Folic acid treating in arsenic treated group:** Nrf2 had a negative immunoreactivity in odontoblastic cell layer. With faint immunoreactivity of Nrf2 in pulp tissue cells (**Fig.2c**).
- **Zinc chloride treating in arsenic treated group:** Nrf2 had a negative immunoreactivity in odontoblastic cell layer. With faint immunoreactivity of Nrf2 in pulp tissue cells (**Fig.2d**).

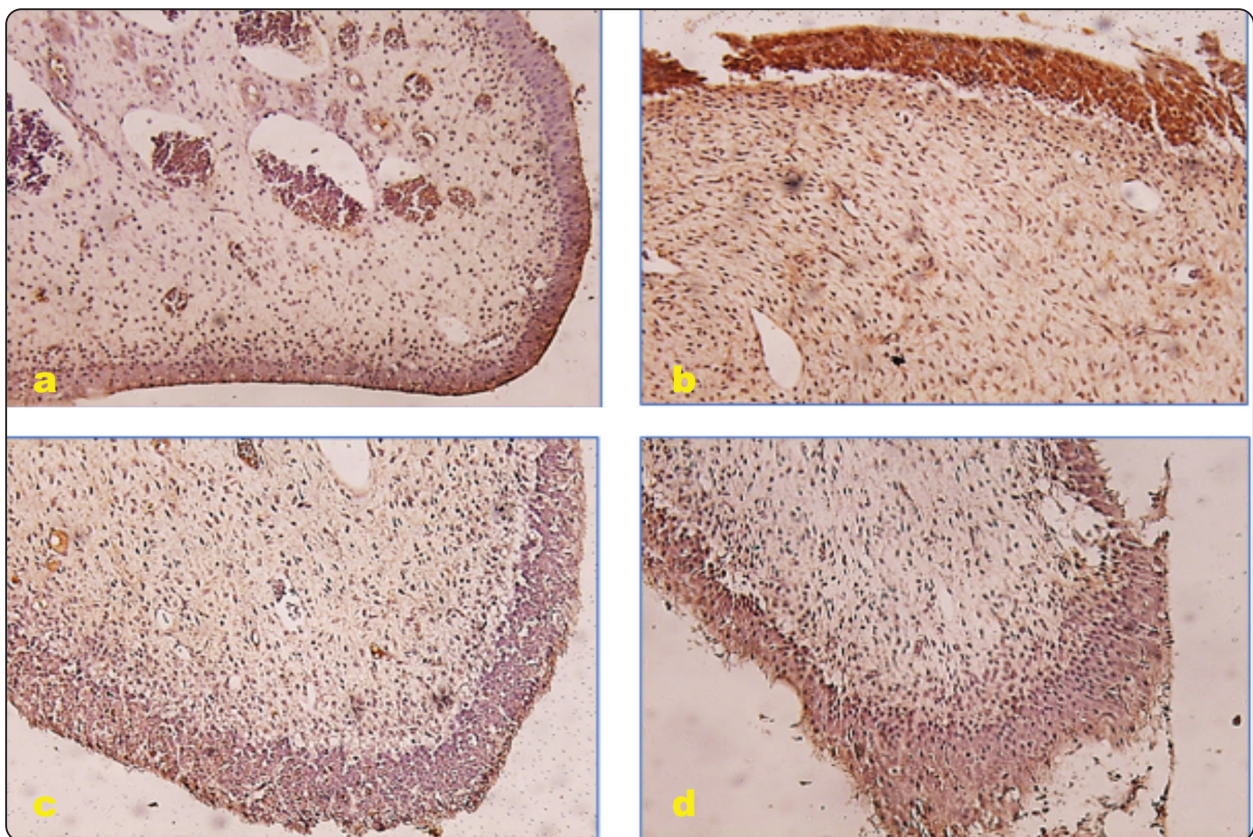


Fig. (2): Immunohistochemical staining of Nrf2 showing a. Control group showing mostly negative immunoreactivity in odontoblastic cell layer and weak immunoreactivity in pulp tissue. b. Arsenic treated group with strong positive immunoreactivity in cytoplasm and nucleus of odontoblastic cell layer. Moreover, there was positive immunoreactivity in pulp tissue cells. c. Folic acid treating in arsenic treated group with Nrf2 showing negative immunoreactivity in odontoblastic cell layer. With faint immunoreactivity of Nrf2 in pulp tissue cells. d. Zinc chloride treating in arsenic treated group with Nrf2 showing negative immunoreactivity in odontoblastic cell layer. With faint immunoreactivity of Nrf2 in pulp tissue cells. (20x).

TNF- α Immunohistochemical staining Results

- **Control untreated group:** TNF- α had very weak immunoreactivity in pulp tissue with negative immunoreactivity in endothelial lining of blood vessels (**Fig.3a**).
- **Arsenic treated group:** TNF- α had very strong positive immunoreactivity in pulp tissue cells with positive immunoreactivity in endothelial lining of blood vessels (**Fig.3b**).
- **Folic acid treating in arsenic treated group:** TNF- α had faint immunoreactivity of TNF- α in pulp tissue cells with negative immunoreactivity in endothelial lining of blood vessels (**Fig.3c**).
- **Zincchloridetreatinginarsenic treated group:**

TNF- α had a negative immunoreactivity in pulp tissue cells with negative immunoreactivity in endothelial lining of blood vessels (**Fig.3d**).

Statistical Analysis

Results of immunohistochemical expression of Nrf2 in tissues of different groups were compared using one way ANOVA. There was a significant difference between control group and the other groups and between arsenic group treated by folic acid and two other treated groups ($p= 0.000$). But the expression of Nrf2 in arsenic treated group and arsenic group treated by $ZnCl_2$ was non-significant ($p=0.47$) (**Table 1**). The mean area fraction of control group was the lowest while the arsenic treated group was the highest (**Fig. 4**).

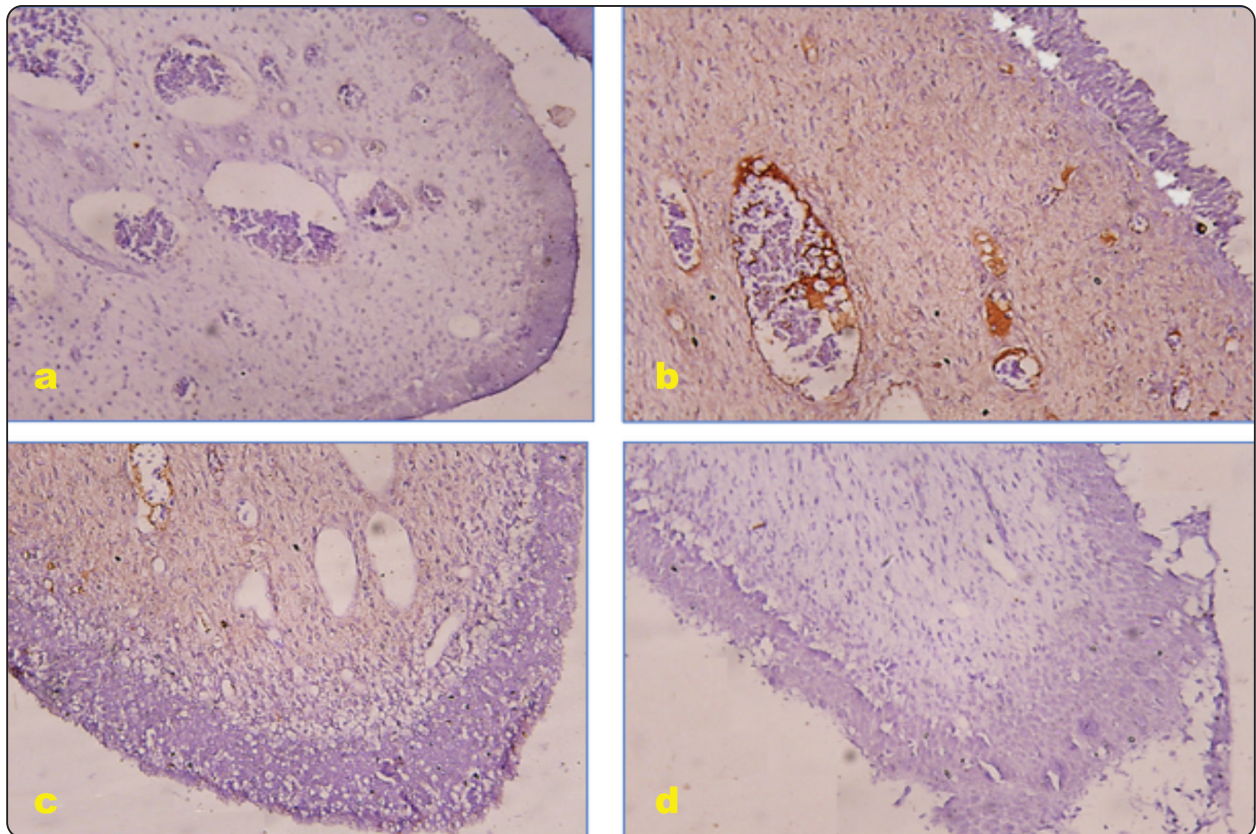


Fig (3): Immunohistochemical staining of TNF- α showing a. Control group exhibiting very weak immunoreactivity in pulp tissue. b. Arsenic treated group with very strong positive immunoreactivity in pulp tissue. c. Folic acid treating in arsenic treated group with faint immunoreactivity in pulp tissue. d. Zinc chloride treating in arsenic treated group showing negative immunoreactivity in pulp tissue. (20x).

Results of immunohistochemical expression of TNF- α in tissues of different groups were compared using one way ANOVA. There was a non-significant difference between control group and arsenic group

treated by ZnCl₂ (p= 0 .768) (**Table 2**). But the expression of TNF- α in arsenic treated group and arsenic group treated by folic acid was significant (p=0.000) with other groups (**Fig. 5**).

TABLE (1): Dependent Variable: area fraction of Nrf2 expression:

(I) group	(J) group	Mean Difference (I-J)	Std. Error	Sig.
Arsenic treated group	Control untreated group	9.245140161*	.270860772	.000
	Arsenic group treated by folic acid	6.332609910*	.267435561	.000
	Arsenic group treated by ZnCl ₂	.637137130	.367784208	.470

*. The mean difference is significant at the 0.05 level.

TABLE (2): Dependent Variable: area fraction of TNF- α expression:

(I) group	(J) group	Mean Difference (I-J)	Std. Error	Sig.
Control untreated group	Arsenic treated group	-20.012156100-*	.124134600	.000
	Arsenic group treated by folic acid	-15.319223100-*	.185503242	.000
	Arsenic group treated by ZnCl ₂	.021528900	.016348030	.768

*. The mean difference is significant at the 0.05 level.

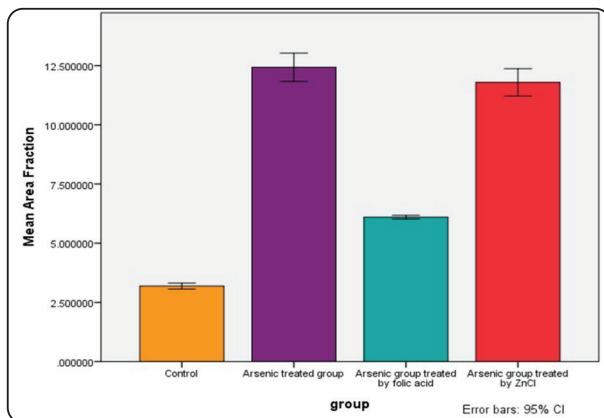


Fig. (4): Bar chart showing the mean of area fractions of Nrf2 between different groups

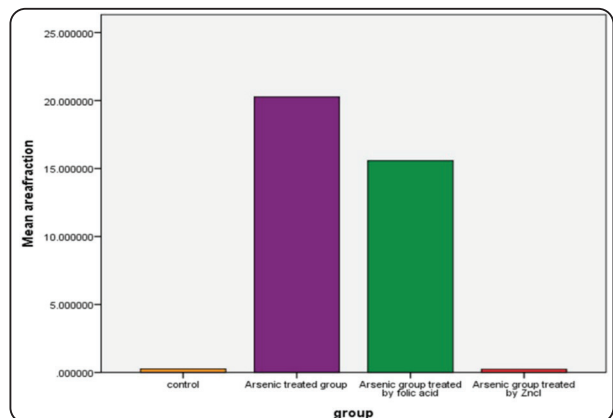


Fig. (5): Bar chart showing the mean of area fractions of TNF- α between different groups

DISCUSSION

Several mechanisms of arsenic toxicity had been proposed including oxidative stress, induction of apoptosis, inhibition of DNA repair, chromosomal aberrations, modification of cellular signaling, aberrant gene expression caused by epigenetic modifications, and altered phenotype of stem cell populations (**Dangleben, Skibola Cf Fau - Smith, & Smith, 2013**).

Oxidative stress is a sensitive indicator of toxicity especially for environmental contaminants and pollutants (**Ahmad, 1995**).

The present work revealed massive pathologic changes in arsenic treated group summarized in disorganization of odontoblastic cell layer together with pulp congestion and vacuolar degeneration. Folic acid and zinc chloride treated groups showed improvement in the morphology and arrangement of odontoblasts and apparent decrease in pulp congestion.

The type of arsenic used in this study was As_2O_3 (the main type of inorganic arsenic found in Portland cement based materials) (**De-Deus et al., 2009**). Our results showing disorganized odontoblasts came in accordance with an in-vitro study carried on rat pulpal cells using a daily oral dose of 3 mg/kg body weight of As_2O_3 for 15 days. The study proved that exposure of cultured pulpal fibroblasts to As_2O_3 had cytotoxic effect. Pulpal fibroblasts appeared contracted with spherical morphology and wide intercellular spaces (**Nassar et al., 2021**).

Arsenic is known to be able to induce apoptosis through the induction of ROS (**Rossman, 2003**). In the absence of phagocytic cells the apoptotic cells proceed to secondary necrosis, that has morphological features of primary necrotic cells (**Krysko, Berghe, Parthoens, D'Herde, & Vandenabeele, 2008**). Our finding suggesting necrotic pulpal cells came online with a study which investigated the effect of intraperitoneal injection of single dose of 10mg/kg

As_2O_3 on solid murine tumors. Authors found that As_2O_3 caused central tumor necrosis via vascular shut down (**Lew, Brown, Griffin, Song, & Kim, 1999**). The mechanism of vascular congestion and decrease blood flow to tissues might be contributed to the ability of As_2O_3 to induce selective endothelial cell injury resulting in vascular shut down (**Y. M. Li & Broome, 1999**).

Oxidative stress through chronic arsenic exposure associated with methyl insufficiency and loss of DNA methylation in animals may be the reason for the histological changes. It is therefore believed that oxidative stress is associated with tissue architectural change in arsenic poisoning. Moreover, the production of ROS has been implicated to contribute to cell injury associated with AS exposure (**Noman et al., 2015**).

Our results related to folic acid treated group is supported by an investigation carried on male rats to clarify the effect of oral supplementation of 36 $\mu\text{g/kg/day}$ folic acid upon short term arsenic induced systemic and pancreatic islet cells DNA damage. Agarose gel electrophoresis of DNA from lymphocytes and islet cells in arsenic group showed DNA smearing. The latter was proved to be reduced with administration of folic acid (**Majumdar et al., 2009**).

Our study outcomes related to alleviation of the toxic effect of arsenic on pulpal tissue by $ZnCl_2$ might be explained based on the function of Zn in protecting biological structure from free radical damage (**Azzouz et al., 2014**). Structures, the bioaccumulation of $ZnCl_2$ in digestive glands and hemolymph was evaluated. Exposure to $ZnCl_2$ caused damage to hemocytes and digestive cells after 7 days of exposure in concentrations of 0.5 and 1 mg/L (**Pagano et al., 2017**).

In the current study, there was a strong immunoreactivity of Nrf2 in nucleus and cytoplasm of disorganized odontoblastic cell layer in arsenic group when compared to other groups. This means

that inorganic arsenic significantly activates Nrf2 pathway in response to oxidative stress and inflammation occurred by toxic arsenic. Our results are in agreement with previous studies that reported that inorganic arsenic induced Nrf2 pathway in hepatocyte cells (**Han et al., 2017**), endothelial cells (**Meng et al., 2010**) and keratinocytes (**Pi, Qu, Reece, Kumagai, & Waalkes, 2003**).

Regarding the arsenic group, which was treated by folic acid for 2 months, there was a significant decrease of Nrf2 expression in nucleus and cytoplasm of odontoblast cells when compared to arsenic treated group, which indicates that the oxidative stress induced by arsenic is decreased. Our findings are in accordance with (**Ma et al., 2015**) who stated that the folic acid supplementation significantly inhibited the formation of ROS in arsenic treated cells of rat.

Concerning the arsenic group, which was treated by ZnCl₂ for 2 months, the expression of Nrf2 was nearly equal to the expression of Nrf2 in the arsenic only group (statistically insignificantly). This is explained by the importance of Zn in expression and transcription function of Nrf2 (**B. Li et al., 2014**). Moreover, (**Cortese, Suschek, Wetzell, Kröncke, & Kolb-Bachofen, 2008**) reported that the antioxidant property of Zn may be mediated by up-regulation of Nrf2.

Our immunohistochemical results using TNF- α in arsenic treated group (statistically significant compared to other groups) is supported by a study which investigated the effects of arsenic on T cell survival and function in mononuclear cells in tissue culture. Arsenic was found to induce TNF- α release from mononuclear cells and caused a cytotoxic effect on T cells pointing to the role of TNF signaling in arsenic-induced T helper cell apoptosis (**Yu, Liao, Chang, Yu, & Chen, 2002**).

The common benefits of folic acid in vascular diseases depends on enhancing endothelial nitric oxide (eNO) production. Folate promotes eNO

synthesis and exhibits anti-inflammatory effect. It stimulates endogenous tetrahydrobiopterin (H₄B) regeneration (a cofactor necessary for eNO synthesis), inhibits intracellular superoxide generation, and so increases the half-life of NO (**Das, 2003**).

(**Bao et al., 2010**) reported that zinc can induce antioxidant mechanism and inhibit inflammatory cytokines and oxidative stress markers and zinc decreased the generation of TNF- α . (**von Bülow et al., 2007**) stated that zinc can suppress the activation of the TNF promoter in intact cells, also zinc inhibits TNF release from human monocytes. Application of ZnCl₂ on arsenic treated group reduces amount of inflammation, which is supported by negative immunoreactivity of TNF- α in our results.

In contrast to our results (negative immunoreactivity in pulp vasculature), the influence of ZnCl₂ at 1, 10 and 100 μ M concentrations on the production of TNF in bovine aorta endothelial cells (BAECs) was investigated. Zinc ions were found to induce TNF activity (**Szuster-Ciesielska, Łokaj, & Kandefler-Szerszeń, 2000**).

CONCLUSION

As₂O₃ has a toxic effect on pulp tissue through increasing the ROS. Both folic acid and Zn can detoxicate the effect of arsenic on pulp tissue. Folic acid decreases the amount of formation of ROS, while Zn up-regulate the expression and function of Nrf2. ZnCl₂ has anti-inflammatory activity in arsenic treated pulp tissue. ZnCl₂ has a more powerful detoxification effect than folic acid in arsenic treated pulp tissue.

REFERENCES

- Ahmad, S. (1995). Oxidative stress from environmental pollutants. Archives of Insect Biochemistry and Physiology, 29(2), 135-157. doi:<https://doi.org/10.1002/arch.940290205>
- Atia, M. (2021). Adipose-derived mesenchymal stem

- cells ameliorate the damages induced by arsenic trioxide in the testis of rats. *International Journal of Cancer and Biomedical Research*, 5(1), 109-122. doi:10.21608/jcbr.2020.38276.1060
- Azzouz, I., Trabelsi, H., Hanini, A., Ferchichi, S., Tebourbi, O., Sakly, M., & Abdelmelek, H. (2014). Interaction between nanoparticles generated by zinc chloride treatment and oxidative responses in rat liver. *International journal of nanomedicine*, 9, 223-229. doi:10.2147/IJN.S55974
 - Bao, B., Prasad, A. S., Beck, F. W., Fitzgerald, J. T., Snell, D., Bao, G. W., . . . Cardozo, L. J. (2010). Zinc decreases C-reactive protein, lipid peroxidation, and inflammatory cytokines in elderly subjects: a potential implication of zinc as an atheroprotective agent. *Am J Clin Nutr*, 91(6), 1634-1641. doi:10.3945/ajcn.2009.28836
 - Cortese, M. M., Suschek, C. V., Wetzel, W., Kröncke, K. D., & Kolb-Bachofen, V. (2008). Zinc protects endothelial cells from hydrogen peroxide via Nrf2-dependent stimulation of glutathione biosynthesis. *Free Radic Biol Med*, 44(12), 2002-2012. doi:10.1016/j.freeradbiomed.2008.02.013
 - Dangleben, N. L., Skibola Cf Fau - Smith, M. T., & Smith, M. T. (2013). Arsenic immunotoxicity: a review. *Environmental Health* 12, 73. doi:10.1186/1476-069X-12-73
 - Das, U. N. (2003). Folic acid says NO to vascular diseases. *Nutrition*, 19(7), 686-692. doi:https://doi.org/10.1016/S0899-9007(02)01044-4
 - De-Deus, G., de Souza, M. C., Sergio Fidel, R. A., Fidel, S. R., de Campos, R. C., & Luna, A. S. (2009). Negligible expression of arsenic in some commercially available brands of Portland cement and mineral trioxide aggregate. *J Endod*, 35(6), 887-890. doi:10.1016/j.joen.2009.03.003
 - Fuse, Y., & Kobayashi, M. (2017). Conservation of the Keap1-Nrf2 System: An Evolutionary Journey through Stressful Space and Time. *Molecules*, 22(3). doi:10.3390/molecules22030436
 - George, J., Shobha, R., & Lazarus, F. (2013). Folic acid: A positive influence on periodontal tissues during health and disease. *International Journal of Health & Allied Sciences*, 2. doi:10.4103/2278-344X.120582
 - Han, X.-D., Zhang, Y.-Y., Wang, K.-L., Huang, Y.-P., Yang, Z.-B., & Liu, Z. (2017). The involvement of Nrf2 in the protective effects of (-)-Epigallocatechin-3-gallate (EGCG) on NaAsO(2)-induced hepatotoxicity. *Oncotarget*, 8(39), 65302-65312. doi:10.18632/oncotarget.18582
 - HINTSALA, H.-R., JOKINEN, E., HAAPASAARI, K.-M., MOZA, M., RISTIMÄKI, A., SOINI, Y., . . . KARIHTALA, P. (2016). Nrf2/Keap1 Pathway and Expression of Oxidative Stress Lesions 8-hydroxy-2'-deoxyguanosine and Nitrotyrosine in Melanoma. *Anticancer Research*, 36(4), 1497-1506.
 - Kabiraj, A., Gupta, J., Khaitan, T., & Bhattacharya, P. T. (2015). Principle and techniques of immunohistochemistry a review.
 - Korany, R., Ahmed, K., Halawany, H., & Ahmed, K. (2019). Effect of Long-Term Arsenic Exposure On Female Albino Rats With Special Reference to the Protective Role of Spirulina Platensis. *Exploratory Animal and Medical Research*, 9.
 - Krysko, D. V., Berghe, T. V., Parthoens, E., D'Herde, K., & Vandenamele, P. (2008). Chapter 16 Methods for Distinguishing Apoptotic from Necrotic Cells and Measuring Their Clearance. In *Methods in Enzymology* (Vol. 442, pp. 307-341): Academic Press.
 - Lew, Y. S., Brown, S. L., Griffin, R. J., Song, C. W., & Kim, J. H. (1999). Arsenic Trioxide Causes Selective Necrosis in Solid Murine Tumors by Vascular Shutdown. *Cancer Research*, 59(24), 6033.
 - Li, B., Cui, W., Tan, Y., Luo, P., Chen, Q., Zhang, C., Cai, L. (2014). Zinc is essential for the transcription function of Nrf2 in human renal tubule cells in vitro and mouse kidney in vivo under the diabetic condition. *J Cell Mol Med*, 18(5), 895-906. doi:10.1111/jcmm.12239
 - Li, N., Zhao, Y., Shen, Y., Cheng, Y., Qiao, M., Song, L., & Huang, X. (2021). Protective effects of folic acid on oxidative damage of rat spleen induced by lead acetate. *Ecotoxicology and Environmental Safety*, 211, 111917. doi:https://doi.org/10.1016/j.ecoenv.2021.111917
 - Li, Y. M., & Broome, J. D. (1999). Arsenic targets tubulins to induce apoptosis in myeloid leukemia cells. *Cancer Res*, 59(4), 776-780.
 - Llewellyn, B. D. (2009). Nuclear staining with alum hematoxylin. *Biotechnic & Histochemistry*, 84(4), 159-177. doi:10.1080/10520290903052899
 - Lynch, R. J. M. (2011). Zinc in the mouth, its interactions with dental enamel and possible effects on caries; a review of the literature. *International Dental Journal*, 61, 46-54. doi:https://doi.org/10.1111/j.1875-595X.2011.00049.x
 - Ma, Y., Zhang, C., Gao, X.-B., Luo, H.-Y., Chen, Y., Li, H.-

- h., . . . Lu, C.-L. (2015). Folic acid protects against arsenic-mediated embryo toxicity by up-regulating the expression of Dvr1. *Scientific Reports*, 5(1), 16093. doi:10.1038/srep16093
- Majumdar, S., Mukherjee, S., Maiti, A., Karmakar, S., Das, A. S., Mukherjee, M., Mitra, C. (2009). Folic acid or combination of folic acid and vitamin B12 prevents short-term arsenic trioxide-induced systemic and mitochondrial dysfunction and DNA damage. *Environmental Toxicology*, 24(4), 377-387. doi:https://doi.org/10.1002/tox.20442
 - Meng, D., Wang, X., Chang, Q., Hitron, A. J., Zhang, Z., Xu, M., . . . Shi, X. (2010). Arsenic promotes angiogenesis in vitro via a heme oxygenase-1-dependent mechanism. *Toxicol Appl Pharmacol*, 244 3, 291-299.
 - Nassar, M., Dargham, A., Jamleh, A., Tamura, Y., Hiraishi, N., & Tagami, J. (2021). The Hormetic Effect of Arsenic Trioxide on Rat Pulpal Cells: An In Vitro Preliminary Study. *Eur J Dent*, 15(02), 222-227.
 - Noman, A. S. M., Dilruba, S., Mohanto, N. C., Rahman, L., Khatun, Z., Riad, W., . . . Haque, A. (2015). Arsenic-induced Histological Alterations in Various Organs of Mice. *Journal of cytology & histology*, 6(3), 323. doi:10.4172/2157-7099.1000323
 - Pagano, M., Porcino, C., Briglia, M., Fiorino, E., Vazzana, M., Silvestro, S., & Faggio, C. (2017). The Influence of Exposure of Cadmium Chloride and Zinc Chloride on Haemolymph and Digestive Gland Cells from *Mytilus galloprovincialis*. *International Journal of Environmental Research*, 11(2), 207-216. doi:10.1007/s41742-017-0020-8
 - Pi, J., Qu, W., Reece, J. M., Kumagai, Y., & Waalkes, M. P. (2003). Transcription factor Nrf2 activation by inorganic arsenic in cultured keratinocytes: involvement of hydrogen peroxide. *Exp Cell Res*, 290(2), 234-245. doi:10.1016/s0014-4827(03)00341-0
 - Rossman, T. G. (2003). Mechanism of arsenic carcinogenesis: an integrated approach. *Mutat Res*, 533(1-2), 37-65. doi:10.1016/j.mrfmmm.2003.07.009
 - Syed, E. H., Melkonian S Fau - Poudel, K. C., Poudel Kc Fau - Yasuoka, J., Yasuoka J Fau - Otsuka, K., Otsuka K Fau - Ahmed, A., Ahmed A Fau - Islam, T., . . . Jimba, M. (2013). Arsenic exposure and oral cavity lesions in Bangladesh. *J Occup Environ Med.* , 55(1), 59-66. doi:10.1097/JOM.0b013e31826bb686.
 - Szuster-Ciesielska, A., Łokaj, I., & Kandfer-Szerszeń, M. (2000). The influence of cadmium and zinc ions on the interferon and tumor necrosis factor production in bovine aorta endothelial cells. *Toxicology*, 145(2), 135-145. doi:https://doi.org/10.1016/S0300-483X(00)00147-5
 - Uwitonze, A. M., Ojeh, N., Murererehe, J., Atfi, A., & Razzaque, M. S. (2020). Zinc Adequacy Is Essential for the Maintenance of Optimal Oral Health. *Nutrients*, 12(4). doi:10.3390/nu12040949
 - von Bülow, V., Dubben, S., Engelhardt, G., Hebel, S., Plümäkers, B., Heine, H., . . . Haase, H. (2007). Zinc-dependent suppression of TNF-alpha production is mediated by protein kinase A-induced inhibition of Raf-1, I kappa B kinase beta, and NF-kappa B. *J Immunol*, 179(6), 4180-4186. doi:10.4049/jimmunol.179.6.4180
 - Yu, H. S., Liao, W. T., Chang, K. L., Yu, C. L., & Chen, G. S. (2002). Arsenic induces tumor necrosis factor alpha release and tumor necrosis factor receptor 1 signaling in T helper cell apoptosis. *J Invest Dermatol*, 119(4), 812-819. doi:10.1046/j.1523-1747.2002.00475.x
 - Zang, H., Mathew, R. O., & Cui, T. (2020). The Dark Side of Nrf2 in the Heart. *Frontiers in Physiology*, 11. doi:10.3389/fphys.2020.00722
 - Zelová, H., & Hošek, J. (2013). TNF- α signalling and inflammation: interactions between old acquaintances. *Inflammation Research*, 62(7), 641-651. doi:10.1007/s00011-013-0633-0