

EFFECT OF PLATELET RICH PLASMA AGAINST THE CYTOTOXICITY INDUCED BY 5-FLUOROURACIL IN ALBINO RATS' TONGUE (HISTOLOGICAL AND IMMUNOHISTOCHEMICAL STUDY)

Amira A. R. Moawad ^{***} and Sally H. Abo Baker ^{****}

ABSTRACT

Introduction: 5-Fluorouracil (5-FU) is considered the backbone of most of chemotherapy regimens, it has been established for the treatment of several neoplasms but one of its most common complications is oral mucositis including tongue epithelium.

Aim: This study aimed to explore the effect of Platelet rich plasma (PRP) against the cytotoxicity induced by 5-Fluorouracil in albino rats' tongue.

Material & Methods: forty male Albino rats were used in this study, 10 rats were used as PRP donors and the other 30 rats were classified into 3 groups, 10 rats each: Group I: 60 mg/kg of saline was injected ip. on day zero, and other 40 mg/kg was injected on the second day. Group II: 60 mg/kg of 5-FU was injected ip. on day zero, and other 40 mg/kg was injected on the second day. Group III: 60 mg/kg of 5-FU was injected ip. on day zero, and other 40 mg/kg was injected on the second day then after 24 hours, 1ml/rat/day of PRP was injected locally into the tongue mucosa for 3 weeks. The animals were sacrificed after 1 week of the second injection in group I and II and at end of third week of PRP injection in group III. specimens were prepared for histological examination and immunohistochemical staining for CD3.

Results: Histological examination revealed significant improvement of mucosal tongue epithelium and connective tissue in group III samples when compared to group II, supported by immunohistochemical results of CD3.

Conclusion: PRP has accelerating healing effect on tongue epithelium and connective tissue.

KEYWORDS: 5-Fluorouracil, tongue papillae, PRP, CD3.

* Department of Oral Biology, Faculty of Dentistry, Mansoura University

** Department of Maxillofacial Surgery and Diagnostic Science, Faculty of Dentistry, Majmaah University. Saudi Arabia.

*** Department of Basic Dental & Medical sciences, Faculty of Dentistry, Ha'il University.

INTRODUCTION

5-Fluorouracil (5-FU) has been greatly used for the treatment of many tumors such as head and neck squamous cell carcinoma ⁽¹⁾, gastrointestinal squamous cell carcinoma and adenocarcinoma ⁽²⁾, and uterine cervix squamous cell carcinoma ⁽³⁾. Its using has been increased in the last decades as the backbone of most of chemotherapy regimens. When it is administered without combination of any other novel cancer therapies it can induces inhibition of DNA replication through prevention of cellular thymidylate synthase ⁽⁴⁾ Besides inhibition of RNA synthesis by the integration of its metabolites ⁽⁵⁾.

Oral mucositis including the tongue remains one of the most common annoying complication of anti-neoplastic radiation and drug therapy ⁽⁶⁾. It mostly appears in 40–80% of patients receiving chemotherapy and it start mildly then gradually becomes more severe within 7 to 10 days of treatment ⁽⁷⁾. Oral mucositis including the tongue is known to be occur as a result of the direct inhibitory effects of chemo-radiotherapy on DNA replication and mucosal cell proliferation, leading to decrease in the renewal capabilities of the epithelium basal cell layer. Subsequently ulceration followed by atrophy of squamous epithelial cells, damage of blood vessels and invasion of inflammatory lymphocytes to the basement region are almost seen ⁽⁸⁾.

The tongue mucosa in rats is made up of an outermost keratinized stratified squamous epithelium below the lamina propria, which is formed of dense connective tissue. The mucosa of the dorsal surface shows various forms of papillae. The anterior part of the dorsal mucosa reveals filiform and fungiform papillae, while the posterior part shows few circumvallate papillae ⁽⁹⁾. It is believed that filiform papillae serve as a reflection of the health condition, so dietary insufficiency or medication toxicity will cause changes to these papillae ⁽¹⁰⁾.

Platelet-rich plasma (PRP) is consists of an concentrated autologous platelet suspended in

plasma that have multiple growth factors such as platelet-derived growth factor (PDGF) and transforming growth factor (TGF)- β 1, vascular endothelial growth factor (VEGF) insulin-like growth factor-1 (IGF-1) ⁽¹¹⁾. These growth factors release and accelerate wound healing when platelets become activated, ⁽¹²⁾. PRP contains plasma, white blood cells, erythrocytes, and platelets in different amounts that determined according to the device and the used technique ⁽¹³⁾. PRP can also enhance tissue regeneration by improving cell recruitment, proliferation, and differentiation ⁽¹⁴⁾. it has been also proved that PRP also show anti-inflammatory and immunomodulation properties ⁽¹⁵⁾.

some researchers have pointed out to the role of platelets in cancer treatment ⁽¹⁶⁾. PRP may negatively affect the tumor growth and its metastasis in cancer patients ⁽¹⁷⁾, in addition it is also considered a promising alternative for various medical applications as repair of chondral and tendon lesions, restoration of injuries and bone renewal besides curing of plantar fasciitis, severe diabetic foot ulcers and burns. PRP promotes bone, muscle, tendon, cartilage and skin growth and minimizes both pain and inflammation ^(18,19).

The present study aimed to evaluate the effects of PRP against the cytotoxicity induced by 5-Fluorouracil on albino rats' tongue mucosa using histological and immunohistochemical investigations.

MATERIAL AND METHODS

The present study used 40 adult male Albino rats (150-200 gm), they were housed in separate cages under appropriate experimental conditions according to the guidelines of the Animal Ethics Committee. The animals were fed standard pellet diet and tap water throughout the study period. Room temperature (22-24°C) and the animals were exposed to 12:12 hours light dark cycles. The present research protocol was approved by the Ethical committee of Faculty of Dentistry, Mansoura University.

After one-week acclimatization period, 10 aged healthy male rats were used as PRP donors and the other 30 rats were classified into 3 groups, 10 rats each:

Group I: 60 mg/kg of saline was injected ip. on day zero, and other 40 mg/kg was injected on the second day.

Group II: 60 mg/kg of 5-FU was injected ip. on day zero, and other 40 mg/kg was injected on the second day ⁽²⁰⁾.

Group III: 60 mg/kg of 5-FU was injected ip. on day zero, and other 40 mg/kg was injected on the second day then after 24 hours, 1ml/rat/day of PRP was injected locally into the tongue mucosa for 3 weeks ⁽²¹⁾.

5-Fluorouracil

5-Fluorouracil (Utoral) (250 mg/5 ml) ampoules were purchased from EIMC United Pharmaceuticals Company, Egypt.

Preparation of plasma rich platelets:

Preparation of PRP was done in faculty of Pharmacy, Mansoura University. 10 healthy male rats were used as PRP donors. Through cardiac puncture, the whole blood was drawn, mixed with 3.2% sodium citrate at a blood/citrate ratio of 9/1, centrifuged at 400 ×g for 10 minutes, and the supernatant was separated and centrifuged again at 800 ×g for 10 minutes. The top 2/3 representing platelet-poor plasma (PPP) was removed. The remaining layer (1/3) was separated as PRP. PRP was allocated and frozen at -80°C for use. The average PRP was evaluated using a Sysmex XT-1600i system. The platelet count was 2410×10^3 platelets/ μ L. CaCl₂ 10% (0.8 mL of PRP + 0.2 mL of CaCl₂ 10%) was used to activate PRP immediately before its application ⁽²²⁾. Injection of PRP was done under local anesthesia with diethyl ether using 1ml insulin syringe with a needle size 27-gauge × 1/2 inch ⁽²¹⁾.

Scarification of animals was done by overdose of sodium thiopental after 1 week of the second

injection in group I and II and at end of third week of PRP injection in group III, sagittal tongue specimens from each animal in each group were fixed in 10% formal saline for 24 h, dehydrated in ascending series of ethyl alcohol and embedded in paraffin. 5 μ m histological sections were cut and subjected to hematoxylin and eosin staining according to the conventional method. Then the specimens were prepared for histological examination ⁽²³⁾.

Immunohistochemical processing

Slides were deparaffinized, rehydrated, rinsed in tap water, and embedded in 3% H₂O₂ for 10 min to block endogenous peroxidase. Then sections were treated with 2% trypsin for 10 min. Nonspecific protein binding was blocked by a blocking solution (PBS and 10% normal goat serum). Sections were incubated with primary antiCD3 antibody for 30 min. Then sections were washed 3 times each for 5 minutes in buffer and incubated for further 30 minutes with the secondary antibodies diluted 1:1000, followed by washing. Following further 30 minutes' incubation with Vectastain ABC kits (Avidin, Biotinylated horse radish peroxidase Complex) and washing for 10 minutes, the substrate, diaminobenzidine tetra hydrochloride (DAB) in distilled water was added for 5- 10 min. The slides were lightly counterstained by hematoxylin. The same method was applied to prepare negative control sections but the primary antibody was not added ⁽²⁴⁾.

As CD3 is primarily present in T-lymphocytes and increased greatly during inflammation, the number of CD3-positive cells /unit area was suspected to be present intensely in group II more than group I and III.

Morphometric analysis

Using a Leica Qwin 500 image analysis computer system (Leica Microsystems Ltd, Cambridge, UK) at the Pathology department, Faculty of Medicine, Mansoura University. Five specimens from five different rats of each group were examined (n=5)., For each specimen, five different captured non-

overlapping high-power fields (X 200) were taken. Five different readings from every captured photo were counted and the mean was calculated for each specimen. Measurements were counted for the mean area percentage of CD3 positive reaction by an independent observer blinded to the specimens' details to perform an unbiased assessment.

Statistical analysis

All the data collected from the experiment recorded and analyzed using IBM SPSS Statistics software for Windows, Version 20 (IBM Corp., Armonk, NY, USA). One-way analysis of variance (ANOVA) with Post Hoc tukey test applied to compare differences among the groups. In each test, the data was evident as the mean (M) value \pm standard deviation (SD) and differences considered significant at $P < 0.05$.

Slides were digitized using Olympus® digital camera installed on Olympus® microscope. The resulted images were analyzed on Intel® Core I3® based computer using Video Test Morphology® software (Russia) with a specific built-in routine for immune-stain quantification.

RESULTS

General observations

- Decreased body weight was observed in rats of group II which treated with 5-FU.
- No systemic complications related to PRP or 5-FU administration were observed.

Histological analysis

Hematoxylin and Eosin stain:

The filiform papilla of the tongue dorsal surface in group I had no remarkable changes with normal epithelial cells, normal thickness of keratin layer, group II showed loss of normal appearance of filiform papillae and loss of continuity of keratin layer, group III showed restoration of the papillae and normal keratin layer, Fig (1).

The fungiform papilla in group I showed with normal architecture of epithelial cells, normal taste buds, and normal connective tissue, group II showed ill-defined taste bud cells with areas of CT degeneration or discontinuity, group III showed more or less normal stratification of epithelium and more organized lamina propria than group II, Fig (2).

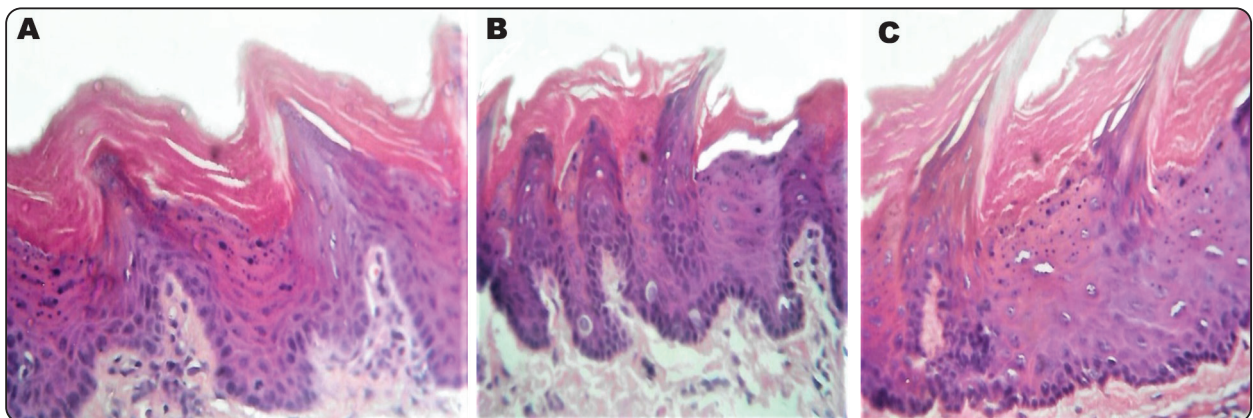


Fig. (1): photomicrograph showed filiform papillae, A showing group I, the dorsal surface of the tongue with normal filiform papilla, covered by keratinized stratified squamous epithelium with underlying connective tissue of the lamina propria, normal thickness of keratin layer and normal connective tissue, B showing group II with loss of some of filiform papillae tips, thinning of the papillae, loss of continuity of keratin layer and decrease in the thickness of epithelium. C showing group III with restoration of normal histology of epithelium, the papillae and connective tissue. normal keratin layer and increase in the thickness of epithelium. (H&E x 400).

Immunohistochemical analysis:

The immunohistochemical positive results were detected as brown deposits in the lamina propria, the reaction was nuclear.

In group I the lamina propria of the tongue showed negative immunoreactivity for CD3, while in group II intense positive immunohistochemical reaction for CD3 was seen in the lamina propria. In group III the immunoreactivity was mild for CD3,

table (1), Fig (3) and (4).

TABLE (1) showing high immunoreactivity of CD3 in group III compared to group I and II

	Group I	Group II	Group III
Area %	0.55±0.64	3.18±0.74 ^a	1.23±0.43 ^{ab}

*Data expressed as mean ± SD SD: standard deviation
P: Probability Test used: One-way ANOVA followed by post-hoc ukey a: significance vs. group I (P<0.05). b: significance vs. Group I and II (P<0.05).*

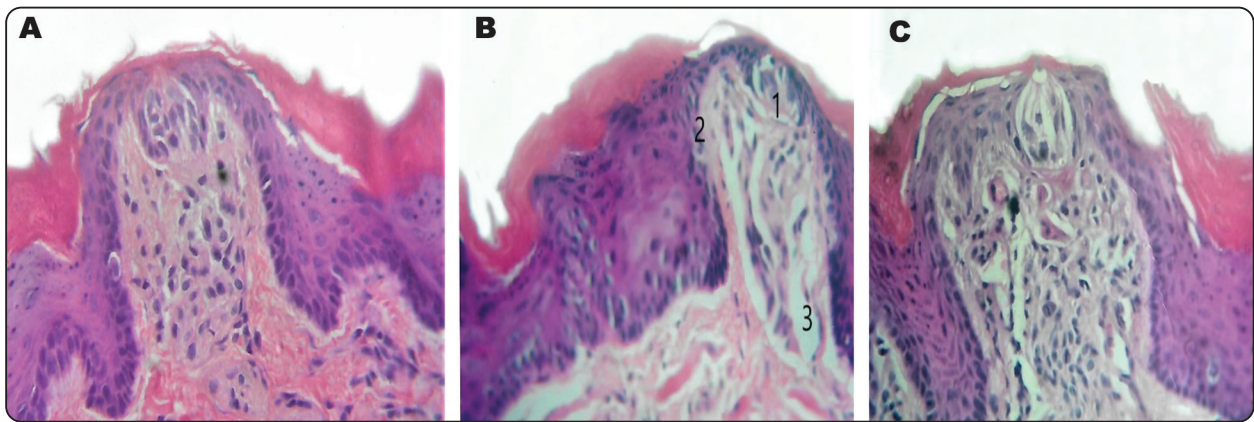


Fig. (2): photomicrograph showed fungiform papillae, A showing group I, fungiform papilla with broad surface and a single taste bud on its upper surface, it is covered by keratinized stratified squamous epithelium with wide well organized vascular connective tissue. normal architecture of epithelial cells, normal taste buds, normal connective tissue are shown, B showing group II with ill-defined taste bud cells (arrow), basal cells (arrow heads) and areas of CT degeneration or discontinuity (3) with changes seen in the shape of papillae, C showing group III with better histological picture than group II presented in the form of more or less normal stratification of epithelium and more organized lamina propria than group II (H&E x 400)

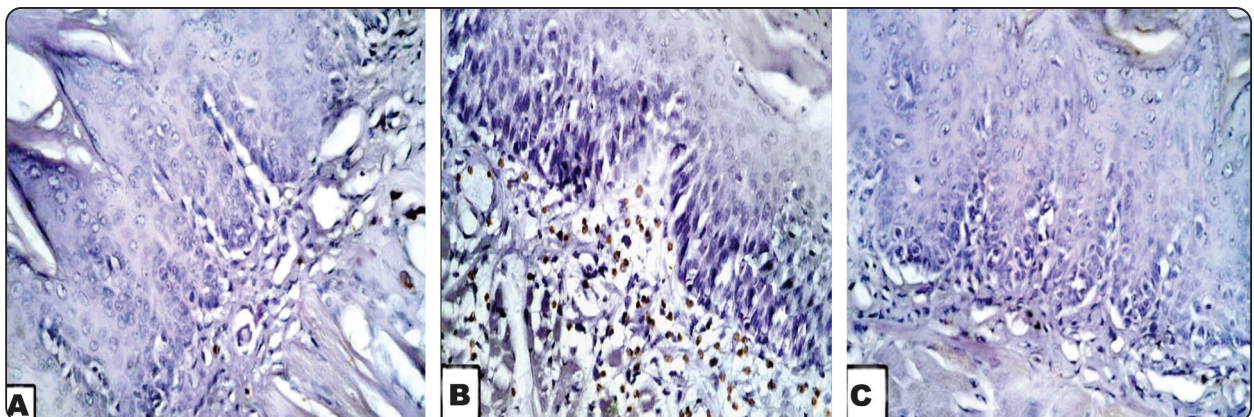


Fig. (3): photomicrograph showed immunohistochemical results for CD3, A showed negative immunoreactivity of group I, B showed intense positive nuclear immunoreactivity in the lamina propria with few positive cells in the basal cell layer of epithelium in group II, C showed mild immunoreactivity of group III (IHC staining, CD3 x400).

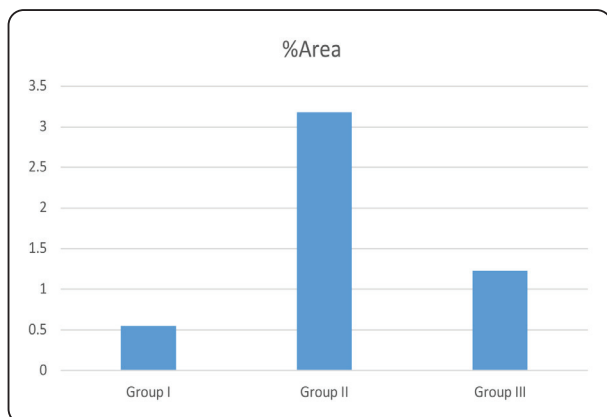


Fig. (4) Histogram. Showing the mean area % of CD3 positive reactivity in all experimental groups

DISCUSSION

5-FU is commonly used for treatment of variety of malignant tumors such as breast, colon, rectum, gastric, primary hepatic, pancreatic, uterine, ovarian and bladder carcinomas⁽²⁵⁾. its cytotoxic effect occur due to entrance of fluoro-nucleotides into RNA and DNA thus inhibition of the nucleotide synthetic enzyme thymidylate synthase occur which is an important enzyme in nucleotide metabolism⁽²⁶⁾.

Many regimes have been followed to prevent or even reduce oral mucositis occurred as a result of using chemotherapy, including oral care protocols, laser or cryotherapy, amifostine (a cytoprotectant)⁽²⁷⁾, chlorhexidine mouthwash,⁽²⁸⁾ colony stimulating factor⁽²⁹⁾, magic mouthwash which contains diphenhydramine, nystatin, lidocaine, and chlorhexidine. however, all these multiple choices may elevate the occurrence of the side effects and may not completely satisfy the patients⁽³⁰⁾.

In the current study, there was shortening of the lingual papillae with shallow epithelial rete pegs, loss of keratin continuity in many areas and destruction of connective tissue in group II and these findings were in agreements with Ali et al 2014 who reported the same findings⁽³¹⁾ and attributed the cause to the occurrence of reduction in epithelial regeneration

due to the 5-FU cytotoxicity. Generally, uses of chemotherapy prevent DNA synthesis, lead to DNA damage and release of reactive oxygen species that consequently affect the progenitor cells metabolism; decrease mitosis and increase apoptosis⁽⁸⁾.

Aisha et al 2017 reported decrease in the epithelium thickness, keratin layer separation and flattened rete ridges, Some epithelial cells showed formation of vacuoles around nuclei, while other cells presented many nuclear changes as karyohexiss, pyknosis or karyolysis and hemorrhage in the rat's group injected with 5-FU when they searched for the possible healing capacities of glucosamine and PRP on experimentally induced oral mucositis in adult male rats.⁽³²⁾, which generally confirm our results.

Some investigators stated that 5-Flurouracil lead to mucosal inflammation that was proved through the elevated expression of many cytokines as tumor necrosis factor- α (TNF- α) and interleukin-1(IL-1), which in turn start the inflammatory response. Furthermore, this inflammation weakens the mucosal membrane barriers which enhance its bacterial penetration, these bacteria will attract the mononuclear cells leading to inflammation and finally mucosal ulceration⁽³³⁾.

It is well known that PRP administration can accelerate tissue healing due to its contents of cytokines and growth factors which in turn increases the stem cell proliferation and differentiation^(34,35). Furthermore, PRP controls other biological processes such as angiogenesis, inflammation, cell proliferation, cell migration, as well as extracellular matrix synthesis and remodeling processes⁽³⁶⁾. It is inexpensive, easily accessible, has antimicrobial action with no risk of rejection or immune reaction⁽³⁷⁾.

In group III, the combination between 5-FU and PRP improved the histological changes in the dorsal surface of the tongue induced by 5- FU alone in group II where regeneration of the epithelium with

normal stratification of tongue papillae, normal thickness of keratin layer and normal appearance of connective tissue was clearly seen in group III and these findings were in accordance with many other researchers, who proved that PRP accelerate the healing process in different forms of lesions as it contains many important bioactive proteins that accelerate the epithelial, mesenchymal, endothelial and epidermal regeneration, reduces the inflammatory response and hastens wound healing in normal tissues besides the healing of compromised wounds^(38,39).

Neveen Salem et al 2018⁽⁴⁰⁾ searched the renoprotective effect of PRP on the nephrotoxicity occurred in rats due to injection of cisplatin and reported that PRP elevates the level of the anti-inflammatory mediators (IL-4, IL-10, and IL-13) that are known to have the principle role in preventing inflammation and reducing the mediated catabolic effect of IL-1 β ⁽⁴¹⁾ and this also explain the histological improvement in group III compared to group II.

The CD3 is a protein complex that functions as the co-receptor of T-cell receptor (TCR), required for T-cell activation and then transmit the activation signal to the cytoplasm. Many human studies have proved that its expression is limited to T-lymphoid cells, with one exception of Purkinje cells in the cerebellum⁽⁴²⁾. Furthermore, it is an excellent marker for the diagnosis of lymphomas in routine fixed material as it is retained following neoplastic transformation⁽⁴³⁾.

T-cells are primarily present in stratum basale and stratum spinosum of the epithelium, in the connective tissue, they are found close to basal cell layer of epithelium. The number of CD3-positive cells /unit area was greatly high in group II compared to group I and III indicating higher degree of inflammation in group II and increased recruitment of T-lymphocytes, and this come in accordance with Marwa and Walaa, 2019 who used irinotecan as a chemotherapeutic agent and study its

effect on the mucosal tongue of juvenile male albino rat at adulthood and registered the inflammation in the group treated with irinotecan; chemotherapy induce tongue mucosal toxicity⁽⁴⁴⁾. The generated inflammatory cytokines produces significant tissue damage either directly or indirectly by increasing vascular permeability, this indirectly increase the cytotoxic drug uptake into the oral mucosa⁽⁴⁵⁾.

Aisha et al 2017 also stated the same observations in their study which are closely similar to our findings in group II regarding the higher percentage of CD3 positive cells in the form of areas of degeneration and accumulation of sub epithelial mononuclear infiltration in lamina propria⁽³²⁾.

CONCLUSION

5-FU administration has an obvious negative effect on tongue mucosa, However, PRP administration greatly promotes the inflammation process, exhibits more rapid epithelial differentiation thus increasing the integrity of tongue's epithelium and lamina propria. Although our study was experimental, its results recommends further clinical application of PRP.

Competing interests: Authors declared that there is no competing of interests.

Authors' Contributions: "Sally H. Abo Baker completed the practical part of the research and Amira A. R. Moawad collected the data and was a major contributor in writing the manuscript. All authors read and approved the final manuscript."

REFERENCES

1. Vermorken JB, Remenar E, van Herpen C, Gorlia T, Mesia R, Degardin M, et al. Cisplatin, Fluorouracil, and Docetaxel in Unresectable Head and Neck Cancer. *N Engl J Med.* 2007;357(17):1695–704.
2. Argilés G, Tabernero J, Labianca R, Hochhauser D, Salazar R, Iveson T, et al. Localised colon cancer: ESMO Clinical Practice Guidelines for diagnosis, treatment and follow-up†. *Ann Oncol.* 2020;31(10):1291–305.

3. Sakai M, Sohda M, Saito H, Kuriyama K, Yoshida T, Kumakura Y, et al. Docetaxel, cisplatin, and 5-fluorouracil combination chemoradiotherapy for patients with cervical esophageal cancer: a single-center retrospective study. *Cancer Chemother Pharmacol*. 2019;83(6):1121–6.
4. Peters GJ, Van Der Wilt CL, Van Groeningen CJ, Smid K, Meijer S, Pinedo HM. Thymidylate synthase inhibition after administration of fluorouracil with or without leucovorin in colon cancer patients: Implications for treatment with fluorouracil. *J Clin Oncol*. 1994;12(10):2035–42.
5. Silverstein RA, De Valdivia EG, Visa N. The incorporation of 5-fluorouracil into RNA affects the ribonucleolytic activity of the exosome subunit Rrp6. *Mol Cancer Res*. 2011; 9(3):332–40.
6. Sonis ST. Mucositis: The impact, biology and therapeutic opportunities of oral mucositis. *Oral Oncol*. 2009;45(12):1015–20.
7. Campos Midc, Campos Cn, Aarestrup Fm, Aarestrup Bjv. Oral mucositis in cancer treatment: Natural history, prevention and treatment. *Mol Clin Oncol*. 2014;2(3):337–40.
8. ST S. Pathobiology of mucositis. *Semin Oncol Nurs*. 2004; 20:11–5.
9. Abayomi TA, Ofusori DA, Ayoka OA, Odukoya SA, Omotoso EO, Amegor FO, et al. A Comparative Histological Study of the Tongue of Rat (*Rattus Norvegicus*), Bat (*Eidolon Helvum*) and Pangolin (*Manis Tricuspis*). *Int J Morphol*. 2009;27(4).
10. Al-Refai A, Omar O KA. Effect of chamomile extract on the tongue of chemotherapy treated Albino rats (histopathological and immunohistochemical study). *J Clin Cell Immunol*. 2014;05(251).
11. Lyras DN, Kazakos K, Verettas D, Polychronidis A, Tryfonidis M, Botaitis S, et al. The influence of platelet-rich plasma on angiogenesis during the early phase of tendon healing. *Foot Ankle Int*. 2009;30(11):1101–6.
12. Yol S, Tekin A, Yilmaz H, Küçükkartallar T, Esen H, Çağlayan O, et al. Effects of Platelet Rich Plasma on Colonic Anastomosis. *J Surg Res*. 2008;146(2):190–4.
13. Brass L. Understanding and evaluating platelet function. *Hematology Am Soc Hematol Educ Program*. 2010; 2010:387–96.
14. Nurden AT. Platelets, inflammation and tissue regeneration. *Thromb Haemost*. 2011;105(SUPPL. 1):13–33.
15. E. Conde-Montero, M.E. Fernandez-Santos RS-F. Platelet-rich plasma: applications in dermatology,. *Actas Dermosifiliogr*. 2015;106:104–111.
16. Andrade SS, Sumikawa JT, Castro ED, Batista FP, Paredes-Gamero E, Oliveira LC, et al. Interface between breast cancer cells and the tumor microenvironment using platelet-rich plasma to promote tumor angiogenesis - Influence of platelets and fibrin bundles on the behavior of breast tumor cells. *Oncotarget*. 2017;8(10):16851–74.
17. Peterson JE, Zurakowski D, Italiano JE, Michel L V., Fox L, Klement GL, et al. Normal ranges of angiogenesis regulatory proteins in human platelets. *Am J Hematol*. 2010;85(7):487–93.
18. Quarteiro ML, Tognini JRF, De Oliveira ELF, Silveira I. The effect of platelet-rich plasma on the repair of muscle injuries in rats. *Rev Bras Ortop*. 2015;50(5):586–95.
19. Girgin M, Binnetoglu K, Duman K, Kanat BH, Cetinkaya Z, Ayten R, et al. Effects of platelet rich plasma on fascial healing in rats with fecal peritonitis. *Acta Cir Bras*. 2016;31(5):314–9.
20. Leitão RFC, Ribeiro RA, Bellaguarda EAL, MacEdo FDB, Silva LR, Oriá RB, et al. Role of nitric oxide on pathogenesis of 5-fluorouracil induced experimental oral mucositis in hamster. *Cancer Chemother Pharmacol*. 2007;59(5):603–12.
21. Elsaadany B, El Kholy S, El Roubly D, Rashed L, Shouman T. Effect of Transplantation of Bone Marrow Derived Mesenchymal Stem Cells and Platelets Rich Plasma on Experimental Model of Radiation Induced Oral Mucosal Injury in Albino Rats. *Int J Dent*. 2017;2017.
22. Pazzini JM, De Nardi AB, Huppes RR, Gering AP, Ferreira MGPA, Silveira CPB, et al. Method to obtain platelet-rich plasma from rabbits (*Oryctolagus cuniculus*). *Pesqui Vet Bras*. 2016;36(1):39–44.
23. Bashkar S. *Orban's Oral Histology and Embryology: 11th Ed.* Baltimore, Boston, Chicago, London, Philadelphia, Sydney, Toronto: Mosby st. Louis., 1990. 339 – 41, 349–50, 365, 470-73. p.
24. Ct S, Ribeiro-da-Silva A, Cuello AC. Current protocols for light microscopy immunocytochemistry. *Immunohistochem II*. 1993;(4):147–68.
25. Mead GM. Management of oral mucositis associated with cancer chemotherapy. *Lancet*. 2002;359(9309):815–6.
26. Longley DB, Harkin DP, Johnston PG. 5-Fluorouracil:

- Mechanisms of action and clinical strategies. *Nat Rev Cancer*. 2003;3(5):330–8.
27. Herrstedt J. Prevention and management of mucositis in patients with cancer. *Int J Antimicrob Agents*. 2000;16:161–163.
 28. Ao M, Xiao X, Li Q. Efficacy and safety of compound Kushen injection combined with chemotherapy on postoperative Patients with breast cancer: A meta-analysis of randomized controlled trials. *Medicine (Baltimore)*. 2019;98(3):e14024.
 29. Altundag K. Is there any association between use of granulocyte colony-stimulating factor and chemotherapy-induced oral mucositis? *Eur J Cancer Care (Engl)*. 2018;27(6).
 30. Uberoi AS, Brown TJ, Gupta A. Magic Mouthwash for Oral Mucositis: A Teachable Moment. *JAMA Intern Med*. 2019;179(1):104–5.
 31. Ali Sultan Al-Refai OAO and AKK. Effect of Chamomile Extract on the Tongue of Chemotherapy Treated Albino Rats (Histopathological and Immunohistochemical Study). *J Cytol Histol*. 2014;5(4).
 32. Mansy AE, El-Azab NE-E, El-Mahalaway AM. Histological and immunohistochemical study of the potential healing effects of glucosamine and platelets rich plasma on experimentally induced oral mucositis in adult male rats. *J Histol Histopathol*. 2017;4(1):12.
 33. Al-Refai A. Chemoprotective effect of ascorbic acid on cyclophosphamide induced oral toxicity. *Zanco J Med Sci*. 2017;21(1):1540–51.
 34. Spartalis E, Tsilimigras DI, Charalampoudis P, Karachaliou GS, Moris D, Athanasiou A, et al. The “Yin and Yang” of Platelet-rich Plasma in Breast Reconstruction after Mastectomy or Lumpectomy for Breast Cancer. *Anticancer Res*. 2017;37(12):6557–62.
 35. Syllaios A, Tsimpoukelis A, Vagios I, Kyros E, Davakis S. Breast reconstruction with autologous fat combined with platelet rich plasma: Fighting between medical novelty and cancer biology. *J BUON*. 2019;24(4):1516–20.
 36. I.A, M.S, N.M. Basic Science: Molecular and Biological Aspects of Platelet-Rich Plasma Therapies. *Oper Tech Orthop [Internet]*. 2012;22(1):3–9. Available from: <http://0-ovidsp.ovid.com.wam.city.ac.uk/ovidweb.cgi?T=JS&PAGE=reference&D=emed10&NEWS=N&AN=2012141626>
 37. Martín-Solé O, Rodó J, García-Aparicio L, Blanch J, Cusí V, Albert A. Effects of platelet-rich plasma (PRP) on a model of renal ischemia-reperfusion in rats. *PLoS One*. 2016;11(8).
 38. Mohammadi R, Mehrdash M, Mehrdash M, Hassani N, Hassanpour A. Effect of Platelet Rich Plasma Combined with Chitosan Biodegradable Film on Full-Thickness Wound Healing in Rat Model. *Bull Emerg trauma [Internet]*. 2016;4(1):29–37. Available from: <http://www.ncbi.nlm.nih.gov/pubmed/27162924> <http://www.pubmedcentral.nih.gov/articlerender.fcgi?artid=PMC4779467>
 39. Sima T, Daryoush HA, Saeedeh K, Elnaz K, Alireza E. Cleft palate reconstruction by platelet-rich-plasma and stem cell injection: Histological evidences. *J Cell Anim Biol*. 2014;8(7):114–23.
 40. Salem N, Helmi N, Assaf N. Renoprotective Effect of Platelet-Rich Plasma on Cisplatin-Induced Nephrotoxicity in Rats. *Oxid Med Cell Longev*. 2018;2018.
 41. Moussa M, Lajeunesse D, Hilal G, El Atat O, Haykal G, Serhal R, et al. Platelet rich plasma (PRP) induces chondroprotection via increasing autophagy, anti-inflammatory markers, and decreasing apoptosis in human osteoarthritic cartilage. *Exp Cell Res*. 2017;352(1):146–56.
 42. Mason DY, Cordell J, Brown M, Pallesen G, Ralfkiaer E, Rothbard J, et al. Detection of T cells in paraffin wax embedded tissue using antibodies against a peptide sequence from the CD3 antigen. *J Clin Pathol*. 1989;42(11):1194–200.
 43. Chott A, Augustin I, WRBA F, Hanak H, Öhlinger W, Radaszkiewicz T. Peripheral T-cell lymphomas: A clinicopathologic study of 75 cases. *Hum Pathol*. 1990;21(11):1117–25.
 44. Ibrahim MAAH, Elwan WM. Effect of irinotecan on the tongue mucosa of juvenile male albino rat at adulthood. *Int J Exp Pathol*. 2019;100(4):244–52.
 45. Niscola P, Romani C, Cupelli L et al. Mucositis in patients with hematologic malignancies: an overview. *Haematologica*. 2007;92(2):222–231.