



ROLE OF MAGNETIC RESONANCE IMAGING IN EVALUATING TYPICAL AND ATYPICAL MENINGIOMAS .

Mohamed Khaled Shawky Amin Fawzi , Mohamed Ibrahim Teama MD, Hazim Ibrahim TantawyMD, and Dina Abdel Aziz EL Samak
Radio diagnosis Department, Faculty of Medicine, Zagazig University. Egypt

Corresponding author

Dina Abdel Aziz EL Samak
volcano_eg8@hotmail.com.

ABSTRACT

Background: Meningioma is the most common primary non-glioma intracranial neoplasm . It occurs in adults between the ages of 40–70 years of age and tend to occur more often in women, the reported average age for females is 42 and that for males is 52 . Meningiomas are benign but locally aggressive tumor, they are found in the following anatomic sites in descending order of frequency: parasagittal region, falx, cerebellar convexity, olfactory groove, tuberculum sellae, sphenoid ridge, petrous face (CPA), tertorium, lateral ventricle, clivus as well as other sites .

Objective: The aim of this study is to evaluate the role of MRI in evaluating typical and atypical meningiomas and predicting its pathological behavior.

Methods: This study was carried out at Radio diagnosis Department, Zagazig University Hospitals, The present study was carried on 24 patients of typical and atypical meningiomas.

Results : We studied 24 cases, 15 of them were typical and only 9 cases were atypical /malignant. Using routine MRI sequences, the meningiomas were diagnosed and DW images were performed using factor of b-0 and b-1000. Apparent diffusion coefficient (ADC) values were measured in the lesion and in the normal white matter. Atypical and malignant types tend to have atypical features by routine MRI such as: heterogeneous signal intensity, heterogeneous pattern of enhancement, irregular tumor margins, marked amount of peri-focal edema, bone or parenchymal invasion. Three or more of above mentioned atypical features could not be seen in the typical meningiomas being unique for atypical and malignant group. Diffusion weighted imaging which is a part of normal brain imaging protocol has a great role in differentiating typical from atypical meningiomas. In this study, typical meningiomas tended to have a larger ADC values & NADC ratios than atypical and malignant ones. Only one case of pathologically proven rhabdoid malignant meningioma (Grade III) has high ADC value & NADC ratio (features of typical type).

Conclusion: Our results indicate that The distinction between benign and atypical / malignant meningiomas is neither easily nor reliably accomplished to date when assessing the imaging features of meningiomas on routine MR images. DWI is helpful in distinguishing benign from malignant and atypical meningiomas. Mean ADC values of atypical/malignant meningiomas were significantly lower compared with benign meningiomas. Mean NADC ratios in the atypical/malignant group were also significantly lower than the benign group.

Keywords: philips; MRI;1.5 T;brain; Meningioma.

INTRODUCTION

Meningioma is the most common primary non-glioma intracranial neoplasm. It occurs in adults between the ages of 40–70 years of age and tends to occur more often in women,

the reported average age for females is 42 years and that for males is 52 years. Meningiomas are benign but locally aggressive tumor, they are found in the following anatomic sites in descending order of frequency: parasagittal

region, falx, cerebellar convexity, olfactory groove, tuberculum sellae, sphenoid ridge, petrous face (CPA), tertorium, lateral ventricle, clivus as well as other sites (1).

The classification and grading of meningiomas is classified into Three degrees, Grade I benign (90%), grade II atypical (5-7 %) and Grade III malignant (1-3%). While it has long been recognized that the presence of brain invasion in a WHO grade I meningioma confers recurrence and mortality rates similar to those of a WHO grade II meningioma in general, prior WHO classifications had considered invasion a staging feature rather than a grading feature and opted to discuss brain invasion as a separate heading. In the 2016 classification, brain invasion joins a mitotic count of 4 or more as a histological criterion that can alone suffice for diagnosing an atypical meningioma, WHO grade II .(2).

As in the past, atypical meningioma can also be diagnosed on the basis of the additive criteria of 3 of the other 5 histological features: spontaneous necrosis, sheeting (loss of whorling or fascicular architecture), prominent nucleoli, high cellularity and small cells (tumor clusters with high nuclear: cytoplasmic ratio) (2).

Atypical and anaplastic (malignant) meningiomas are biologically more aggressive tumors that account for 10–15% of all meningiomas and are more prone to recurrence and rapid growth (1).

These neoplasms are usually well encapsulated with broad dural attachments. Adjacent bony destruction or hyperostosis is common as intramural psammomatous calcification. Some meningiomas are quite invasive and may extend into the dural sinuses and skull base (1).

Imaging plays a role in intracranial lesions management. Magnetic resonance imaging in particular has emerged as imaging modality most frequently used to evaluate intracranial lesions. In general, the role of MR imaging in the work up of intracranial mass lesions can be broadly divided into diagnosis,

classification, treatment planning and post-treatment surveillance (3).

MR imaging can demonstrate tumor vascularity, arterial enhancement, venous sinus invasion and relationship between the tumor and surrounding structures. This modality is advantageous in depicting the juxta-sellar region and posterior fossa and in demonstrating the rare presence of disseminated disease via CSF (4).

Meningiomas range from iso-intense to hypo-intense on T1WIs and from iso-intense to hyper-intense in T2WIs after Gadolinium injection , they shows homogenous enhancement .Up to 72 % shows dural tail but it is not specific for meningiomas (5).

Atypical features include heterogeneous enhancement, large amount of peri-focal edema, and absence of calcifications, necrosis and irregular margins. Found that atypical and malignant meningiomas or those that invade brain, may show resonance in location of NAA (N-acetylaspartate) and differentiation from astrocytomas may then prove difficult , found that on MR Spectroscopy , alanine was not found to be increased in all meningiomas .so MRS cannot differentiate typical intracranial meningiomas from atypical meningiomas (1).

Atypical and malignant meningiomas has marked increased signal on diffusion WIs and extremely low apparent diffusion coefficient on ADC maps. Mean ADC values for peri-tumoral edema do not differ between benign and malignant meningiomas (6). MRI perfusion can provide critical information on vascularity of meningiomas that not available with conventional MRI (7).

MATERIALS & METHODS

Patients

This prospective study was conducted in Radio-diagnosis department-Zagazig University in the time frame of December 2016 to August 2017, and included 24 patients (9 males & 15 females; average age is 50 years old) referred from neurosurgery department. All of them were suspected to have meningiomas according to CT findings and institutional review board

approval was obtained. Two patients had previous history of surgical resection of benign meningiomas.

The patients were subjected to the following:

- 1- **Clinical history.**
- 2- **Neurologic examination.**
- 3- **Imaging modalities:**
 - A) **Conventional magnetic resonance imaging (MRI):**

All MRI studies were done using Philips machine (01.5 Tesla). All patients were asked to get rid of any metallic subjects. The patients were informed about the duration of the examination, the position of the patient and the importance of being motionless.

MRI study was done with the patients in the supine position using the standard head coil. The examination was done before contrast administration, a scout sagittal T1-weighted view was obtained to verify the precise position of the patient and to act as a localizer for subsequent slices, then multiple pulse sequences were used to obtain axial images followed by coronal and/or sagittal images based on the location of the pathology encountered. In midline lesions sagittal planes were used while in laterally located lesions coronal images were more helpful.

The contrast media used was Magnevist (Gadolinium Diethylene Triamine Penta acetic acid) ("Gd-DTPA"), it was administrated intravenously in a dose of 0.1 mmol/kg body weight. T1-WIs was obtained immediately after the end of contrast injection.

All cases were examined using the following protocol:

Sagittal T1-WI as a localizer:

*TE = 10–12 m/s

*TR = 400–600 m/s

Axial and coronal spin-echo sequences, short TR/TE (T1-weighted images):

*TE = 10–12 m/s

*TR = 400–600 m/s

Axial fast spin-echo, long TR/TE (T2-weighted images):

*TE = 70–90 m/s

*TR = 2800–3500 m/s

Post-contrast axial, sagittal and coronal spin-echo sequences, short TR/TE (T1-weighted images):

*TE = 10–12 m/s

*TR = 400–600 m/s

FOV = 24–18 cm in axial images and 30–22 cm in coronal images.

Matrix (frequency × phase) 192 × 160.

Slice thickness = 6 mm with 2 mm interval. (In all sequences.)

(B) Advanced magnetic resonance imaging:

Diffusion-weighted MR imaging (DWI):

The imaging sequence for DWI was a multi-section single shot spin-echo EPI sequence (TR/TE/NEX: 4200/140 ms/D) with diffusion sensitivities of b values = 0, 500 and 1000 s/mm². The diffusion gradients were applied sequentially in three orthogonal directions (X, Y and Z directions). Sections of 5 mm thickness, interslice gap of 1 mm, FOV 240 mm and a matrix of 128 × 256 were used for all images. The total acquisition time was 80 s.

Three types were obtained; orthogonal images, trace images and ADC maps. The ADC maps were calculated automatically by MRI software and included in the sequence. Measurements of ADC were made in different regions of interest (ROI) of the lesions. The ADC values were expressed in 10–3 mm²/s.

STATISTICAL ANALYSIS

Our results indicate that The distinction between benign and atypical / malignant meningiomas is neither easily nor reliably accomplished to date when assessing the imaging features of meningiomas on routine MR images. DWI is helpful in distinguishing benign from malignant and atypical meningiomas. Mean ADC values of atypical/malignant meningiomas were significantly lower compared with benign meningiomas. Mean NADC ratios in the atypical/malignant group were also significantly lower than the benign group.

RESULTS**Table 2** Demographic data of the studied group:

Variable	Studied group (n=24)	
Age:		
Mean \pm SD	43.5 \pm 13.2	
Median (range)	44.5 (30-70)	
Age: (years)	No	%
30-40	11	45.8
41-50	6	25
51-60	4	16.7
61-70	3	12.5
Sex:	No	%
Female	15	62.5
Male	9	37.5

This table shows that patient's age ranged between 30-70 years with mean of 43.5 years. Almost half of them (45.8%) were in 30-40 year's group followed by 25% in 41-50 year's group.

It was also noticed that 62.5% were females compared to 37.5% males.

Table 4 Anatomical classification of meningioma among the studied group.

Primary site of diagnosis:	(n=24)	
	No	%
Para-sagittal:	6	25
Parietal:	2	8.3
Temporal:	6	25
Falcine:	3	12.5
Optic nerve:	1	4.2
Spinal cord:	2	8.3
Sellar & para-sellar:	2	8.3
Petro-clival:	1	4.2
Sphenoid:	1	4.2

This table shows that para-sagittal and temporal sites were found to be the commonest anatomical sites of meningioma (25%, 25%) followed by falcine which represented 12.5% of the studied group.

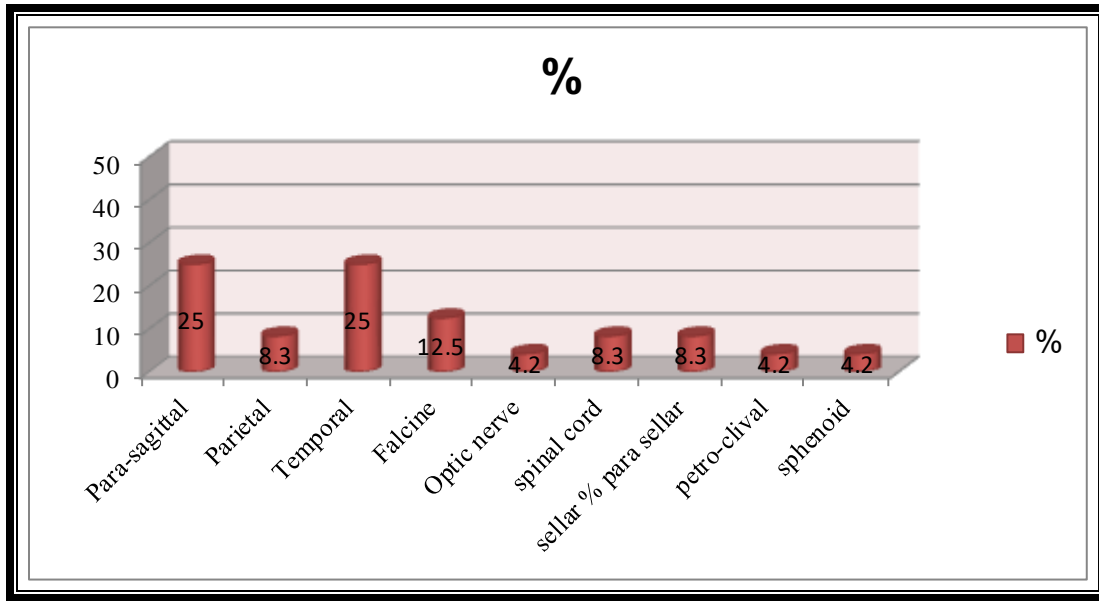


Figure (47): Bar chart showing anatomical classification of meningioma among studied group.

Table 5 Pathological classification of meningioma among the studied group.

Pathological classification	(n=24)	
	No	%
Meningioma:	15	62.5
Typical:	9	37.5
Atypical/Malignant:		

This table shows that out of 24 studied patients, 15 patients had typical meningioma with percentage of 62.5% and only 9 patients (37.5%) had atypical meningioma/malignant.

Table 6 Histopathological entities of meningioma of the studied group.

Histopathological entities	Studied group (n=24)	
	No	%
Typical (grade I): (n=15)		
Meningiothelial	8	53.3
Fibroblastic	2	13.3
Transitional	3	20
Microcystic	1	6.7
Secretory	1	6.7
Atypical/malignant Grade (II/III): (n=9)		
Clear cell	2	22.2
Papillary	3	33.3
Rhabdoid	4	44.5

This table shows that among the histopathological entities, meningiothelial type was the commonest type in typical meningiomas represented by 53.3% followed by transitional type (20%).

As regarding atypical/malignant meningiomas, rhabdoid entity was the commonest form (44.5%) followed by papillary type (33.3%).

Table 7 Conventional MRI findings in different types of meningiomas among the studied groups.

MRI findings	Detected lesions	
	Typical meningioma (n=15)	Atypical meningioma (n=9)
	No.	No.
Peri-focal edema:	8	8
Irregular tumor margin:	2	5
Bone destruction:	0	3

This table shows that irregular tumor margin and bone destruction were found to be more common among patients with atypical meningioma compared to typical one. However, peri-focal edema was the same in both groups.

Table 11 Validity of functional MRI In diagnosis of meningioma in comparison to histopathology as Gold standard.

Functional MRI	Histopathological examination		Total
	Typical	Atypical/Malignant	
Typical	15	1	16
Atypical/Malignant	0	8	8
Total	15	9	24
Sensitivity: 100%		Specificity: 88.9%	
Positive predictive value: 93.7%		Negative predictive value: 100%	
Accuracy: 95.8%			

This table shows that functional MRI is able to correctly identify 15 out of 15 patients with typical meningioma (when the comparison is made with the gold-standard test; i.e., histopathological examination). It can also identify 8 out of 9 patients with atypical/Malignant meningiomas as compared to the gold-standard test. Only one case of rhabdoid (Grade III) has high ADC & high NADC ratio.

Functional MRI has sensitivity of 100%, specificity of 88.9%, PPV of 93.7% and NPV of 100%.

Table 12 Validity of conventional MRI In diagnosis of meningioma in comparison to histopathology as Gold standard.

Conventional MRI	Histopathological examination		Total
	Typical	Atypical/Malignant	
Typical	10	5	15
Atypical/malignant	5	4	9
Total	15	9	24
Sensitivity: 66.7%		Specificity: 44.4%	
Positive predictive value: 66.7%		Negative predictive value: 44.4%	
Accuracy: 58.3%			

This table shows that conventional MRI is able to correctly identify 10 out of 15 patients with typical meningioma (when the comparison is made with the gold-standard test; i.e., histopathological examination). It can also identify 4 out of 9 patients with

atypical/Malignant meningioma as compared to the gold-standard test.

Conventional MRI has sensitivity of 66.7%, specificity of 44.4%, PPV of 66.7% and NPV of 44.4%.

Table 13 Validity of functional and conventional MRI among the studied groups.

Modality	Sensitivity (%)	Specificity (%)	Positive Predictive Value (%)	Negative Predictive Value (%)	Accuracy
DWI & ADC	100%	88.9%	93.7%	100%	95.8%
Conventional MRI	66.7%	44.4%	66.7%	44.4%	58.3%

Table 14 Performance of mean ADC level as a predictor of atypical/malignant meningioma among the studied groups.

Cutoff Point	UC	A ens.	S pec.	S pec.	P PV	P PV	N PV	accu racy	P value
≤ 0.55	.918	0	8	100%	100%	1	1.8%	91.7%	<0.001

This table shows that cutoff value of ADC of less than or equal to 0.55 can be used as a predictor for occurrence of atypical/malignant meningioma with sensitivity of 88.9%, specificity of 100%, PPV of 100% and NPV of 91.7%.

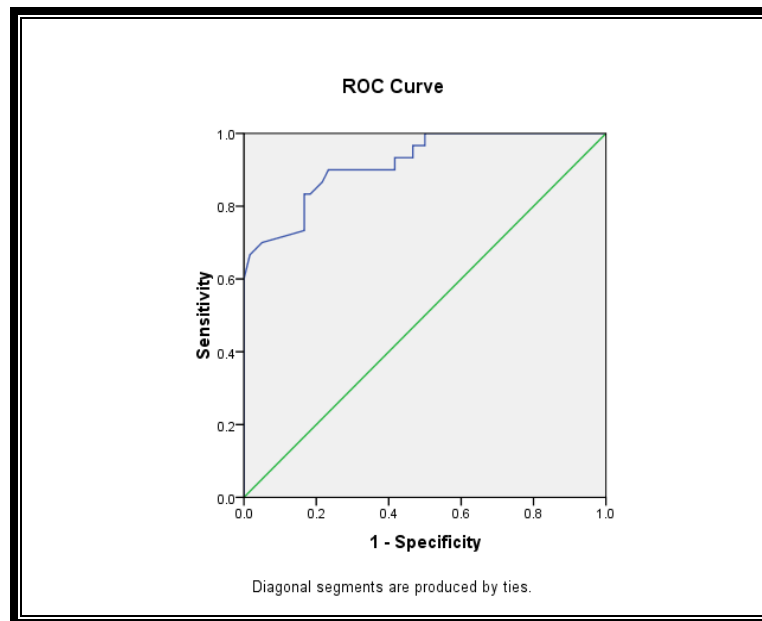


Figure 52 Receiver Operator Curve of ADC level as an indicator for atypical/malignant meningioma.

DISCUSSION

Meningiomas are common benign tumors which constitute about 20% of all intracranial tumors. They are more common in women, mostly benign, and usually have distinct appearance on histopathology and imaging, although there are variants which present with unusual radiological and pathological features (68).

There is a growing interest in the applications of diffusion-weighted-imaging (DWI) in oncologic area for last ten years. DWI plays an important role in tumor detection and characterization. It does not require contrast medium, and it provides qualitative and quantitative information that can be helpful for tumor assessment (69).

Apparent-diffusion-coefficient (ADC) value is quantitative parameter of DWI which reflects diffusion movements of water molecules in various tissues. Most of the studies suggested that atypical meningiomas had lower ADC values than typical ones, so the calculation of the ADC value & NADC ratio are the best predictor of the histologic subtypes of meningiomas (1).

Our study included 24 patients, their ages ranged between 30-70 years with mean of 43.5 years. Almost half of them (45.8%) were in 30-40 year's group followed by 25% in 41-50 year's group. It was also noticed that 62.5% were females compared to 37.5% males.

In agreement with Neenu Philip et al., 2017 (68) who stated that meningiomas are more common in women. Also Tantawy et al., 2010 (1) stated that Meningiomas predominantly occur in adults between the ages of 40–70 years of age and tend to occur more often in women, the reported average age for females is 42 and that for males is 52.

In this study, para-sagittal and temporal sites were found to be the commonest anatomical sites of meningioma (25%, 25%) followed by falcine which represented 12.5% of the studied group.

Neenu Philip et al, 2017 (68) stated that the most common sites of occurrence are the cerebral convexities, parasagittal location and

sphenoid ridge, accounting for 20–34%, 18–22% and 17–25%, respectively. Cerebello-pontine angle is another frequent site of involvement with meningiomas accounting for approximately 10–15% of all cerebello-pontine angle neoplasms.

Most meningiomas are benign and classified as Grade-I according to World Health Organization (WHO) standards. Benign meningiomas are subdivided into four basic subtypes: fibroblastic, transitional, meningothelial and angioblastic. Atypical and malignant meningiomas display less favorable clinical outcomes and are classified as Grades-II and -III. Atypical/malignant meningiomas are biologically more aggressive tumors that account for 10–15% of all meningiomas and are more prone to recurrence and rapid growth, they are subdivided into clear, papillary and Rhabdoid type (1).

In this study, 15 patients had typical meningioma with percentage of 62.5% and only 9 patients (37.5%) had atypical meningioma. In the histopathological entities, meningiothelial type was the commonest type in typical meningiomas represented by 53.3% followed by transitional type (20%). As regarding atypical/malignant meningiomas, rhabdoid entity was the commonest form (44.5%) followed by papillary type (33.3%).

Neenu Philip et al, 2017 (68) & Tantawy et al, 2010 (1) stated that the meningiothelial, fibroblastic and transitional types are the most common in typical meningiomas; however the rhabdoid & papillary types are the commonest in atypical and malignant meningiomas.

In our study, we found that peri-focal edema is more likely seen with high grade tumors as it was seen in 8 out of 9 cases of atypical/malignant meningiomas but only in 8 out of 15 cases of typical meningiomas.

In agreement with Drevelegas et al, 2011 (70) who stated that meningiomas that are more biologically aggressive, tend to display greater amount of edema regardless of location.

In this study, heterogeneous signal intensity seen on T1WI, T2WI or both are

statistically more with atypical meningiomas than in typical types. It is seen in 6 out of 9 cases of atypical meningiomas; however it is only seen in 2 out of 15 cases of typical meningiomas.

In disagreement with Modha A and Gutin PH, 2005 (71) who found that neuroimaging features such as heterogeneous appearance, marked peri-focal edema, heterogeneous enhancement, irregular cerebral surface and bone destruction are not unique or reliable for diagnosing atypical and malignant meningiomas.

In agreement with Demir et al, 2006 (5) and Drevelegas et al, 2011 (70) who stated that atypical features by conventional MRI include heterogeneous signal intensity, heterogeneous enhancement pattern, large amount of peritumoral edema, absence of calcifications, necrosis, irregular margins, mushrooming on outer surface, cystic changes, lipomatous infiltration and presence of intracranial hemorrhage.

Our study shows that the cutoff value of ADC of less than or equal to 0.55 can be used as a predictor for occurrence of atypical meningioma with sensitivity of 88.9%, specificity of 100%, PVP of 100% and PVN of 91.7%.

In agreement with Filippi et al, 2001 (72) who reported that ADC values less than $0.52 \times 10^{-3} \text{ mm}^2/\text{s}$ was seen in atypical meningiomas. Also Nagar et al, 2008 (48) estimate the cut of ADC value & NADC ratio between typical and atypical meningiomas groups for optimal tumor grading and found that ADC values & NADC ratios in atypical meningiomas are significantly lower than in typical meningiomas. This also agrees with Bano et al, 2013 (73) studies.

Hakyemez et al, 2006 (74) stated that only few studies have evaluated DW MR imaging for grading meningiomas, some have found that apparent diffusion co-efficient of atypical meningiomas was significant lower than that of typical meningiomas. Furthermore the accuracy and clearly defined threshold ADC

value to distinguish between typical and atypical meningiomas has not been established.

In this study, Functional MRI is able to correctly identify 15 out of 15 patients with typical meningioma (using histopathology as a gold standard), it can also identify 8 out of 9 patients with atypical meningiomas. Functional MRI has a sensitivity of 100%, specificity of 88.9%, PPV of 93.7% and NPV of 80%. However the conventional MRI is able to correctly identify 10 out of 15 patients with typical meningiomas, it can also identify 4 out of 9 patients with atypical meningioma as compared to the gold-standard histopathology. Conventional MRI has a sensitivity of 66.7 %, specificity of 44.4%, PPV of 66.7% and NPV of 44.4%.

In agreement with Xiao-Quan et al., 2016 (75) who stated that Conventional MRI has a limited role in differentiating between typical and atypical/malignant meningiomas, however DWI with ADC values & NADC ratios are reliable in differentiation between malignant and benign meningiomas.

CONCLUSION

1. The distinction between benign and atypical / malignant meningiomas is neither easily nor reliably accomplished to date when assessing the imaging features of meningiomas on routine MR images.
2. DWI is helpful in distinguishing benign from malignant and atypical meningiomas.
3. Mean ADC values of atypical/malignant meningiomas were significantly lower compared with benign meningiomas.
4. Mean NADC ratios in the atypical/malignant group were also significantly lower than the benign group.

CASES:

Case (1)
Parafalcine Meningioma

↳ Patient History:

- ◆ Female patient, 50 years old.
- ◆ Presented by severe headache & focal motor changes.

↳ MRI Findings:

(A) Axial T2 WI shows a well defined lobulated outline para-falcine extra axial mass lesion with broad dural base at high parietal region. It is surrounded with mild amount of peri-focal edema exerting mass effect in the form of effacement of the left cortical brain sulci. The mass is iso/ hyperintense to the grey matter in T2WI.

(B) Axial FLAIR: The mass is hyperintense to the grey matter.

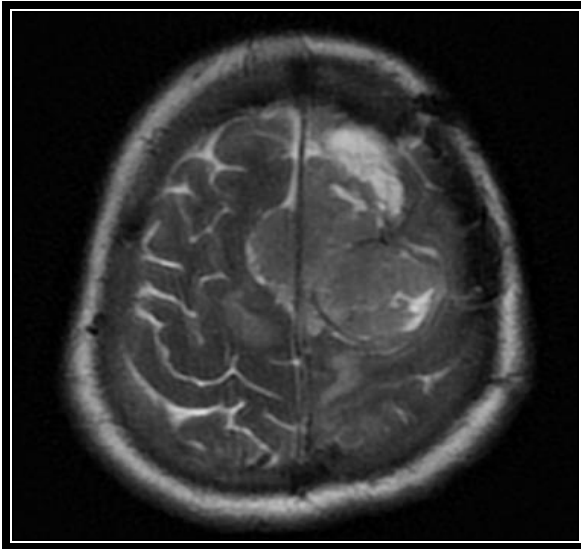
(C) Axial & (D) Sagittal post-contrast T1 WI: the mass shows homogenous intense enhancement.

(E) DWI: the lesion is hyper-intense to white matter.

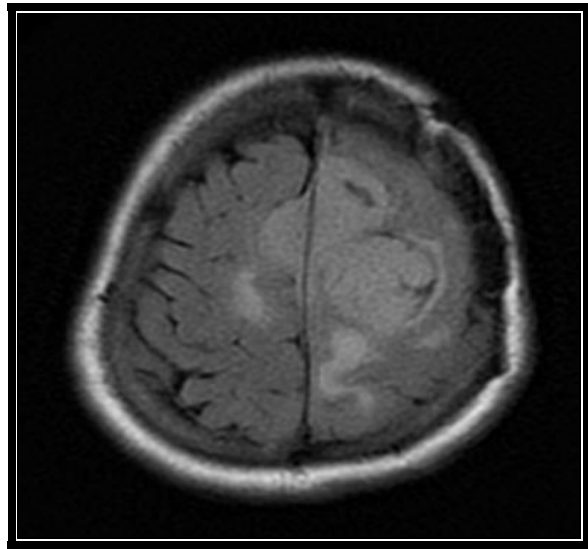
(F) ADC Map: the lesion is iso-intense to white matter with ADC value = $0.8 \times 10^{-3} \text{ mm}^2/\text{sec}$ & NADC ratio = 1

↳ Histopathology :

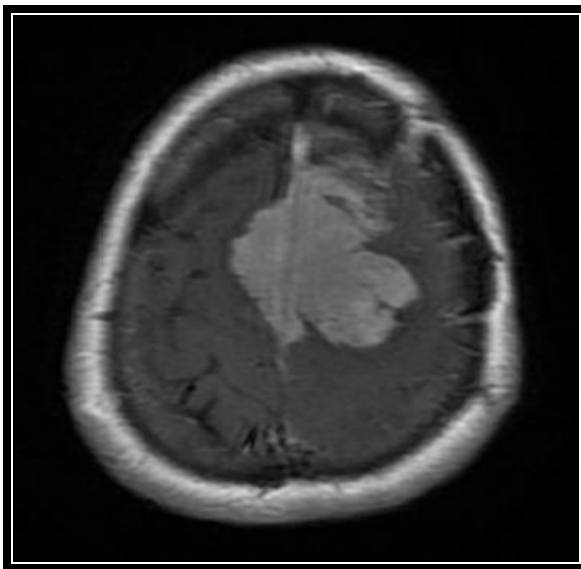
Transitional typical meningioma (Grade I).



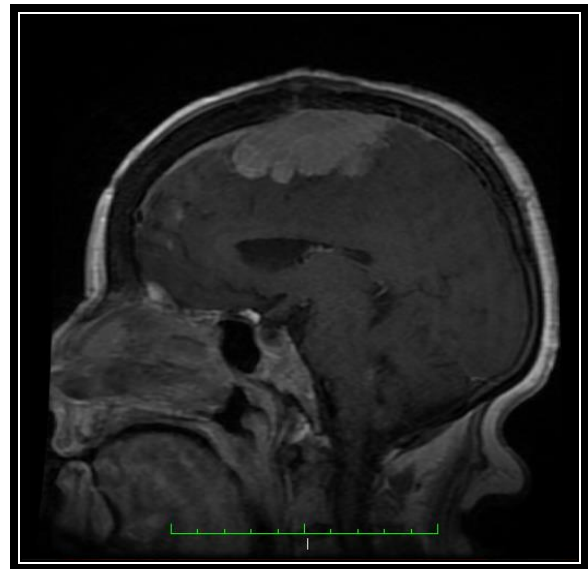
A



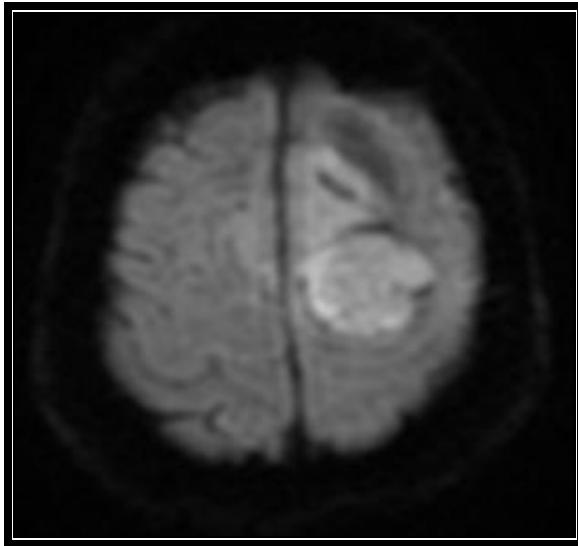
B



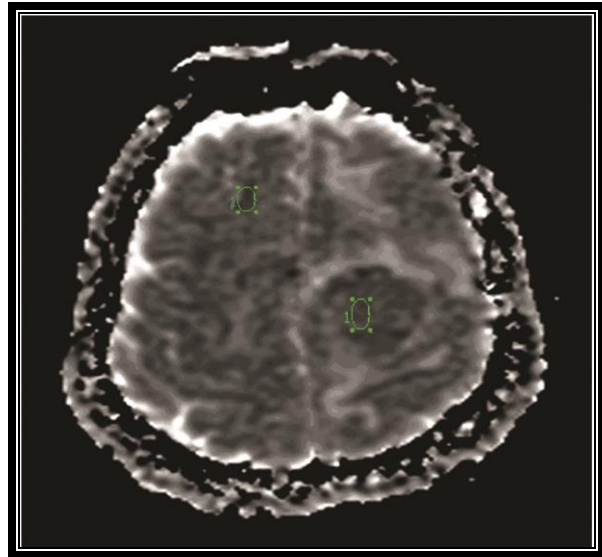
C



D



E



F

Case (2)
Left fronto-temporal Meningioma

↪ Patient History:

- ◆ Female patient, 53 years old.
- ◆ Presented by sensory & focal motor changes.

↪ MRI Finding:

(A) Axial T1WI & (B) Axial T2WI reveals a well circumscribed lobulated outline extra axial mass lesion seen in the infero-medial left frontal lobe and anterior temporal lobe surrounded with mild peri-focal edema exerting mass effect in the form of compression of the frontal horns of lateral ventricle with midline shift. The mass is iso-intense to the grey matter.

(C) Axial FLAIR: The mass is slightly hyper-intense to the grey matter.

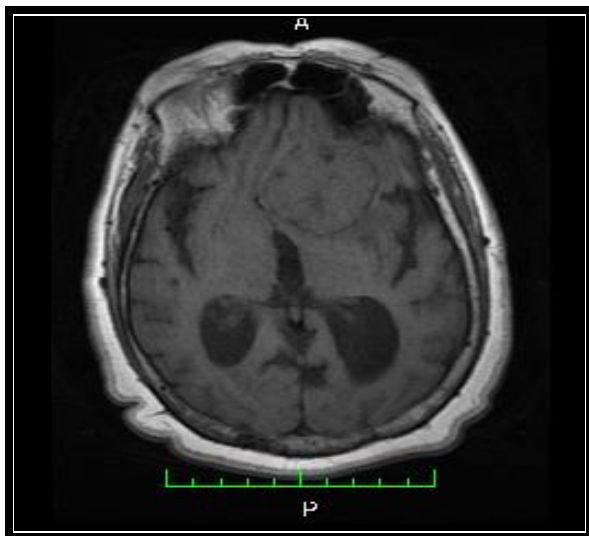
(D) Coronal post-contrast T1 WI: The mass shows homogenous enhancement. It abuts the left cavernous sinus at the superior-lateral aspect, compressing the third ventricle with midline shift.

E) DWI: the lesion is hyper-intense to the white matter.

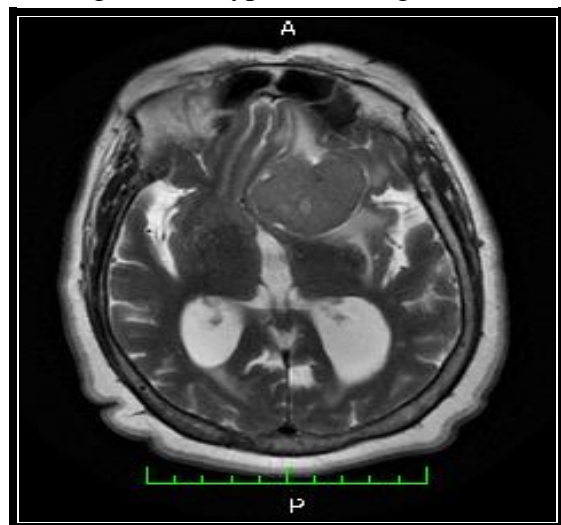
F) ADC Map: the lesion is iso-intense to the white matter. Its ADC value = 0.9×10^{-3} mm²/sec, NADC ratio= 1.2

↪ Histopathology :

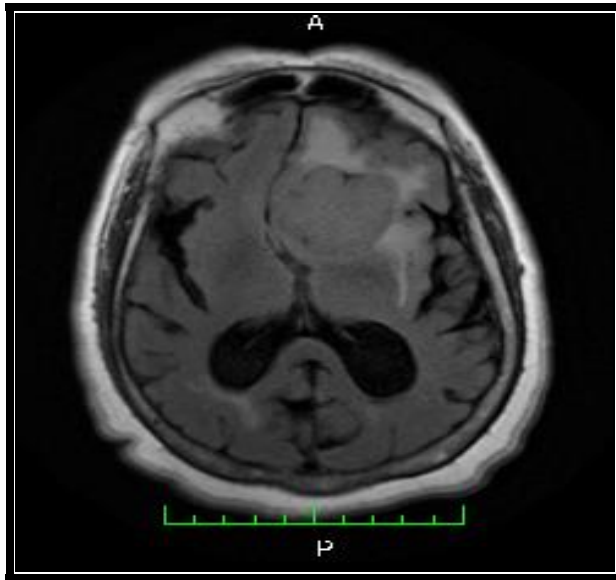
Meningiothelial typical meningioma (Grade I).



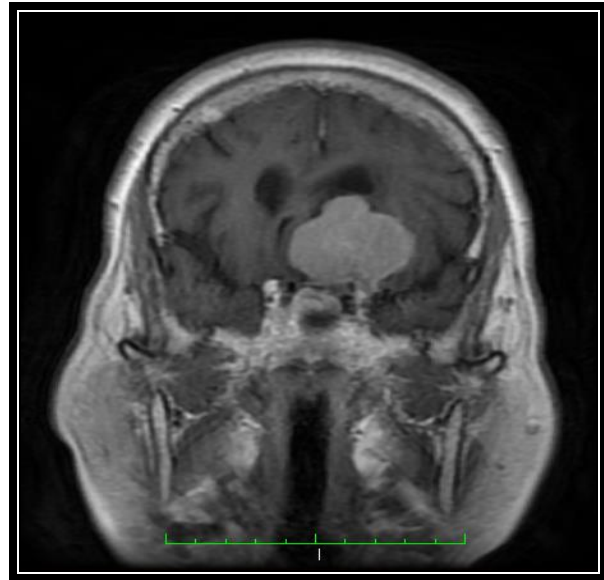
A



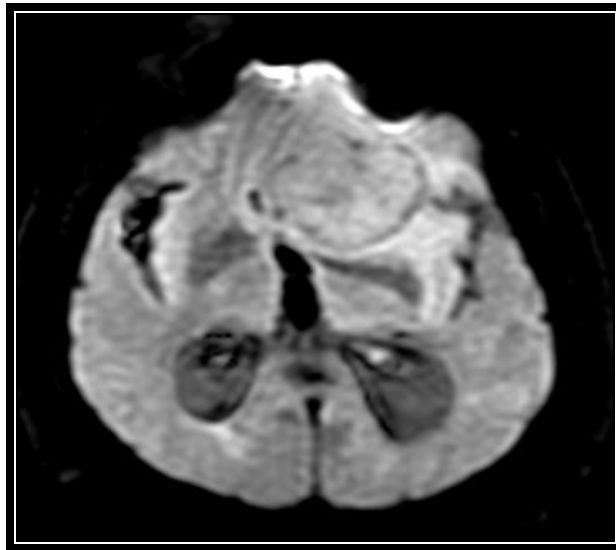B



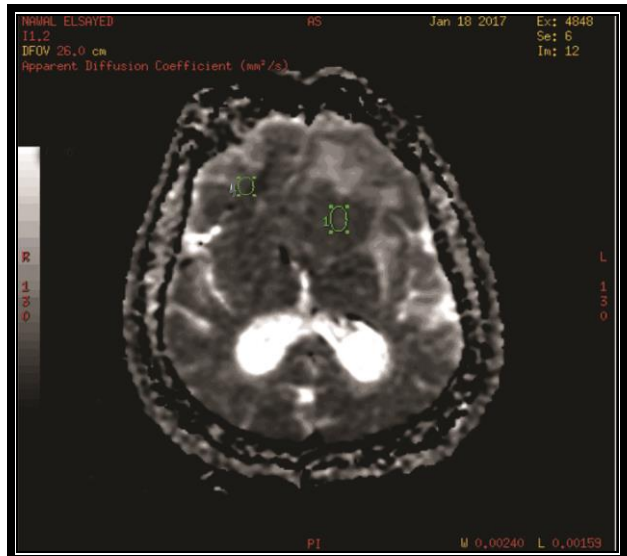
C



D



E



F

**Case (3)
Left temporal Meningioma**

↪ Patient History :

- ◆ Male patient, 40 years old.
- ◆ Presented by severe headache & focal motor changes.

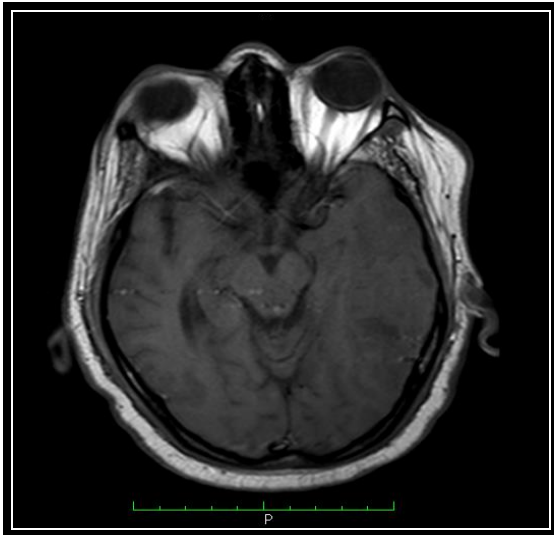↪ MRI Findings:

(A) Axial T1 WI, (B) Axial T2 WI & (C) Axial FLAIR reveal a well defined LT temporal extra axial mass lesion with broad dural attachment surrounded with mild amount of peri-focal edema. The mass is iso-intense to the grey matter on T1WI, T2WI & FLAIR.

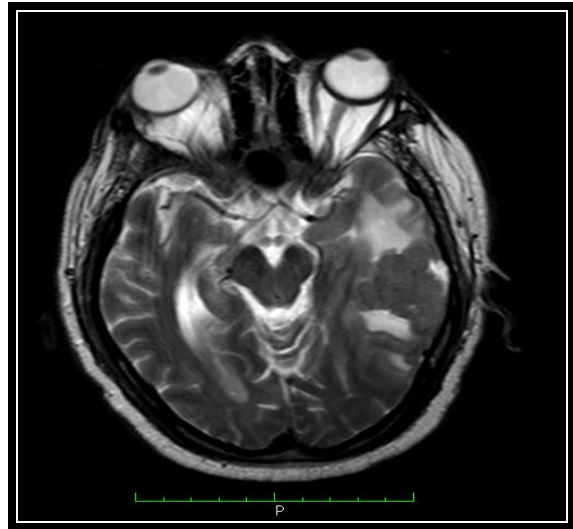- D) Sagittal Post-contrast T1 WI reveals: the mass shows homogenous enhancement.
- e) DWI: the lesion is hyper-intense to the white matter.
- f) ADC Map: the lesion is hyper-intense to the white matter with ADC value = 1.2×10^{-3} mm²/sec & NADC ratio= 0.94.

↪ Histopathology :

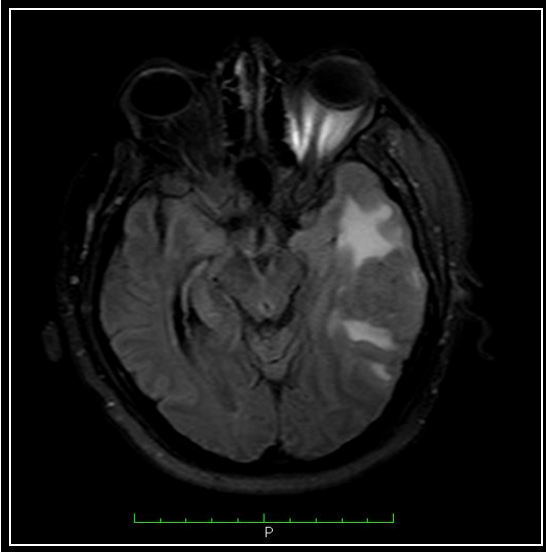Meningiothelial typical meningioma (Grade I).



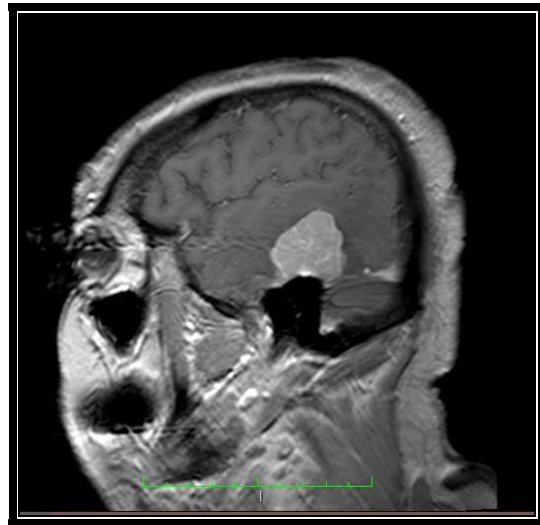
A



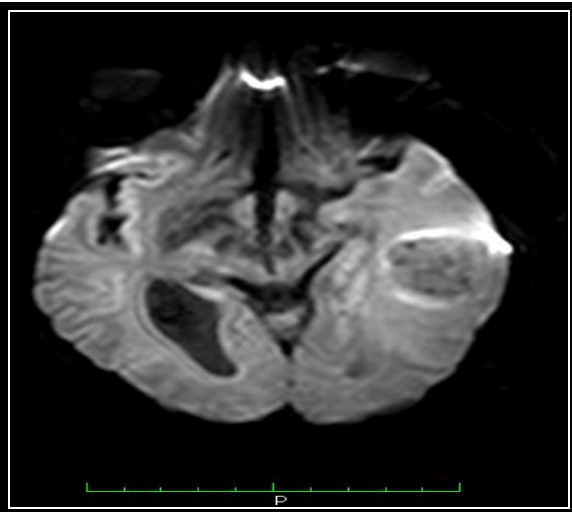
B



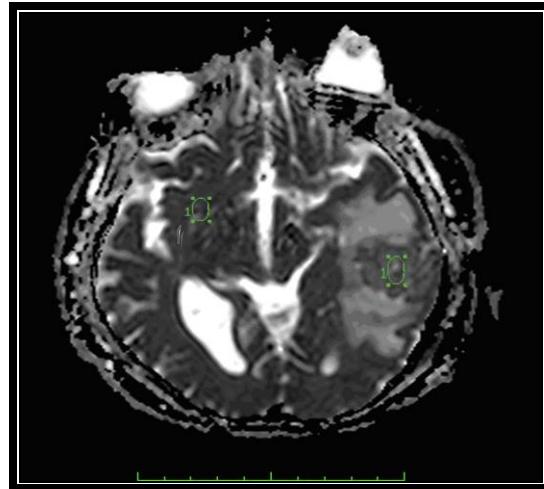
C



D



E



F

REFERENCES

1. Tantawy H. I., Mohamad F.F and Ismael A.M. (2010): The role of advanced MRI techniques in differentiating typical, from atypical and malignant meningiomas. The Egyptian Journal of Radiology and Nuclear Medicine 41, 411–419.
2. David N. Louis, Arie Perry, Guido Reifenberger, et al., (2016): The World Health Organization Classification of Tumors of the Central Nervous System. Acta Neuropathol 131:803–820.
3. Jansen JF1, Shablott MJ, van Zijl PC, et al (2006): Stem cell profiling by nuclear magnetic resonance spectroscopy. Magn Reson Med. Sep; 56(3):666-70.
4. Yamada S, Miyazaki M, Yamashita Y, et al., (2013): Fluids Barriers CNS. Dec 27; 10(1):36.
5. Demir MK1, Iplikcioglu AC, Dincer A, et al., (2006): Single voxel proton MR spectroscopy findings of typical and atypical intracranial meningiomas. Eur J Radiol. Oct; 60(1):48-55.
6. Shazia Bano, Mustansar Mahmood Waraich and Muhammad Afzal Khan, et al (2013): Diagnostic value of apparent diffusion coefficient for the accurate assessment and differentiation of intracranial meningiomas. Acta Radiol Short Rep. Nov; 2(7).
7. Hao Zhang, Lars A. Rödiger, Tianzhen Shen, et al., (2008): Matthijs Oudkerk Neuroradiology. Jun; 50(6): 525–530.
8. Patel N and Kirmi O. (2009): Anatomy and imaging of the normal meninges. Dec; 30(6):559-64.
9. Mack J, Squier W and Eastman JT, et al (2009): Anatomy and development of the meninges: implications for subdural collections and CSF circulation. Pediatr Radiol. Mar; 39(3):200-10.
10. Haines DE, Harkey HL1, al-Mefty O, et al., (1993): The surgical anatomy of the cerebral sulci. Neurosurgery. 32, 111-120.
11. <https://www.studyblue.com/notes/n/regional-anatomy-meninges/desk/4684068> (2017)
12. Vutskits L, Reisch R, Patonay L, et al., (1996): The "rete mirabile" of the clivus and the dorsum sellae. A microanatomical study. Minim Invasive Neurosurg. Dec; 39(4):138-40.
13. Shukla V, Hayman LA, Ly C, Fuller G, et al., (2002): Adult cranial dura I: Intrinsic vessels. J Comput Assist Tomogr; 26(6):1069–74.
14. Standring and Susan. Gray's, et al (2016): anatomy: the anatomical basis of clinical practice, New York : Elsevier Limited, NLM ID: 101667594.
15. Bauer DF, Youkilis A, Schenck C, et al. (2005): Thompson BG. The falcine trigeminocardiac reflex: case report and review of the literature. Surg Neurol. Feb;63(2):143-8
16. Masuhrf, Mehraein S and Einhaupl K. et al (2004): Cerebral venous and sinus thrombosis J Neurol. Jan;251(1): 11-23
17. Gupta AK, Chowdhury and Khandelwal N. et al (2013): Diagnostic radiology. Recent Advances and Applied Physics in Imaging. 2 nd ed. New Delhi: Jaypee Brothers Medical Publishers (p) Ltd.; p. 195-201).
18. Bitar R, Leung G, Perng R, et al., (2006): MR pulse sequences: What every radiologist wants to know but is afraid to ask. Radiographics; 26: 513-37).
19. Cha S. et al (2006): Update on brain tumor imaging: From anatomy to physiology. AJNR Am J Neuroradiol; 27:475-87).
20. Mulkern RV and Atlas SW, et al (2009): Magnetic Resonance Imaging of the Brain and Spine. 4 th ed. Philadelphia (PA): Lippincott Williams and Wilkins; p. 94-150).
21. Forbes KP, Pipe JG, Bird CR, et al., (2001): PROPELLER MRI: Clinical testing of a novel technique for quantification and compensation of head motion. J Magn Reson Imaging; 14:215-22).
22. Atlas SW and Thulborn KR. et al (2009): Intracranial hemorrhage. In: Atlas SW, editor. Magnetic Resonance Imaging of the Brain and Spine. 4 thed. Philadelphia (PA): Lippincott Williams and Wilkins; p. 644-94).
23. Wattjes MP, Lutterbey GG, Harzheim M, et al., (2007): Higher sensitivity in the....; 34:509–17.
24. Schaefer PW, Hahn R, Gotoh T, et al. (2000). Chem Eco 26(8):
25. Pipe JG, Jones DK, Knosche TR, et al., (2011): The basis of anisotropic water diffusion in the nervous system; 192:176–82.
26. Neelavalli J, Haacke EM, Mittal S, et al., (2009): Susceptibility weighted imaging: technical aspects and clinical applications; part 1. AJNR AMJ. Neuroradiol, 30(1) 19-30.
27. W Chen, W Zhu, II Kovanlikaya, et al., (2014): Intracranial calcifications and hemorrhages: characterization with quantitative susceptibility mapping...Radiology, 270 (2), 496-505.
28. Wetzel SG, Cha S, Johnson G, et al., (2002): Relative cerebral blood volume measurements

- in intracranial mass lesions. *Radiology*, Sep; 224(3): 797-803.
29. Hingwala D, Chatterjee S, Kesavadas C, et al., (2011): Kapilamoorthy TR. *Indian J Radiol Imaging*. Apr;21(2):90-7
 30. Castillo M, Kwock L, Mukherji SK, et al., (1996): *AJNR Am J Neuroradiol*. Sep; 17(8):1485-90.
 31. Thulborn KR, Lu A, Atkinson IC, et al., (2009): *Neuroimaging Clin N Am.*; 19:615–24).
 32.) Lu L, Wei X, Li M, et al., (2014): Emerging MRI and metabolic neuroimaging techniques in mild traumatic brain injury. *Neurol India*. Sep-Oct; 62(5):487-91.
 33. Grant PE. et al (2004): Structural MR imaging, *Epilepsia.*; 45 Suppl 4:4-16.
 34. Therese A, Dolecek, Jennifer M. et al., (2012): Primary Brain and Central Nervous System Tumors Diagnosed in the United States. *Neuro Oncol*. Nov; 14(Suppl 5): v1–v49.
 35. Nikki B, Thuijs, Bernard M. et al., (2012): Pediatric meningiomas in The Netherlands Childs Nerv Syst. 2012 Jul; 28(7): 1009–1015. Published online Apr 29.
 36. B. Godlewski, K. J. Drummond, and A. H. Kaye, et al (2012): “Radiation-induced meningiomas after high-dose cranial irradiation,” *Journal of Clinical Neuroscience*, vol. 19, no. 12, pp. 1627–1635,.
 37. Claus EB (1), Calvocoressi L, Bondy ML, et al., (2013): Dental x-rays and risk of meningioma. ... Jan 15; 119(2):465-6.
 38. Louis DN, Ohgaki H, Wiestler OD, et al., (2007): The WHO classification of tumours of the central nervous system..*Acta Neuropathol*. Aug; 114(2):97-109.
 39. Contarino MF1, Groot PF, van der Meer JN, et al., (2012): Is there a role for combined EMG-fMRI in exploring the pathophysiology of essential tremor and improving functional neurosurgery? *PLoS One.*; 7(10).
 40. Aavikko M1, Li SP, Saarinen S, et al., (2012): Loss of SUFU function in familial multiple meningioma. *Am J Hum Genet*. Sep 7; 91(3):520-6.
 41. Smith MJ, O'Sullivan J, Bhaskar SS, et al., (2013): Loss-of-function mutations in SMARCE1 cause an inherited disorder of multiple spinal meningiomas..*Nat Genet*. Mar; 45(3):295-8.
 42. Smirniotopoulos JG, Murphy FM, Rushing EJ, et al., (2007): Patterns of contrast enhancement in the brain and meninges. *Radiographics*. Mar-Apr; 27(2):525-51.
 43. http://www.hopkinsmedicine.org/neurology_neurosurgery/centers_clinics/brain_tumor/centers/meningioma/types.html.
 44. Toh CH1, Castillo M, Wong AM, et al., (2008): Primary cerebral lymphoma and glioblastoma multiforme: differences in diffusion characteristics evaluated with diffusion tensor imaging. *AJNR Am J Neuroradiol*. Mar; 29(3):471-5.
 45. Joseph E, Sandhyamani S, Rao MB, et al., (2000): Atypical meningioma: a clinicopathological analysis. *Neurol India*. Dec; 48(4):338-42.
 46. Tokgoz N et al., (2005): .Primary intraosseous meningioma: CT and MRI appearance. *AJNR Am J Neuroradiol* 26(8):2053–2056.
 47. O’Leary S et al. (2007): Atypical imaging appearances of intracranial meningiomas. *Clin Radiol* 62(1):10–17.
 48. Nagar VA et al. (2008): Diffusion-weighted MR imaging: diagnosing Atypical or malignant meningiomas and detecting tumor dedifferentiation. *AJNR Am J Neuroradiol* 29(6):1147–1152.
 49. Paek SH et al. (2005): Microcystic meningiomas: radiological characteristics of 16 cases. *Acta Neurochir (Wien)* 147(9):965–972, discussion972.
 50. R. Ideguchi, M. Morikawa, M. Enokizono, et al., (2011): MR appearances of atypical/malignant meningioma: Value of ADC and proton MR Spectroscopy. *ECR /C-1336*.
 51. D. Saloner and A. Uzelac, et al (2010): Modern meningioma imaging techniques. *J Neurooncol* 99:333–340.
 52. Young-Dae Choa and Gi-Hwan Choia, et al (2003): 1H-MRS metabolic patterns for distinguishing between meningiomas and other brain tumors. *Magnetic Resonance Imaging*;21:663-72
 53. Chourmouzi D1, Potsi S, Moumtzouoglou A, et al., (2012): Dural lesions mimicking meningiomas. *World J Radiol*. Mar 28; 4(3):75-82.
 54. Johnson MD1, Powell SZ, Boyer PJ, et al., (2002): Dural lesions mimicking meningiomas, *hum Pathol*. Dec; 33(12):1211-26.
 55. Maroldi R1 and Ambrosi C, (2005): Metastatic disease of the brain: extra-axial metastases (skull, dura, leptomenigeal) and

- tumour spread. *Eur Radiol.* Mar; 15(3):617-26.
56. Hirmiz K1, Foyle A, Wilke D, et al., (2004): Intracranial presentation of systemic Hodgkin's disease. *Leuk Lymphoma.* Aug; 45(8):1667-71.
 57. Thurnher MM1 and Rieger A, et al (2001): Malignant lymphoma of the cranial vault in an HIV-positive patient: imaging findings. *Eur Radiol.*; 11(8):1506-9.
 58. Fountas KN1 and Kapsalaki E, et al (2006): Management of intracranial meningeal hemangiopericytomas: outcome and experience. *Neurosurg Rev.* Apr; 29(2):145-53.
 59. Bisceglia M and Galliani C, et al (2011): Solitary fibrous tumor of the central nervous system. *Adv Anat Pathol.* Sep; 18(5):356-92.
 60. Witwer BP1 and Salamat MS, et al (2000): Gliosarcoma metastatic to the cervical spinal cord. *Surg Neurol.* Nov; 54(5):373-8.
 61. Dwyer KW1 and Naul LG, et al (1996): Gliosarcoma: MR features. *J Comput Assist Tomogr.* Sep-Oct; 20(5):719-23.
 62. Lerdlum S1 and Lalitanantpong S, et al (2004): MR imaging of CNS leiomyosarcoma in AIDS patients. *J Med Assoc Thai.* Sep; 87 Suppl 2:S152-60.
 63. Sahin F, Saydam G, Ertan Y, et al., (2006): Dural plasmacytoma mimicking meningioma in a patient with multiple myeloma. *J Clin Neurosci.* Feb; 13(2):259-61.
 64. Gallina P1 and Mascalchi M, et al (2004): Misleading imaging features of intracranial dural plasmacytoma: report of two cases. *Br J Neurosurg.* Dec; 18(6):643-6.
 65. Wu M, Anderson AE, Kahn LB, et al., (2001): A report of intracranial Rosai-Dorfman disease. *Ann Diagn Pathol.* Apr; 5(2):96-102.
 66. Konishi E, Ibayashi N, Yamamoto S, et al., (2003): Isolated intracranial Rosai-Dorfman disease (sinus histiocytosis with massive lymphadenopathy). *AJNR Am J Neuroradiol.* Mar; 24(3):515-8.
 67. Beseoglu K1, Knobbe CB, Reifenberger G, et al., (2006): Supratentorial meningeal melanocytoma mimicking a convexity meningioma. *Acta Neurochir (Wien).* Apr; 148(4):485-90.
 68. Neenu Philip and Prasant Peter, et al (2013): Intracranial meningiomas- a pictorial review of MRI features. *INDIAN JOURNAL OF MEDICAL SPECIALITIES*; 4(1).
 69. Zulkif Bozgeyik and Mehmet Ruhi Onur, et al (2013): The role of diffusion weighted magnetic resonance imaging in oncologic settings. *Quant Imaging Med Surg.* Oct; 3(5): 269–278.
 70. Drevelegas A, Karkavelas G, Chourmouzi D, et al. (2011): imaging of brain tumors with histological correlation. 2nd edition. Heidelberg: Springer; p. 255–88. 99.
 71. Modha A and Gutin PH, et al (2005): Diagnosis and treatment of atypical and anaplastic meningiomas: A review. *Neurosurgery.* 57(3 Sept): 439– 593.
 72. Filippi CG and Edgar MA, et al (2001): Appearance of meningiomas on diffusion-weighted images: correlating diffusion constants with histopathologic findings. *AJNR Am J Neuroradiol.* Jan; 22(1):65-72.
 73. Bano S and Waraich MM, et al (2013): Diagnostic value of apparent diffusion coefficient for the accurate assessment and differentiation of intracranial meningiomas. *Acta Radiol Short Rep.* Nov 23;2(7)
 74. Hakyemez B and Yildirim N, et al (2006): The contribution of diffusion-weighted MR imaging to distinguishing typical from atypical meningiomas. *Neuroradiology.* Aug; 48(8):513-20.
 75. Xiao-Quan Xu and Hao Hu, et al (2016): Combined Magnetic Resonance Morphometry and Histogram Analysis of Apparent Diffusion Coefficient Maps for Predicting Malignancy. *Acad Radiol*; 23:200–208.

How to cite this article: Shawky MK, Teama MI, MD, Tantawy HI, and EL Samak DA. Role of Magnetic Resonance Imaging in Evaluating Typical and Atypical Meningiomas . *ZUMJ* 2019; 25 (1); 171-186.