

Interventional Radiology in the Management of Liver Diseases: Review Article

Mostafa Saleem Hassaf

Department of Interventional Radiology, Ibn Sina Specialty Centre, Iraq

Corresponding author: Mostafa Saleem Hassaf, Mobile: 009647807070014, E-Mail: mustafasaleemkhassaf@yahoo.com

ABSTRACT

Background: Infections of the liver are common and can continue a long time. Furthermore, the fatality rate associated with chronic liver illnesses remains high, despite continuing development of novel diagnostic and treatment processes. As a result, significant attempts to improve imaging techniques have been made, notably in this decade. The morphology, circulation, metabolism, parenchymal texture, fibrosis, and/or tumour viability of the liver can all be investigated using contemporary imaging methods. Some of the novel imaging techniques and procedures that have made it possible to monitor liver function include magnetic resonance perfusion, magnetic resonance elastography, and dual-energy computed tomography (CT).

Objective: The study aimed to highlight on improved imaging techniques and advanced interventional radiology (IR) technologies, new multimodality treatments for liver illnesses have been developed.

Methods: PubMed and Google scholar were searched using the following keywords: Liver diseases, CT, MRI and liver treatments. The authors also screened references from the relevant literature, including all the identified studies and reviews, only the most recent or complete study was included, and in peer-reviewed articles between February 2010 and July 2021. **Conclusion:** Finally, this special review reviewed recent breakthroughs in both diagnostic and interventional radiology, providing us with useful perspectives in this rapidly evolving discipline.

Keywords: Liver diseases, CT, MRI, Liver treatments.

INTRODUCTION

Diseases of the liver are common and often chronic. Moreover, the mortality rate associated with chronic liver diseases remains high, despite the constant development of novel diagnostic and therapeutic modalities. Therefore, numerous efforts are being made to improve imaging techniques, especially in this decade. Currently available imaging procedures allow us to ascertain the morphology, circulation, metabolism, parenchymal texture, fibrosis, and/or tumor viability in the liver. New modalities and protocols, such as magnetic resonance (MR) perfusion, MR elastography, and dual-energy computed tomography (CT), enable the potential evaluation of liver function via imaging studies. Thus, the utilization of advanced imaging techniques and contemporary interventional radiology (IR) devices has realized novel multimodality treatments for liver diseases, resulting in promising outcomes in many patients who cannot be surgically treated⁽¹⁾. In individuals with chronic liver disorders, MRI is frequently used to examine the liver. **Kim et al.**⁽²⁾ give a well-written review on a variety of commonly used hepatic MR sequences to imaging patients with limited breath-hold skills in this special issue. Recent advances in robust liver imaging, as well as the benefits and drawbacks of these new technologies, are thoroughly explored.

Because of its many causes, liver fibrosis is a life-threatening illness with a high morbidity and fatality rate. But it has significant drawbacks, including sample variability and the intrusive nature of the procedure, which can lead to problems. To address these issues, various noninvasive imaging-based approaches for the correct identification of liver fibrosis have been developed. However, because these techniques can only assess morphological or perfusion-related changes in the liver, they can only be used to diagnose late-stage

liver fibrosis, which is marked by "irreversible" anatomic and hemodynamic changes. As a result, early detection of hepatic fibrosis is critical for initiating therapy on time and efficiently achieving disease regression⁽³⁾. Percutaneous liver biopsy is a painless treatment that can be done in the office. Imaging guidance is becoming more common, and it has a number of benefits over palpation- or percussion-guided procedures, including a lower complication rate and a higher diagnostic yield. Because of its low cost, real-time guidance, multiplanar imaging, portability, visualization and avoidance of major blood vessels and lung, and lack of ionizing radiation, ultrasound is the chosen imaging modality in most instances. The use of ultrasound for imaging guiding has also been proven to reduce the number of severe and minor problems. Although ultrasound-guided liver biopsies are slightly more expensive per procedure than palpation-guided biopsies, cost-effectiveness studies have revealed that the various advantages of ultrasound guidance may lower the overall cost of liver⁽⁴⁾.

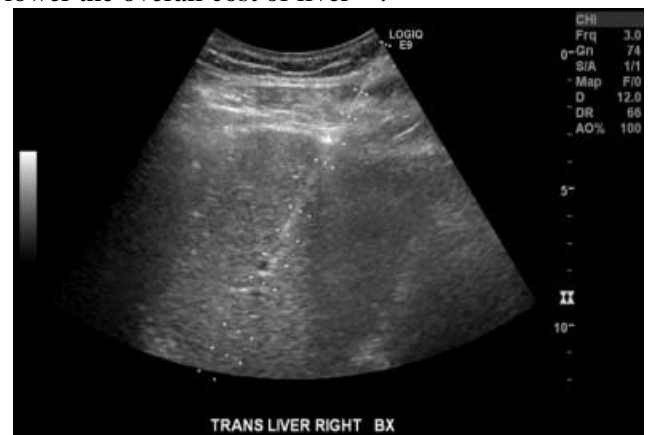

Figure (1): In the examination of a patient with known hepatitis C through a subcostal route, an ultrasound image shows real-time percutaneous needle placement for a random liver biopsy⁽⁵⁾.

HOW DOES IT WORK?

A liver biopsy's most prevalent side effect is discomfort. The majority of post-biopsy pain can be treated with intravenous or oral opioids. Bleeding is the most prevalent side effect of a liver biopsy. Subclinical bleeding can occur in up to 23% of liver biopsies and is not treated, but major haemorrhage requires a transfusion or other intervention in 0.35 of cases. Damage to surrounding organs, pneumothorax, hemothorax, peritonitis, and mortality are all possible complications ⁽⁶⁾.

Targeted liver biopsies are commonly used to assess focal hepatic abnormalities that aren't suspected

of being HCC. Because of their capacity to definitively diagnose numerous HCCs, hemangiomas, adenomas, and focal hepatic steatosis, CT and MRI are frequently utilised for first-line characterisation of focal hepatic abnormalities. Other lesions have a less distinct imaging appearance and necessitate tissue biopsy for diagnosis. As metastatic lesions are more common than basic hepatic malignant illness. The biopsy of metastatic lesions in the liver (or elsewhere) can be used to diagnose and stage the illness at the same time. As a result, liver biopsy is frequently conducted ⁽⁷⁾.

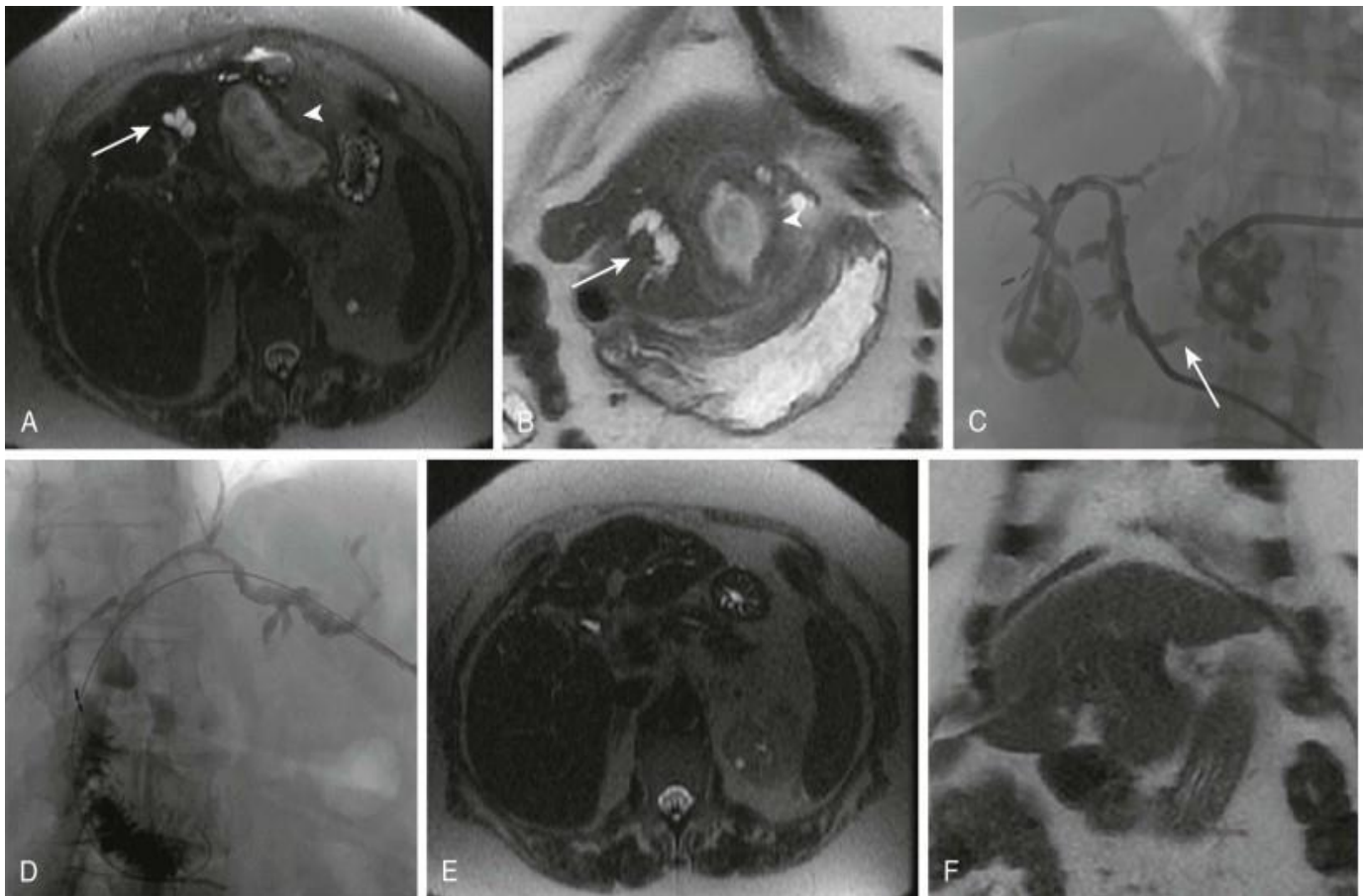


Figure (2): A and B are the two choices. A substantial heterogeneous T2 intense lesion in segment III of the liver (arrowhead) with surrounding intrahepatic biliary dilatation can be seen in the initial axial T2 and coronal T2 single-shot rapid spin-echo MR cholangiopancreatography images from a patient who presented with a hepatic abscess (arrow).

The polymicrobial infection was treated with a multi-side hole pigtail drain in the abscess, an internal/external biliary drain through the peripheral dilated biliary radicles of segment III, and intravenous antibiotics.

C. After constructing a drain and injecting contrast material into the abscess chamber, a fluoroscopic image was taken to show interaction with the biliary system (arrow). As a result of recurrent balloon dilation for a benign intrahepatic stricture, an abscess formed (images not shown).

D. The intrahepatic abscess has cleared, and a follow-up pullback cholangiogram showed no residual stricture.

E and F are the first two letters of the alphabet. Follow-up axial T2 and coronal T2 single-shot rapid spin-echo MR cholangiopancreatography images three months later indicate complete clearance of the intrahepatic abscess and biliary dilatation in segment III ⁽⁸⁾.

INTERVENTIONAL RADIOLOGY IN THE LIVER TREATMENTS

Our interventional radiologists are skilled at performing life-saving procedures for patients suffering from cancer and other diseases affecting the liver ⁽⁹⁾.

Balloon-occluded retrograde transvenous obliteration (BRTO)

Portal hypertension is when scar tissue blocks blood flow from the portal vein to the hepatic veins. This can lead to enlarged stomach and esophageal veins (called varices), which are at risk for bursting and creating dangerous internal bleeding. Balloon-occluded retrograde transvenous obliteration (BRTO) is a minimally invasive procedure that can reduce the likelihood of rupture. It can be performed as a standalone treatment or as a supplement to a transjugular intrahepatic portosystemic shunt (TIPS) procedure ⁽¹⁰⁾.

Biliary drain placement

If your bile duct is blocked by scar tissue or a tumor, your interventional radiologist may use a minimally invasive procedure called biliary drain placement to drain the built-up bile in your liver. Since biliary drain placement only involves a small nick in the skin, you can also expect less pain and fewer risks of complication than open surgery ⁽¹¹⁾.

Biliary stent placement

Similar to a biliary drain placement, biliary stent placement is used to drain built-up bile in the liver when the bile duct is blocked. Rather than using a catheter to drain the bile fluid outside of the body, biliary stent placement uses a plastic or metal tube to keep the bile duct open while the fluid drains internally ⁽¹²⁾.

Percutaneous transhepatic cholangiogram (PTC)

When the bile ducts are blocked, this can cause a buildup of bile in the liver, leading to further life-threatening health complications. Percutaneous transhepatic cholangiogram (PTC) is a diagnostic procedure in which X-ray images of the bile ducts are taken with contrast dye in order to help medical teams understand where exactly the blockage has occurred ⁽¹³⁾.

Transjugular intrahepatic portosystemic shunt (TIPS)

A transjugular intrahepatic portosystemic shunt (TIPS) is used to treat complications of portal hypertension, which occurs when scar tissue blocks blood flow from the portal vein to the hepatic veins. Our interventional radiologists are experts in using TIPS to reduce internal bleeding with fewer risks than open surgery ⁽¹⁴⁾.

Transjugular liver biopsy

A transjugular liver biopsy can help to diagnose or confirm a diagnosis of liver disease. As a minimally invasive procedure, your interventional radiologist will remove tissue samples from the body under the guidance of advanced imaging.

Unlike traditional biopsies, a transjugular liver biopsy is conducted through the jugular vein in the neck and into a hepatic vein. This makes it a safer approach for patients with a high risk for bleeding ⁽¹⁵⁾.

CONCLUSION

Finally, this special review reviewed recent breakthroughs in both diagnostic and interventional radiology, providing us with useful perspectives in this rapidly evolving discipline.

Conflict of interest: The author declared no conflict of interest.

Sources of funding: This research did not receive any specific grant from funding agencies in the public, commercial, or not-for-profit sectors.

REFERENCES

1. **Murata S, Niggemann P, Lee E et al. (2015):** Diagnostic and Interventional Radiology for Liver Diseases. doi: 10.1155/2015/147583
2. **Kim S, Lee J, Lee E et al. (2015):** Preoperative staging of gallbladder carcinoma using biliary MR imaging. *J Magn Reson Imaging*, 41: 314–321.
3. **Golzarian N, Rostambeigi D, Hunter S et al. (2013):** A case series meta-analysis comparing stenting to angioplasty for hepatic artery stenosis after liver transplant. *Eur Radiol.*, 23: 1323–1334.
4. **Mannelli L, Nougaret S, Vargas H et al. (2015):** Advances in diffusion-weighted imaging. *Radiol Clin North Am.*, 53: 569–581.
5. **Defreyne L (2021):** Interventional radiology for liver diseases. *European Radiology*, 31: 2227–2230.
6. **Wile G, Leyendecker J (2010):** Magnetic resonance imaging of the liver: Sequence optimization and artifacts. *Magn Reson Imaging Clin N Am.*, 18: 525–547.
7. **Hernando D, Levin Y, Sirlin C et al. (2014):** Quantification of liver iron with MRI: State of the art and remaining challenges. *J Magn Reson Imaging*, 40: 1003–1021.
8. **Agostini A, Kircher M, Do R et al. (2016):** Magnetic Resonance Imaging of the Liver (Including Biliary Contrast Agents): Part 2: Protocols for Liver Magnetic Resonance Imaging and Characterization of Common Focal Liver Lesions. *Semin Roentgenol.*, 51 (4): 317–333.
9. **Mannelli L, Bhargava P, Osman S et al. (2013):** Diffusion-weighted imaging of the liver: A comprehensive review. *Curr Probl Diagn Radiol.*, 42: 77–83.
10. **Dhondt E, Vanlangenhove P, Van Vlierberghe H et al. (2019):** Benign anastomotic biliary strictures untreatable by ERCP: a novel percutaneous balloon dilatation technique avoiding indwelling catheters. *Eur Radiol.*, 29: 636–644.
11. **Dhondt E, Vanlangenhove P, Van Vlierberghe H et al. (2019):** Benign anastomotic biliary strictures untreatable by ERCP: a novel percutaneous balloon dilatation technique avoiding indwelling catheters. *Eur Radiol.*, 29: 636–644.
12. **De Gregorio M, Criado E, Guirola J et al. (2020):** Absorbable stents for treatment of benign biliary strictures: long-term follow-up in the prospective Spanish registry. *Eur Radiol.*, 30 (8): 4486–4495.
13. **Krokidis M, Fanelli F, Orgera G et al. (2010):** Percutaneous treatment of malignant jaundice due to extrahepatic cholangiocarcinoma: covered Viabil stent versus uncovered Wallstents. *Cardiovasc Intervent Radiol.*, 33: 97–106.
14. **Geeroms B, Laleman W, Laenen A et al. (2017):** Expanded polytetrafluoroethylene-covered stent-grafts for transjugular intrahepatic portosystemic shunts in cirrhotic patients: long-term patency and clinical outcome results. *Eur Radiol.*, 27: 1795–1803.
15. **Bureau C, Thabut D, Oberti F et al. (2017):** Transjugular intrahepatic portosystemic shunts with covered stents increase transplant-free survival of patients with cirrhosis and recurrent ascites. *Gastroenterology*, 152: 157–163.