

Radiology and the Treatment of Brain Injury and Disease: Review Article

Mostafa Saleem Hassaf

Department of Interventional Radiology, Ibn Sina Specialty Centre, Iraq

Corresponding author: Mostafa Saleem Hassaf, Mobile: 009647807070014, E-Mail: mustafasaleemkhassaf@yahoo.com

ABSTRACT

Background: Traumatic brain injury (TBI) is a major cause of morbidity and mortality worldwide. Radiology, MRI, CT, and PET scans play an important role in the evaluation, diagnosis, and triage of patients with TBI. Recent studies suggest that it will also help predict patients' outcomes.

Objective: This study aimed to investigate the benefits from using MRI, CT, and PET scans to diagnose brain injuries or diseases, radiologically. **Methods:** PubMed, Google scholar and Science direct were searched using the following keywords: Brain injury, brain disease, MRI, CT and PET scans. The authors also screened references from the relevant literature, including all the identified studies and reviews, only the most recent or complete study was included between December 2007 and January 2022. Documents in a language apart from English have been excluded as sources for interpretation. Papers apart from main scientific studies had been excluded (documents unavailable as total written text, conversation, conference abstract papers and dissertations).

Conclusion: Primary and metastatic brain tumours are frequently observed in neuroimaging practice. Because of the wide number of treatment options currently available to treat these tumours, post-treatment imaging interpretation has proven to be challenging. Understanding post-treatment imaging methods, treatment response criteria, and common treatment-related issues will help you tackle this tough topic more easily.

Keywords: Brain injury and disease, MRI, CT, PET.

INTRODUCTION

Radiologists typically employ magnetic resonance imaging (MRI), computed tomography (CT), or positron emission tomography (PET) scans to obtain thorough images of a patient's brain. These images are used to identify a number of brain disorders, such as dementia, Alzheimer's disease, and Parkinson's disease, as well as to assist clinicians in developing the most effective treatment options. They can also show the consequences of trauma, strokes, and convulsions, as well as diagnose brain infections and tumors ⁽¹⁾.

Every year, more than 2.5 million people in the United States attend the emergency room, are

hospitalized, or die as a result of brain injuries. MRI, CT, and PET scans are vital in assisting clinicians in making the best decisions possible when treating everything from mild head injuries to traumatic brain injuries. Doctors can use the right scans to determine the severity of an injury and make informed judgments about operations or less invasive procedures ⁽²⁾.

In addition to using MRI, CT, and PET scans to diagnose brain injuries or diseases, radiology is useful for treating specific types of brain disease, such as cancer ⁽¹⁾.

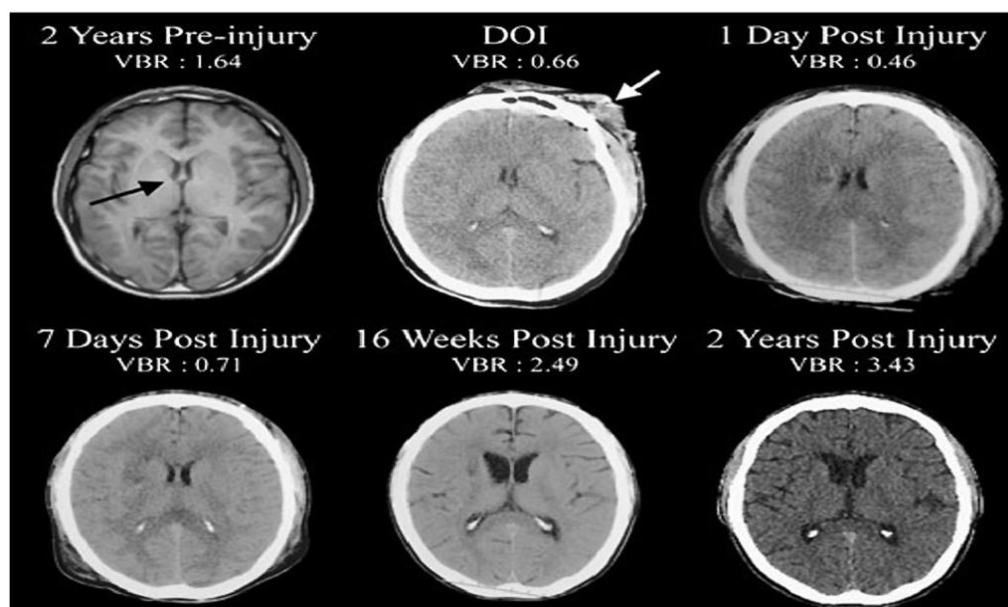


Figure (1): Two years prior to sustaining a severe traumatic brain injury (TBI) this patient underwent magnetic resonance imaging (MRI) as part of an assessment for persistent headache. The MRI was interpreted as within normal limits (WNL) and computation of the ventricle-to-brain ratio (VBR) was likewise WNL (average adult VBR is ~1.5 with a 0.5 standard deviation based on total ventricular volume/total brain volume multiplied by 100 so that whole numbers may be used) ⁽³⁾.

According to the National Cancer Institute, more than 23,380 new instances of brain and other nervous system tumours are discovered each year. Radiation therapy is used to treat patients with brain cancer, with the goal of curing the disease in about half of the cases. When cancer affects only one – or possibly a few – areas of the brain, stereotactic radiosurgery, which focuses high-power energy on a limited area of the brain, is employed. Occasionally, the entire brain will be treated. This can be done if the cancer has progressed to multiple sites or if there is a risk of it spreading ⁽⁴⁾.

How does it work?

The detection and treatment of epilepsy is another application for brain imaging. Medical imaging has advanced to the point that it may now be used to both diagnose and guide tissue removal procedures. The procedure was invented by Yale University's James Duncan, as well as engineers, physicists, and doctors from Albert Einstein College of Medicine, the University of Minnesota, and Brain LAB, Inc. Surgery time has been slashed in half because of the new image-centric method, which allows doctors to remove hazardous tissue more swiftly. MRI is the most sensitive

approach for detecting and studying epileptic pathophysiology in situations with lesional epilepsies, such as hippocampal sclerosis and cortical abnormalities. MRI can help predict surgical success and may hold promise in the future for dimensional seizure focus localization according to the National Center for Biotechnology Information ⁽⁴⁾.

The ability of an MRI to detect cerebral abnormalities by analysing a person's metabolism or blood flow determines its sensitivity. Medical neuroimaging has a thorough understanding of the intricacies of brain disorders and their causes ⁽⁵⁾.

One of the most examples in radiology and the treatment of brain injury and disease is traumatic brain injury:

Young patients are more likely to suffer from traumatic brain injuries, and men account for the bulk of cases (75%) ⁽⁴⁾. Although sports are a significant cause of relatively minor repetitive head injuries that can develop to chronic traumatic encephalopathy, motor vehicle accidents and assault are the most common causes of more serious injuries ⁽⁶⁾.

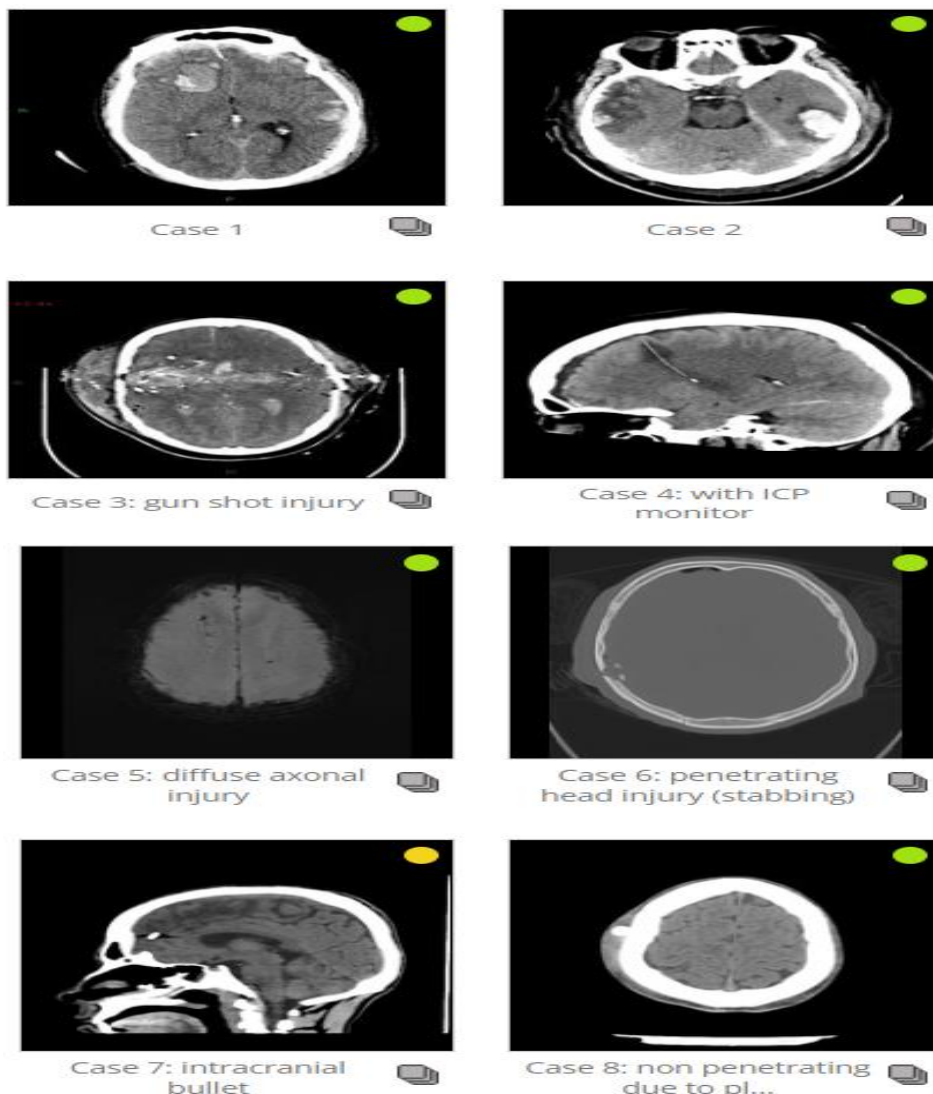


Figure (2): Some brain injury disorders (8 instances) that reveal various forms of injury and their radiological images ⁽⁷⁾.

Some of the possible indications for using CT in the acute setting for concussion patients (to rule out more serious forms of traumatic brain injury, such as intracranial bleeding) are as follows: Consciousness loss, post-traumatic amnesia, permanently changed mental status, focal neurology, signs of skull fractures, or clinical deterioration are all possible causes for clinical deterioration ⁽⁷⁾.

CT is the imaging workhorse in TBI, especially in the acute setting, and can detect the majority of damage right away. Multiple injuries are prevalent, including a mix of brain contusions and traumatic subarachnoid, subdural, and extradural haemorrhage, as well as skull and face fractures, which are discussed individually. In the acute context, the advantages of CT over MRI include increased sensitivity for fracture, vascular injury, and CSF leak detection, as well as the elimination of the need for MRI safety screening (particular in the setting of penetrating injury) ⁽⁸⁾.

MRI is useful in certain situations, such as when the clinical status of a patient does not match the CT findings (this can often occur in DAI) ⁽⁹⁾. Blood products (SAH, EDH, SDH, and hemorrhagic contusions) are more sensitive to MRI than non-hemorrhagic cortical contusions, brain-stem injuries, and axonal injuries ⁽⁸⁾. If there are chronic unexplained neurological signs and clinically severe brain injury is suspected, there is evidence to justify the use of MRI in the setting of normal CT. Because of its increased sensitivity, MRI is the recommended imaging modality in the setting of subacute or chronic traumatic brain damage with neurologic symptoms. For imaging results, please refer to the respective articles ^(9,10).

Treatment and prognosis:

To remove big hematomas with a large mass effect, neurosurgery should be utilized as soon as feasible. If you develop hydrocephalus, ventricular drainage may be required right away. The insertion of an intracranial pressure (ICP) monitor is a frequent procedure used to aid in the evaluation of severe TBI ^(11,12).

Follow-up CT scans are required on a regular basis. 6-9 hours after the occurrence, 15% of those with diffuse injuries will acquire new lesions, and 35% (range 25-45%) of people with brain contusions will have their size expand ⁽¹³⁾.

CONCLUSION

Primary and metastatic brain tumours are frequently observed in neuroimaging practice. Because of the wide number of treatment options currently available to treat these tumours, post-treatment imaging interpretation has proven to be challenging. Understanding post-treatment imaging methods, treatment response criteria,

and common treatment-related issues will help you tackle this tough topic more easily.

Conflict of interest: The author declared no conflict of interest.

Sources of funding: This research did not receive any specific grant from funding agencies in the public, commercial, or not-for-profit sectors.

REFERENCES

1. **Yuh E, Jain S, Sun X et al. (2021):** Pathological computed tomography features associated with adverse outcomes after mild traumatic brain injury. *JAMA Neurol.*, 78 (9): 1–12.
2. **Menon D, Schwab K, Wright D et al. (2010):** Position Statement: Definition of Traumatic Brain Injury. *Archives of Physical Medicine and Rehabilitation*, 91 (11): 1637–1640.
3. **Bigler E, Maxwell W (2012):** Neuropathology of mild traumatic brain injury: Relationship to neuroimaging findings. *Brain Imaging Behav.*, 6: 108–136.
4. **Wintermark M, Sanelli P, Anzai Y et al. (2015):** Imaging Evidence and Recommendations for Traumatic Brain Injury: Conventional Neuroimaging Techniques. *Journal of the American College of Radiology*, 12 (2): 1–14.
5. **Saunders D, Thompson C, Gunny R et al. (2007):** Magnetic resonance imaging protocols for paediatric neuroradiology. *Pediatr Radiol.*, 37: 789-96.
6. **McAllister T, Saykin A, Flashman L et al. (2010):** Brain activation during working memory 1 month after mild traumatic brain injury: a functional MRI study. *Neurology*, 53: 1300–1308.
7. **Lizzo J, Waseem M (2022):** Brain Trauma. Treasure Island (FL): StatPearls Publishing. <https://www.ncbi.nlm.nih.gov/books/NBK549892/>
8. **Schweitzer A, Niogi S, Whitlow C et al. (2019):** Traumatic Brain Injury: Imaging Patterns and Complications. *RadioGraphics*, 39 (6): 1571-1595.
9. **Hergan K, Schaefer P, Sorensen A et al. (2010):** Diffusion-weighted MRI in diffuse axonal injury of the brain. *Eur Radiol.*, 12 (10): 2536–41.
10. **Moen K, Skandsen T, Folvik M et al. (2012):** A longitudinal MRI study of traumatic axonal injury in patients with moderate and severe traumatic brain injury. *J Neurol Neurosurg Psychiatry*, 83 (12): 1193–200.
11. **Bodanapally U, Shanmuganathan K, Saksobhavit N et al. (2013):** MR imaging and differentiation of cerebral fat embolism syndrome from diffuse axonal injury: application of diffusion tensor imaging. *Neuroradiology*, 55 (6): 771–8.
12. **Biffi W, Cothren C, Moore E et al. (2010):** Western Trauma Association critical decisions in trauma: screening for and treatment of blunt cerebrovascular injuries. *J Trauma*, 67 (6): 1150–3.
13. **Kobata H (2017):** Diagnosis and treatment of traumatic cerebrovascular injury: pitfalls in the management of neurotrauma. *Neurol Med Chir.*, 57 (8): 410–7.