

# EFFECT OF MATERNAL VITAMIN D3 DEFICIENCY ON DENTINOGENESIS IN RATS (EXPERIMENTAL STUDY)

Ahmed A. Saleh<sup>1\*</sup> Msc, Amira A. Elnozahy<sup>2</sup> PhD, Khadiga Y. Kawana<sup>2</sup> PhD, Hossam Eldin M. Mostafa<sup>3</sup> PhD

## ABSTRACT

**INTRODUCTION:** Vitamin D3 insufficiency has become a severe health problem that affects more than one billion people worldwide. Maternal vitamin D3 deficiency can induce dentin defects during tooth development.

**OBJECTIVES:** To evaluate the biological effect of maternal vitamin D3 deficiency on dentinogenesis of the rat offspring.

**MATERIALS AND METHODS:** Twelve female Albino rats were used. Rats were divided randomly into two equal groups. In the control group, rats were fed normal balanced diet and exposed to the normal light/dark cycle. In the study group, rats were housed in incandescent light devoid of ultraviolet B-light and fed a diet free of vitamin D3. Vitamin D3 level in the serum was measured every two weeks till reached vitamin D3 deficiency. Female rats were mated to be pregnant. At the fourth day after labor, two pups were taken from the litter of each mother. The dentinogenesis of the developing mandibular first molars was examined by the light and transmission electron microscope and evaluated by histomorphometric analysis.

**RESULTS:** Vitamin D3 deficiency harmfully affected odontoblast differentiation, dentin formation and mineralization.

**CONCLUSION:** Maternal vitamin D3 deficiency during tooth development has an adverse effect on odontoblast differentiation, dentin formation and mineralization.

**KEYWORDS:** vitamin D3, dentinogenesis, odontoblast.

1. Assistant Lecturer of Oral Biology -Faculty of Dentistry –Alexandria University
2. Professor of Oral Biology -Faculty of Dentistry –Alexandria University
3. Lecturer of Oral Biology- Faculty of Dentistry - Alexandria University

*\*Corresponding author*

E-mail: [salehsaleh.ss25@gmail.com](mailto:salehsaleh.ss25@gmail.com)

## INTRODUCTION

Vitamin D3 is a fat-soluble vitamin that is required for regular bone and tooth growth. It coordinates physiological processes by maintaining calcium and phosphate homeostasis, promoting growth, and inducing required bone remodelling (1).

Vitamin D3 is produced when the skin is exposed to sunlight. A daily half-hour of full-body exposure to sunlight can produce almost 10,000 units of cholecalciferol (2). Different factors, such as skin pigmentation and geographic location, influence vitamin D production (e.g., higher latitude). Vitamin D3 has a 15-day half-life in the blood circulation, emphasizing the importance of replenishing the body's supply on a regular basis (3).

Vitamin D3 is not naturally present in many foods. Some foods are rich in vitamin D like oily fish while other foods like eggs, mushrooms and oats contain trace amounts (4).

According to the Institute of Medicine (IOM), serum levels of 25(OH)D of 20 ng/mL are regarded sufficient, whereas levels of 12 ng/mL or less are termed vitamin D3 deficiency, while serum levels of >50 ng/mL are considered an overdose and may cause possible harm (5).

Vitamin D3 insufficiency has become a severe health problem that affects over one billion people worldwide. Due to the usage of sun screens, it is mostly caused by a lack of exposure to sunshine with sufficient ultraviolet B rays (6). Vitamin D3 shortage can also be caused by a lack of vitamin D3 in the diet or congenital abnormalities of absorption and metabolic conversion. Due to increased renal clearance, several medications might cause vitamin D3 insufficiency (for instance, with carbamazepine, phenytoin and oxcarbazepine regimens). Vitamin D3 deficiency has been linked to a variety of skeletal illnesses,

including rickets (in children) and osteomalacia (in adults) (7).

Vitamin D3 has been shown to affect the transcription of a wide range of target genes, including numerous genes involved in bone and tooth development (8). Transcription mechanism is initiated by the circulating 1,25(OH)2D3 initiates signaling primarily via the vitamin D3 receptor (VDR), a widely expressed intracellular steroid second receptor that once activated, participates in the transcription of 1,25(OH)2D3 related genes. Signaling mediated by 1,25(OH)2D3 activates cells in the dento-alveolar complex. Vitamin D receptor (VDR) and 1,25(OH)2D3-responsive calcium binding proteins, such as calbindin-D9k and D28k genes, are expressed in ameloblasts, odontoblasts, cementoblasts, osteoblasts, and other cells of the developing periodontium (9).

Because of its function in placental development and calcium delivery to the embryo, vitamin D3 is extremely important during pregnancy (10). In females with low 25(OH)D levels, the fetus is unable to obtain sufficient vitamin D3 for normal mineralization processes in utero, and shorter gestation duration affecting growth has been reported (11). Several studies in the Middle East have found that pregnant or breastfeeding women are at higher risk of vitamin D3 insufficiency (12,13). Over the previous two decades, data on Egyptians' vitamin D3 status has accumulated, indicating that vitamin D insufficiency is common among healthy people (14).

Dentin is the mineralized tissue of the tooth with the highest volume. Dentinogenesis is a highly regulated and well-controlled process that involves a variety of cellular and extracellular factors. Vitamin D3 is essential for odontoblast differentiation during the bell stage of tooth development. Vitamin D3 also controls the mineralization of the predentin through expression of various non-collagenous matrix proteins such as dentin matrix protein-1 (DMP-1) and osteocalcin (15).

Individuals with vitamin D3 deficiency have developmental disorders in both the alveolar bone and teeth and have increased incidence of dental diseases Such as dental hypoplasia, delayed eruption of teeth, increased incidence of dental caries, and periodontal diseases ranging from mild gingivitis to complete alveolar bone loss (7).

Few studies have revealed the changes caused by vitamin D3 deficiency and its impact on formation and mineralization of dentin (16,17). These previous studies used

light microscopic images for assessment of the impact of vitamin D3 deficiency on dentinogenesis. So, in the present study aimed to probe the depth of vitamin D3 deficient dentin using both light and transmission electron microscope.

## MATERIALS AND METHODS

The study design was approved by the Ethical Committee of Faculty of Dentistry, Alexandria University. This study employed 12 adult female albino rats who were 6 months old and weighed (200- 250) grams. Animals were obtained from the animal house of medical research institute, Alexandria University. They were kept under the same environmental conditions in the animal house. The animals were randomly divided into two equal groups (6 in each group). In each group, rats were prepared for two weeks to optimize their Vitamin D level in their sera before mating as follows:

Group I (control group): rats were fed on normal balanced diet and exposed to the normal light/dark cycle with constant temperature with food and water provided ad libitum.

Group II (Study group): rats were fed on vitamin D3 free diet and housed in incandescent light devoid of ultraviolet B radiation with food and water provided ad libitum.

After 2 weeks, blood was collected from lateral tail vein of each rat to measure the level of vitamin D3 metabolites in the serum before mating. For the control group, Vitamin D3 was checked by measurements of 25(OH) D3 in the sera of female rats. Normal level ranging from 12-20 ng/ml of vitamin D3 was sufficient. For the study group, vitamin D3 was checked by measurements of 25(OH) D3 in the sera of the female rats. Vitamin D3 metabolites were undetectable in the serum.

**Mating, pregnancy and Labor**

Male rats were allowed to mate with female rats overnight (two females with one male). Male rats were removed from their cages in the early morning. Pregnancy was tested by the formation of vaginal plug. Gestational period took about 21-27 days .After birth; two pups were taken from the litter of each mother (18).

**Euthanasia**

At the fourth day after birth, pups of each group were euthanized, decapitated and the mandible of each rat was dissected out. Mandibles were prepared for histological and ultrastructural examination (19).

**Histological examination**

Specimens were fixed in 10% neutral-buffered formalin, washed, decalcified with 10% trichloroacetic acid, dehydrated with ascending concentrations of ethanol, cleared with xylene, and embedded in paraffin wax blocks. From each specimen, approximately 60 mesio-distal 5µm-thick sections of the lower first molars were obtained stained with haematoxylin and Eosin (H&E) and examined by light microscope for histological evaluation of dentin (20).

**Transmission electron microscope examination**

These procedures were done at the Faculty of Science, Alexandria University. The specimens were fixed in 3% glutaraldehyde 0.1 M sodium cacodylate buffer, pH 7.3. Then they were decalcified using 4% EDTA After that, they were osmicated for 1 h in 1% osmium tetroxide. Prior to embedding, all samples were dehydrated in a graded ethanol series, infiltrated with the embedding media, placed into mounting molds and the blocks were polymerized in an oven regulated to 60 °C for 2 days. Semi-thin sections (1 micron) were cut using a Leica ultra-microtome followed by staining by toluidine blue for tissue orientation to choose the field of examination by the electron microscope. After this, ultra-thin sections were cut and stained with uranyl acetate and lead citrate after which the sections were visualized by transmission electron microscope (21).

**Histomorphometric analysis**

Computer assisted histomorphometry (Image J) was performed in H&E sections to measure the average dentin and pre-dentin thickness formed in each group. The area of interest was the pre-dentin and dentin thickness in occlusal region of the mandibular first molar (22).

## RESULTS

**Histological results**

*Control group*

The odontoblasts are well differentiated tall columnar cells with proximally situated nuclei. The sub-odontoblastic zone is studded with undifferentiated mesenchymal cells. The newly formed dentin exhibited a uniform thickness and a homogenous staining denoting a uniform mineralization without evident inter-globular dentin. Regular mineralization front between dentin and pre-dentin. (Fig.1)

*Study group*

The odontoblasts appear disorganized, ill differentiated and poorly arranged in homogenous row. The newly formed dentin was not uniform in thickness with irregular mineralization front between dentin and

pre-dentin. The pre-dentin Increase in thickness could also be noticed in comparison to the control group. Evident interglobular dentin was present in this group. (Fig.2)

**Histomorphometric and statistical analysis**

Two different parameters were evaluated statistically, the thickness of the newly formed dentin and the pre-dentin thickness. The statistical analysis of the results using t-test was done. Dentin and pre-dentin thickness were measured in the occlusal area of the tooth germ in group I (control) and group II (study). Differences were statistically significant which demonstrated in Table (1) and Table (2).

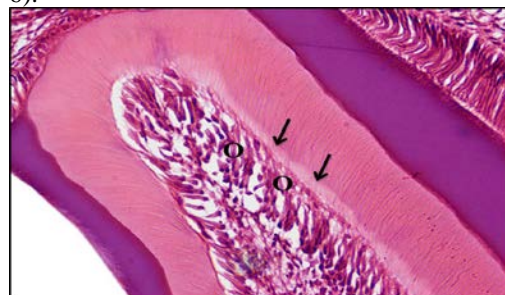**Ultrastructure results**

*Control group*

The appearance of odontoblasts coincided with that of active secretory cells. The nuclei were euchromatic with a continuous nuclear membrane. The supranuclear cytoplasm showed numerous Golgi complexes which appeared cylindrical in shape and were surrounded by numerous rough endoplasmic reticulum (rER) which were concentrated on its sides. Cells were well organized and attached by junctional complexes (Fig 3). Odontoblasts also showed well developed odontoblastic process embedded in the pre-dentin. Numerous secretory granules, occasional multivesicular bodies, multiple mitochondria are present and microfilaments are found in the process. Numerous collagen fibers could be seen in the area of pre-dentin (Fig4).

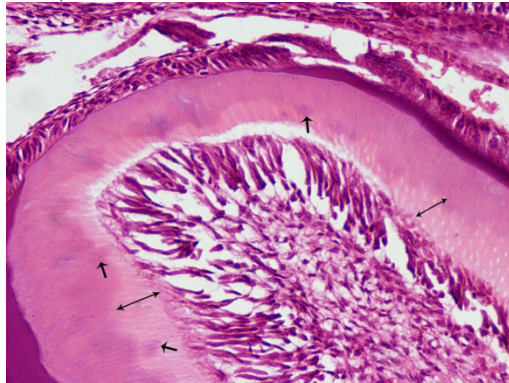
*Study group*

The ultrastructural observations in this group revealed disorganization of the odontoblasts. The nuclei of the odontoblasts appeared heterochromatic. The rough endoplasmic reticulum showed extensively dilated cisternae. Numerous vacuoles presented in the supranuclear cytoplasm and in between the odontoblasts. Few junctional complexes between the odontoblasts were noticed (Fig 5). Odontoblasts also showed less developed odontoblastic process containing less number of mitochondria and secretory vesicles (Fig-6).

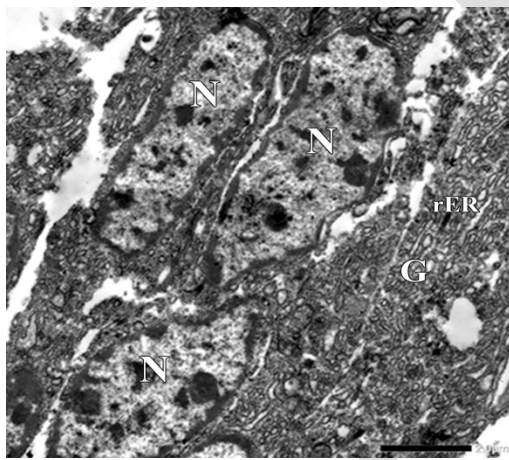





**Figure (1):** LM (control group) showing; the odontoblasts (O) are well differentiated with proximally situated nuclei. The subodontoblastic zone is studded with undifferentiated mesenchymal cells. Regular mineralization front line present between dentin and predentin (arrows). (H&E stain x100)



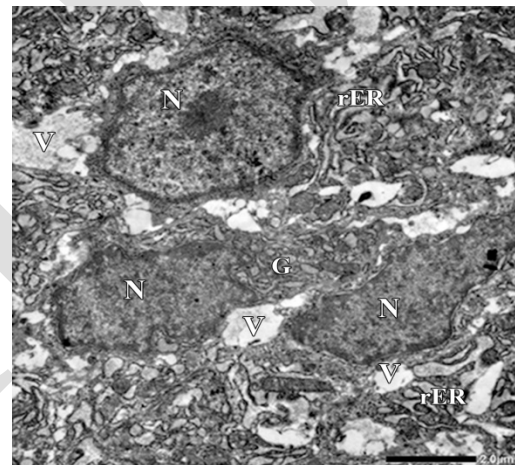
**Figure (2):** LM (study group) showing; the odontoblasts appear disorganized, ill differentiated and poorly arranged in homogenous row. Evident interglobular dentin areas are present in the newly formed dentin (arrows). Irregular mineralization front. Increased predentin thickness (double head arrows). (H&E stain x100)



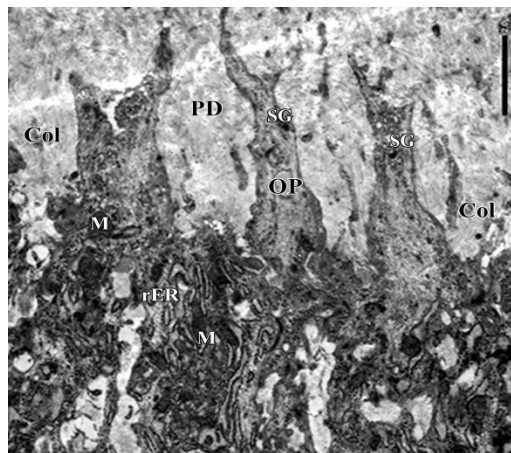
**Figure (3):** TEM (control group) showing the cell body of a secretory odontoblast. The nuclei (N) are euchromatic with a continuous nuclear membrane. The supranuclear cytoplasm contains numerous rough endoplasmic reticulum (rER) and Golgi complex (G), X2500.



**Figure (4):** TEM (control group) showing odontoblastic process (OP) of the newly differentiated odontoblast embedded in the predentin. Numerous secretory granules SG (arrows), occasional multivesicular bodies (mvb), multiple mitochondria are present (M) and microfilaments (MF) arrowhead are found in the process. Numerous collagen fibers could be seen in the area of predentin, X4000.



**Figure (5):** TEM (study group) for cell body of a secretory odontoblast showing ill-differentiated cells with heterochromatic nuclei. The rough endoplasmic reticulum with extensively dilated cisternae (rER) and altered ill formed Golgi complex (G). Numerous vacuoles (V) presented in the supranuclear cytoplasm and in between the odontoblasts, X2500.



**Figure (6):** TEM (study group) showing odontoblastic process (OP) of the newly differentiated odontoblast embedded in the predentin. The odontoblastic process appeared less developed. Few number of secretory granules (SG) and mitochondria (M) and microfilaments (MF) could be observed. Decreased number and thickness of Collagen fibers (Col) could be observed in area of predentin, X4000.

**Table (1):** Showing the mean and standard deviation values of dentin thickness between the control group and study group.

Group	Mean	Std. deviation	P. value
Control group	27.7435	5.209569	<0.004
Study group	18.3828	3.946978	

**Table (2):** Showing the mean and standard deviation values of predentin thickness between the control group and study group.

Group	Mean	Std. deviation	P. value
Control group	11.851	2.128229	<0.0001
Study group	19.2393	2.370188	

## DISCUSSION

Vitamin D3 deficiency became a global health problem since it affects about one billion humans nowadays (23). Many studies used mouse model to reveal the effects of vitamin D3 deficiency on bone and teeth (24-26). Rats have a short gestational period and give rise to numerous pups at once (27). This study was conducted on pregnant rats to investigate how maternal Vitamin D deficiency could affect the dentinogenesis of the offspring. Dentin is not

amenable to remodeling like bone, so it can record all the changes that take place during its formation and mineralization (16).

In this study, the first molar was chosen as a model to study the disturbances that occur during dentinogenesis. This is in accordance with Lungová (28) and de Souza et al., (29) who choose the first rat molars begin their formation by day 13 of intrauterine life, and their mineralization is completed 2 weeks after birth (29).

Contrary to the present choice of rat molars for the study, in other several studies, rat incisors were used as a model. The explanation for their choice of incisor is their rapid and continuous eruption (30-34).

In the present study vitamin D3 deficiency, harmfully affected dentin formation and mineralization caused thinning of dentin, increased thickness of predentin, interglobular dentin and irregular mineralization front. These results are in accordance with D’Ortenzio L et.al and Descroix V et al., who studied also the effect of vitamin D3 deficiency on dentinogenesis (24, 35).

The impairment of dentin formation and mineralization could be secondary to systemic effects of vitamin D3 causing hypocalcemia and hypophosphatemia. Dentin hypomineralization could be also related to the local effects of vitamin D3 on odontoblasts yielding decreased expression of calcium binding proteins (calbindins) and osteocalcin as previously described by Berdal et al., (36).

In the study group, interglobular dentin was formed when mineralization processes have slowed down or stopped resulting in calcospherites that do not fully coalesce, leaving identifiable spaces in dentin; this is in accordance with D’Ortenzio L who used the interglobular dentin as an archeological record of vitamin D3 deficiency (16).

Regarding the ultrastructure results, vitamin D3 deficiency affected the odontoblast differentiation rendering them with heterochromatic nuclei. The odontoblast is a target cell for vitamin D3 metabolites (36). Vitamin D3 receptor (VDR) is highly expressed in the dental papilla cells during the early stages of tooth development resulting in expression of genes associated with odontoblastic differentiation, such as dentinsialophosphoprotein (DSPP) and dentin matrix protein-1 (DMP1) and increase the alkaline phosphatase (ALP) activity (37).

In the ultrastructure results of the deficiency group, odontoblasts showed dilated cisternae of rough endoplasmic reticulum with impaired predentin formation as the collagen was thin, ill formed with increased ground substance formation. The odontogenesis on the ultrastructural level was few, Sakamoto et al., (38) studied the effect of ascorbic acid deficiency using the transmission electron microscope and concluded that the dilated rER may be due to the accumulation of misfolded dentin matrix proteins within rER leading to disturbance of the secretory pathway with the formation of thin ill formed collagen fibers and profuse ground substances.

Limited to our knowledge, the deficiency of vitamin D could impair the dentin formation, mineralization and structural organization of the odontoblasts.

## CONCLUSION

The findings of this study provide evidence that vitamin D3 deficiency impaired dentin formation and maturation as well as the differentiation of odontoblasts.

### Conflict of interest

-The authors declare that they have no conflicts of interests.

-The authors received no specific funding for this work.

## REFERENCES

- Martens PJ, Gysemans C, Verstuyf A, Mathieu AC. Vitamin D's Effect on Immune Function. *Nutrients*. 2020;12:1248.
- Saponaro F, Saba A, Zucchi R. An Update on Vitamin D Metabolism. *Int J Mol Sci*. 2020;21:6573.
- Foo LH, Zhang Q, Zhu K, Ma G, Hu X, Greenfield H, Fraser DR. Low vitamin D status has an adverse influence on bone mass, bone turnover, and muscle strength in Chinese adolescent girls. *J Nutr*. 2009;139:1002-7.
- Lehmann B, Meurer M. Vitamin D metabolism. *Dermatol Ther*. 2010;23:2-12.
- Ross AC, Manson JE, Abrams SA, Aloia JF, Brannon PM, Clinton SK, et al. The 2011 report on dietary reference intakes for calcium and vitamin D from the Institute of Medicine: what clinicians need to know. *J Clin Endocrinol Metab*. 2011;96:53-8.
- Carpagnano GE, Di Lecce V, Quaranta VN, Zito A, Buonamico E, Capozza E, et al. Vitamin D deficiency as a predictor of poor prognosis in patients with acute respiratory failure due to COVID-19. *J Endocrinol Invest*. 2021;44:765-71.
- Botelho J, Machado V, Proença L, Delgado AS, Mendes JJ. Vitamin D Deficiency and Oral Health: A Comprehensive Review. *Nutrients*. 2020;12:1471.
- Ramasamy I. Vitamin D Metabolism and Guidelines for Vitamin D Supplementation. *Clin Biochem Rev*. 2020;41:103-26.
- Ruiz-Ballesteros AI, Meza-Meza MR, Vizmanos-Lamotte B, Parra-Rojas I, de la Cruz-Mosso U. Association of Vitamin D Metabolism Gene Polymorphisms with Autoimmunity: Evidence in Population Genetic Studies. *Int J Mol Sci*. 2020;21:9626.
- Lockau L, Atkinson SA. Vitamin D's role in health and disease: How does the present inform our understanding of the past? *Int J Paleopathol*. 2018;23:6-14.
- Hyde NK, Brennan-Olsen SL, Bennett K, Moloney DJ, Pasco JA. Maternal Nutrition During Pregnancy: Intake of Nutrients Important for Bone Health. *Matern Child Health J*. 2017;21:845-51.
- Amr N, Hamid A, Sheta M, Elsedfy H. Vitamin D status in healthy Egyptian adolescent girls. *Georgian Med News*. 2012;:65-71.
- El Rifai NM, Abdel Moety GA, Gaafar HM, Hamed DA. Vitamin D deficiency in Egyptian mothers and their neonates and possible related factors. *J Matern Fetal Neonatal Med*. 2014;27:1064-8.
- Brouzes CMC, Darcel N, Tomé D, Dao MC, Bourdet-Sicard R, Holmes BA, et al. Urban Egyptian Women Aged 19-30 Years Display Nutrition Transition-Like Dietary Patterns, with High Energy and Sodium Intakes, and Insufficient Iron, Vitamin D, and Folate Intakes. *Curr Dev Nutr*. 2020;4:nzz143.
- Foster BL, Hujoel PP. Vitamin D in dentoalveolar and oral health. In: Feldman D, Pike JW, Bouillon R (eds). *Vitamin D*. 4<sup>th</sup> ed. London, United Kingdom : Academic Press; 2018:497-519.
- D'Ortenzio L. Tooth tales: what internal dental structures reveal about vitamin d deficiency and age estimation. Ph.D. Thesis. Anthropology Department. McMaster University, Canada. 2018.
- Zhang X. Vitamin D Receptor Deficiency and Postnatal Tooth Formation. M.S.c. Thesis. Department of Prosthodontics.



- Faculty of University of Alabama, Birmingham, Alabama. 2007.
18. Landry GJ, Opiol H, Marchant EG, Pavlovski I, Mear RJ, Hamson DK, et al. Scheduled daily mating induces circadian anticipatory activity rhythms in the male rat. *PLoS One*. 2012;7:e40895.
  19. El-Zainy MA, El-Haddad KN, Obeid RF. Efficacy of transforming growth factor- $\beta$  on development of ameloblasts and odontoblasts in tooth germ of young albino rat. *Futur Dent J*. 2017;3:39-46.
  20. Kumar G, [Orban](#) BJ. *Orban's oral histology and embryology*: New Delhi : Elsevier; 2015.
  21. Pease DC. *Histological techniques for electron microscopy*. 2<sup>nd</sup> ed. Amsterdam : Academic Press; 2013.
  22. Mostafa HM, Shehata FI, Omar SO, Kawana KY. The effect of amoxicillin on the secretory stage of amelogenesis in rats. *ADJ*. 2020;45:34-8.
  23. Holick MF. Vitamin D deficiency. *N Engl J Med*. 2007;357:266-81.
  24. Descroix V, Kato S, Lézet F, Bernal A. Physiopathology of dental rickets in vitamin D receptor-ablated mice. *J Dent Res*. 2010;89:1427-32.
  25. Zhang X, Rahemtulla FG, MacDougall MJ, Thomas HF. Vitamin D receptor deficiency affects dentin maturation in mice. *Arch Oral Biol*. 2007;52:1172-9.
  26. Zhang X, Rahemtulla F, Zhang P, Beck P, Thomas HF. Different enamel and dentin mineralization observed in VDR deficient mouse model. *Arch Oral Biol*. 2009;54:299-305.
  27. Ankeny RA, Leonelli S. What's so special about model organisms? *Stud Hist Philos Sci A*. 2011;42:313-23.
  28. Lungová V, Radlanski RJ, Tucker AS, Renz H, Míšek I, Matalová E. Tooth-bone morphogenesis during postnatal stages of mouse first molar development. *J Anat*. 2011;218:699-716.
  29. de Souza JF, Gramasco M, Jeremias F, Santos-Pinto L, Giovanini AF, Cerri PS, et al. Amoxicillin diminishes the thickness of the enamel matrix that is deposited during the secretory stage in rats. *Int J Paediatr Dent*. 2016;26:199-210.
  30. Hata M, Kawamoto T, Kawai M, Yamamoto T. Differential expression patterns of the tight junction-associated proteins occludin and claudins in secretory and mature ameloblasts in mouse incisor. *Med Mol Morphol*. 2010;43:102-6.
  31. Lacruz RS, Smith CE, Kurtz I, Hubbard MJ, Paine ML. New paradigms on the transport functions of maturation-stage ameloblasts. *J Dent Res*. 2013;92:122-9.
  32. Okumura R, Shibukawa Y, Muramatsu T, Hashimoto S, Nakagawa K, Tazaki M, Shimono M. Sodium-calcium exchangers in rat ameloblasts. *J Pharmacol Sci*. 2010;112:223-30.
  33. Kumazawa K, Sawada T, Yanagisawa T, Shintani S. Effect of single-dose amoxicillin on rat incisor odontogenesis: a morphological study. *Clin Oral Investig*. 2012;16:835-42.
  34. Houari S, Liodice S, Jedeon K, Bernal A, Babajko S. Expression of Steroid Receptors in Ameloblasts during Amelogenesis in Rat Incisors. *Front Physiol*. 2016;7:503.
  35. D'Ortenzio L, Ribot I, Kahlon B, Bertrand B, Bocaege E, Raguin E, et al. The rachitic tooth: The use of radiographs as a screening technique. *Int J Paleopathol*. 2018;23:32-42.
  36. Bernal A, Papagerakis P, Hotton D, Bailleul-Forestier I, Davideau JL. Ameloblasts and odontoblasts, target-cells for 1,25-dihydroxyvitamin D<sub>3</sub>: a review. *Int J Dev Biol*. 1995;39:257-62.
  37. Woo SM, Lim HS, Jeong KY, Kim SM, Kim WJ, Jung JY. Vitamin D Promotes Odontogenic Differentiation of Human Dental Pulp Cells via ERK Activation. *Mol Cells*. 2015;38:604-9.
  38. Sakamoto Y, Takano Y. Site-specific effect of ascorbic acid deficiency on the structure and function of odontoblasts in the teeth of osteogenic disorder rat in vivo. *Tissue Cell*. 2005;37:11-23.