

Role of Sonoelastography versus Magnetic Resonance Imaging in Patellar Tendon Lesions

Nadia Talaat Abdelhai Mahmoud*, Manal Farouk Altohamy,
Farida Mohamed Elfawal, Ahmed Mohamed Alsowey

Department of Radiodiagnosis, Faculty of Medicine, Zagazig University, Egypt
*Corresponding author: Nadia Talaat Abdelhai Mahmoud, Mobile: (+20)01149567273,
E-Mail: mahmoudbadawy526@gmail.com

ABSTRACT

Background: Sonoelastography is a growing tool in evaluation of tendon pathologies. Due to its superficial position, patellar tendon pathology can be well evaluated by superficial ultrasound (US) and sonoelastography. Evaluation of tendon pathology is best done with magnetic resonance imaging.

Objective: To evaluation of the accuracy of sonoelastography compared to MRI in patellar tendon lesions.

Patients and methods: Forty eight patients (25 males, 23 females) with patellar tendon lesion were referred from the Department of Orthopedic Surgery and Rheumatology Outpatient Clinics. The patient's mean age was 42.85 (ranged from 12 to 68) years. All patients were evaluated by US, sonoelastography and MRI.

Results: The mean modulus of elasticity of the patellar tendon in this study was 114.4 kPa ranging from 70-186 kPa. There were three cases that were wrongly diagnosed as patellar tendon lesion by US and sonoelastography but they showed no abnormality in MRI [no tendon thickening or signal intensity changes]. The percentage of true positive cases was 93.8% compared to 6.2% false positive cases.

Conclusion: When compared to magnetic resonance imaging (MRI), shear-wave elastography provides adequate accuracy (93.8%) when measuring patellar tendon stiffness.

Keywords: MRI, Patellar tendon, Sonoelastography

INTRODUCTION

It has been established that degenerative and structural changes within a tendon can be detected using ultrasonography. Sonoelastography is a growing tool for evaluation of different patellar tendon lesions such as patellar tendinopathy, stiffness after knee surgery, healing of repaired patellar tendon rupture and patellar tendon tumours and distinguishing between benign and malignant types⁽¹⁻³⁾.

Shear-wave elastography is a color image analysis technique that uses ultrasound to determine tissue viscoelasticity. This color-coded images has wide color scale from red (represents stiff tissues) to blue (represents soft tissues). According to **De Zordo et al.**⁽⁴⁾, the patellar tendon is considered elastic and healthy if it appears "blue and/or green" while if it is "yellow and/or red", this indicates a diseased tendon.

Patellar tendinopathy, also known as "jumper's knee", is a frequent overuse illness that affects players who are engaged in jumping sports such as volleyball and basketball⁽⁵⁾. Because of its high resolution, high sensitivity, and high soft-tissue contrast, MRI is the imaging modality of choice for diagnosing patellar tendon disorders⁽⁶⁾.

The aim of the present study was to evaluation of the accuracy of sonoelastography compared to MRI in patellar tendon lesions.

PATIENTS AND METHODS

Between May 2021 and April 2022, at the Radiodiagnosis Department at Zagazig University Hospital, we carried out this prospective study. Forty eight patients (25 males, 23 females) with patellar tendon lesion were referred from the Department of

Orthopedic Surgery and Rheumatology Outpatient Clinics.

Inclusion criteria:

- Male or female patients suspected for patellar tendon lesion complaining of localized pain, tenderness and swelling below the knee cap with limitation of knee motion.
- Closed patellar tendon tear.
- Patellar tendon contracture after different knee surgeries.
- Insertional tendinitis as Osgood Schlatter disease

Exclusion criteria:

- Acute open patellar tendon tear.
- Patients with severe pain in the examined area during the examination session.
- Patients unfit for MRI.

Imaging technique:

A. Cannon (Aplio 500, China) machine superficial linear high frequency transducer ultrasonography examination (7-10 MHZ) was used. The flexed knee supine posture was used for all examinations (about 30°). A rolled towel was placed behind the knee for support. Each patient had a longitudinal ultrasound scan of their injured patellar tendon. The linear transducer was positioned distal to the patella along the lone axis. Patellar tendon thickness was measured at three distinct points: near its origin, in the centre, and further from it. At the first hyperechoic zone between the subcutaneous tissue and the deep fascia layer, tendon boundaries were defined inferiorly.

B. Shear wave elastography (SWE): Patients were examined while lying supine, with the examination table's back raised to an angle of 60 degrees for

maximum relaxation of the patellar tendon. The afflicted knee was flexed at a 30° angle during SWE.

SWE was conducted using a gentle amount of pressure, in the longitudinal plane, with the inferior patellar pole just within the field of vision. Dual-screen mode was used to construct elastograms, which showed both GSUS and the elastogram superimposed on top of each other. We worked our way along the patellar tendon, first from its proximal end to its midpoint, and then its distal end.

C. MRIs were taken with a Philips Achieva 1.5 T scanner or a GE Signa 1.5 T scanner at Zagazig University Hospitals or at independent imaging centres, using a knee coil.

Positioning:

Each patient was positioned supine with their knees bent at a 90-degree angle. No motion was allowed during the procedure.

Protocol:

All patients had a multi-planar magnetic resonance imaging (MRI) scan of their injured knee performed, with different sequences (T1, T2, STIR, proton density, and fat suppression) applied to each plane:

- T1 weighted image: with repetition time *500-600* msec, Echo time*20-25* msec.
- T2 weighted image: with repetition time *3000-4000* msec, Echo time*15-17*msec.
- Proton density image: The repetition time= 1000 msec, Echo time=10-30 msec.
- STIR image: The repetition time= 5000 msec, Echo time=30 msec.
- Fat suppression T2 weighted image: The repetition time= 3500- 3600 msec, Echo time=90-100 msec.
- Fat suppression proton density image: The repetition time= 2000- 2500 msec, Echo time=40-50 msec.
- Other settings included a slice thickness between 3 and 5 mm, a matrix of 256/192 or 512/224, a range of 2 to 3 excitations, and a field of view between 12 and 16 cm (ideally confined to lower than 14 cm).

Images interpretation:

Ultrasound, elastography, and MRI scans were analyzed for abnormalities including:

- Lesion site.
- Lesion type: patellar tendinopathy, Osgood Schlatter syndrome, patellar tendon abnormality after previous surgery and knee stiffness.
- Results from ultrasonography and elastography were compared with those from MRI.

Ethical consent:

An approval of the study was obtained from Zagazig University Academic and Ethical Committee. Every patient or caregiver of a child

patient signed an informed written consent for acceptance of participation in the study. This work has been carried out in accordance with The Code of Ethics of the World Medical Association (Declaration of Helsinki) for studies involving humans.

Statistical analysis

In order to analyze the data acquired, Statistical Package for the Social Sciences version 20 was used to execute it on a computer (SPSS). The quantitative data were presented in the form of the mean, median, standard deviation, and range. The qualitative data were presented as frequency and percentage. The significance of a P value of 0.05 or less was determined.

RESULTS

The patient’s mean age was 42.85 (ranged from 12 to 68) years. There were 24 patients with left-sided patellar tendon lesion and also 24 patients with right-sided lesion. In this study; patellar tendinopathy was the most frequent diagnosed disease in 35 cases (72.9%) [Table 1].

Table (1): Basic characteristic of the studied patients

Basic characteristics	The studied patients (N=48)	
	No.	%
Sex		
Male	25	52.1%
Female	23	47.9%
Age (years)		
Mean ±SD	42.85±20.47	
Median (Range)	42.50 (12 – 68)	
Age group (years)		
10-<20	12	25%
20- <30	8	16.66%
30-<40	6	12.5%
40-<50	0	0
50-<60	5	10.41%
60-<70	17	35.41%
Side		
Right	24	50%
Left	24	50%

The mean modulus of elasticity of the patellar tendon in this study was 114.4 kPa ranging from 70-186 kPa. In this study there was no statistically significant difference between male and female patellar tendon modulus of elasticity. There was statistically significant decrease of the modulus of elasticity of patellar tendon in 10-<20 years age group compared to other age groups with patellar tendon pathology [Table 2]. There were three cases that were wrongly diagnosed as patellar tendon lesion by US and sonoelastography but they showed no abnormality in MRI [no tendon thickening or signal intensity changes]. The percentage of true positive cases was 93.8% compared to 6.2% false positive cases.

Table (2): Relationship between basic characteristics and elasticity modulus (kPa)

Basic characteristics	N	Elasticity modulus (kPa)				Test	p-value
		Mean	±SD	Median	(Range)		
Sex							
Female	23	109.20	±23.26	110	(70 – 155)	-1.291^b	0.197
Male	25	120.08	±28.36	123	(74 – 186)		
Age group (years)							
10-<20	12	78.81	±5.94	80	(70 – 87)	25.125^c	<0.001
20-<30	8	126.60	±20.19	129.50	(93 – 186)		
30-<40	6	124.60	±20.14	129.50	(93 – 186)		
50-<60	5	128.60	±20.09	129.50	(93 – 186)		
60-<70	17	123.11	±19.13	120	(96 – 159)		
Side							
Right	24	113.75	±26.61	113.50	(74 – 186)	-0.464^b	0.642
Left	24	115.08	±26.21	121.50	(70 – 159)		
Disease							
Tendinopathy	35	123.22	±21.31	123	(80 – 186)	23.113^c	<0.001
Knee stiffness	5	82	±4.69	83	(75 – 87)		
Osgood Schlatter	5	75.40	±6.22	74	(70 – 86)		
Previous knee surgery	3	130.66	±5.13	132	(125 – 135)		

b: Mann Whitney U test; c: Kruskal Wallis H test

Figure 1 shows the US, shear wave sonoelastography, and MRI of the right proximal patellar tendon of one patient.

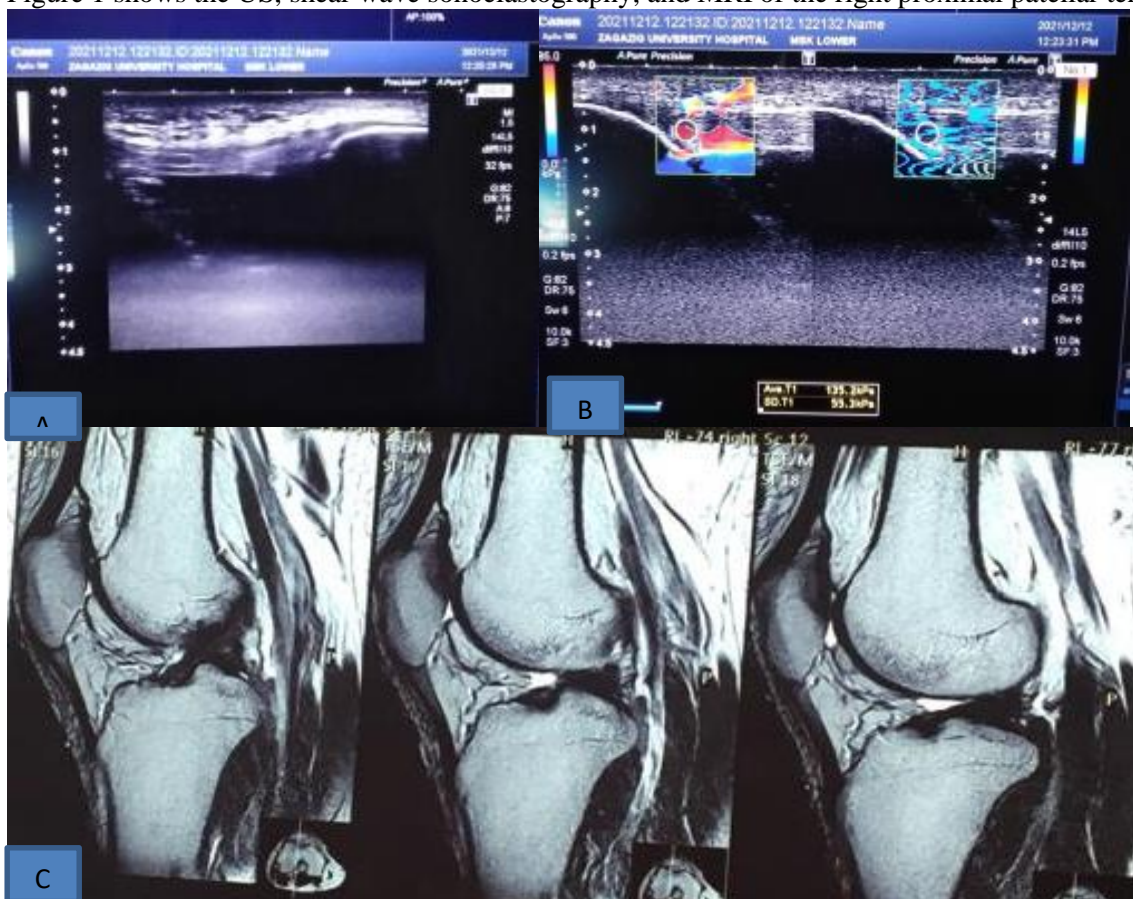


Fig. (1): 30 years old male patient presented with anterior right knee pain. A: US scan shows thickened proximal patellar tendon with loss of its fibrillar appearance with hypoechoic areas. B: Shear wave sonoelastography shows mixed red (stiff) and yellow areas (intermediate stiffness) in the proximal tendon, and the modulus of elasticity was 135.2 kPa. C: Magnetic resonance imaging shows focal thickening with high signal intensity of the proximal tendon.

Figure 2 shows the US, shear wave sonoelastography, and MRI of the left patellar tendon of another patient.

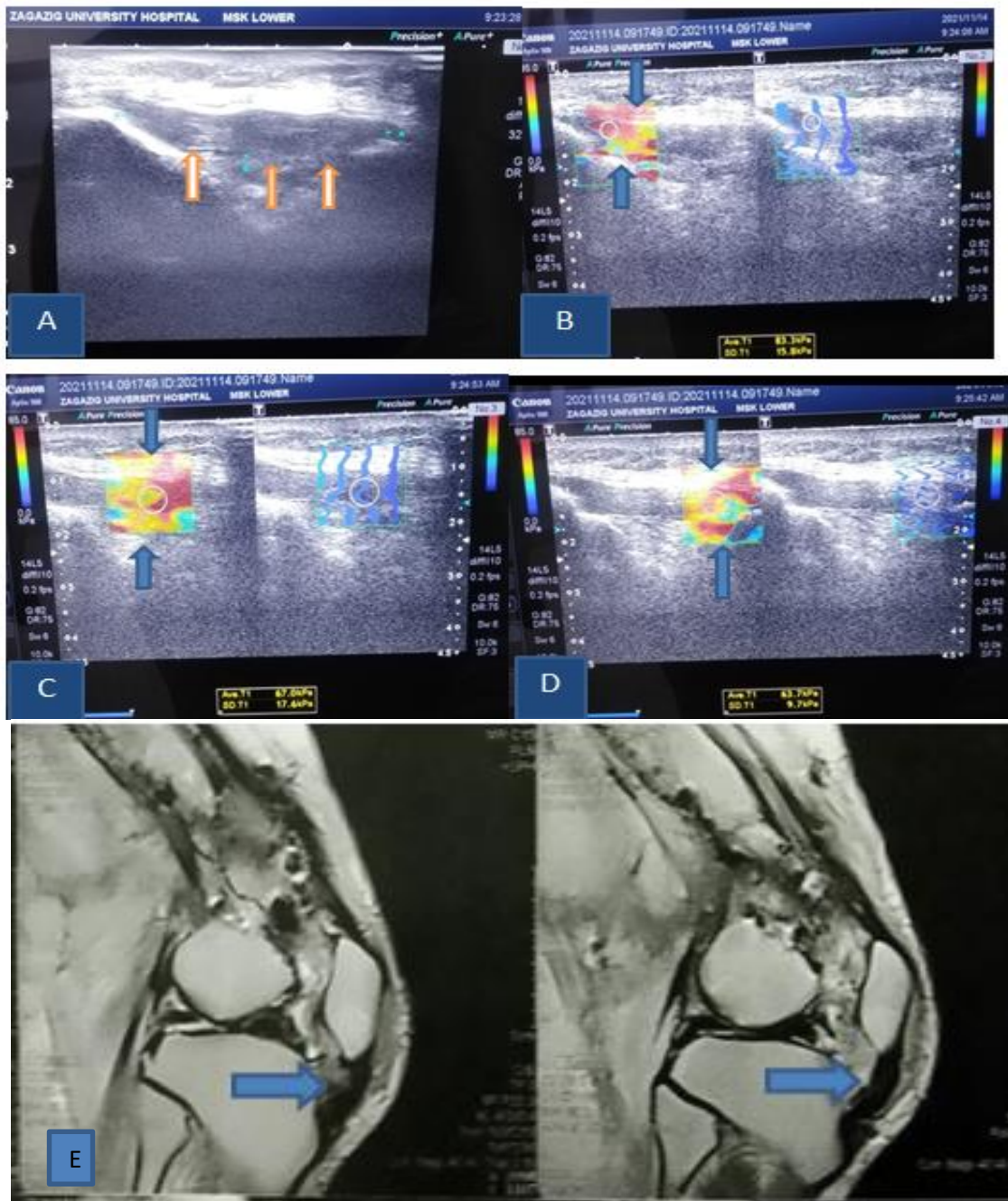


Fig. (2): A 14 years old female cerebral palsy patient presented with fixed left knee deformity with knee pain. A: Longitudinal US scan of the left patellar tendon showed diffuse thickening of the whole patellar tendon with loss of its fibrillar appearance with hypoechoic areas. B, C, D: Shear wave sonoelastography of the left patellar tendon showed that the whole tendon had mixed red (stiff) and yellow areas (intermediate stiffness). E: MRI (PD) showed diffuse thickening of the patellar tendon.

DISCUSSION

Due to its superficial position, patellar tendon can be easily and accurately assessed by ultrasound and sonoelastography. The combination of traditional ultrasound and sonoelastography offers several benefits over magnetic resonance imaging (MRI), including reduced cost and increased speed. Moreover, dynamic evaluation of muscle and tendon can be easily obtained, as well as rapid assessment of the contralateral side for comparison⁽¹⁾. Studies of patellar tendon elasticity have typically involved subjects lying supine with their knees

in various positions (from full extension to 90 degrees of flexion)⁽⁷⁻⁹⁾.

Different knee angles generate different passive forces on the patellar tendon. Patellar tendon stiffness differs with different knee joint angles with the maximum at 90° and the minimum when the knee is fully extended. Changing the position from full knee extension to 60 degree flexion increases the median shear-wave speed by 9.2 percent, and it increases by 5.1 percent when knee flexion is increased from 30 to 60 degrees. The median shear-wave speed did not

significantly increased after changing from 0 to 30 degrees knee flexion. These results imply that shear-wave velocity are relatively unaffected up to a knee flexion angle of 30 degrees ⁽⁹⁾. In this study, we performed sonoelastography with the knee angle at 30° flexion.

Different studies on patellar tendinopathy show different patellar tendon's modulus of elasticity. Both elevated ^(10,11) and reduced modulus of elasticity ^(9,12). **Breda et al.**⁽¹³⁾ reported in their study evaluating the stiffness of the patellar tendon that athletes with patellar tendinopathy had a considerably higher modulus of elasticity (median 74.9 kPa) than asymptomatic athletes (median 35.6 kPa). Also, they found that, the side of the lesion had no statistically significant effect on the modulus of elasticity of the patellar tendon. The median modulus of elasticity in the present study was 117.5 kPa, and the lesion side had no statistically significant effect on the modulus of elasticity.

Malliaras and Cook⁽¹⁴⁾ noted that normal tendon morphology on US were commonly present in symptomatic patellar tendons, and also abnormal tendon morphology on US were commonly present in asymptomatic patellar tendons. Subsequent cross-sectional studies had confirmed their results ⁽¹⁵⁾. The low sensitivity of the US system to detect tendon pathology was cited as a possible explanation for these data.

We studied the accuracy of sonoelastography compared to MRI in the diagnosis of different patellar tendon lesion and it was found that the accuracy of sonoelastography was 93.8% with three false positive cases. In these cases MRI showed no focal thickening or signal intensity changes, although in sonoelastography, the modulus of elasticity was high.

Limitations of this study:

There are several limitations in this study; first the small sample size. Second, both the sonography and the sonoelastography were done by the same operator. The third, the present study did not assess the intra- and inter-operator reliability of sonoelastography.

CONCLUSION

The use of shear-wave elastography to evaluate tendon stiffness has been proved to be promising and reliable. When compared to magnetic resonance imaging, sonoelastography has 93.8% accuracy.

Conflict of interest: The authors declare no conflict of interest.

Sources of funding: This research did not receive any specific grant from funding agencies in the public, commercial, or not-for-profit sectors.

Author contribution: Authors contributed equally in the study.

REFERENCES

1. **Magarelli N, Carducci C, Bucalo C et al. (2014):** Sonoelastography for qualitative and quantitative evaluation of superficial soft tissue lesions: a feasibility study. *Eur Radiol.*, 24: 566-573.
2. **Fusini F, Langella F, Busilacchi A et al. (2017):** Real-time sonoelastography: Principles and clinical applications in tendon disorders. A systematic review. *Muscles, Ligaments and Tendons Journal*, (3):467-477.
3. **Cushman D, Petrin Z, Eby S et al. (2020):** Ultrasound evaluation of the patellar tendon and Achilles tendon and its association with future pain in distance runners. *The Physician and Sportsmedicine*, 26:1-10.
4. **De Zordo T, Chhem R, Smekal V (2010):** Real-time sonoelastography: findings in patients with symptomatic Achilles tendons and comparison to healthy volunteers. *Ultraschall Med.*, 31: 394–400.
5. **DePalma M, Perkins R (2004):** Patellar tendinosis: Acute patellar tendon rupture and jumper's knee. *Phys Sportsmed.*, 32(5):41-45.
6. **Bahr R, Fossan B, Løken S et al. (2006):** Surgical treatment compared with eccentric training for patellar tendinopathy (Jumper's knee). A randomized, controlled trial. *J Bone Joint Surg Am.*, 88(8):1689–1698.
7. **Hsiao M, Chen Y, Lin C et al. (2015):** Reduced patellar tendon elasticity with aging: In vivo assessment by shear wave elastography. *Ultrasound Med Biol.*, 41(11):2899–905.
8. **Porta F, Damjanov N, Galluccio F et al. (2014):** Ultrasound elastography is a reproducible and feasible tool for the evaluation of the patellar tendon in healthy subjects. *International Journal of Rheumatic Diseases*, 17: 762–766.
9. **Dirrachs T, Quack V, Gatz M et al. (2015):** Shear wave elastography (SWE) for the evaluation of patients with tendinopathies. *Acad Radiol.*, 23:1204–1213.
10. **Zhang Z, Ng G, Lee W et al. (2014):** Changes in morphological and elastic properties of patellar tendon in athletes with unilateral patellar tendinopathy and their relationships with pain and functional disability. *PLoS One*, 9(10):e108337.
11. **Coombes B, Tucker K, Vicenzino B (2018):** Achilles and patellar tendinopathy display opposite changes in elastic properties: a shear wave elastography study. *Scand J Med Sci Sports*, 28:1201–1208
12. **Ooi C, Richards P, Maffulli N (2016):** A soft patellar tendon on ultrasound elastography is associated with pain and functional deficit in volleyball players. *J Sci Med Sport*, 19:373–378.
13. **Breda J, van der Vlist A, de Vos R et al. (2020):** The association between patellar tendon stiffness measured with shear-wave elastography and patellar tendinopathy—a case-control study. *Eur Radiol.*, 30:5942–5951.
14. **Malliaras P, Cook J (2006):** Patellar tendons with normal imaging and pain: change in imaging and pain status over a volleyball season. *Clin J Sport Med.*, 16(5):388-391.
15. **Warden S, Kiss Z, Malara F et al. (2007):** Comparative accuracy of magnetic resonance imaging and ultrasonography in confirming clinically diagnosed patellar tendinopathy. *Am J Sports Med.*, 35(3):427-436.