

## Transoral Submandibular Sialoadenectomy Feasibility and Case Selection

Ehab M. Oraby, Mohammad I. Aburezk , Mokhtar A. Bahbah

General Surgery Department,  
Benha Faculty of Medicine,  
Benha University, Egypt.

**Corresponding to:** Dr. Ehab  
Mahroos Oraby, General  
Surgery Department, Benha  
Faculty of Medicine, Benha  
University, Egypt.

**Email:**

ehab.arabi@fmed.bu.edu.eg

**Received:** 27 May 2022

**Accepted:** 25 July 2022

**Abstract:**

The last century gave birth to the concept of minimal invasive surgery and the scarless operations. The transoral approach targeted mainly the concept of scarless surgery, in addition, to keeping the marginal mandibular nerve safe. The transoral approach faces many limitations as pathology type, lump size, lump mobility, and enough workspace.

**Patients and methods:** This prospective study was carried out on 20 consecutive patients. All of them were presented with submandibular salivary gland swelling. All swellings included should be mobile, 2 cm or less, and the patient showed a positive 3-fingers test.

**Results:** In this study, 13 patients showed evidence of calculi submandibular sialadenitis, 4 patients with non calculi submandibular sialadenitis, and 3 patients with pleomorphic adenoma. All cases were presented with small mobile gland. The mean lump size was 16.4 mm (12-20 mm). All patients passed the 3-finger test to evaluate maximal mouth opening. Two patients developed wound infection and showed delayed wound healing. Five cases developed abnormal tongue tip sensation. No patients developed limitations in tongue movement.

**Conclusion:** In selected cases, the transoral approach can be a good alternative, especially for those patients who are strongly appreciating scarless operations as young age females.

**Keywords:** Scarless surgery, Transoral Sialoadenectomy, Submandibular Salivary Gland.

---

**Introduction:**

Over the last century, a big shift has happened in the surgeons' orientation and patients' concern. Surgeons are paying every effort to achieve the most effective, less invasive, and more cosmetic procedures. On the other hand, patients raised their attention toward the aesthetic aspect of each procedure. These interactions gave birth to the concept of minimal invasive surgery and the scarless operations (1,2).

In 1954, a dental surgeon during his work to reconstruct cases of alveolar atrophy, noted the possibility to excise the submandibular gland through the oral cavity after he cut the mylohyoid border. This technique was reported in 1960 (3). Since that time, the proposed technique started to gain some popularity after other surgeons' report published in 2008 (4).

Many procedures were described for submandibular sialoadenectomy. The standard technique is still the transcervical conventional sialoadenectomy. This conventional approach offers the direct access with cumulated experience and low incidence of complications (5,6). The most prominent negative point in this technique is its scar which lies in a very exposed area and is going to be not accepted anymore by cosmetically oriented patients (1,6).

Although neurological insult after this approach is low especially with experienced hands, but still happening especially the injury to marginal mandibular nerve. Also, remnant of submandibular duct may induce repeated intraoral infection or cysts (4,7).

In this context, surgeons tried to modify and/or find alternatives. Some procedures targeted to hide the scar through facelift postauricular incision (6,7). Others tried to make smaller wounds by the aid of endoscopic and even robotic instruments (1,6,8). This era refreshed the idea of transoral approach. Even in the transoral approach, many variations developed. Either by regular instruments or through endoscopic or robotic instruments (4,8,9).

The transoral approach targeted mainly the concept of scarless surgery in addition to keep the marginal mandibular nerve safe. On the other hand, this approach is giving a very high incidence of lingual nerve affection but fortunately, temporary affection. Also, it has some drawbacks with wound healing and tongue movements (3,5).

Many limitations are facing the transoral approach. These limitations are pathology type (6), lump size (9), lump mobility (5), and enough workspace. This workspace is much affected by factors such as tongue

size, maximal mouth opening, and presence of molar teeth (3,4,10,11).

---

## Patients and Methods:

This prospective study was conducted at Department of General Surgery, Benha University Hospital after obtaining approval from local ethical committee and after fully informed written consent signed by patient. This study carried out on 20 consecutive patients. All of them presented with submandibular salivary swelling, from January 2018 to October 2021.

### Inclusion Criteria:

Swelling should be mobile and not fixed. Its diameter is 2 cm or less by ultrasound assessment. Maximal mouth opening can admit the three middle fingers of the patient hand (3 finger test). Inflammatory or benign pathology confirmed by preoperative ultrasound guided FNAC.

### Exclusion Criteria:

Swelling size more than 2 cm, fixed swelling, repeated attacks of sialadenitis, malignant lesions, big tongue, maximal mouth opening not admitting three fingers.

### Operative Technique:

All patients were advised to have povidone iodine mouth wash in the day before operation. Under general anesthesia, trans-nasal endotracheal tube, patient lies in supine position with shoulder elevation and head stabilized by ring cushions. Mouth irrigation with saline and wash with

povidone iodine. ordinary surgical instruments were used for mouth opening and tongue retraction to the opposite side. Two assistants were required to keep the field exposed.

Local injection of lidocaine and diluted epinephrine 1/80,000 in the submucosal plane (Fig.1). Dexamethasone ampoule was injected parenterally prior to dissection around nerves in oral floor. Incision of mucosa from papillary caruncle to reach opposite the retromolar area, 1-2 cm medial to mandibular border (Fig.2). Elevation of medial and lateral flaps to expose the sublingual gland. Blunt dissection of sublingual gland from its anterior end backwards. Excision of sublingual gland to evacuate the sublingual triangle except for submandibular duct and lingual nerve. Both structures are running over mylohyoid muscle.

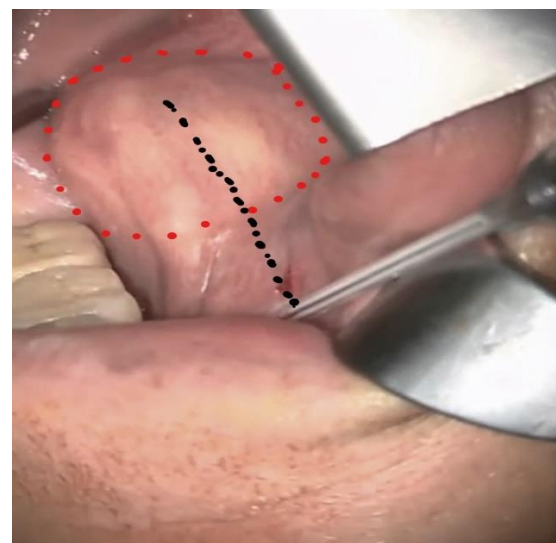


Fig (1): Submucosal injection of Local Anesthetic with Adrenaline.

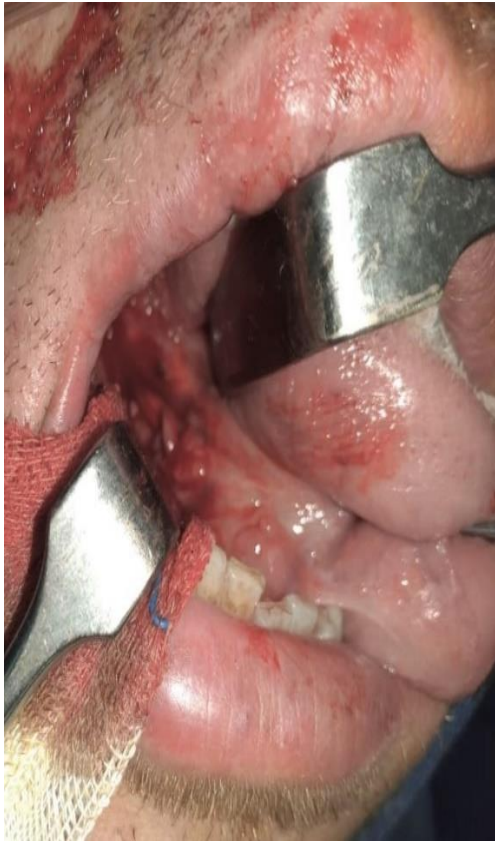

Fig (2): Starting the Mucosal Incision.

Handling of submandibular duct starts by mobilizing its orifice and then distal to proximal dissection (Fig.3). Then uncrossing the duct from lingual nerve (Fig.4) to put the duct laterally while the nerve is maintained medially toward the tongue to avoid undue stretching during the following steps. Further dissection of the lingual nerve from its ganglion was done to make it free.

Gentle upward traction of duct synchronous with extraoral upward pushing through submandibular area to facilitate gland exposure and delivery into oral cavity. Freeing the deep lobe from mylohyoid muscle then anterior retraction

of muscle border. The last step brings the swelling more toward operative field. Meticulous bit by bit dissection around the posterior pole of the gland where we suspect to deal with facial vessels. Bipolar diathermy was the main hemostatic instrument, sometimes required ligation. Further blunt dissection with judicious bipolar cauterization to completely extract the gland. Inspection for hemostasis and then wound irrigation. Hypoglossal nerve appears deep in the wound bed after gland removal. Closure of mucosa with loose stitches. External (extraoral) compression packs over the submandibular area.

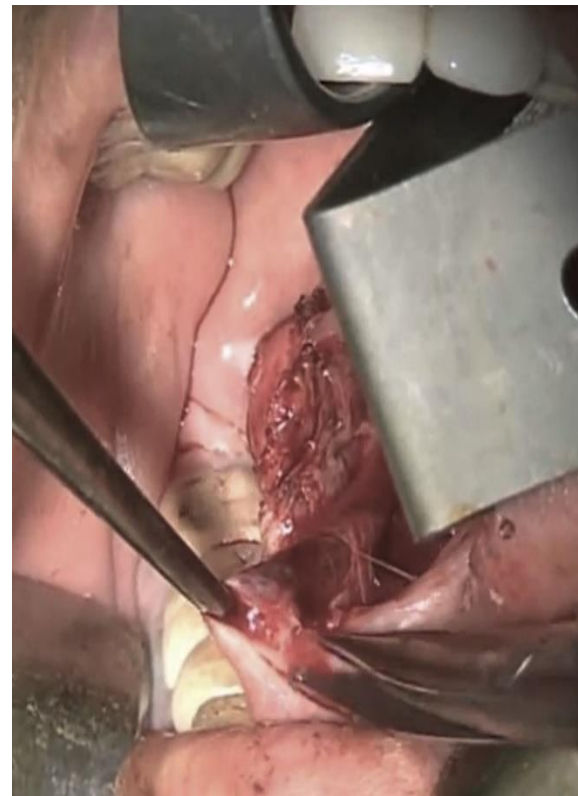

Fig (3): Submandibular Duct Dissection, distal to proximal approach.

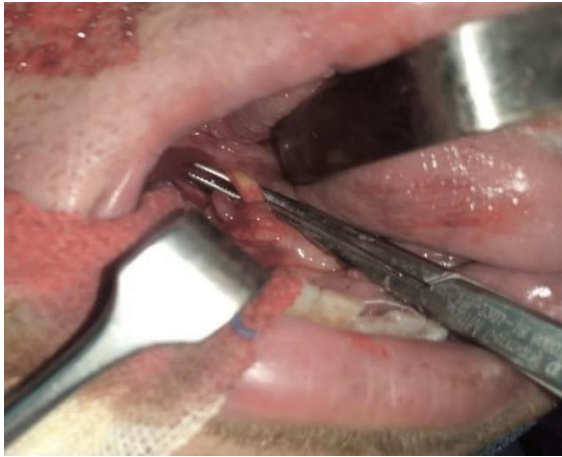


Fig (4): Lingual Nerve medialization after uncrossing with the duct.

Post-operative follow-up:

Collection of post-operative data as tongue sensation, tongue movements, wound healing, wound bleeding, wound infection, and final pathology.

Statistical methods

Data management and statistical analysis were done using SPSS version 25. (IBM, Armonk, New York, United States).

---

## Results:

Transoral sialoadenectomy was performed on 20 patients, 8 men (40%) and 12 women (60%). The mean age was 33.83 years (17.1–51.6 years) (Table 1).

In this study, 13 patients (65%) showed evidence of calculi submandibular sialadenitis, 4 patients (20%) with non calculi submandibular sialadenitis, and 3 patients (15%) with pleomorphic adenoma (Table 1).

All cases were presented with small mobile gland. The mean lump size was

16.4 mm (12-20 mm). all patients passed the 3-finger test to evaluate maximal mouth opening (Table 1).

In the early phase of this study synchronous with still little experience in this approach, two cases (10%) showed difficult dissection due to dense adhesions. Hard dissection complicated by glandular fragmentation and unaccepted hemostasis. Conversion to standard transcervical approach was accomplished in both cases (Table 2).

The mean operative time was 93.75 min (range 55–125 min). The mean duration of hospital stay was 2.75 days (ranged from 2-5 days). Healing time (full mucosal healing and recovery of oral sensations) was 14–23days (Table 2).

Two patients (10%) developed wound infection, treated with transoral drainage and antibiotics after culture and sensitivity. Those patients showed delayed wound healing (30 and 35 days).

Five cases (25%) developed abnormal tongue tip sensation that gradually disappeared after 2-3 weeks. No patient developed limitations in tongue movement either early or late. In literature, early limitations in tongue movement are attributed to hypoglossal nerve affection. While late tongue movement affection usually related to the developed scar in the floor of mouth (12) (Table 2).

**Table (1):** Preoperative data (Original).

Gender	Male	8 (40%)
	Female	12 (60%)
Age (y)		33.83 (17.1-51.6)
Pathology	Sialolithiasis	13 (65%)
	Sialadenitis	4 (20%)
	Pleomorphic adenoma	3 (15%)
Gland size (mm)		16.4 (12-20)

**Table (2):** Operative and Postoperative Data (Original)

Operative time (min)	93.75 (55-125)
Transcervical Conversion	2 (10%)
Hospital Stay (days)	2.75 (2-5)
Healing Time (days)	14-23
Wound infection	2 (10%)
Abnormal Tongue Sensation	5 (25%)
Limited Tongue Movement	0

### Discussion:

Modern surgery launched many bright topics as Minimal Invasive Surgery, Scarless Surgery, and Natural Orifice Surgery. All these efforts are trying to deliver the surgical therapy in less morbidity, more efficacy, and better patient satisfaction (13).

Before 1960, a dental surgeon noticed the feasibility to remove the submandibular

gland with natural orifice transoral approach. This new concept was kept unfamous till the beginning of 21st century (3, 4).

In this study, we started to perform transoral sialoadenectomy for selected cases. Many points were considered for patient selection. All cases with malignant suspicion are excluded from this study for fear of malignant dissemination.

Lump size was the second point for selection. Lumps more than 2 cm, and lumps with limited mobility are excluded. These parameters match the Chang et al findings (4).

This parameter was found to be helpful, as we did not find difficulty in gland removal specially after the initial phase in this study.

Transoral approach for submandibular sialoadenectomy eliminates the visible neck scar plus eliminating the risk of marginal mandibular nerve injury. The main risk in this approach is the liability to injure the lingual nerve. In this study, we found lingual nerve paresthesia in 25% of cases. Fortunately, this paresthesia improved after 2-3 weeks. Other studies reported higher incidence of lingual nerve affection; 74% (4), 50% (14), 43% (12), and 25% (15).

In this study, the relatively low incidence of lingual nerve affection may be attributed to our protocol for dexamethasone injection before nerve dissection. The same strategy with recurrent laryngeal nerve during thyroidectomy. Also, the step of uncrossing the nerve and Wharton's duct. This step minimizes the undue traction over the lingual nerve.

The hypoglossal nerve is almost far from being injured during transoral approach as it lies deep in the bed. Hypoglossal nerve

injury is presented with early affection of tongue movement. On the other hand, late affection of tongue movement due to the formed scar in oral floor and possible injury of extrinsic tongue muscles (4). In this study, no early or late affection of tongue movement was reported. Some authors reported no limitation of tongue movement (12, 15). While others reported tongue movement limitation in 70% and 40% in their first and second papers respectively (4, 14).

In this study, no cases with much bleeding intraoperatively or postoperatively. Slow meticulous dissection and bipolar coagulation of small blood vessels offer the reliable hemostasis. Two cases (10%) suffered from wound infection and subsequent wound dehiscence. Previous study (4) reported bleeding in 2.6% and postoperative infection in 2.6%. Cases with immediate postoperative swelling in submandibular area was diagnosed as bleeding. Urgent return to OR for wound exploration was mandatory. One case was controlled through intraoral approach, while the other case required external transcervical approach for proper control (4).

---

### **Conclusion:**

Although transcervical approach for submandibular sialoadenectomy is still the standard approach, transoral approach can

be a good alternative in selected cases, especially with those patients who are strongly appreciating scarless operations as young age females.

---

## References:

1. P. P. Singh, M. Goyal. Our Experience with Intraoral Submandibular Gland Excision 2020. *Indian J Otolaryngology Head Neck Surg.* 2020;72(3):297–301.
2. Pasquale Capaccio, Filippo Montevercchi, Giuseppe Meccariello, Giovanni Cammarato, Jeffery Scott Magnuson, Stefano Pelucchi, et al. Transoral Robotic Submandibular Sialadenectomy: How and When? *Gland Surgery.* 2020;9(2):423–9.
3. Downton D, Qvist G, London FRCS. Intra-oral Excision of the Submandibular Gland. *Proc R Soc Med.* 1960; 53:9–10.
4. Hong KH, Yang YS. Surgical results of the intraoral removal of the submandibular gland. *Otolaryngology - Head and Neck Surgery.* 2008 Oct;139(4):530–4.
5. Ying-Nan Chang, Chaun-Hsiang Kao, Yaoh-Shiang Lin, Jih-Chin Lee. Comparison of the intraoral and transcervical approach in submandibular gland excision. *Eur Arch Otorhinolaryngol.* 2013; 270:669–74.
6. Giovanni Cammarato, claudio Vicini, Fillipo Montevercchi, Anna Bonsembiante, Giuseppe Meccariello, Lorenzo Bresciani, et al. Submandibular gland excision\_ From external surgery to robotic intraoral and extraoral approaches. *Oral Diseases.* 2020; 26:853–7.
7. Seung Wook Jung, Young Hoon Cha, Yoon Woo Koh, Woong Nam. Robot-assisted submandibular gland excision via modified facelift incision 2017. *Maxillofacial Plastic and Reconstructive Surgery.* 2017;39(25).
8. Beahm DD, Peleaz L, Nuss DW, Schaitkin B, Sedlmayr JC, Rivera-Serrano CM, et al. Surgical approaches to the submandibular gland: A review of literature. Vol. 7, *International Journal of Surgery.* 2009. p. 503–9.
9. Capaccio P, Montevercchi F, Meccariello G, Cammaroto G, Magnuson JS, Pelucchi S, et al. Transoral robotic submandibular sialadenectomy: How and when. *Gland Surgery.* 2020 Apr 1;9(2):423–9.
10. Khalid H. Zawawi, Emad A. Al-Badawi, Silvia Lobo Lobo, Marcello Melis, Noshir R. Mehta. An Index for the Measurement of Normal Maximum Mouth opening. *J Can Dent Assoc.* 2003;69(11):737–41.
11. Agrawal J, Shenai PK, Chatra L, Kumar PY. Evaluation of normal range of mouth opening using three finger indexes: South India perspective study [Internet]. Available from: <https://www.ijdr.in/text.asp?2015/26/4/361/167638>
12. Weber SM, Wax MK, Kim JH. Transoral excision of the submandibular gland. *Otolaryngology - Head and Neck Surgery* [Internet]. 2007 Aug [cited 2021 Dec 6];137(2):343–5. Available from: [https://www.researchgate.net/publication/6173455\\_Transoral\\_Excision\\_of\\_the\\_Submandibular\\_Gland](https://www.researchgate.net/publication/6173455_Transoral_Excision_of_the_Submandibular_Gland)
13. Bhatt N, Perakis H, Brown JJ. Transoral excision of the submandibular gland. *Laryngoscope.* 2010;120(SUPPL. 4).
14. Hong KH, Yang YS. Intraoral approach for the treatment of submandibular salivary gland mixed tumors. *Oral Oncology.* 2008 May 1;44(5):491–5.
15. Kauffman RM, Netterville JL, Burkey BB. Transoral excision of the submandibular gland: Techniques and Results of nine cases. *Laryngoscope.* 2009 Mar;119(3):502–7.



**To cite this article:** Ehab M. Oraby , Mohammad I. Aburezk , Mokhtar A. Bahbah. Transoral Submandibular Sialoadenectomy; Feasibility and Case Selection. BMFJ 2022;39(2): 721-729. DOI: 10.21608/bmfj.2022.141274.1599