

Dept. of Animal Medicine,  
Fac. of Vet. Med., Assiut University, Assiut Egypt.

## **EFFECT OF INTRODUCING A NOVEL ANTIGEN INTO THE DIET OF CATS ON GASTROINTESTINAL ABSORPTIVE FUNCTION AND BACTERIAL FLORA**

(With 2 Tables and 5 Figures)

By

**NASHWA E. WALY; C.R. STOKES\***

**and T.J. GRUFFYDD-JONES\***

\* Veterinary Pathology, Infection and Immunity (VPIL), Faculty of Veterinary  
Medicine, University of Bristol, Langford BS40 5DU, UK.

(Received at 7/3/2007)

**تأثير إدخال أنتيجين جديد في غذاء القطط على وظيفة الإمتصاص في الجهاز  
الهضمي وعلى الفلورا الموجودة في الأمعاء**

**نشوى عصمت والى ، تيموثى جريفيث جونز ، كريستوفر ستوكس**

تم دراسة تأثير تغذية قطط خالية من مسببات الأمراض بأنتيجين جديد على وظيفة امتصاص القناة الهضمية وذلك باستخدام BH2 X Test والمزرعة البكتيرية لسائل الأمعاء الذي تم جمعة عن طريق المنظار (Endoscopy). هذا وقد تمت متابعة هذه الوظيفة بعد كل دورة تغذية وذلك لقياس قدرة امتصاص القناة الهضمية وكذلك تأثير الأنتيجين الجديد على تغيرات فلورا الأمعاء. وقد أوضحت الدراسة أن نتائج BH2 X Test لم تكن موحية بسوء الامتصاص بصورة منتظمة وذلك في المجموعة المختبرة (treatment group) والتي تم إدخال زلال البيض (ovalbumin) المجفف في غذائها. على أن الدراسة أظهرت وجود ارتفاع معنوي ( $P < 0.05$ ) في عدد البكتيريا الهوائية مع تغيير ملحوظ في نوعية البكتيريا في السائل المعوي المجمع من كل القطط (control & treatment groups) بعد إدخال الأنتيجين الجديد إلى غذاء المجموعة المختبرة (treatment group). وعلى ذلك فنتائج هذا البحث تبين أن عدد ونوعية البكتيريا الهوائية في الأمعاء الدقيقة للقطط تتغير بصورة واضحة وجوهريّة بعد إدخال الأنتيجين الجديد إلى غذائهم، ويمكن أن نستنتج ونتوقع أن هذه التغيرات يمكن أن تؤثر على الجهاز المناعي المصاحب للأمعاء ويمكن أن تتدخل في خط سير أمراض التهابات المعوية.

### **SUMMARY**

The effect of feeding a novel dietary antigen on the gastrointestinal tract function of specific pathogen free cats was determined using breath hydrogen xylose (BH<sub>2</sub>X) test and bacteriological culture of duodenal aspirates collected during endoscopy. These functions were monitored after each feeding cycle for detection of absorptive ability of

gastrointestinal tract as well as the effect of novel dietary antigen on change of intestinal flora. Breath hydrogen xylose test results were not suggestive of consistent mal-absorption in the treatment group due to introducing ovalbumin into their diet. After the start of ovalbumin feeding, the aerobic bacterial count significantly increased in all cats ( $P < 0.05$ ). A remarkable change in quality of bacteria was also evidenced in duodenal aspirates collected from all cats after introducing ovalbumin into the cats' diet. Anaerobic bacterial quality and quantity changes were not significant ( $P > 0.05$ ). In conclusion, the results of this study demonstrates that aerobic bacteria change significantly in quality and quantity in the small intestine of cats after introducing a novel antigen into their diet. Such changes might have an effect on the gut associated lymphoid tissue response which could be involved in the pathogenesis of enteropathies in cats.

**Key words:** *Feline IBD, Aerobic and Anaerobic bacterial counts, duodenal aspirates, SIBO, Breath hydrogen xylose test.*

## INTRODUCTION

Following the introduction of a novel antigen into the diet of mice, their capacity to regulate responses to unrelated, mucosally-presented soluble protein antigens is transiently altered (Stokes *et al.*, 1983). Failure to control such changes and lack of development of tolerance may be an important factor in the immunological changes, which may lead to establishment of inflammatory bowel disease (IBD). This disease is a multifactorial disorder, the exact cause of which remains undetermined. Breakdown of mucosal integrity and subsequent impact on barrier function of the gut of IBD patients is implicated in the pathogenesis of the disease.

It has been previously shown that the repeated feeding of ovalbumin to cats may in some individuals cause low-grade disruption of mucosal integrity accompanied by histological evidence of inflammation in the small intestinal lamina propria (Waly *et al.*, 2001); this may also be associated with alterations in the immune response to commensal microflora (Ibbotson *et al.*, 1992; Duchmann *et al.*, 1995 & 1996). Histological evidence of inflammation such as villous stunting results in malabsorption (Corazza *et al.*, 1987) which may reflect on tests designed to indicate mal-absorption such as breath hydrogen xylose tests ( $BH_2X$ ). Although  $BH_2X$  test can reflect gut function, it can also be influenced by the bacterial overgrowth (Kerlin *et al.*, 1984). Breath  $H_2X$  test has been used to assess the functional relevance of mild

abnormalities in small bowel biopsy specimens (Matz and Guilford, 2003).

Small intestinal bacterial overgrowth (SIBO) is a recognized syndrome in humans (Bouhnik, 2001) and dogs (German *et al.*, 2003) characterized by an increase in number and variety of bacteria in small intestinal fluid that is associated in gastrointestinal abnormalities manifested by diarrhoea. It has been reported that SIBO is not a recognized clinical syndrome in cats with chronic non-obstructive gastrointestinal tract disease (Johnston, 1999). The naturally high number of small intestinal bacteria has been an obstacle to setting criteria for diagnosis of SIBO in cats. Wide quantitative and qualitative variation in the duodenal flora of healthy cats is reported (Sparkes *et al.*, 1998). However, these reported studies have not questioned the effect of a novel dietary protein antigen on bacterial flora and intestinal absorptive function.

The aim of the study was to examine whether oral administration of a novel dietary antigen to cats leads to changes in gut function, absorption and changes in bacterial flora of the small intestine.

## **MATERIALS and METHODS**

### **Animals**

Six clinically healthy SPF-derived, barrier-maintained, cats were used for the study and were housed at the feline research facility, Feline Centre, Department of Clinical Veterinary Sciences, University of Bristol, Langford, UK. They were all domestic shorthair, neutered male adult cats aged between 12-14 months. The cats were fed on a commercial canned chicken and rabbit-based diet (KiteKat, Waltham). Their full previous dietary history was known and they had never been fed eggs or any related components.

### **Experimental design**

The cats were divided into two groups, a control (n=3) and treatment (n=3) group.

Treatment group cats were fed with 7.5gm ovalbumin (grade II, Sigma) mixed with canned food per day (dosage selected on basis of the results of preliminary experiments). The mixing of canned food with ovalbumin was done in a preparation room and each cat was fed from a different bowl in the anteroom. The three control cats were fed canned food with no added ovalbumin. Ovalbumin feeding was performed for five consecutive days; duodenal aspirates were taken on day 6, and breath hydrogen test was performed on day 7. The cats received canned

food only for the following 10 days (rest period) and then received ovalbumin mixed with food on day 11 for another 5 days. This regime was repeated four times (Fig.1).

### **Endoscopy**

Samples of duodenal aspirates were collected by endoscopy using a flexible gastroscope with 6 mm diameter insertion tube and 2 mm biopsy channel (Olympus gastrointestinal fibrescope GIF N30, Keymed). Food was withheld from cats overnight prior to endoscopy. Endoscopy was performed under general anaesthesia.

### **Histopathology**

Duodenal biopsies were collected to monitor changes occurring in the duodenum before and after feeding of ovalbumin and for monitoring control cats. Formalin-fixed biopsies were cut and stained by haematoxylin and eosin (H&E) for assessment of intestinal histology throughout the experiment.

### **Breath Hydrogen-Xylose Test**

As above, Breath Hydrogen test is used to assess intestinal damage leading to malabsorption by the small intestine (Muir *et al.*, 1991 and 1996; Papasouliotis *et al.*, 1998) but can also be influenced by SIBO. After an overnight fast, exhaled breath samples were collected using the method described previously (Papasouliotis *et al.*, 1998), with the cats confined in Perspex chamber. Breath hydrogen excretion was measured before and every 15 minutes for 4 hours after the administration of D-Xylose. D-xylose was given through a nasogastric tube at 1 g/kg.B.W. diluted to 1g/ml in water (Papasouliotis *et al.*, 1998). Measurement of Hydrogen concentration in breath samples and calculation of hydrogen excretion in ml/hr were performed as described previously (Papasouliotis *et al.*, 1998). In brief, for each of the cats, the total breath hydrogen excretion was calculated by adding together the hydrogen concentration at each time point during the four hour monitoring period. The mean and standard deviation (SD) for breath hydrogen excretion was then computed. The test was considered abnormal if the breath hydrogen increase over the baseline level (at time 0 minutes) equalled or exceeded twice the SD for normal cats and that the increase in hydrogen excretion was sustained for at least three consecutive time points (45 min.)

### **Bacteriology of duodenal aspirates**

A sample of small intestinal fluid (100  $\mu$ l) was collected from the duodenum during endoscopy by inserting an aspiration tube through the endoscope. The sample was then placed in a sterile vacutainer; the air in

the vacutainer was removed using a syringe to protect oxygen sensitive bacteria. After sampling, dilutions of the specimen were put into an anaerobic cabinet and inoculated onto agar plates within 10 minutes of sampling. Media used were blood agar, MacConkey agar and fastidious anaerobe agar (FAA) with and without gentamycin.

Series of dilutions of the specimen ranged from 1/10-1/10000 in sterile saline were prepared for quantitation of aerobic and anaerobic bacteria. Plates for anaerobes were inoculated and incubated in the anaerobic cabinet while plates for aerobes were inoculated in room air and incubated in 5% carbon dioxide atmosphere.

A drop of each dilution (10  $\mu$ l) was spread on plates using a sterile loop. After appropriate incubation, colonies on the plates were counted and species identified using standard techniques.

### **Statistics**

A standard T-test was used to detect differences between groups before and after introducing ovalbumin into the diet of cats using the Excel software (Microsoft Office Excel 2003, Microsoft Incorporation, USA). The significance level was set at 0.05.

## **RESULTS**

### **Histopathology**

Biopsies collected from control group cats showed no deviation from the normal structure throughout the experiment (Fig. 2). Biopsies from treatment group cats had no significant histopathological changes before introducing ovalbumin into their diet. After the second feed, there was mild inflammatory change of biopsies from two cats showing increased villous width and increase infiltration of the lamina propria with neutrophils and macrophages. Cat 3 showed similar changes with a degree of villous stunting after the third and fourth feed.

### **Breath H<sub>2</sub> Xylose Test**

Breath hydrogen excretion over a 3-hour period after a xylose meal was recorded for each cat at four time points during this experiment. Baseline results, measured before the start of feeding ovalbumin, showed that one control cat and two treatment cats had an increased H<sub>2</sub> excretion. After the second feed, one control and one treatment cat showed an increase of H<sub>2</sub> excretion (cats 2 and 6). After the third feed, two cats (cats 5 and 6) from the treatment group showed increased H<sub>2</sub> excretion. After the fourth feed, cat 2 of the control group and cat 6 of the treatment group also showed increased H<sub>2</sub> excretion (Table 1).

**Table 1:** BH<sub>2</sub>X Test Results

	Baseline	Feed 1	Feed 2	Feed 3	Feed 4
Cat 1	-	ND	+	+	-
Cat 2	+	ND	+	-	+
Cat 3	-	ND	-	-	-
Cat 4	-	ND	-	-	-
Cat 5	+	ND	-	+	-
Cat 6	+	ND	+	+	+

ND, not done, +, positive, -, negative BH<sub>2</sub>X test result. Cats 1, 2 and 3 represent the control group; cats 4, 5 and 6 represent the treatment group.

### Bacteriology

Samples were collected twice from treatment group cats before introducing ovalbumin into their diets and once from the control group. These time points were considered as a first and second baseline points. The results were pooled for cats in each group.

The range of aerobic bacteria isolated increased after ovalbumin was introduced into the diet of cats. *Neisseria/Branhamella spp.*, Diphtheroid-like bacillus, *Streptococci* type 1 and 2, Unidentified Gram negative bacilli and faecal *Streptococci* were identified after the first feed as well as other aerobes isolated after baseline points one and two. *Pasteureulla sp.*, alpha-haemolytic *Streptococci*, *Pseudomonas sp.*, Gram negative rods, *Coliform* bacilli type 1 and 2 were isolated after the second feed whereas Indole-negative oxidase-positive Gram-negative rods, Gram positive rods were isolated after the fourth feed (Table 2).

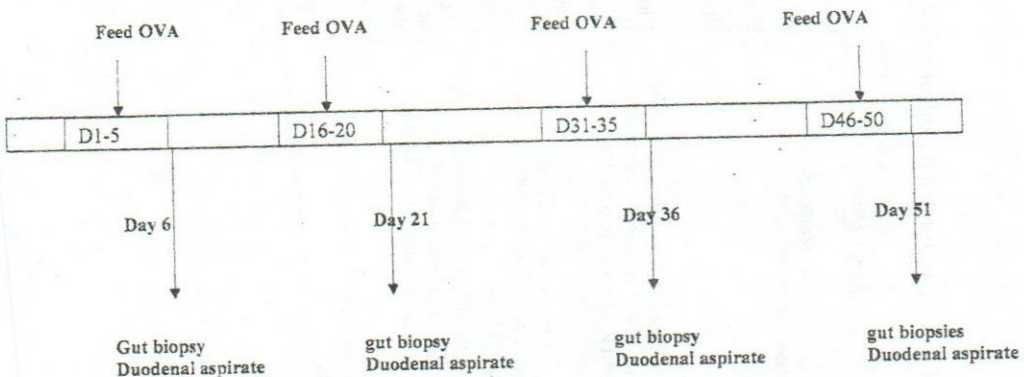
The species of anaerobes isolated after each time point was less variable. *Clostridium spp.*, were isolated from the two groups before the start of the experiment. Following the first feed *Clostridium perfringens*, *Clostridium sp.*, and *Bacteroides sp.* were isolated from the control group. After the second feed, Pleomorphic Gram negative bacilli and unidentified Gram negative coccobacilli were the anaerobes isolated from the control group which had not been isolated previously whereas *Clostridium perfringens* was isolated after the third feed from the same group. After the fourth feed, there were no new anaerobes isolated from the control group.

For the treatment group, *Weeksella sp.*, unidentified Gram-negative bacilli types 1 and 2, *Clostridium sp.*, and Gram positive bacilli were isolated before feeding ovalbumin started. After the first feed, *Clostridium perfringens* was isolated; following the third feed, *Bacteroides*, *Clostridium perfringens*, anaerobic Gram-negative rods types 1, 2 and 3, Pleomorphic Gram-positive rods were isolated. After the fourth feed, no new anaerobes were isolated.

The results of aerobic bacterial counts are summarized in figure 2. Aerobic bacterial counts ranged from 1-120 X 10<sup>3</sup> CFU/ml before the introduction of ovalbumin into the diet of cats (Fig. 3). Aerobic bacterial counts for the control group increased after the second feed and the difference was significant (P=0.001). After the first feed one cat showed a dramatic increase in the number of aerobic bacteria. The number of aerobic bacteria increased after the first feed for the treatment group (P=0.04) and then varied after the second, third and fourth feeds with slight inconsistent increase or decrease. Aerobic bacterial counts were approximately twice as high as the anaerobic bacterial counts from all cats (P=0.013).

Anaerobic bacterial counts did not show a consistent pattern throughout the study (Fig. 4). Cat 2 of the control group showed an increase of anaerobic count after the second and fourth feed but this was not statistically significant (P=0.38). Cat 6 of the treatment group also showed an increase of anaerobic count after the fourth feed.

The total bacterial count was recorded and was the sum of total aerobic and total anaerobic bacterial count for each cat in the experiment. The results were more representative of the aerobic bacterial count as the high number of aerobic bacteria overshadowed those of the anaerobic bacteria (Fig. 5). The total bacterial count increased only after the second feed for the control group except for cat 2 which showed a sharp rise after the first feed. Following the second feed, total bacterial count increased for all cats of both the control and treatment groups but the increase was not statistically significant (P>0.05).



**Fig. 1: Experimental protocol.**

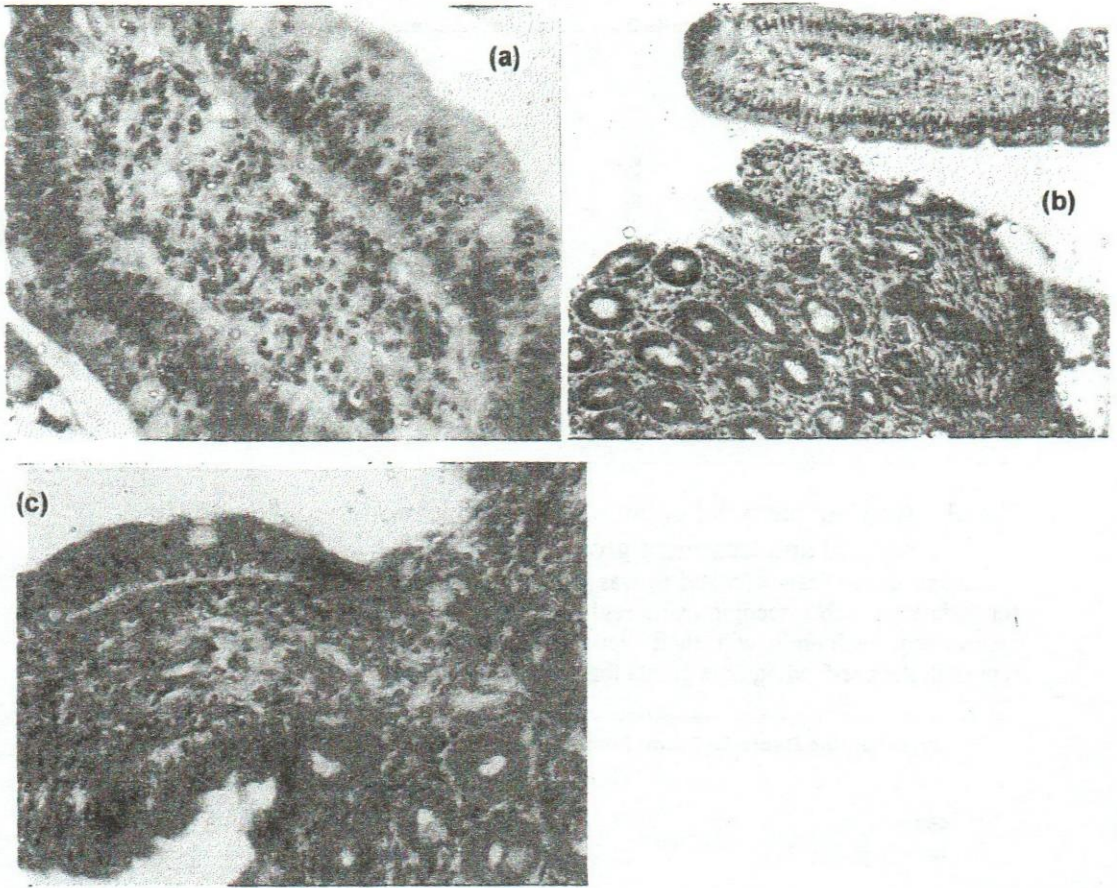
Test cats were fed ovalbumin (OVA) for five consecutive days, control cats were maintained on chicken based diet; the feeding regime was repeated four times with rest interval of ten days where all cats were fed a chicken based diet with no OVA. Breath hydrogen test was formed the day after endoscopy.

Table 2. Bacteria isolated from duodenal aspirates cultures throughout the experiment

Time points	Control Group		Treatment Group	
	Aerobes Isolated	Anaerobes Isolated	Aerobes Isolated	Anaerobes Isolated
Baseline 1	Streptococci, E. coli, Weeksella species, unidentified Gram -ve bacilli	Clostridium species, Streptococcus species, Gram-ve bacillus type 1-6, Gram+ve bacillus	Pasteurella species.	Weeksella, unident Gram -ve bacilli types 1 and 2, Clostridium species
Baseline 2	ND	ND	Streptococci, E. coli, Weeksella species, unidentified Gram-ve bacilli	Clostridium species, Gram +ve bacilli
Feed 1	As B1+ Neisseria/ Branhamella species, Diphtheroid-like bacillus, Streptococci type 1 and 2, Unidentified Gram -ve bacilli, faecal Streptococci	Clostridium perfringens, Clostridium species, Bacteroides	as B2 + Coliform bacillus, faecal Streptococci, Neisseria/ Branhamella species	Clostridium perfringens
Feed 2	As feed 1 + non-haemolytic Streptococci, Gram +ve bacilli, Diphtheroid bacilli type 2, Coliform bacilli	Clostridium species, Pleomorphic Gram -ve bacilli, unidentified Gram-ve coccobacilli	as Feed 1 + Proteus species	Bacteroides, Clostridium perfringens, anaerobic Gram -ve rods types 1, 2 and 3, Pleomorphic Gram +ve rods
Feed 3	Pasteurella species, alpha-haemolytic Streptococci, Pseudomonas species, Gram -ve rods, Coliform bacilli type 1 and 2	Clostridium species, Gram -ve rods type 1,2, Clostridium perfringens	As Feed 1 + Pasteurella species, alpha-haemolytic Streptococci	Gram -ve coccobacilli, Fusobacterium species, Clostridium perfringens
Feed 4	Indole-ve oxidase + Gram-ve rods, Gram +ve rods	C perfringens, Clostridium species, anaerobic Gram +ve rods and cocci	As feed 1 + Pseudomonas species, Pasteurella species	anaerobic g-ve bacilli 1, 2, c perfringens

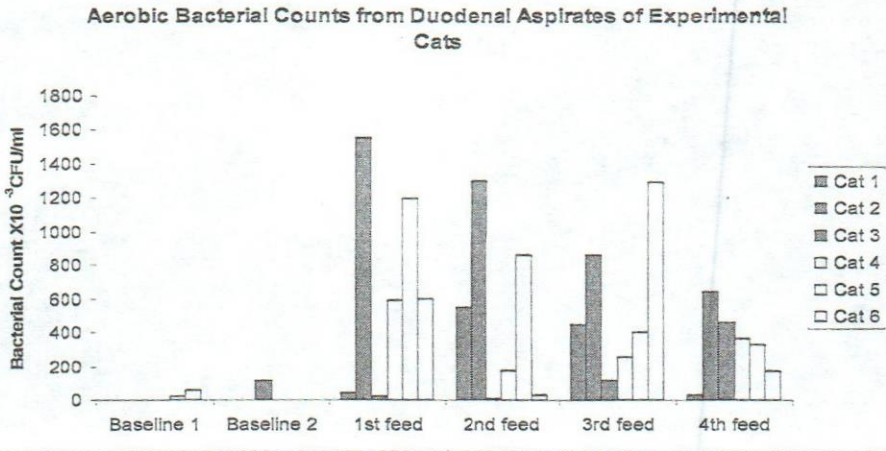
ND, not done.





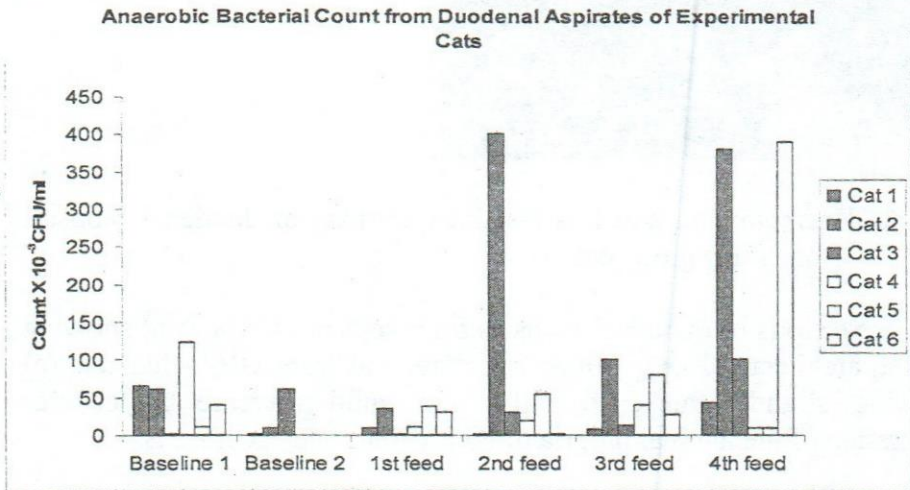
**Fig. 2:** Haematoxylin and Eosin-stained sections of duodenal biopsies from study group cats.

Sections of duodenal biopsies from control cats (a & b) showing normal architectural and cellular structure; and from OVA- fed cats (c) showing slightly thickened villus and mild increase in cellular infiltration of the laminal propria of both villous and crypt areas.



**Fig. 3:** Aerobic bacterial count of duodenal aspirates collected from control and treatment groups.

Treatment group (cats 4, 5 and 6) was fed 7.5 gm of ovalbumin mixed with their diet for 5 days of a four-feeding cycle regimen. Control group (cats 1, 2 and 3) did not receive any ovalbumin with their diet throughout the experiment. Baseline 1 and 2 represent the pre-feeding time points for the treatment group.



**Fig. 4:** Anaerobic bacterial count of duodenal aspirates collected from control and treatment groups.

Treatment group (cats 4, 5 and 6) was fed 7.5 gm of ovalbumin mixed with their diet for 5 days of a four-feeding cycle regimen. Control group (cats 1, 2 and 3) did not receive any ovalbumin with their diet throughout the experiment. Baseline 1 and 2 represent the pre-feeding time points for the treatment group.

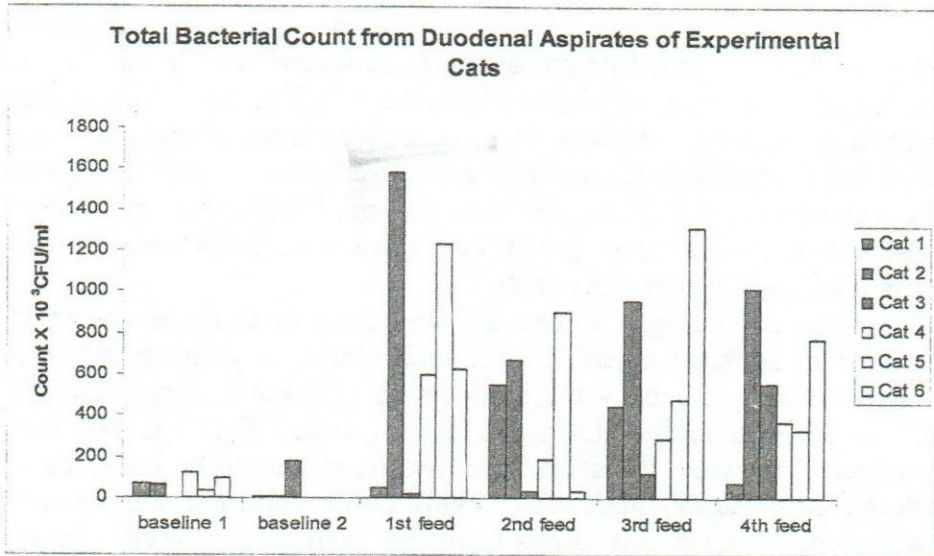


Fig. 5: Total bacterial count of duodenal aspirates collected from control and treatment groups.

This represents the sum of the total aerobic and anaerobic count for each cat throughout the experiment.

## DISCUSSION

Numerous studies have been performed to characterize the pathogenesis of inflammatory bowel conditions in various species. The role of bacteria, in particular the possibility that commensal organisms are a target for an aberrant intestinal immune response is yet to be investigated in the cat. Recent data have suggested an association between intestinal inflammation, loss of mucosal integrity and the loss of tolerance to commensal flora (Duchmann *et al.*, 1995). Therefore, this study has attempted to investigate the effect of the introduction of ovalbumin into the diet of cats, upon intestinal flora and intestinal absorptive function and hence, an association to gut inflammation. The experiment was designed to compare the response between a group of cats fed ovalbumin as a novel dietary antigen, and a group of control cats. The small number of cats per group is a limitation that could not be avoided in these experiments due to high cost of maintaining cats. All cats were sampled before the start of feeding to obtain baseline values so that each cat acted as its own control to compensate for the low cat numbers per group.

Changes suggestive of an inflammatory process was detected in biopsies from treatment group cats after the second feed in the form of villous stunting, neutrophil and macrophage infiltration of the lamina propria of duodenal biopsies. One cat showed these changes after the third and fourth feeds. Control cats were described as normal throughout the experiment, which implies that the mild inflammatory changes observed in the treatment group were a result of introducing a novel dietary antigen into the diet of cats

Breath hydrogen xylose test was used to evaluate absorptive function of the small intestine as an indication of any abnormality that may result or accompany the introduction of a novel dietary antigen. Xylose is a naturally absorbable carbohydrate; if it has not been absorbed following ingestion then hydrogen excretion increases in affected cats (Papasouliotis *et al.*, 1998). Of the control group, two cats had abnormal BH<sub>2</sub>X test results before the start of the experiment and after the third feed. Only cat 6 (control) had abnormal results following the second and fourth feeds. This result may be accidental since these cats never received ovalbumin during the experiment and never showed other signs of gastrointestinal disorder. One of the treatment group cats showed increased H<sub>2</sub> excretion before the start of the experiment, two after the second, and one after the third and fourth feeds. Such inconsistencies have been previously reported by Papasouliotis and coworkers, when only two cats out of ten had abnormal BH<sub>2</sub>X test values suggestive of malabsorption (1998). These are common problems encountered with feline research due to individual variations.

The bacterial count of duodenal aspirates included that of aerobes and anaerobes. The aerobic bacterial count started low (baseline 1 and 2) and then significantly increased in duodenal aspirates from all cats with the introduction of ovalbumin into the diet of treatment group. The quality of aerobes also changed with the experiment as more bacterial species were isolated after the first feed than before the start of feeding from both groups of cats (Table 2). Cats are fastidious groomers; they groom themselves and others in the same social group as part of their normal behavior. This could explain why the increase of bacterial count was not restricted to treatment group that received ovalbumin. Intestinal bacteria passed in faeces is found in all cats, which also explains the presence of *Streptococcus faecalis* in duodenal aspirates and also explains the increase in bacterial counts in all cats after the start of feeding and not during the baseline time points. The anaerobic bacterial count was lower than aerobic bacterial count and there was not a clear

pattern to the increase in numbers. The quality of anaerobic bacterial species was less varied than that of aerobes.

Overall, the increase in the number of aerobic bacteria despite its significance does not qualify as SIBO. In human, SIBO which may result from intestinal stasis is common in malabsorption syndrome (Ghoshal *et al.*, 2006). However, it is still not well-defined in veterinary practice (Johnston, 1999) and has proven difficult to diagnose in dogs and bacterial counts were found to vary on repeated sampling (Willard *et al.*, 1994). Veterinary clinicians commonly refer to SIBO in dogs as antibiotic-responsive diarrhoea (ARD). German and others studied a group of dogs with enteropathies and ARD and found that there was no significant difference between the two groups in terms of intestinal bacterial numbers and concluded that the value of quantitative duodenal bacteriology for SIBO in the investigation of canine gastrointestinal disorders is questionable (2003). On the other hand, it has been suggested that SIBO may be associated with mild mucosal damage undetected on histological examination of intestinal biopsies (Rutgers *et al.*, 1996).

From the above, it could be suggested that introducing ovalbumin to the diet of cats resulted in a mild mucosal damage which led to the significant increase in the aerobic bacterial count and quality in the small intestine of treatment group. The feline grooming habits, may have been the cause of the increase in aerobic bacterial count in the control group especially that this increase was more consistent after the second feed rather than the first as with the treatment group.

It could be therefore concluded that dietary change can lead to mild mucosal damage or inflammation which in turn may affect the intestinal bacterial flora in cats. Such changes have an effect on the gut associated lymphoid tissue response as demonstrated by the mild infiltrative changes in duodenal biopsies from fed cats and could be therefore, involved in the pathogenesis of enteropathies in felines.

Further work should be carried-out on the mucosal immune response to such increases in aerobic counts and types in the small intestine. This could be important in elucidating the pathogenesis of idiopathic gastrointestinal inflammation and hypersensitivity and will help in understanding how such conditions should be approached.

### **ACKNOWLEDGEMENT**

The Authors would like to acknowledge Professor Michael Day for the histopathology evaluation of duodenal samples included in this study and all the technicians at the Bacteriology Laboratory at the

Department of Clinical Veterinary Science, University of Bristol, UK for their help and assistance with bacteriology work performed in this study.

## REFERENCES

- Bouhnik, Y. (2001):* Chronic bacterial overgrowth in the small intestine. *La Reveue Du Praticien*, 51; 964-968.
- Corazza, G.R., Strocchi, A. and Gasbarrini, G. (1987):* Fasting breath hydrogen in celiac disease. *Gastroenterology*, 93; 53-58.
- Duchmann, R.; Kaiser, I.; Hermann, E.; Mayet, W.; Ewe, K. and Meyer Zum Buschenfelde, K.H. (1995):* Tolerance exists towards resident intestinal flora but is broken in active inflammatory bowel disease (IBD). *Clinical and Experimental Immunology*, 102(3); 448-455.
- Duchmann, R.; Märker-Hermann, E. and Meyer Zum Buschenfelde, K.H. (1996):* Bacteria-specific T-cell clones are selective in their reactivity towards different enterobacteria or *H. pylori* and increased in inflammatory bowel disease. *Scandinavian Journal of Immunology*, 44; 71-79.
- German, A.J.; Day, M.J.; Ruaux, C.G.; Steiner, J.M.; Williams, D.A. and Hall, E.J. (2003):* Comparison of direct and indirect tests for small intestinal bacterial overgrowth and antibiotic-responsive diarrhoea in dogs. *Journal of Veterinary Internal Medicine*, 17; 5-7.
- Ghoshal, U.C.; Ghoshal, U.; Das, K. and Misra, A. (2006):* Utility of hydrogen breath tests in diagnosis of small intestinal bacterial overgrowth in mal-absorption syndrome and its relationship with oro-cecal transit time. *Indian Journal of Gastroenterology*, 25; 6-10.
- Ibbotson, J.P.; Lwoes, J.R.; Chahal, H.; Gaston, J.S.H.; Life, P.; Kumararatne, D.S.; Sharif, H.; Alexander-Williams, J. and Allan, R.N. (1992):* Mucosal cell mediated immunity to mycobacterial, enterobacterial and other microbial antigens in inflammatory bowel disease. *Clinical and Experimental Immunology*, 87; 224-230.
- Johnston, K.L. (1999):* Small intestinal bacterial overgrowth. *Veterinary Clinical North American Small Animal Practice*, 29; 523-550, vii.
- Kerlin, P.; Wong, L.; Harris, B. and Capra, S. (1984):* Rice flour, breath hydrogen and malabsorption. *Gastroenterology*, 87; 578-585.

- Matz, M.E. and Guilford, W.G. (2003):* Laboratory procedures for the diagnosis of gastrointestinal tract diseases of dogs and cats. *New Zealand Veterinary Journal*, 51; 292-301.
- Muir, P.; Gruffydd-Jones, T.J.; Cripps, P.J. and Brown, P.J. (1996):* Breath hydrogen excretion by healthy cats after oral administration of oxytetracycline and metronidazole. *Veterinary Record*, 138; 635-639.
- Muir, P.; Papasouliotis, K.; Gruffydd-Jones, T.J.; Cripps, P.J. and Harbour, D.A. (1991):* Evaluation of carbohydrate malassimilation and intestinal transit time in cats by measurement of breath hydrogen excretion. *American Journal of Veterinary Research*, 52; 1104-1109.
- Papasouliotis, K.; Gruffydd-Jones, T.J.; Werrett, G.; Brown, P.J.; Hopper, C.D.; Stokes, C.R. and Harbour, D.A. (1998):* Assessment of intestinal function in cats with chronic diarrhoea after infection with feline immunodeficiency virus. *American Journal of Veterinary Research*, 59; 569-574.
- Rutgers, H.C.; Batt, R.M.; Proud, F.J.; Sorensen, S.H.; Elwood, C.M.; Petrie, G.; Matthewman, L.A.; Forster-van Hijfte, M.A.; Boswood, A.; Entwistle, M. and Fensome, R.H. (1996):* Intestinal permeability and function in dogs with small intestinal bacterial overgrowth. *Journal of Small Animal Practice*, 37; 428-434.
- Sparkes A.H.; Papasouliotis, K.; Sunvold, G.; Werrett, G.; Clarke, C.; Jones, M.; Gruffydd-Jones, T.J. and Reinhart, G. (1998):* Bacterial flora in the duodenum of healthy cats, and effect of dietary supplementation with fructo-oligosaccharide. *American Journal of Veterinary Research*, 59; 431-435.
- Stokes, C.R.; Newby, T.J. and Bourne, F.J. (1983):* The influence of oral immunization on local and systemic immune responses to heterologous antigens. *Clinical and Experimental Immunology*, 52; 399-406.
- Waly, N.E.; Stokes, C.R.; Gruffydd-Jones, T.J. and Day, M.J. (2001):* The distribution of leukocyte subsets in the small intestine of healthy cats. *Journal of Comparative Pathology*, 124; 172-182.
- Willard, M.D.; Simpson, R.B.; Fossum, T.W.; Cohen, N.D.; Delles, E.K.; Kolp, D.L.; Carey, D.P. and Reinhart, G.A. (1994):* Characterization of naturally developing small intestinal bacterial overgrowth in 16 German shepherd dogs. *Journal of American Veterinary Medical Association*, 204; 1201-1206.