

Original Article

Frequency of Oral and Para-Oral Lymphomas in Cairo Governorate: A Multi-Center Retrospective Study

Madiha Ashoub^{1*}, Mona Wali², Nada Nour Eldin², Khaled Keraa³, Eman El Desouky⁴, Marwa Mokbel¹

¹ Oral Pathology Department, Faculty of Oral and Dental Medicine, Misr International University, Cairo, Egypt

² Oral and Maxillofacial Pathology Department, Faculty of Dentistry, Cairo University, Cairo, Egypt

³ Biostatistician, Faculty of Oral and Dental Medicine, Misr International University, Cairo, Egypt

⁴ Department of Epidemiology and Biostatistics, National Cancer Institute, Cairo University, Cairo, Egypt

Email: madiha.nabil@miuegypt.edu.eg

Submitted: 5-5-2022

Accepted: 16-7-2022

Abstract

Aim: To describe the frequency of oral and para-oral lymphomas in Cairo governorate's educational hospitals and institutions between 2010 and 2019.

Methods: Histopathological reports of patients diagnosed with oral and para-oral lymphomas from 2010 to 2019 were retrospectively retrieved from archives of educational hospitals and institutions in Cairo governorate. Data regarding age, gender, site and diagnosis was collected and analyzed using descriptive statistical methods.

Results: 362 cases of lymphomas were found which constituted 2.86 % of oral and para-oral lesions. The mean age of patients was 54 (standard deviation 18.5), the median age was 56 (range 3.5-92 years). Tonsil was the most common site, followed by parotid gland. Intra-oral affection was less frequent, with the hard palate being the most common intra-oral site. Non-Hodgkin lymphoma was more common than Hodgkin lymphoma. Diffuse large B-cell lymphoma was the most prevalent histologic subtype.

Conclusions: The findings of the current study were consistent with majority of other studies held in different geographic regions. Since there were no previous studies that described the epidemiology of oral and para-oral lymphomas in Egypt, this study serves as a stepping-stone towards understanding their prevalence in Egypt.

Keywords: Lymphoma, Oral cavity, Oropharynx, Salivary glands, Epidemiology

Introduction:

Lymphoma is a diverse group of malignant neoplasms, caused by abnormal proliferation of lymphoid cells or their precursors. It is considered the third most common malignancy worldwide (Storck et al., 2019). There has been a significant rise in the

overall incidence of lymphoma, including the number of lymphoma cases occurring in the head and neck area (Bojanowska-Pozniak et al., 2017). Globally, lymphoma is considered the third most frequently encountered malignant neoplasm in oral and para-oral sites, after squamous cell carcinoma and salivary gland

malignancy (Triantafillidou et al., 2012). According to WHO, lymphoma constitutes 3.5 % of oral cavity malignancies and 1.7-6 % of salivary gland tumors (El-Naggar et al., 2017).

Despite the rare occurrence of lymphoma in the oral and para-oral regions, it is very important for clinicians, oral surgeons and pathologists to be aware of its clinicopathological features as well as its distribution among different populations (Sirsath et al., 2014; Storck et al., 2019). This is because oral lymphoma may clinically and radiographically resemble other oral lesions such as odontogenic infections or other oral malignancies (Walter et al., 2015). Thus, lack of awareness of epidemiological characteristics of oral and para-oral lymphoma can often lead to low index of clinical suspicion which may lead to misdiagnosis, improper treatment and worse prognosis (Kusuke, Custodio and de Sousa, 2019; Sirsath et al., 2014).

Not only is it important to determine the prevalence of oral and para-oral lymphomas, but it is also relevant to identify the different subtypes of lymphoma present in these sites. This is because lymphoma constitutes a heterogenous group of malignant neoplasms with a wide range of behavioral spectrum ranging from relatively indolent to highly aggressive (Silva et al., 2016). Besides, information regarding the different anatomic sites involved, age and gender predilection is very beneficial in order to build up relevant differential diagnoses when similar lesions are encountered (Hart et al., 2004; Guevara-Canales et al., 2011). Therefore, there is a need for epidemiological studies that describe the prevalence, distribution and characteristics of lymphomas occurring in oral and para-oral sites. Unfortunately, there is a sparsity of this type of studies in literature, especially in developing countries (Alli and Meer, 2017).

Statistics have shown that incidence of lymphoma has been exceptionally high in Egypt, compared to other Middle Eastern countries (Herzog et al., 2012). According to

Global Cancer Observatory results (GLOBOCAN), non-Hodgkin lymphoma was the 4th most incident cancer in Egypt in 2020 (Ferlay et al., 2020). However, there are no documented studies on the prevalence of lymphoma in oral and para-oral sites in Egypt. Hence, the main aim of this study was to describe the frequency of oral and para-oral lymphomas in educational hospitals and institutions in Cairo governorate. Besides, the results of the current study were compared with those of previously published studies in other populations.

Subjects and Methods:

The study conducted was a multicenter observational, descriptive, retrospective study of patients' histopathological records. Histopathological reports of patients diagnosed with oral and para-oral lymphomas within the 10-year period from 2010 to 2019 were retrospectively retrieved from archives of the following educational hospitals and institutions in Cairo governorate: Cairo University, Faculty of Dentistry, Oral and Maxillofacial Pathology Department; Cairo University, Faculty of Medicine, General Pathology Department; Ain Shams University, Faculty of Dentistry, Oral Pathology Department; Al-Azhar University, El-Sayed Galal Hospital; Ahmed Maher Teaching Hospital and National Cancer Institute.

Inclusion criteria included all age groups and genders; lesions occurring in oral cavity, oropharynx and salivary glands and all histological subtypes of Hodgkin and non-Hodgkin lymphoma. Exclusion criteria, however, involved hematolymphoid tumours other than lymphoma and cases of lymphoma diagnosed without histopathological proof.

The histopathological reports of patients that met the inclusion and exclusion criteria were either checked manually or were electronically retrieved from digital databases using appropriate search terms. Data regarding

age, gender, site and diagnosis was collected and recorded from the histopathological reports. The diagnoses were reviewed according to the most recent 2017 WHO classification of head and neck tumors, which coincides with the 2017 WHO classification of tumors of hematopoietic and lymphoid tissues. Inaccurately classified lesions were reclassified, based on histologic description and immunohistochemical results recorded in histopathology reports.

Based on the most recent 2017 WHO classification, lymphoma was divided into Hodgkin lymphoma (HL) or non-Hodgkin lymphoma (NHL). Non-Hodgkin lymphoma was further classified into B-cell, T-cell or NK cell types. On the other hand, Hodgkin lymphoma was divided into classical Hodgkin lymphoma (cHL) or nodular lymphocyte predominant Hodgkin lymphoma (NLPHL).

Statistical analysis:

The data gathered was entered into Microsoft Excel spreadsheets, and transferred to IBM SPSS Statistics for Windows, Version 23.0. Armonk, NY: IBM Corp. statistical software program for analysis. Qualitative data were presented as frequencies and percentages. Quantitative data were presented as mean, standard deviation (SD), median, range and 95% Confidence Interval (95% CI).

Ethical considerations:

The study was approved by The Research Ethics Committee at Faculty of Dentistry, Cairo University (No. 16 12 19). Patients' names included in the histopathological reports were kept confidential and were not used in this study.

Results:

There were 362 cases of oral and para-oral lymphomas out of 12662 oral and para-oral lesions diagnosed in the study centers in the ten-year period (2010-2019), giving an overall frequency of (2.86 %). Non-Hodgkin lymphoma (NHL) was the more common type

(n=326, 90.1%), compared to Hodgkin lymphoma (HL) (n=15, 4.1%). 21 lesions (5.8%) were diagnosed as lymphoma without specifying the type (lymphoma, NOS=lymphoma, not otherwise specified).

The most common type of NHL was B-cell type (n=291, 89.3%) while T-cell/NK-cell type represented (n=13, 4%) of NHL. 22 (6.7%) were diagnosed as NHL without specifying the immunophenotype of neoplastic cells (NHL, NOS=non-Hodgkin lymphoma, not otherwise specified). Specific histologic subtypes were mentioned in only 279 cases of non-Hodgkin lymphomas. The most common histologic subtype of NHL was DLBCL (68.5 %) followed by MALT lymphoma (16.5%), then Burkitt lymphoma (3.9 %). The least common subtypes were plasmablastic lymphoma and T-lymphoblastic lymphoma (0.4 % each). Table (1) shows the distribution of all the histologic subtypes of NHL.

As for Hodgkin lymphoma, the specific histologic subtype was recorded in 13 cases, while two cases were diagnosed as HL without specifying the type (HL, NOS=Hodgkin lymphoma, not otherwise specified). The most common type was classical HL (92.3 %) while nodular lymphocyte predominant HL (NLPHL) represented (7.7%) of HL, as shown in Table (1).

Para-oral sites were more commonly affected by lymphomas (n=264, 72.9%), compared to intra-oral sites which represented (n=97, 26.8%) of the study sample, as demonstrated in Figure (1). One lesion (0.3%) had non-specified site. Overall, the most commonly affected specific site was the palatine tonsils (38.5 %), followed by parotid gland (19.4 %). The most common intra-oral site was the hard palate (3.9 %), followed by maxilla and mandible (3.6 % each). Floor of the mouth was the least common site (0.3 %). 35 lesions (9.7 %) were diagnosed as being from the oral cavity without specifying the site (oral cavity,

NOS). Figure (2) shows the distribution of lymphomas among all specific oral and para-oral sites.

Age was recorded in 344 cases of oral and para-oral lymphomas, while 18 cases had undetermined age. The mean age of oral and para-oral lymphomas was 54 (SD 18.5), the median age was 56 (age range 3.5-92 years). Table (2) and Figure (3) show the distribution of oral and para-oral lymphomas among different age groups.

The age group with the highest peak was (51-60 years), while the lowest percentage of cases was found in the age group (<10 years). Gender was recorded in 351 cases of oral and para-oral lymphomas, while 11 cases had unspecified gender. There were slightly more females (n=179, 51 %) affected by oral and para-oral lymphomas than males (n=172, 49 %).

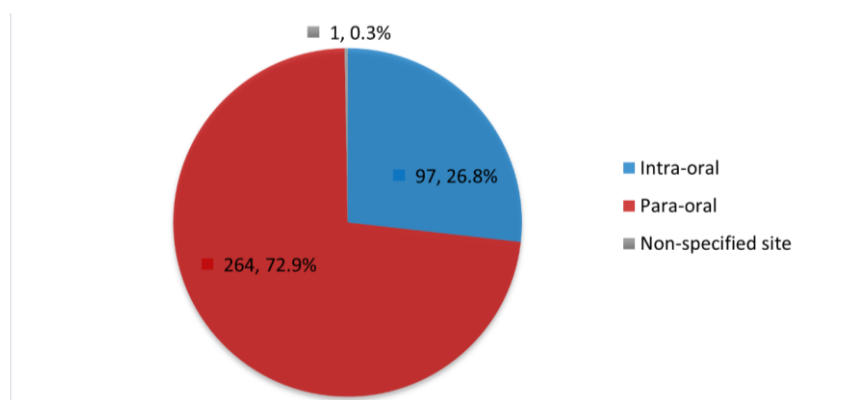


Figure (1): Pie chart showing frequencies and percentages of lymphomas in intra-oral versus para-oral sites

Table (1): Frequencies (n) and percentages (%) for all histologic subtypes of non-Hodgkin and Hodgkin lymphomas (excluding non-specified types)

		Histologic subtypes	n	%
B-cell type (n=270)		DLBCL	191	68.5
		MALT lymphoma	46	16.5
		Burkitt lymphoma	11	3.9
		Follicular lymphoma	7	2.5
		CLL/SLL	7	2.5
Non-Hodgkin lymphoma (n=279)		T-cell/histiocyte rich B-cell lymphoma	3	1.1
		Mantle cell lymphoma	2	0.7
		B-lymphoblastic lymphoma	2	0.7
		Plasmablastic lymphoma	1	0.4
		T-cell/NK-cell type (n=9)	Anaplastic large T-cell lymphoma	4
		Extra-nodal NK/T-cell lymphoma	2	0.7
		Peripheral T-cell lymphoma	2	0.7
		T-lymphoblastic lymphoma	1	0.4
Hodgkin lymphoma (n=13)		Classical Hodgkin lymphoma	12	92.3
		NLPHL	1	7.7

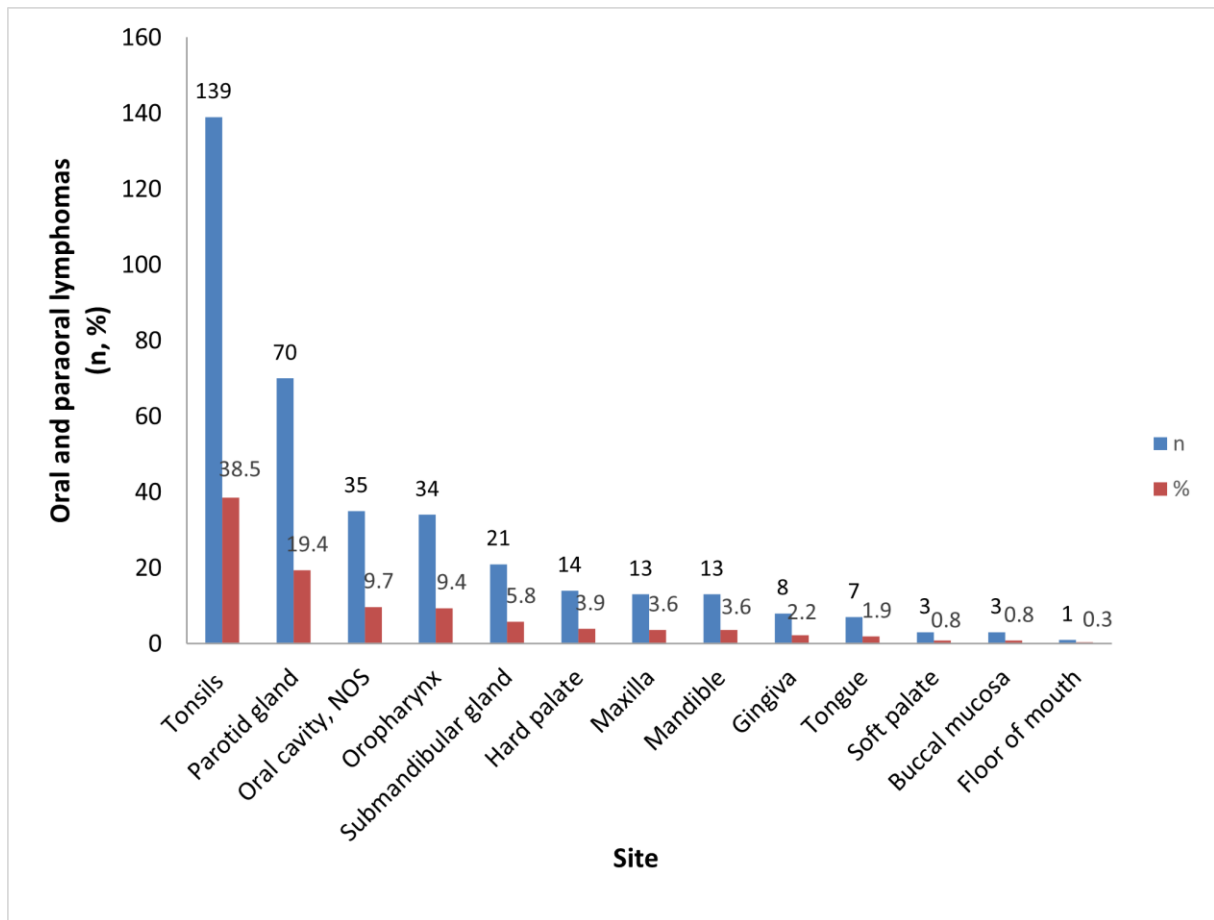


Figure (2): Bar chart showing distribution of lymphomas among all oral and para-oral sites

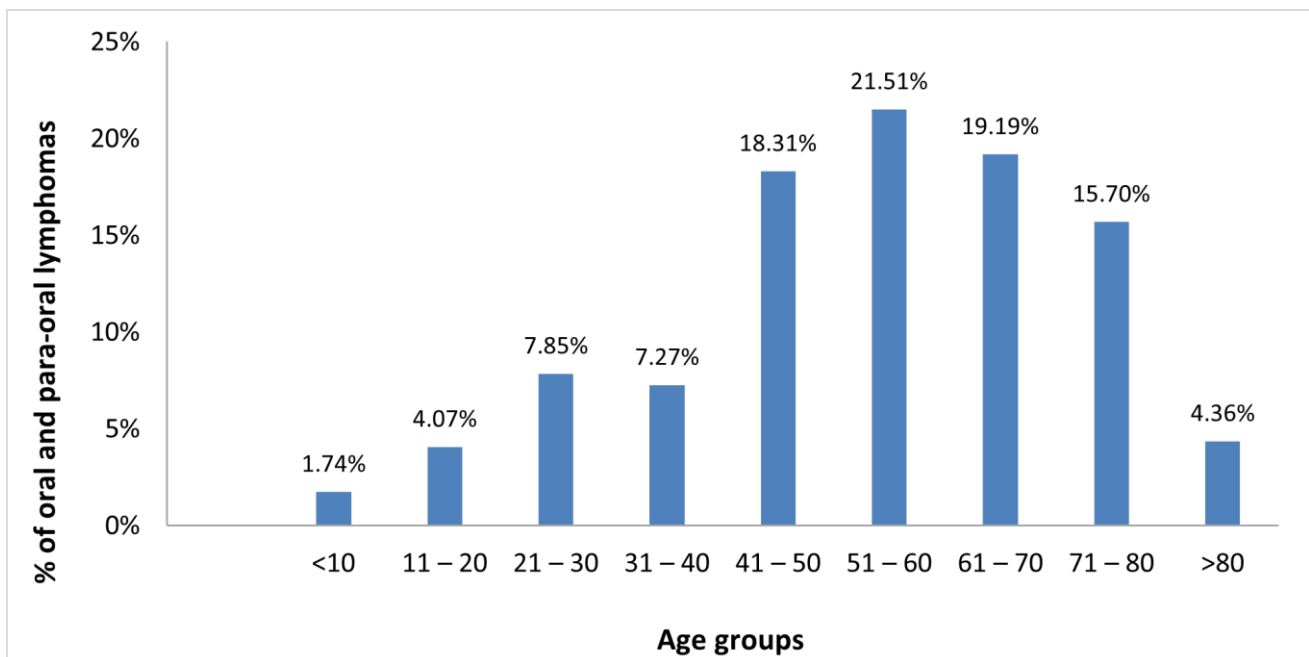


Figure (3): Bar chart illustrating the distribution of oral and para-oral lymphomas among age groups

Table (2): Frequencies (n) and percentages (%) for lymphomas in different age groups (n = 344 excluding undetermined age)

Age group	n	%
<10 y	6	1.74%
11 – 20 y	14	4.07%
21 – 30 y	27	7.85%
31 – 40 y	25	7.27%
41 – 50 y	63	18.31%
51 – 60 y	74	21.51%
61 – 70 y	66	19.19%
71 – 80 y	54	15.70%
>80 y	15	4.36%

Discussion:

The current study described the frequency and distribution of oral and para-oral lymphomas diagnosed within a ten-year period (2010 to 2019) in Cairo governorate's educational hospitals and institutions. The main aim of the study was to contribute in filling the research gap that exists as epidemiology of oral and para-oral lymphomas has not yet been reported in Egypt.

Results revealed that in the ten-year period from 2010 till 2019, a total of 12662

Non-Hodgkin lymphoma was the more common type (90.1%), compared to HL which represented (4.1%) of the study sample. These results coincide with the findings of other studies conducted on oral and para-oral lymphomas in various parts of Canada, UK, Brazil, Iran and France. These studies even reported slightly higher proportions of NHL than our study, ranging from 94.5 to 100 % of all included cases (Guevara-Canales et al., 2013; Bahramian et al., 2019; Epstein et al., 2001; Akbari et al., 2015; Picard et al., 2015; Hart et al., 2004). The higher frequency of NHL in oral and para-oral sites can be explained by the fact that NHL can frequently occur in both nodal and extra-nodal sites, unlike HL which has a propensity for nodal sites.

In the preset study, most of the NHL

lesions occurring in oral and para-oral sites were archived in the pathology units of six of Cairo governorate's educational hospitals and institutions. Out of these 12662 cases, 362 were histologically diagnosed as lymphomas, which constituted 2.86 % of the total number of oral and para-oral lesions. Other than these 362 oral and para-oral lymphoma cases, 38 cases were recorded as suggestive for lymphoma. Accordingly, these cases were excluded from the study due to the lack of enough histological or immunohistochemical evidence to support a definitive final diagnosis.

cases were of B-cell type (89.3%) while T-cell/ NK-cell type represented 4% of NHL. These findings are consistent with other studies held in different parts of USA, The Netherlands, Argentina, Japan, Malaysia, Iran and Kenya (Kemp et al., 2008; Tsabedze, 2019; Keszler et al., 2008; van der Waal et al., 2005; Solomides et al., 2002; Akbari et al., 2015; Ramanathan et al., 2014; Iguchi et al., 2012).

Even though all studies on oral and para-oral lymphomas showed a higher proportion of B-cell NHL compared to T-cell/NK-cell NHL, the percentages of T-cell lymphomas reported by Iguchi et al (2012) and Ramanathan et al. (2014) were noticeably higher than in our study. Iguchi et al (2012) reported that 18.8 % of oral and para-oral NHL diagnosed in a single center in Japan were of T-

cell type while Ramanathan et al. (2014) found that 27.8 % of oral and para-oral NHL diagnosed in a center in Malaysia were of T-cell type. The geographic setting of these two studies explains the higher percentage of T-cell lymphomas, as the literature shows that Asian countries have more prevalence of NK/T-cell lymphomas compared to countries in other continents (Iguchi et al., 2012; Ramanathan et al., 2014).

Results showed that the most common specific histologic subtype of NHL was DLBCL, constituting 68.5 % of cases. The predominance of DLBCL in oral and para-oral sites in our study is in accordance with the majority of epidemiological studies held in different geographic regions such as Canada, USA, The Netherlands, Iran, Argentina, Poland and Brazil. In these studies, DLBCL was reported to constitute from 42 % to 74.2 % of NHL occurring in oral and para-oral region (Kemp et al., 2008; Corti et al., 2014; Leong, Fernandes and Mock, 2001; Niemiec et al., 2017; Kusuke, Custodio and de Sousa, 2019; Akbari et al., 2015; van der Waal et al., 2005; Etemad-Moghadam et al., 2010; Solomides et al., 2002; Shamloo et al., 2017; Basirat, Rabiei and Bashardoust, 2016).

On the other hand, plasmablastic lymphoma was the most common histologic subtype (31.6 %) in a study conducted by Alli and Meer (2017) on cases of head and neck lymphomas in South Africa. In contrast, plasmablastic lymphoma was the least common subtype of NHL in our study, with only 0.4 % of cases. The high frequency of plasmablastic lymphoma in the study by Alli and Meer (2017) could be justified by the extremely high incidence of AIDS in South Africa (Alli and Meer, 2017). Plasmablastic lymphoma is considered the number one type of lymphoma to be associated with HIV-related immunosuppression (Corti et al., 2015).

Our study showed that MALT lymphoma was the second most common histologic subtype of NHL (16.5 %). Other

studies on oral and para-oral lymphomas held in USA, Greece and France also reported MALT lymphoma as the second most common NHL, following DLBCL (Kolokotronis et al., 2005; Solomides et al., 2002; Picard et al., 2015). However, in another study conducted by Triantafillidou et al. (2012) in Greece, MALT lymphoma was reported as the most common subtype of oral and maxillofacial NHL. It should also be mentioned that Triantafillidou et al. (2012) reported salivary glands as the most common site for oral and maxillofacial lymphomas. Since MALT lymphoma has a predilection for salivary glands, this explains the higher frequency of MALT lymphoma in that study.

Regarding HL, the most common subtype in the current study was cHL (92.3 %) while NLPHL represented (7.7 %) of HL. These findings are in line with results of similar work conducted on head and neck lymphomas by Basirat, Rabiei and Bashardoust (2016) in Iran and Tsabedze (2019) in Kenya. The predominance of cHL in oral and para-oral sites correlates with its predominance in other parts of the body; cHL is generally more common than NLPHL, the former constituting 90-95 % of all HL cases worldwide (Piris, Medeiros and Chang, 2020; Silva et al., 2016).

A wide age range of (3.5-92 years) was found in the current study, which highlights how oral and para-oral lymphomas can occur in any age category. Only three other studies were found in literature which presented an even wider age range. The study conducted by Etemad-Moghadam et al. (2010) in Iran reported an age range of (7 months-98 years) while Alli and Meer (2017) found an age range of (2-100 years) in their study that was carried out in South Africa. Furthermore, a recent study carried out by de Arruda et al. (2021) in Brazil recorded an age range of (2-92 years). As for gender, no certain gender predilection for oral and para-oral lymphomas was observed in the current study, as 179 cases were females (51 %) while 172 cases were males (49 %).

Regarding site of occurrence, para-oral involvement (72.9 %) was higher than intra-oral affection (26.8 %). This is in agreement with the majority of other similar studies that were held in Canada, UK, Iran, Taiwan, Japan, Greece and France. These studies all reported more cases of extra-oral lymphomas than intra-oral ones (Triantafillidou et al., 2012; Epstein et al., 2001; Akbari et al., 2015; Etemad-Moghadam et al., 2010; Picard et al., 2015; Chi et al., 2012; Hart et al., 2004; Iguchi et al., 2012).

On the other hand, a study conducted by Corti et al. (2014) in Argentina reported more intra-oral involvement of lymphomas. This could be explained by the fact that that study was exclusively conducted on HIV-positive patients diagnosed with head and neck NHL. HIV infection is a well-recognized risk factor for NHL in general, but especially for cases occurring inside the oral cavity (Singh et al., 2020).

Out of all oral and para-oral sites included in the current study, the tonsil was the most commonly affected site (38.5 %), followed by the parotid gland (19.4 %). These findings coincide with the results of previously published studies held in Canada, UK, Brazil and Iran (Guevara-Canales et al., 2013; Bahramian et al., 2019; Epstein et al., 2001; Hart et al., 2004). Anatomically, the tonsils are non-capsulated primary lymphoid organs that naturally harbor lymphoid cells, which explains the high prevalence of lymphomas in this area. The parotid gland is usually the most commonly affected salivary gland by lymphoma which is explained by the great number of peri-parotid and intra-parotid lymph nodes, from which the lymphoid neoplastic cells originate.

Even though the present study reported more para-oral involvement of lymphomas, intra-oral affection was still also observed. The most common intra-oral site was the hard palate, followed by mandible and maxilla while the floor of the mouth was the least common

site. Affection of other specific intra-oral sites such as gingiva, tongue, soft palate and buccal mucosa was also noted. Other studies held in Canada, Greece, Brazil and Iran have also recorded the hard palate as the most common intra-oral site to be affected by lymphomas (Guevara-Canales et al., 2013; Kolokotronis et al., 2005; Bahramian et al., 2019; Leong, Fernandes and Mock, 2001; de Arruda et al., 2021). A plausible explanation for the palate being the most common intra-oral site is due to the anatomical position of the palate which is in close vicinity to the tonsils (Kusuke, Custodio and de Sousa, 2019). Conversely, fewer studies have found the gingiva to be the most common intra-oral site for lymphoma, such as studies conducted in Argentina and Brazil (Keszler et al., 2008; Kusuke, Custodio and de Sousa, 2019).

Based on all the previously mentioned results, this research managed to describe the frequency as well as the clinicopathological features of oral and para-oral lymphomas in Cairo governorate's educational hospitals and institutions. Nonetheless, several limitations were encountered throughout the data collection and analysis processes. Owing to the retrospective nature of the study, the issue of missing data was inevitably faced. Besides, some lesions were diagnosed as suggestive for lymphoma, without histological or immunohistochemical verification of diagnosis and were therefore excluded from the study.

Lack of specific information regarding the affected intra-oral sites was also encountered in some places. Consequently, these non-specified intra-oral sites were referred to as oral cavity, NOS. Last but not least, the descriptive nature of the study did not allow for analysis of the effects of possible etiologic factors, such as certain viral infections or auto-immune diseases, on the prevalence of lymphomas. However, this should not negate the importance of descriptive epidemiological studies as they are considered the base upon which analytical studies are built.

Conclusions:

For the most part, the results of the current study compare well with studies conducted in other populations. However, some differences were noticed in the patterns of distribution of different types and sites of oral and para-oral lymphomas among different geographic regions. These variations highlight the importance of conducting further similar epidemiologic studies in different parts of the world. Only with the results of such epidemiologic studies can we understand and analyze the possible etiologic and environmental factors that lead to variations in lymphoma distribution among different populations.

Conflict of Interest:

All authors declare that they have no conflict of interest.

Source of Funding:

This research did not receive any specific grant from funding agencies in the public, commercial, or not-for-profit sectors.

References:

1. Akbari, M. E., Bastani, Z., Mokhtari, S. & Atarbashi Moghadam, S. 2015. 'Oral Lymphoma Prevalence in Iranian Population: A Multicenter Retrospective Study'. *Iran J Cancer Prev*, 8(6), pp e4124.
2. Alli, N. & Meer, S. 2017. 'Head and neck lymphomas: A 20-year review in an Oral Pathology Unit, Johannesburg, South Africa, a country with the highest global incidence of HIV/AIDS'. *Oral Oncol*, 67, pp 17-23.
3. Bahramian, A., Halimi, M., Kafili, M., Behroozian, A., Soleimani, S., Razi, T. & Emamverdizadeh, P. 2019. 'THE PREVALENCE OF ORAL LYMPHOMA AND ITS RELATION WITH TYPE OF LYMPHOMA, AGE, GENDER AND LOCATION IN PATIENTS REFERRED TO TABRIZ IMAM REZA HOSPITAL'. *URMIA MED J*, 29(10), pp 698-706.
4. Basirat, M., Rabiei, M. & Bashardoust, N. 2016. 'Incidence of Head and Neck Lymphoma in Guilan Province, Iran'. *Asian Pac J Cancer Prev*, 17(S3), pp 1-4.
5. Bojanowska-Pozniak, K., Nurkowska, M., Danilewicz, M. & Pietruszewska, W. 2017. 'Clinical manifestation of malignant lymphomas of the head and neck region'. *Otolaryngol Pol*, 71(6), pp 14-21.
6. Chi, H. S., Lee, K. W., Chiang, F. Y., Tai, C. F., Wang, L. F., Yang, S. F., Lin, S. F. & Kuo, W. R. 2012. 'Head and neck extranodal lymphoma in a single institute: a 17-year retrospective analysis'. *Kaohsiung J Med Sci*, 28(8), pp 435-441.
7. Corti, M., Minue, G., Campitelli, A., Narbaitz, M. & Gilardi, L. 2015. 'An Aggressive Plasmablastic Lymphoma of the Oral Cavity as Primary Manifestation of Acquired Immunodeficiency Syndrome: Case Report and Literature Review'. *Int Arch Otorhinolaryngol*, 19(4), pp 354-358.
8. Corti, M., Villafane, M., Bistmans, A., Narbaitz, M. & Gilardi, L. 2014. 'Primary extranodal non-hodgkin lymphoma of the head and neck in patients with acquired immunodeficiency syndrome: a clinicopathologic study of 24 patients in a single hospital of infectious diseases in Argentina'. *Int Arch Otorhinolaryngol*, 18(3), pp 260-265.
9. de Arruda, J. A. A., Schuch, L. F., Conte Neto, N., de Souza, L. L., Rodrigues-Fernandes, C. I., Abreu, L. G., Soares, C. D., de Carvalho, M. G. F., Agostini, M., de Andrade, B. A. B., Romañach, M. J., Zanella, V. G., Barra, M. B., Martins, M. D., Souto, G. R., Etges, A., Pontes, H. A. R., Pontes, F. S. C.,

- Vargas, P. A., de Almeida, O. P., Santos-Silva, A. R., Lopes, M. A., Pires, F. R., Gomez, R. S., Fonseca, F. P. & Mesquita, R. A. 2021. 'Oral and oropharyngeal lymphomas: A multi-institutional collaborative study'. *J Oral Pathol Med*, 50(6), pp 603-612.
10. El-Naggar, A. K., Chan, J. K. C., Grandis, J. R., Takata, T. & Slootweg, P. J. 2017. *WHO classification of head and neck tumours, 4th ed.*, pp. 141-144, International Agency for Research on Cancer, Lyon, France
11. Epstein, J. B., Epstein, J. D., Le, N. D. & Gorsky, M. 2001. 'Characteristics of oral and paraoral malignant lymphoma: a population-based review of 361 cases'. *Oral Surg Oral Med Oral Pathol Oral Radiol Endod*, 92(5), pp 519-525.
12. Etemad-Moghadam, S., Tirgary, F., Keshavarz, S. & Alaeddini, M. 2010. 'Head and neck non-Hodgkin's lymphoma: a 20-year demographic study of 381 cases'. *Int J Oral Maxillofac Surg*, 39(9), pp 869-872.
13. Ferlay, J., Ervik, M., Lam, F., Colombet, M., Mery, L., Piñeros, M., Znaor, A., Soerjomataram, I. & Bray, F. 2020. *Global Cancer Observatory: Cancer Today* [Online]. Lyon, France: International Agency for Research on Cancer. Available: <https://gco.iarc.fr/today> [Accessed].
14. Guevara-Canales, J. O., Morales-Vadillo, R., de Faria, P. E., Sacsquispe-Contreras, S. J., Leite, F. P. & Chaves, M. G. 2011. 'Systematic review of lymphoma in oral cavity and maxillofacial region'. *Acta Odontol Latinoam*, 24(3), pp 245-250.
15. Guevara-Canales, J. O., Morales-Vadillo, R., Sacsquispe-Contreras, S. J., Barrionuevo-Cornejo, C., Montes-Gil, J., Cava-Vergiu, C. E., Soares, F. A., Chaves-Netto, H. D. M. & Chaves, M. G. A. M. 2013. 'Malignant lymphoma of the oral cavity and the maxillofacial region: overall survival prognostic factors'. *Med Oral Patol Oral Cir Bucal*, 18(4), pp e619-626.
16. Hart, S., Horsman, J. M., Radstone, C. R., Hancock, H., Goepel, J. R. & Hancock, B. W. 2004. 'Localised extranodal lymphoma of the head and neck: the Sheffield Lymphoma Group experience (1971-2000)'. *Clin Oncol (R Coll Radiol)*, 16(3), pp 186-192.
17. Herzog, C. M., Dey, S., Hablas, A., Khaled, H. M., Seifeldin, I. A., Ramadan, M., El-Hamzawy, H., Wilson, M. L. & Soliman, A. S. 2012. 'Geographic distribution of hematopoietic cancers in the Nile delta of Egypt'. *Ann Oncol*, 23(10), pp 2748-2755.
18. Iguchi, H., Wada, T., Matsushita, N., Oishi, M. & Yamane, H. 2012. 'Anatomic distribution of hematolymphoid malignancies in the head and neck: 7 years of experience with 122 patients in a single institution'. *Acta Otolaryngol*, 132(11), pp 1224-1231.
19. Kemp, S., Gallagher, G., Kabani, S., Noonan, V. & O'Hara, C. 2008. 'Oral non-Hodgkin's lymphoma: review of the literature and World Health Organization classification with reference to 40 cases'. *Oral Surg Oral Med Oral Pathol Oral Radiol Endod*, 105(2), pp 194-201.
20. Keszler, A., Piloni, M., Paparella, M., Soler, M., Ron, P. & Narbaitz, M. 2008. 'Extranodal oral non-Hodgkin's lymphomas. A retrospective study of 40 cases in Argentina'. *Acta Odontol Latinoam*, 21(1), pp 43-48.
21. Kolokotronis, A., Konstantinou, N., Christakis, I., Papadimitriou, P., Matiakis, A., Zaraboukas, T. & Antoniadis, D. 2005. 'Localized B-cell non-Hodgkin's lymphoma of oral cavity and maxillofacial region: a clinical

- study'. *Oral Surg Oral Med Oral Pathol Oral Radiol Endod*, 99(3), pp 303-310.
22. Kusuke, N., Custodio, M. & de Sousa, S. 2019. 'Oral lesion as the primary diagnosis of non-Hodgkin's lymphoma: a 20-year experience from an oral pathology service and review of the literature'. *Eur Arch Otorhinolaryngol*, 276(10), pp 2873-2879.
23. Leong, I. T., Fernandes, B. J. & Mock, D. 2001. 'Epstein-Barr virus detection in non-Hodgkin's lymphoma of the oral cavity: an immunocytochemical and in situ hybridization study'. *Oral Surg Oral Med Oral Pathol Oral Radiol Endod*, 92(2), pp 184-193.
24. Niemiec, M., Stryjewska-Makuch, G., Janik, M., Kolebacz, B., Lisowska, G. & Scierski, W. 2017. 'Head and neck lymphomas - a retrospective ten-year observation'. *Contemp Oncol (Pozn)*, 21(1), pp 66-69.
25. Picard, A., Cardinne, C., Denoux, Y., Wagner, I., Chabolle, F. & Bach, C. A. 2015. 'Extranodal lymphoma of the head and neck: a 67-case series'. *Eur Ann Otorhinolaryngol Head Neck Dis*, 132(2), pp 71-75.
26. Piris, M. A., Medeiros, L. J. & Chang, K. C. 2020. 'Hodgkin lymphoma: a review of pathological features and recent advances in pathogenesis'. *Pathology*, 52(1), pp 154-165.
27. Ramanathan, A., Mahmoud, H. A., Hui, L. P., Mei, N. Y., Valliappan, V. & Zain, R. B. 2014. 'Oral extranodal non Hodgkin's lymphoma: series of forty two cases in Malaysia'. *Asian Pac J Cancer Prev*, 15(4), pp 1633-1637.
28. Shamloo, N., Ghannadan, A., Jafari, M., Ahmadi, S., Mortazavi, H. & Baharvand, M. 2017. 'Head and Neck Lymphoma in an Iranian Population'. *Iran. J. Otorhinolaryngol.*, 29(94), pp 261-267.
29. Silva, T. D., Ferreira, C. B., Leite, G. B., de Menezes Pontes, J. R. & Antunes, H. S. 2016. 'Oral manifestations of lymphoma: a systematic review'. *Ecancermedicalscience*, 10, pp 665.
30. Singh, R., Shaik, S., Negi, B. S., Rajguru, J. P., Patil, P. B., Parihar, A. S. & Sharma, U. 2020. 'Non-Hodgkin's lymphoma: A review'. *J Family Med Prim Care*, 9(4), pp 1834-1840.
31. Sirsath, N. T., Lakshmaiah, K. C., Das, U., Lokanatha, D., Chennagiri, S. P. & Ramarao, C. 2014. 'Primary extranodal non-Hodgkin's lymphoma of oral cavity--a single centre retrospective study'. *J Cancer Res Ther*, 10(4), pp 945-950.
32. Solomides, C. C., Miller, A. S., Christman, R. A., Talwar, J. & Simpkins, H. 2002. 'Lymphomas of the oral cavity: histology, immunologic type, and incidence of Epstein-Barr virus infection'. *Hum Pathol*, 33(2), pp 153-157.
33. Storck, K., Brandstetter, M., Keller, U. & Knopf, A. 2019. 'Clinical presentation and characteristics of lymphoma in the head and neck region'. *Head Face Med*, 15(1), pp 1.
34. Triantafillidou, K., Dimitrakopoulos, J., Iordanidis, F. & Gkagkalis, A. 2012. 'Extranodal non-hodgkin lymphomas of the oral cavity and maxillofacial region: a clinical study of 58 cases and review of the literature'. *J Oral Maxillofac Surg*, 70(12), pp 2776-2785.
35. Tsabedze, V. N. 2019. *Clinical Profile And Histological Characteristics Of Head And Neck Lymphomas In Patients Seen At Two Referral Centres In Nairobi, Kenya*. Master's thesis, University Of Nairobi, Nairobi, Kenya. <http://erepository.uonbi.ac.ke/handle/11295/109612>
36. van der Waal, R. I., Huijgens, P. C., van der Valk, P. & van der Waal, I. 2005.

'Characteristics of 40 primary extranodal non-Hodgkin lymphomas of the oral cavity in perspective of the new WHO classification and the International Prognostic Index'. *Int J Oral Maxillofac Surg*, 34(4), pp 391-395.

37. Walter, C., Ziebart, T., Sagheb, K., Rahimi-Nedjat, R. K., Manz, A. & Hess, G. 2015. 'Malignant lymphomas in the head and neck region--a retrospective, single-center study over 41 years'. *Int J Med Sci*, 12(2), pp 141-145.