

Trans Vaginal Assessment of Cesarean Scar Niche and its Complications in Non-Pregnant Women

Hesham Ahmed Elsaid Alassi^{1,*} M.B.B.Ch, Mohamed Hesham Hassan Anwar¹ MD,
Ibrahem Ramadan Al Sawy¹ MD.

*Corresponding Author:

Hesham Ahmed Elsaid Alassi

helassi89@gmail.com

Received for publication March 10, 2022; Accepted July 30, 2022;
Published online July 30, 2022.

doi: 10.21608/aimj.2022.152405.2054

Citation: Hesham A. Mohamed H. Ibrahem R. . Trans Vaginal Assessment of Cesarean Scar Niche and its Complications in Non-Pregnant Women. AIMJ. 2022; Vol3-Issue7: 56-63 .

¹Obstetrics and Gynecology Department, Faculty of Medicine, Al-Azhar University Damietta, Egypt.

ABSTRACT

Background: In a routine ultrasound examination of non-pregnant women with a previous caesarean section (CS), the prevalence of CS niche ranges from 24–70%. So it is a serious problem affecting large number of women.

Aim of the work: To assess post caesarean section scar defect (PCSD) by trans-vaginal ultrasound and evaluation of its related complications in non-pregnant women.

Patients and methods: The observational prospective cohort study was conducted on 200 women who fulfilled the inclusion and exclusion criteria were recruited and enrolled in the study after talking careful history, from all women attended Family planning 6 months or more after previous elective CS at Maternity Hospital of Bab Al Shaareya Hospital.

Results: Women with CS scar niche have significantly, higher uterine length, longer menstrual duration, higher PBAC score, more postmenstrual spotting days, more inter - menstrual spotting days and more dysmenorrhea. The most frequent SC scar niche shape found by transvaginal ultrasonography in the studied women is triangular shape. The complications mostly occur with niche subsequently as follow: Postmenopausal spotting, chronic pelvic pain, subfertility, dyspareunia, and dysuria.

Conclusion: Symptomatic niche incidence rate was 69.5% of women had a niche detected by TVS and by sonohysterography. Presence of the niche was associated with postmenstrual spotting, heaviness of menstruation and dysmenorrhea which were related to the niche width and depth.

Keywords: PCSD; trans-vaginal ultrasound; Non-Pregnant Women.

Disclosure: The authors have no financial interest to declare in relation to the content of this article. The Article Processing Charge was paid for by the authors.

Authorship: All authors have a substantial contribution to the article.

Copyright The Authors published by Al-Azhar University, Faculty of Medicine, Cairo, Egypt. Users have the right to read, download, copy, distribute, print, search, or link to the full texts of articles under the following conditions: Creative Commons Attribution-Share Alike 4.0 International Public License (CC BY-SA 4.0).

INTRODUCTION

Cesarean section is the commonest major operation worldwide, thus pay more attention to its rising incidence and long-term adverse sequelae.¹

In the last two decades, we become more aware to pay attention to complications after C.S like chronic pelvic pain, dyspareunia, postmenstrual spotting, dysmenorrhea, even infertility and in further pregnancy, such as scar pregnancy with life threatening bleeding, placenta previa, placenta accreta, increta or percreta and uterine rupture. Large defects are associated with more complications.^{2,3}

The results of abnormally adherent placenta are serious problems and they are responsible for 41-64% of all hysterectomies done during delivery. Sixty five percent (65%) of the cases have a previous caesarean section. Eighty percent (8%) of deaths of

mothers in the (U.K) due to placenta Previa.⁴

The PCSD (Post Cesarean Section Scar Defect) is a commonest complication after C.S; with different names in studies (pouch, niche, or isthmocoele). It is defined as dehiscence of focal area of uterine cavity at the site of the previous scar, which mostly a triangular shape defect in continuous with the endometrial cavity, which indents the anterior utero-cervical junction, form a small hollow of shelf in the anterior myometrium which faces into the endometrium cavity.⁵

Recently several studies found a relation between the niche and prolonged menstrual bleeding and postmenstrual spotting with a niche observed in 60 % of all women after a C.S. postmenstrual spotting is higher in patients with a niche (OR 3.1 [95 % CI,

1.5–6.3]).^{3,6,7}

This study aims to assess (PCSD) by trans-vaginal (U.S) and evaluation of its related complications in non-pregnant women.

PATIENTS AND METHODS

The current observational prospective cohort study was performed between January 2020 and February 2021 at the department of Obstetrics and Gynecology at Bab Al Shaareya Hospital Al Azhar University, Cairo, Egypt.

From all women attended Family planning 6 months or more after previous elective C.S at maternity hospital of Bab Al Shaareya hospital 200 women who fulfilled the inclusion and exclusion criteria were recruited and enrolled in the study after talking careful history

Inclusion Criteria: Maternal age between "18-35" years old (child bearing period), previous single or multiple C.S 6 months ago or more, no previous uterine surgery other than C.S (myomectomy, polypectomy, removal of septum), and presence of Post Cesarean Section Scar (PCSD).

Exclusion criteria: Pregnancy, using contraception, presence of uterine pathology (fibroid, polyp), presence of uterine anomaly (bicornuate uterus, arcuate uterus, unicornuate uterus, septate uterus), and Presence of other medical or gynecological disorders (D.M, thyroid dysfunction, hypertension, ovarian masses).

All 200 women under the study were asked about the following:

Detailed history including:

(I) Personal history (including lactation),past history (medical and surgical),obstetric history, contraceptive method.

(II) All women were asked to do pregnancy test (serum BHCG) before the ultrasound in order to exclude pregnancy.

(III) Then a detailed questionnaire was filled for uterine bleeding (premenstrual, intermenstrual, postmenstrual spotting), dysmenorrhea, and urinary symptoms.

Menstrual symptoms:

Women were asked about their menstrual cycle regular or not, duration of blood loss (including of brownish discharge just before and after the cycle), and duration of intermenstrual bleeding.

Dysmenorrhea:

In the same questionnaire women were asked about: (a) significant pain during menstruation. (b) Onset and offset of pain in relation to menstrual flow. (c) Pain was assessed by asking the patient using the 10-Visual scale (with 0 denoting no pain and 10 denoting the worst pain).

Urinary symptoms:

Women were asked in the same questionnaire about the symptoms of urinary incontinence. After giving informed oral consent all included women were subjected to trans- vaginal ultra-sound scan in Maternity university Hospital of Bab Al Sharreya for detection of a C.S scar niche.

TVS was performed during the first postmenstrual week and the day of the cycle was recorded, or if the woman is amenorrheic or on irregular menstruation TVS done after negative serum human chorionic gonadotropin. TVS was performed recording the uterine position, length, width, endometrial thickness and examined for presence of a niche.

Then the depth of the niche (The vertical distance between the base and apex of the defect) and residual myometrium (from the serosal surface of the uterus to the apex of the niche) were measured (a) (b). The niche shape was assessed according to a specified classification (c).

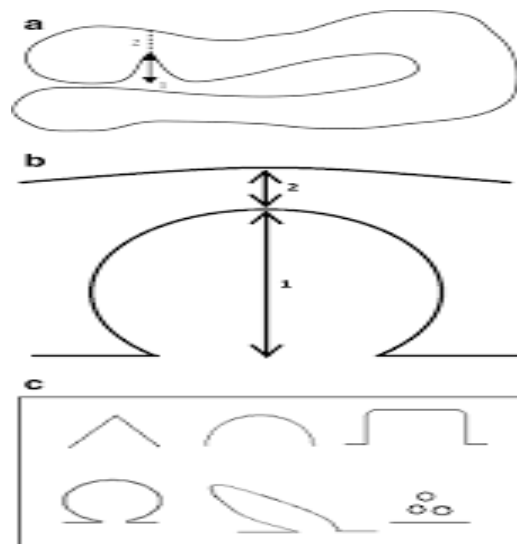


Fig 1: Relation between niche &post menstrual spotting

Diagram showing measurement of the niche, (depth, residual myometrium, total myometrial thickness) and common shapes of niche (triangular, semicircular, circular, droplet, rectangular and inclusion cyst) Marjolein Dieleman_Bij de vaate ,the uterine niche in the C.S,Relation between niche &post menstrual spotting,cha[ter 4,page 45Fig(1,2).

Using the following technique: (1) Using speculum to expose the external cervix. (2) Sterilizing with povidone iodine both the cervix and vagina. (3) Insertion of an 8 Fr balloon catheter into the uterine cavity which was flushed with saline to rid it of air and then inserted into the uterine cavity. (4) Dripping of 5 to 30 ml sterile saline guided by T.V.S into the uterine cavity and the ultrasound images were taken while the saline was injected through the catheter. (5) Infusion of saline continued till the patient felt slight uterine pain, a maximum of 10 mL can reach pain.

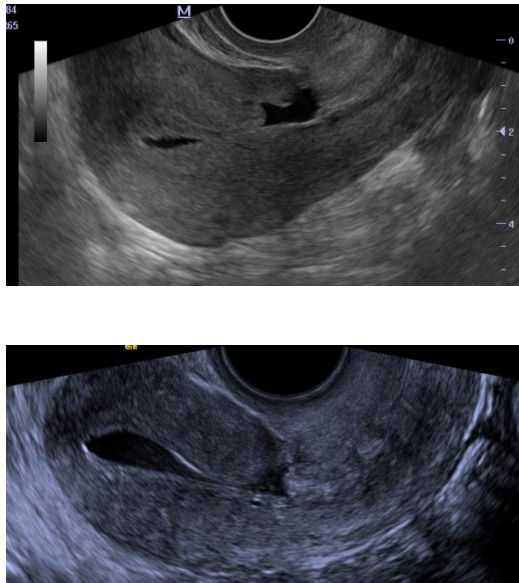


Fig 2: T.V.S image showing residual myometrium and C.S defect

T.V.S image showing residual myometrium and C.S defect taking in family planning clinic at Bab Al Shaareya Hospital Al Azhar University, Cairo, Egypt tusing voluson E6Expert GE medical system Fig (3.4).

Methods of Diagnosis of such defect:

The first - line test for clinic diagnosis is T.V.S or saline - infusion sono- hysteroqram.8

(A) Hystrosalpingraphy: (HSG) small niches may be missed.9 (B) High resolution Trans - vaginal ultrasound (TVS) is a valuable tool for detection of myometrial thinning or scar dehiscence.4 (C) Gel or saline instillation sonohysterography (GIS or SIS):6 The image of SCSH is better than GIS. (D) Hysteroscopy. (E) Others Magnetic resonance imaging (MRI), and 3 - D ultra-sonography, are additional methods for diagnosis.

Treatments for cesarean scar defect vary dramatically and include :

Hormonal therapy: Oral contraceptives (OC) may result in the temporary improvement in symptoms,

but many patients cannot tolerate their adverse effects.10

Surgical repair (Abdominal): An abdominal approach to repair the uterine defect can completely correct the defect but its invasiveness and complications significantly restrain.11

Vaginal repair of PCSD: by removal of the scar and surrounding tissue, then repairing by 2 layers of sutures. Vaginal repair of CSD is improving the symptoms of postmenstrual spotting and anatomically correct the scars.12

Hysteroscopic resection of the (niche): The least invasive surgical therapy which enhance of menstrual blood and prevent hemorrhage produced by the fragile vessels in the niche.

Laparoscopic Repair of the “Niche” has the advantage over hysteroscopy in repairing of the scar defect, by restoring a normal myometrial thickness. So laparoscopy is the first choice for large uterine niche.13

For women whose childbearing is completed, Hysteroscopic resection can resolve symptoms of pain and bleeding with a 92% to 100% success rate while 75% of patients undergoing laparoscopic repair to achieve pregnancy and guard against uterine rupture .2

Statistical analysis:

The collected data were coded, processed and analyzed using the SPSS (Statistical Package for Social Sciences) version 22 for Windows® (IBM SPSS Inc, Chicago, IL, USA). Data were tested for normal distribution using the Shapiro Walk test. Qualitative data were represented as frequencies and relative percentages. Chi square test (χ^2) to calculate difference between two or more groups of qualitative variables. Quantitative data were expressed as mean \pm SD (Standard deviation). Independent samples t-test was used to compare between two independent groups of normally distributed variables (parametric data). P value < 0.05 was considered significant.

RESULTS

Items	Study cases n= 200	
	Number	Percent (%)
Age (Years)		
Mean \pm SD	31.74 \pm 4.14	
Median (Range)	32 (24- 42)	
Quality of life		
Housewife	45	22.5
Working	155	77.5
Parity		
Mean \pm SD	2.77 \pm 0.86	
Median (Range)	3 (1- 5)	

Categorical data expressed as Number (%)

Continuous data are expressed as mean \pm SD median (Min-Max)

Table (1): Basic demographic data of the subjects in the study

The mean age of the included cases was 31.74 years (range, 24 – 42). Most of them were working (77.5%), whereas the remaining participants were housewives. They had a mean parity of 2.77 (range, 1 – 5) (Table 1).

Items	Study cases n= 200	
	Number	Percent (%)
Regularity		
Regular	123	61.5
Irregular	77	38.5
Frequency (Every certain days)		
Mean ± SD	24.78 ± 3.36	
Median (Range)	25 (14- 30)	
Duration of menstruation (Days)		
Mean ± SD	4.98 ± 1.81	
Median (Range)	4 (3- 11)	
Post menstrual spotting		
No	61	30.5
Yes	139	69.5
Duration (Days)		
Mean ± SD	4.78 ± 2.49	
Median (Range)	4 (2- 15)	

Categorical data expressed as Number (%) Continuous data are expressed as mean ± SD median (Min-Max)

Table (2): Menstrual history of the subjects in the study

Regarding menstrual history of the included cases, regular menses were reported by 61.5%, while the remaining ladies had irregular menses (38.5%). Menses was reported to occur every 24.78 days (range, 14 – 30). The duration of menstruation ranged between three and eleven days (mean = 4.98 days). Post-menstrual spotting was reported by 69.5% of ladies. The duration of spotting ranged between two and 15 days (mean = four days) (Table 2).

Items	Study cases n= 200	
	Number	Percent (%)
Pain during intercourse		
No	126	63
Yes	74	37
Pain during micturition		
No	150	75
Yes	50	25
Infection (PID)		
No	93	46.5
Yes	107	53.5
Subfertility		
No	156	78
Yes	44	22

Table (3): Symptoms (Mode of presentation) of the subjects in the study

Regarding the presentation of the included cases, painful intercourse was reported by 37% of patients, while painful micturition was experienced by 25% of them. In addition, PID was present in 53.5% of patients whereas 22% of them had subfertility (Table 3).

Items	Study cases n= 200	
	Number	Percent (%)
Position of uterus		
AVF	167	83.5
RVF	33	16.5
Shape of niche		
Oval	41	20.5
Rectangular	34	17.0
Semi circular	9	4.5
Triangular	116	58.0
Depth of Niche (mm)		
Mean \pm SD	6.22 \pm 5.21	
Median (Range)	6.3 (1- 25)	
Width of Niche (mm)		
Mean \pm SD	5.16 \pm 3.87	
Median (Range)	4 (0.2- 22)	
Residual myometrium (mm)		
Mean \pm SD	3.32 \pm 1.41	
Median (Range)	3 (1.1- 7)	
Intra-niche fluid		
No	110	55
Yes	90	45

Categorical data expressed as Number (%)

Continuous data are expressed as mean \pm SD median (Min-Max)

Table (4): Ultrasonographic criteria of the subjects in the study

Most patients had anteverted uterus (83.5%), while the remaining ones had a retroverted one. Triangular niche was the commonest encountered type (58%), followed by oval one (20.5%), rectangular (17%), and semicircular (4.5%). The depth of the niche had a mean value of 6.22 mm (range, 1 – 25), whereas its width had a mean value of 4 mm (0.2 – 22 mm). The thickness of the residual myometrium ranged between 1.1 and 7 mm (mean = 3.32 mm). Intra-niche fluid was detected in 90 ladies (45%) (Table 4).

Items	Asymptomatic (n= 61)	Symptomatic (n= 139)	Test of significance
Age	31.62 \pm 5.36	31.79 \pm 3.50	t= - 0.264 p = 0.792
Quality of life			
Housewife	17 (27.9%)	28 (20.1%)	$\chi^2 = 1.451$
Working	44 (72.1%)	111 (79.9%)	P = 0.228
Parity	2.61 \pm 1	2.83 \pm 0.79	z= - 2.109 p = 0.035*

Continuous data expressed as mean \pm SD.

Categorical data are expressed as number (percentage within group)

χ^2 : Chi-square test t: Paired samples t-test z: Mann Whitney U-test *: Statistically significant (p< 0.05)

Table (5): Comparison of basic demographic data between the symptomatic and asymptomatic cases

When dividing the included cases into asymptomatic and symptomatic groups, the mean age of the included cases was 31.62 and 31.79 years in the two groups respectively. Most of the included cases were working, as they represented 72.1% and 79.9% of patients in the same groups respectively. Both age and occupation showed no significant difference between the two groups. On the other hand, parity had mean values of 2.61 and 2.83 in the two groups respectively, with a significant increase in the symptomatic group (p = 0.035) (Table 5).

Items	Asymptomatic (n= 61)	Symptomatic (n= 139)	Test of significance
Regularity			
Regular	61 (100%)	64 (46%)	$\chi^2 = 51.246$
Irregular	0 (0%)	75 (54%)	P < 0.001*
Frequency	25.34 \pm 2.69	24.30 \pm 3.79	t= 1.804

Duration	4.56 ± 0.99	5.16 ± 2.04	p = 0.074 z = - 1.074 p = 0.283
Postmenstrual spotting	0 (0%)	16 (43.2%)	χ ² = 36.145 P < 0.001*
Duration of postmenstrual spotting		31.79 ± 3.50	

Continuous data expressed as mean ± SD. Categorical data are expressed as number (percentage within group)

χ²: Chi-square test t: Paired samples t-test z: Mann Whitney U-test *: Statistically significant (p< 0.05)

Table (6): Comparison of Menstrual history between the symptomatic and asymptomatic cases

Irregular menstrual history was reported by 54% of symptomatic cases, while it was not reported by ant lady in the asymptomatic group (p < 0.001). The frequency of periods showed no significant difference between the two groups (25.34 and 24.3 days in the asymptomatic and symptomatic groups respectively – p = 0.074). The duration of menses was also comparable between the two groups (4.56 and 5.16 days in the same two groups respectively - p = 0.283). Postmenstrual spotting showed a significant increase in the symptomatic group (43.2% vs. 0% in the asymptomatic group – p < 0.001) (Table 6).

Items	Asymptomatic (n= 61)	Symptomatic (n= 139)	Test of significance
Position of uterus			
AVF	59 (96.7%)	108 (77.7%)	χ ² = 18.844 P < 0.001*
RVF	2 (3.3%)	31 (22.3%)	
Shape of niche			
Oval	15 (24.6%)	26 (18.7%)	FET = 8.142 P = 0.015*
Rectangular	2 (3.3%)	32 (23%)	
Semi circular	2 (3.3%)	7 (5%)	
Triangular	42 (68.8%)	74 (53.2%)	
Depth of Niche (mm)	4.24 ± 3.42	8.62 ± 5.66	z= - 5.969 p < 0.001*
Width of Niche (mm)	2.06 ± 1.56	6.52 ± 3.79	z = - 9.021 p < 0.001*
Residual myometrium (mm)	3.87 ± 1.52	3.07 ± 1.29	z= - 3.415 p < 0.001*
Intra-niche fluid	0 (0%)	90 (64.7%)	χ ² = 71.812 P < 0.001*

Continuous data expressed as mean ± SD. Categorical data are expressed as number (percentage within group)

χ²: Chi-square test FET: Fischer’s exact test z: Mann Whitney U-test *: Statistically significant (p< 0.05)

Table (7): Comparison of ultrasonographic features between the symptomatic and asymptomatic cases

The position of the uterus showed a significant difference between the asymptomatic and symptomatic groups (p < 0.001). anteverted uterus was present in 96.7% and 77.7% of ladies in the two groups respectively. The shape of the niche was significantly different between the two groups, as rectangular defects were more encountered in symptomatic group (23% vs. 3.35 in the asymptomatic group – p = 0.015). Both niche depth and width showed a significant increase in the symptomatic group (p < 0.001). The former had mean values of 4.24 and 8.62mm, while the latter had mean values of 2.06 and 6.52 mm in the asymptomatic and symptomatic groups respectively. On the other hand, the thickness of residual myometrium showed a significant decrease in the symptomatic group (3.07 vs. 3.87 mm in the asymptomatic group – p < 0.001). Intra-niche fluid was detected in 64.7% of symptomatic cases, compared to no subjects in the asymptomatic group (p < 0.001) (Table 7).

DISCUSSION

This study was operated at Al-Azhar University Hospitals aiming to assess (PCSD) by trans-vaginal ultrasound and evaluation of its related complications in non-pregnant women. We included a total of 200 ladies with previous CS, whose age had a mean value of 31.74 years (range, 24 – 42).

In a similar study, Pomorski et al.¹⁴ reported that the mean age of the included 26 ladies with CS defect, who had a mean age of 32.62 years, which is near to our findings.

In the current study, the number of previous CS ranged between one and four sections (mean = 2.44).

In a previous similar study, the majority (71%) of the women analysed had had only one previous

caesarean section,. Sixty-four (24%) had had two and eleven (4%) had had three previous caesarean sections.²

In our study, symptomatic niche was detected in 139 ladies, with an incidence rate of 69.5%.

And it has been reported in previous study to range from 19.4 to 88%.^{5, 6, 16} and our reported incidence lies within the previous range.

In the current study, post-menstrual spotting was reported by 69.5% of ladies. The duration of spotting ranged between two and 15 days (mean = four days). Moreover, irregular menses was reported by 38.5% of the included women.

Bij de Vaate et al.¹⁷ reported that by using SHG, postmenstrual spotting was found in 34% of women with a niche.

In our study, subfertility was reported by 22% of the included ladies diagnosed with CSD. As the presence of blood in this area badly affects the cervical mucus and semen, and interferes with semen transport, leading to subfertility.¹⁹

In the current study, painful intercourse was reported by 37% of patients, while painful micturition was experienced by 25% of them.

In the current study, most patients had anteflexed uterus (83.5%), while the remaining ones had a retroverted one.

Another study reported that anteflexed uterus was the commonest type in ladies with CSD, as it was encountered in 224 out of 83.58% of the included participants. The remaining ladies had retroflexed uterus.¹⁵ This is in line with our findings.

On the other hand, another study Pomorski et al.¹⁴ reported more or less similar prevalence of uterine positions, as ante flexed uterus was detected in 14 cases (53.85%), while the remaining 12 cases had retroflexed uterus (46.15%).

When it comes to CSD dimensions in our study, the depth of the niche had a mean value of 6.22 mm (range, 1 – 25), whereas its width had a mean value of 4 mm (0.2 – 22 mm).

Pomorski et al.¹⁴ reported that the mean width and depth of the detected defects were 0.99 and 0.62 cm respectively. Another study Vikhareva et al.⁵ reported that uterine scar defect had median values of 5 and 4.1 mm regarding the height and width respectively. In cases with previous one CS, defect height ranged between 2 and 12.4 mm, whereas defect width ranged between 1.9 and 13.7 mm.

The shape of the niche was different between the two groups, as rectangular defects were more encountered in symptomatic group (23% vs. 3.35 in the asymptomatic group – $p = 0.015$).

Contrarily, Bij de Vaate and his colleagues denied any significant difference between symptomatic and asymptomatic ladies with CSD regarding niche shape ($p = 0.19$). Semicircular type was the commonest in both groups, followed by triangular ones.¹⁷

In our study, both niche depth and width showed a significant increase in the symptomatic group ($p < 0.001$). The former had mean values of 4.24 and 8.62mm, while the latter had mean values of 2.06 and 6.52 mm in the asymptomatic and symptomatic groups respectively.

In the same context, Bij de Vaate et al.¹⁷ reported that symptoms were significantly associated with niches with larger volume ($p = 0.02$). It had mean values of 0.08 and 0.04 cm³ in the symptomatic and asymptomatic groups respectively.

More post menstrual spotting found in large niches due to its capacity to collect blood.

In another study, Van der Voet et al.² reported no significant difference between patients with and without postmenstrual spotting regarding niche depth ($p = 0.72$), which had mean values of 5.46 and 5.15 mm in the two groups respectively. This contradicts our findings.

In the current study, the thickness of residual myometrium showed a significant decrease in the symptomatic group (3.07 vs. 3.87 mm in the asymptomatic group – $p < 0.001$).

However, in a previous similar study, authors noted comparable residual myometrial thickness between symptomatic and asymptomatic ladies without CSD ($p = 0.73$). It had mean values of 8.92 and 9.31 mm in the two groups respectively.² Other authors confirmed the previous findings.¹⁷

Some limitations in our study, this study operated in one center. Also, we evaluated the included cases with only one diagnostic modality (TVUS), which may show operator dependency. These drawbacks should be well covered in the upcoming studies.

CONCLUSION

Symptomatic niche incidence rate was 69.5% of women .had a niche detected by TVS and by sonohysterography. Presence of the niche was associated with postmenstrual spotting, heaviness of menstruation and dysmenorrheal which were related to the niche width and depth .

Therefore, the present study encourages gynecologists to consider the niche as an important differential diagnosis for postmenstrual spotting In a previous Cesarean section.

Conflict of interest : none

REFERENCES

1. Mathai, M, Hofmeyr GJ, Mathai NE. Abdominal surgical incisions for caesarean section. *The Cochrane Database of Systematic Reviews*. 2013; 5: Cd004453. 10.1002/14651858.CD004453.pub3.
2. Van der Voet L, Bij de Vaate A, Veersema S, Brölmann H, Huirne J. Long- term complications of caesarean section. The niche in the scar: a prospective cohort study on niche prevalence and its relation to abnormal uterine bleeding. *BJOG: An International Journal of Obstetrics & Gynaecology*. 2014; 121(2): 236-44.

3. Wang CB, Chiu WW, Lee CY, Sun YL, Lin YH, et al. Cesarean scar defect: correlation between Cesarean section number, defect size, clinical symptoms and uterine position. *Ultrasound in Obstetrics and Gynecology*. 2009; 34(1): 85-9.
4. Ofili-Yebovi D, Ben-Nagi J, Sawyer E, Yazbek J, Lee C, et al. Deficient lower-segment Cesarean section scars: prevalence and risk factors. *Ultrasound in Obstetrics & Gynecology*. 2008; 31(1): 72-7.
5. Vikhareva O, Jokubkiene L, Valentin L. High prevalence of defects in Cesarean section scars at transvaginal ultrasound examination. *Ultrasound in Obstetrics and Gynecology*. 2009; 34(1): 90-7.
6. Regnard C, Nosbusch M, Felleman C, Benali N, Van Rysselberghe M, et al. Cesarean section scar evaluation by saline contrast sonohysterography. *Ultrasound in Obstetrics and Gynecology*. 2004; 23(3): 289-92.
7. Bij de Vaate A, Van der Voet L, Naji O, Witmer M, Veersema S, et al. Prevalence, potential risk factors for development and symptoms related to the presence of uterine niches following Cesarean section: systematic review. *Ultrasound in Obstetrics & Gynecology*. 2014; 43(4): 372-82.
8. Naji O, Daemen A, Smith A, Abdallah Y, Bradburn E, et al. Does the presence of a Cesarean section scar influence the site of placental implantation and subsequent migration in future pregnancies: a prospective case-control study. *Ultrasound in Obstetrics & Gynecology*. 2012; 40(5): 557-61.
9. Surapaneni K, Silberzweig JE. Cesarean section scar diverticulum: appearance on hysterosalpingography. *American Journal of Roentgenology*. 2008; 190(4): 870-4.
10. Florio P, Gubbini G, Marra E, Dores D, Nascetti D, et al. A retrospective case-control study comparing hysteroscopic resection versus hormonal modulation in treating menstrual disorders due to isthmocele. *Gynecological Endocrinology*. 2011; 27(6): 434-8.
11. Donnez O, Jadoul P, Squifflet J, Donnez J. Laparoscopic repair of wide and deep uterine scar dehiscence after cesarean section. *Fertility and Sterility*. 2008; 89(4): 974-80.
12. Luo L, Niu G, Wang Q, Xie H, Yao S. Vaginal repair of cesarean section scar diverticula. *Journal of Minimally Invasive Gynecology*. 2012; 19(4): 454-8.
13. Aimi G, Buggio L, Berlanda N, Vercellini P. Laparoscopic repair of a symptomatic post-cesarean section isthmocele: a video case report. *Fertil Steril.*, 2017; 107(6): e17-e18.
14. Pomorski M, Fuchs T, Rosner-Tenerowicz A, Zimmer M. Morphology of the cesarean section scar in the non-pregnant uterus after one elective cesarean section. *Ginekologia Polska*. 2017; 88(4): 174-9.
15. Pomorski M, Fuchs T, Rosner-Tenerowicz A, Zimmer M. Standardized ultrasonographic approach for the assessment of risk factors of incomplete healing of the cesarean section scar in the uterus. *European Journal of Obstetrics & Gynecology and Reproductive Biology*. 2016; 205: 141-5.
16. Armstrong V, Hansen WF, Van Voorhis BJ, Syrop CH. Detection of cesarean scars by transvaginal ultrasound. *Obstetrics & Gynecology*, 2003; 101(1): 61-5.
17. Bij de Vaate A, Brölmann H, Van Der Voet L, Van Der Slikke J, Veersema S, et al. Ultrasound evaluation of the Cesarean scar: relation between a niche and postmenstrual spotting. *Ultrasound in Obstetrics & Gynecology*. 2011; 37(1): 93-99.
18. Valenzano MM, Lijoi D, Mistrangelo E, Costantini S, Ragni N. Vaginal ultrasonographic and hysterosonographic evaluation of the low transverse incision after caesarean section: correlation with gynaecological symptoms. *Gynecologic and Obstetric Investigation*. 2006; 61(4): 216-22.
19. Woźniak A, Pyra K, Tinto HR, Woźniak S. Ultrasonographic criteria of cesarean scar defect evaluation. *Journal of Ultrasonography*. 2018; 18(73): 162.
20. Rosa F, Perugin G, Schettini D, Romano N, Romeo S, et al. Imaging findings of cesarean delivery complications: cesarean scar disease and much more. *Insights Into Imaging*. 2019; 10(1): 1-14.