

## Evaluation of the Central Vault Following Implantable Phakic Contact Lens and its Correlation to Horizontal White to White Corneal Diameter by Anterior Segment Optical Coherence Tomography

Amr Radi Mahmoud <sup>1</sup>\*MSc; Mohamed Abdelhamid Aboelenin <sup>1</sup>MD; Hatem Mahmoud Samy <sup>1</sup>MD.

### \*Corresponding Author:

Amr Radi Mahmoud  
amrradi053@gmail.com

Received for publication February 05, 2022; Accepted July 30, 2022; Published online July 30, 2022.

doi: 10.21608/aimj.2022.119769.1826

**Citation:** Amr R. , Mohamed A. , Hatem M. Evaluation of the Central Vault Following Implantable Phakic Contact Lens and its Correlation to Horizontal White to White Corneal Diameter by Anterior Segment Optical Coherence Tomography. AIMJ. 2022; Vol.3-Issue7 : 76-82.

<sup>1</sup>Ophthalmology Department, Faculty of Medicine, Al-Azhar University, Cairo , Egypt.

### ABSTRACT

**Background:** Implantable Phakic Contact Lenses have been developed as a cost-effective alternative to Visian Implantable Collamer lenses for refractive correction.

**Aim of The Work:** To evaluate the central vault of implantable phakic contact lens (IPCL) and its correlation to horizontal white to white (WTW) corneal diameter using anterior segment optical coherence tomography.

**Patients and Methods:** 30 eyes that match the inclusion criteria for IPCL V2.0 implantation were studied. Two groups were divided to study the correlation between pre-operative horizontal (WTW) corneal diameter and post-operative central vault: group 1 with WTW diameter < 12 mm and group 2 with WTW diameter ≥ 12 mm.

**Results:** Visual acuity and spherical equivalent improved post-operatively with P value < 0.01, IOP increased maximally at 1 week and 1 month post operatively but declined at 6 and 12 months with P value < 0.01. Central vault in group 1 decreased from the 1st week post-operatively till the end of 12 months with P value < 0.05. While in group 2, it decreased till the end of 12 months with P value > 0.05. Comparison between the 2 groups showed mild difference in all visits with P value > 0.05. Also correlation between pre-operative WTW diameter and central vault was negative with P value > 0.05.

**Conclusion:** IPCL is a safe and effective approach for correction of high degrees of refractive errors or when corneal refractive surgery is contraindicated. Also, no correlation was found between pre-operative horizontal WTW corneal diameter and post-operative central vault.

**Keywords:** IPCL; Vault; WTW.

**Disclosure:** The authors have no financial interest to declare in relation to the content of this article. The Article Processing Charge was paid for by the authors.

**Authorship:** All authors have a substantial contribution to the article.

**Copyright** The Authors published by Al-Azhar University, Faculty of Medicine, Cairo, Egypt. Users have the right to read, download, copy, distribute, print, search, or link to the full texts of articles under the following conditions: Creative Commons Attribution-Share Alike 4.0 International Public License (CC BY-SA 4.0).

### INTRODUCTION

In those cases where corneal refractive surgery is contraindicated, phakic intraocular lenses (PIOLs) are a well-established method of correcting moderate to high refractive errors.<sup>1</sup>

Reversibility, high optical quality, and potential gain in visual acuity owing to retinal magnification are all features of PIOLs, which are also unaffected by corneal thickness or topography.<sup>2</sup>

However, because it is an intraocular surgery, it carries a higher risk of complications, including anterior segment damage, retinal detachment, and infections such as endophthalmitis.<sup>3,4</sup>

Over a long period of time, the Visian Implantable Collamer lens has been shown to be safe and effective for moderate and high ametropia.<sup>5-7</sup>

The cost of treatment, particularly in developing countries, would be a constraint of the ICL. The Implantable Phakic Contact Lens was developed as a

cost-effective alternative option for refractive correction.<sup>3</sup>

IPCL can correct ametropia up to - 30.0 D. In addition, the earlier design V1 was replaced with V2.0, which features a central hole (380 μ) to reduce scattering and glare while also facilitating alignment and aqueous humour circulation.<sup>8</sup>

The most important parameters for determining patients' eligibility for phakic posterior chamber intraocular lens surgery and selecting the right lens size are anterior chamber depth (ACD) and white to white (WTW) corneal diameter. ICL surgery is not recommended if the ACD value is less than 3.00 mm.<sup>9</sup>

The vault is the distance between the posterior IPCL surface and the anterior crystalline lens pole, which is important for determining the safety of surgery.<sup>10</sup>

An ideal vault has been recommended to be between 250 and 750 μ. The contact between the IPCL and the anterior lens capsule might cause anterior sub-

capsular cataract if the vault is insufficient. Also, excessive vaulting can result in angle closure, pupillary blockage, or pigmentary dispersion syndrome, all of which can raise intraocular pressure and therefore the risk of glaucoma.<sup>11-14</sup>

Anterior segment optical coherence tomography (AS-OCT) is a non-invasive method for obtaining high-resolution images of the anterior segment, which can be used for both quantitative and qualitative analysis. As a result, an assessment of IPCL's central vault to guarantee its safety.<sup>15</sup>

This work aimed to evaluate the central vault of IPCL and its correlation to horizontal (WTW) corneal diameter using anterior segment optical coherence tomography.

**PATIENTS AND METHODS**

A non-randomized prospective study was carried out from February 2020 to February 2022 on thirty eyes of patients with moderate to high myopia with or without Astigmatism. The patients were selected from the outpatient Ophthalmology clinics of Al-Azhar university hospitals. All patients were informed about the details & risk of the procedure and were asked to provide written informed consent.

**Inclusion criteria:** Patient age (18 - 40 years). Myopia between -1.50 and – 18.00 DS. Astigmatism between 0 and – 4.00 DC. Stable refraction for a minimum period of 1 year. Endothelial cell count ≥ 2,500 cells/mm2. Anterior chamber depth ≥ 3.00 mm.

**Exclusion criteria:** Eyes with prior ocular surgery. Comorbidities including cataract, glaucoma, uveitis or corneal ectasia. Patients with systemic diseases.

Full medical history has been taken and ocular examination was done to exclude any other pathology. Uncorrected distant visual acuity (UDVA) and corrected distant visual acuity (CDVA) were measured using a landolt's C chart and expressed in decimal scoring. Manifest and cycloplegic refraction were measured using (Topcon KR Auto-refractometer). Intraocular pressure was measured using Goldmann applanation tonometer. Slit-lamp biomicroscopic examination and dilated fundus examination were done. Corneal tomography was assessed using (Siirus, CSO, Italy). Anterior chamber depth was measured using (Siirus, CSO, Italy). Horizontal white to white corneal diameter was measured using (IOL master, Zeiss).

**IPCL power and size:**

The phakic intraocular lens power was calculated using a modified vertex formula as per the manufacturer's recommendation, with a target refraction of emmetropia. The variables in the formula included preoperative manifest spherical and cycloplegic refractions, keratometric power, central corneal thickness and central ACD. The size (length) of the implanted ICL was determined based on the patient's WTW and ACD.

**Surgical procedure:**

Pupillary dilatation was done by tropicamide 1% and phenylephrine hydrochloride 2.5% 30 minutes before operation. General or peri-bulbar anaesthesia. Sterilization with betadine 10 % for the eye lids and surgical field. Betadine 5% eye-drops were used for the conjunctival cul-de-sac. Application of sterile drapes. Loading the IPCL before opening the eye. Implantation was done through 2.8 mm clear temporal corneal incision after viscoelastic substance injection, with 2 side ports at 90 degrees. Important land mark on the side of IPCL was noted and must be to the left side during implantation to prevent upside down of IPCL. After implantation, the footplates were tucked under the iris. Removal of viscoelastic substance and finally wound hydration was done.

Post-operative treatment consisted of topical antibiotic Moxifloxacin, topical anti-inflammatory prednisolone acetate 1% in tapering doses. Anti-glaucomatous drugs were used in cases of IOP elevation.

At 1week, 1month, 6 months and 12 months post-operatively: Visual acuity and spherical equivalent were measured. IOP was measured using Goldmann applanation tonometer. Central vault was measured using Topcon DRI OCT Triton anterior segment OCT.

**Statistical analysis:**

Recorded data were analyzed using the statistical package for social sciences, version 20.0 (SPSS Inc., Chicago, Illinois, USA). Quantitative data were expressed as mean ± standard deviation (SD). Qualitative data were expressed as frequency and percentage. The confidence interval was set to 95% and the margin of error accepted was set to 5%. So, the probability value (P-value) was considered significant as the following: P-value < 0.05 was considered significant. P-value < 0.001 was considered as highly significant. P-value > 0.05 was considered insignificant.

**RESULTS**

Thirty eyes of nineteen patients were selected. They were five males and fourteen females.

Eighteen eyes were right and twelve eyes were left.

Variable	Thirty Eyes	Percentage
Sex	5 Males	26.32%
	14 Females	73.68%
Affected eye	18 right	60%
	12 left	40%
Age	24.1 ± 4.93 years (18-35) years	

**Table 1:** summarize demographic data of age, sex and affected eyes.

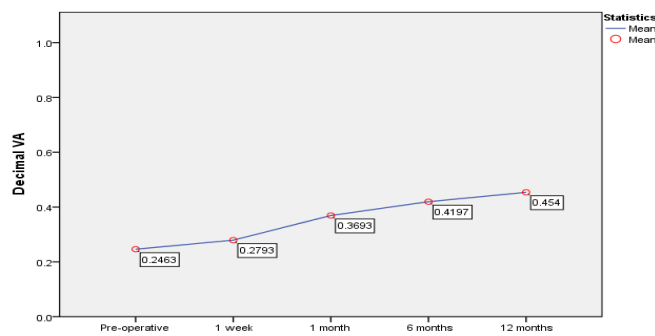
Visual acuity, Spherical equivalent and IOP were analyzed in all eyes at first.

Visual acuity:

VA improved from  $0.24 \pm 0.14$  pre-operatively to  $0.45 \pm 0.18$  at the end of 12 months post-operatively with P value < 0.01 indicating highly statistically significant difference (Table 2 & Fig. 1)

Decimal VA	Mean $\pm$ SD	Mean difference from pre-operative	P value
Pre-operative BCVA	$0.24 \pm 0.14$		
UCVA 1 week	$0.27 \pm 0.14$	$0.03 \pm 0.04$	< 0.01
UCVA 1 month	$0.36 \pm 0.17$	$0.12 \pm 0.07$	< 0.01
UCVA 6 months	$0.41 \pm 0.16$	$0.17 \pm 0.08$	<0.01
UCVA 12 months	$0.45 \pm 0.18$	$0.2 \pm 0.09$	<0.01

**Table 2:** Differences between pre and post-operative VA.



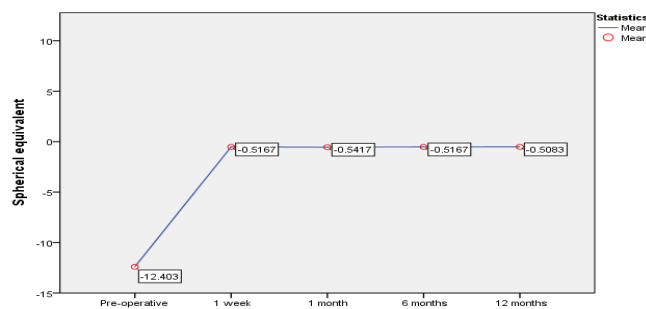
**Fig. 1 :** Diagrammatic representation of pre and post-operative VA.

Spherical equivalent:

SE improved markedly from  $-12.4 \pm 4.91$  pre-operatively to  $-0.5 \pm 0.63$  at the end of 12 months with P value < 0.01 indicating highly statistically significant difference (Table 3 & Fig. 2)

Spherical equivalent	Mean $\pm$ SD	Mean difference from pre-operative	P value
Pre-operative	$-12.4 \pm 4.91$		
1 week	$-0.51 \pm 0.72$	$-11.88 \pm 5.11$	<0.01
1 month	$-0.54 \pm 0.66$	$-11.86 \pm 5.09$	<0.01
6 months	$-0.51 \pm 0.63$	$-11.88 \pm 5.08$	<0.01
12 months	$-0.5 \pm 0.63$	$-11.89 \pm 5.07$	<0.01

**Table 3:** Differences between pre and post-operative spherical equivalent.



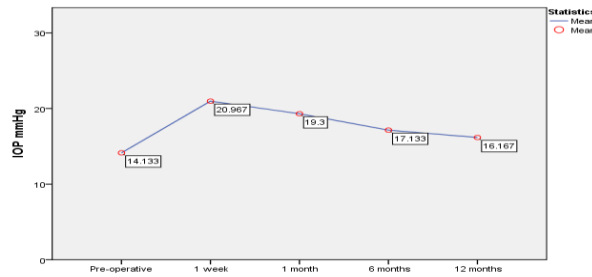
**Fig. 2:** Diagrammatic representation of pre and post-operative spherical equivalent.

Intraocular pressure:

IOP measured by Goldmann applanation tonometry increased maximally at 1 week and 1 month post operatively but declined at 6 and 12 months with P value < 0.01 indicating highly statistically significant difference as shown in (Table 4 & Fig. 3)

IOP	Mean ± SD	Mean difference from pre-operative	P value
Pre-operative	14.13 ± 1.61 mmHg		
1 week	20.97 ± 3.3 mmHg	6.83 ± 2.82	< 0.01
1 month	19.3 ± 2.85 mmHg	5.16 ± 2.4	< 0.01
6 months	17.13 ± 1.71 mmHg	3 ± 1.46	< 0.01
12 months	16.17 ± 1.76 mmHg	2.03 ± 1.77	< 0.01

**Table 4:** Differences between pre and post-operative IOP.



**Fig. 3:** Diagrammatic representation of pre and post-operative IOP.

After analysis of all data, two groups were divided according to the pre-operative horizontal WTW corneal diameter and central vault was measured to compare between the 2 groups: Group 1 Include eyes with horizontal white to white diameter < 12 mm. Group 2 include eyes with horizontal white to white diameter ≥ 12 mm.

Group	Description	Mean ± SD	Average
Group 1	WTW < 12 mm	11.44 ± 0.39 mm	10.79 – 11.9 mm
Group 2	WTW ≥ 12 mm	12.3 ± 0.26 mm	12 – 12.9 mm

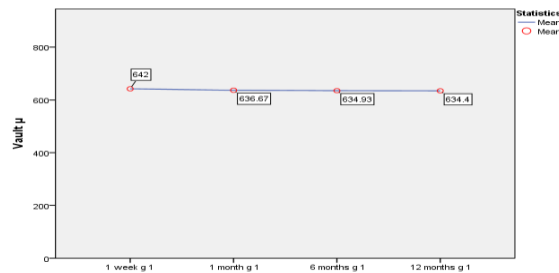
**Table 5:** Differences between pre-operative WTW in the two groups.

Group 1 central vault:

Central vault in group 1 decreased from 642 ± 129 μ at 1 week post-operative to 634 ± 134 μ at the end of 12th months with P value < 0.05 indicating statistically significant difference (Table 6 & Fig. 4)

Group 1 central vault	Mean ± SD	Mean difference from 1st week	P value
1 week	642 ± 129.19 μ		
1 month	636.67 ± 132.12 μ	5.33 ± 8.64	0.031
6 months	634.93 ± 134.45 μ	7.06 ± 11.3	0.030
12 months	634.4 ± 135.13 μ	7.6 ± 12.4	0.032

**Table 6:** Group 1 post-operative central vault and its difference from the 1st week.



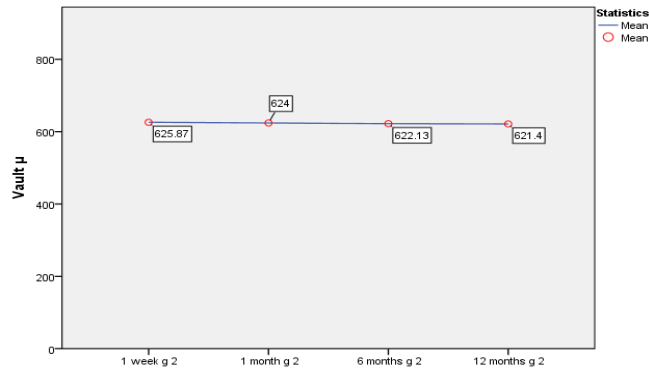
**Fig. 4:** Diagrammatic representation of post-operative central vault in group 1.

Group 2 central vault:

Central vault change in group 2 from the 1st week to the end of 12th month showed P value > 0.05 indicating statistically insignificant difference (Table 7&Fig. 5).

Group 2 central vault	Mean ± SD	Mean difference from 1 <sup>st</sup> week	P value
1 week	625.87 ± 133.68 μ		
1 month	624 ± 128.86 μ	1.86 ± 17.44	0.68
6 months	622.13 ± 127.77 μ	3.73 ± 17.91	0.43
12 months	621.4 ± 128.36 μ	4.46 ± 18.58	0.36

**Table 7:** Group 2 post-operative central vault and its difference from the 1st week.



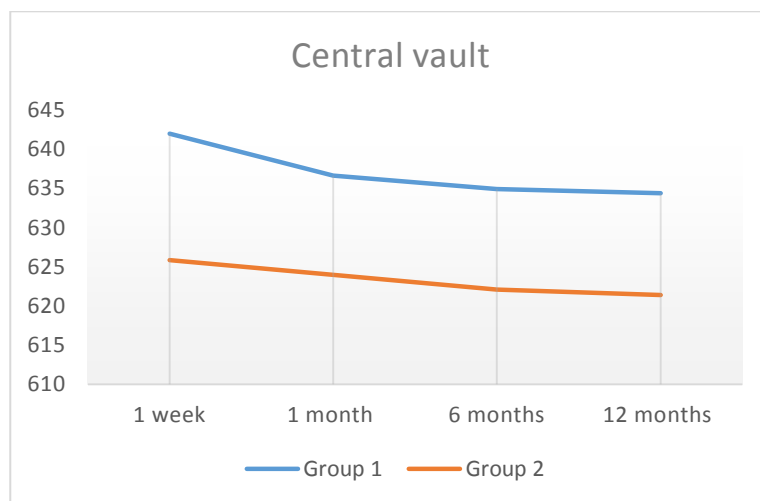
**Fig. 5:** Diagrammatic representation of post-operative central vault in group in group 2.

Comparison between Groups:

Comparison between the 2 groups showed mild difference in all visits with P value > 0.05 indicating statistically insignificant difference (Table 8 & Fig. 6).

	Group 1 central vault	Group 2 central vault	Mean difference	P value
1 week	642 ± 129.19 μ	625.87 ± 133.68 μ	16.13 ± 135.07	0.65
1 month	636.67 ± 132.12 μ	624 ± 128.86 μ	12.66 ± 135.89	0.723
6 months	634.93 ± 134.45 μ	622.13 ± 127.77 μ	12.8 ± 136.18	0.721
12 months	634.4 ± 135.13 μ	621.4 ± 128.36 μ	13 ± 136.99	0.719

**Table 8:** Difference between post-operative central vault in the two groups.



**Fig.6:** Diagrammatic representation of post-operative vault in the two groups.

Complications: 4 eyes developed IOP rise up to 30 mmHg. This IOP rise was due to retained viscoelastic and steroid responsiveness. This IOP rise decreased with anti-glaucomatous drugs and returned to normal after one month and with

discontinuation of steroids. 2 eyes developed rotation of IPCL but no decentration occurred with no visual affection or IOP rise. 2 eyes developed increased vault  $> 750 \mu$  ( $868 \mu$  in group 1 &  $854 \mu$  in group 2) but no IOP rise occurred along all periods of follow up with no narrowing of the angle neither by gonioscopy or by Sirius tomography. However these 2 eyes need long term follow and close observation.

## DISCUSSION

Except for two studies on the prior IPCL model V1 with no central hole, there have been few published studies on IPCL until now.<sup>3, 16</sup> as well as one study on the most recent model V2.0 with central hole.<sup>8</sup>

Vasavada V et al.<sup>16</sup> reported on the three-year follow-up of 30 IPCL V 1 implanted eyes. They observed a 9.73 % average endothelial cell loss, with satisfactory refractive outcomes without complications.

After implantation of the IPCL V 1 model intraocular lens, Sachdev G et al.<sup>3</sup> observed 134 eyes for at least one year and they conclude that IPCL is a safe and effective procedure for correction of myopia and myopic astigmatism.

Our study has been conducted on IPCL V2.0 design similar to Bianchi GR study<sup>8</sup> who described six months' follow up of 100 eyes implanted with IPCL V2.0.

Regarding visual acuity, it improved gradually along follow up period from  $0.24 \pm 0.14$  pre-operatively to  $0.45 \pm 0.18$  at the end 12 months post-operatively. Also spherical equivalent improved markedly from  $-12.4 \pm 4.91$  pre-operatively to  $-0.5 \pm 0.63$  at the end of 12 months indicating effectiveness of this procedure.

The improvement of visual acuity with time was due to increased retinal magnification and plastic changes in the visual cortex as supported by Elisa Vuori et al.<sup>17</sup>

According to Bianchi GR study<sup>8</sup> 52% of the eyes implanted with IPCL V2.0 exhibited SE values ranging from  $-0.5$  to  $+0.5$  D, while the remaining eyes had SE values ranging from  $-1.5$  D to  $+1.35$  D.

Regarding IOP, it increased at 1 week and 1 month post-operatively mostly due to retained viscoelastic, postoperative inflammation and topical steroid but decreased thereafter with drop to the pre-operative values at 6 and 12 months of follow up with all values within normal range.

Bianchi GR<sup>8</sup> found that IOP values remained similar at baseline, 1 day and 6 months after IPCL V2.0 implantation with no statistical significant difference.

Special concern in our study has been made to evaluate the effect of pre-operative horizontal white to white corneal diameter on post-operative central vault. So we divide eyes into 2 groups: Group 1 Include eyes with horizontal (WTW) diameter  $< 12$  mm. Group 2 include eyes with horizontal (WTW) diameter  $\geq 12$  mm.

Group 1 central vault was found to be  $642 \pm 129.19 \mu$  at the 1<sup>st</sup> week and decreased mildly after that till the end of 12 months to be  $634.4 \pm 135.13 \mu$  this

decrease was statistically significant but values were within normal range in all visits of follow up.

Group 2 central vault was found to be  $625.87 \pm 133.68 \mu$  at the 1<sup>st</sup> week and decreased mildly till the end of 12 months to be  $621.4 \pm 128.36 \mu$ . This decrease was statistically and clinically insignificant.

Comparing two groups together revealed insignificant statistical difference in all periods of follow up with P value  $> 0.05$ .

Bianchi GR<sup>8</sup> evaluated the central vault in patients implanted with IPCL V2.0 at 3 and 6 months and they found that central vault was  $541.15 \pm 117.12 \mu$  at 3 months and  $541.71 \pm 117.67 \mu$  at 6 months post-operative and these results show no statistically significant difference.

Our results were similar to Bianchi GR which indicate that vault remained stable with no significant change along follow up period.

These data showed that no affection of the pre-operative horizontal WTW diameter on the post-operative vault, and proper pre-operative measurement of ACD and WTW diameter is essential for proper sizing of IPCL which will lead to proper post-operative vault.

Regarding complications; IOP rise up to 30 mmHg was developed in 4 eyes. This IOP rise was due to retained viscoelastic and steroid responsiveness. This rise decreased with anti-glaucomatous drugs and returned to normal after one month and with discontinuation of steroids.

Also IPCL rotation occurred in 2 eyes with no decentration or IOP rise in these 2 eyes. This may be related to improper measurement of horizontal WTW diameter pre-operatively.

2 eyes developed increased vault  $> 750 \mu$  ( $868 \mu$  in group 1 &  $854 \mu$  in group 2) but no IOP rise occurred along all periods of follow up with no narrowing of the angle neither by gonioscopy or by Sirius tomography. However these 2 eyes need long term follow up and close observation.

## CONCLUSION

Implantation of Implantable phakic contact lens (IPCL) is an effective and safe approach for correction of high degrees of refractive errors or when corneal refractive surgery is contraindicated.

No correlation was found between pre-operative horizontal white to white corneal diameter and post-operative central vault. And proper measurement is essential to avoid excessive or low vault.

Anterior segment OCT is an effective method for evaluation of the central vault of IPCL and its position.

Conflict of interest : none

## REFERENCES

1. Alió JL and Toffaha BT. Refractive surgery with phakic intraocular lenses: an update. *International ophthalmology clinics*. 2013;53(1):91-110.
2. Kohnen T, Kook D, Morral M and Güell JL. Phakic intraocular lenses: part 2: results and complications. *Journal of Cataract & Refractive Surgery*. 2010;36(12):2168-94.
3. Sachdev G and Ramamurthy D. Long-term safety of posterior chamber implantable phakic contact lens for the correction of myopia. *Clinical Ophthalmology (Auckland, NZ)*. 2019;13:137.
4. Igarashi A, Shimizu K and Kamiya K. Eight-year follow-up of posterior chamber phakic intraocular lens implantation for moderate to high myopia. *American journal of ophthalmology*. 2014;157(3):532-9. e1.
5. Packer M. The implantable collamer lens with a central port: review of the literature. *Clinical Ophthalmology (Auckland, NZ)*. 2018;12:2427.
6. Kamiya K, Shimizu K, Igarashi A, Kitazawa Y, Kojima T et al. Posterior chamber phakic intraocular lens implantation: comparative, multicentre study in 351 eyes with low-to-moderate or high myopia. *British Journal of Ophthalmology*. 2018;102(2):177-81.
7. Fernandes P, González-Méijome JM, Madrid-Costa D, Ferrer-Blasco T and Montés-Micó R. Implantable collamer posterior chamber intraocular lenses: a review of potential complications. *Journal of refractive surgery*. 2011;27(10):765-76.
8. Bianchi GR. Initial Results From a New Model of Posterior Chamber Implantable Phakic Contact Lens: IPCL V2. 0. Medical Hypothesis, *Discovery and Innovation in Ophthalmology*. 2019;8(2):57.
9. Lim DH, Lee MG, Chung E-S and Chung T-Y. Clinical results of posterior chamber phakic intraocular lens implantation in eyes with low anterior chamber depth. *American journal of ophthalmology*. 2014;158(3):447-54. e1.
10. Gargallo-Martinez B, Garcia-Medina JJ, Rubio-Velazquez E, Fernandes P, Villa-Collar C et al. Vault changes after cyclopentolate instillation in eyes with posterior chamber phakic intraocular lens. *Scientific Reports*. 2020;10(1):1-9.
11. Maeng H-S, Chung T-Y, Lee D-H and Chung E-S. Risk factor evaluation for cataract development in patients with low vaulting after phakic intraocular lens implantation. *Journal of Cataract & Refractive Surgery*. 2011;37(5):881-5.
12. Almalki S, Abubaker A and Alsabaani NA, Edward DP. Causes of elevated intraocular pressure following implantation of phakic intraocular lenses for myopia. *International ophthalmology*. 2016;36(2):259-65.
13. Gimbel HV, LeClair BM, Jabo B and Marzouk H. Incidence of implantable Collamer lens-induced cataract. *Canadian Journal of Ophthalmology*. 2018;53(5):518-22.
14. Repplinger B and Kohnen T. Intraocular pressure after implantation of an ICL with aquaport: Development of intraocular pressure after implantation of an ICL (model V4c) with aquaport without iridotomy. *Der Ophthalmologe: Zeitschrift der Deutschen Ophthalmologischen Gesellschaft*. 2018;115(1):29-33.
15. Porporato N, Baskaran M, Husain R and Aung T. Recent advances in anterior chamber angle imaging. *Eye*. 2020;34(1):51-9.
16. Vasavada V, Srivastava S, Vasavada SA, Sudhalkar A, and Vasavada VA. Safety and efficacy of a new phakic posterior chamber IOL for correction of myopia: 3 years of follow-up. *Journal of Refractive Surgery*. 2018;34(12):817-23.
17. Vuori E, Tervo TM, Holopainen MV and Holopainen JM. Improvement of visual acuity following refractive surgery for myopia and myopic anisometropia. Slack Incorporated Thorofare, NJ; 2007. p. 447-55.