

Feasibility of Axillary Reverse Mapping (ARM) in cancer breast with positive axilla using sodium diethyl ammonium hydroxide (patent blue) dye

General Surgery

Osama Al Shabrawy Al Saied ^{1,*} M.B.B.Ch, Mohamed Ibrahim El- Anany ¹ MD and
Mohamed Fathy Labib ¹ MD

***Corresponding Author:**

Osama Al Shabrawy Al Saied
drsemsem02@gmail.com

Received for publication January 22, 2022; Accepted July 30, 2022;
Published online July 30, 2022.

doi: 10.21608/aimj.2022.117775.1809

Citation: Osama A. , Mohamed I. , Mohamed F. Feasibility of Axillary Reverse Mapping (ARM) in cancer breast with positive axilla using sodium diethyl ammonium hydroxide (patent blue) dye. AIMJ. 2022; Vol.3-Issue7 : 108-113.

¹General Surgery Department, Faculty of Medicine, Al-Azhar University Cairo, Egypt.

ABSTRACT

Background: Sentinel lymph node biopsy is now a standard therapeutic approach for early-stage breast cancer. Arm lymphatic mapping, according to some researchers, is useful for identifying and preserving the arm lymphatics, and this novel process is referred to as "axillary reverse mapping" (ARM), since the arm lymphatics are being identified for preservation rather than eradication.

Aim of the work: To study the feasibility of using sodium diethyl ammonium hydroxide (patent blue) dye to perform an axillary reverse mapping (ARM) procedure in breast cancer women with positive axillary lymph nodes.

Patients and methods: This study included (40) patients. All patients were underwent surgery in general surgery and surgical oncology departments of Al-Azhar university hospitals. Inclusion criteria in study, patients who are histopathologically proved to have breast cancer, and patients with clinical and radiological positive axillary lymph nodes.

Results: Our study findings; 20.0% were diabetic and 15.5% were hypertensive. 72.5% of studied group managed by MRM and 27.5% by CBS. Majority were below axillary vein 62.5% and lateral to thoraco-dorsal nerve 57.5% and we had 5 cases not detected regard stain. No case had anaphylaxis, 4 cases had infection, and 2 cases with ulceration and overall complicated cases were 6 (15.0%). Complicated cases significantly elder and higher regard weight and BMI also significantly associated with diabetes mellitus (DM).

Conclusion: ARM can be done by using Sodium diethyl ammonium hydroxide (patent blue) dye With high rate of success and very low rate of complications .

Keywords: ARM; Cancer breast; Positive axilla; Sodium diethyl ammonium hydroxide dye.

Disclosure: The authors have no financial interest to declare in relation to the content of this article. The Article Processing Charge was paid for by the authors.

Authorship: All authors have a substantial contribution to the article.

Copyright The Authors published by Al-Azhar University, Faculty of Medicine, Cairo, Egypt. Users have the right to read, download, copy, distribute, print, search, or link to the full texts of articles under the following conditions: Creative Commons Attribution-Share Alike 4.0 International Public License (CC BY-SA 4.0).

INTRODUCTION

Breast cancer represents the most frequent cancer in women globally and the most prevalent deadly malignancy, accounting for roughly 23% of all cancers in women and nearly 1,000,000 new instances every year.^{1,2}

For decades, axillary lymph node dissection (ALND) was considered a beneficial procedure for ultimate axillary staging and loco-regional management in carcinoma patients. On the other hand, ALND is thought to be associated with morbidity, such as numbness, pain, or paraesthesia, arm and/or shoulder motion limitation, and, in particular, upper limb lymphedema.³ limb lymphedema has been documented in ALND patients and is thus the most common complication.³

Breast cancer-related lymphedema (BCRL) Breast cancer-related lymphedema (BCRL) has become one of the most prevalent and unpleasant consequences amongst post-surgical carcinoma survivors.⁴ The prevalence of which ranges from 13.5% to 42.0% and varies from study to study due to differences in target population, measurement duration, and other factors.⁵

The biopsy of sentinel lymph nodes (SLN) has been a generally established approach for the operative staging of axillary lymph nodes for carcinoma. In node-negative patients, this procedure may reduce arm lymphedema by avoiding unnecessary axillary lymph gland dissection (ALND). SLN biopsy, however, is disliked by node-positive individuals undergoing ALND; additionally, SLN biopsy doesn't completely remove arm lymphedema.⁶

The purpose of axillary reverse mapping (ARM) is to distinguish the lymphatics and arm lymph nodes from those of the breast during an axillary operation, allowing arm lymphatics to be preserved and decreasing arm lymphedema in node-positive patients.⁷

A multicenter patient- and assessor-blind randomized controlled trial was launched in the Netherlands in 2013 (Axillary Reverse Mapping trial). The goal was to determine the therapeutic safety and effectiveness of using Axillary Reverse Mapping to selectively preserve upper-limb axillary nodes as well as lymphatics in lymph node positive cases.⁸

Blue dye injection and tracking are presently supported ARM techniques.⁹

The purpose of the work has been to check the feasibility of the axillary reverse mapping (ARM) technique in carcinoma patients with positive axillary lymph nodes using sodium diethyl ammonia (patent blue) dye.

PATIENTS AND METHODS

This study included 40 patients. All patients were underwent surgery in general surgery and surgical oncology departments of Al-Azhar university hospitals.

Inclusion criteria: patients who are histopathologically proved to have breast cancer, and patients with clinical and radiological positive axillary lymph nodes.

Exclusion criteria: Patients who have negative axillary lymph nodes, patients who were medically unfit for surgery, patients who are received neo adjuvant therapy, and patients who refused this technique.

The following procedures were carried out on all of the patients:

Medical history-taking and careful clinical examination.

Laboratory investigations: Full labs: Cbc, (Pt, Ptt, Inr), S.Creat, liver enzymes, and RBG.

Imaging: Bilateral sonomammography, plain chest-X-ray, pelvi- abdominal US, and further radiology whether local or systemic according to indication

Diagnostic pathology: Core biopsy or wedge biopsy.

Axillary reverse mapping procedure:

Type of dye: patent blue dye.(Sodium diethyl ammonium hydroxide)

Skin sensitivity test: intra dermal injection of 0.1 ml of the dye in the conteralateral forearm in the night before surgery and see if there was allergic reaction or not.

Dose of injected dye: 5ml.

Time of injection: 10 minutes preoperative

Site of injection: upper inner aspect of the ipsilateral arm intra dermal and subcutaneous (Figs. 1, 2).

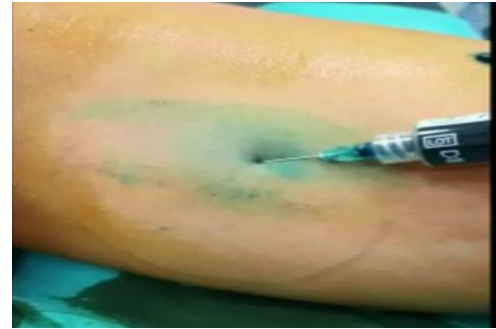

Fig. 1: Site of injection of dye at the ipsilateral arm's upper inner aspect

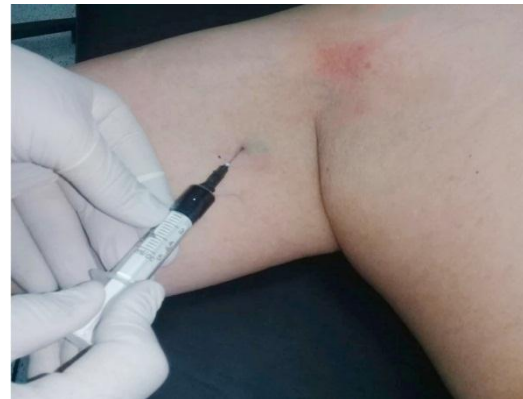

Fig. 2: Site of injection of dye at the ipsilateral arm's upper inner aspect.

We sterilize the skin at site of injection then we introduce the needle by an angle of 10 to 15 degrees (intra dermal) or 45 degrees (subcutaneous).

Then we did: mastectomy (MRM) or (lumpectomy or quadrantectomy as a part of conserving breast surgery) both of them were subjected to ALND.

Management of the axilla:

All cases were subjected to ALND:

Identification of axillary vein.

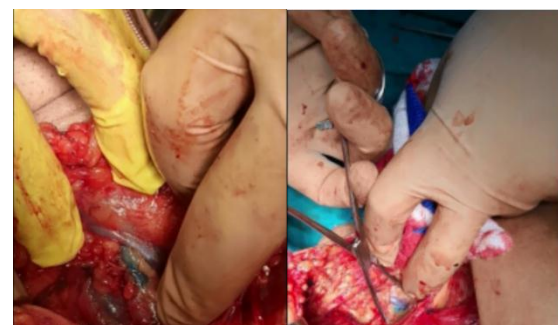

Fig. 3: Stained axillary LNs.

Detection of stained LNs.

Determine the location of stained LNs (belong to which group).

Axillary clearance with preservation of identified arm lymphatics.

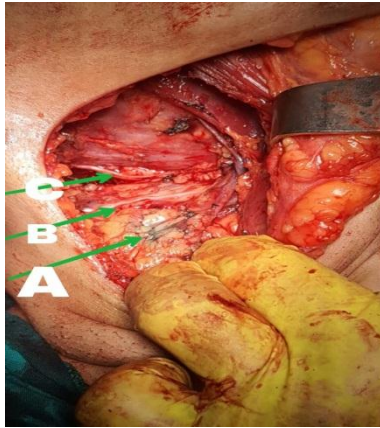


Fig. 4: Important contents of axilla: (A) Stained LNs (lateral group). (B) Thoraco dorsal nerve (nerve to latissimus dorsi muscle). (C) Long thoracic nerve.

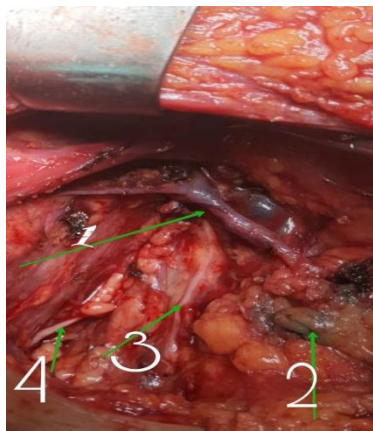


Fig. 5: Important contentes of axilla: (1) Branched axillary veien. (2) Stained lateral axillary LNs. (3)

Thoraco dorsal nerve (nerve to latissimus dorsi muscle). (4) Long thoracic nerve.

Statistical analysis:

To code, enter, and analyze data obtained during the history, basic clinical examinations, laboratory testing, and result measurements, the Microsoft Excel program was used. The data was then analyzed using the Statistical Package for the Social Sciences (SPSS) version 20.0 software. The following tests have been performed to evaluate differences for significance difference and connection of qualitative variables using the Chi-square test (X²), based on the kind of data qualitatively represented as numbers and percentages, and quantitatively described using mean ± SD. The t test has been employed to compare differences between quantitatively independent groups. For significant findings, the P value was set to < 0.05, and for highly significant findings, it was set at < 0.001.

RESULTS

		Age/ years	
Mean± SD		52.42±3.80	
Median (Range)		53.0 (45-59)	
	Weight/ Kg	Height/cm	BMI
Mean± SD	80.30±10.65	164.12±5.04	29.83±3.89
Median (Range)	78.0 (65-100)	164.0 (155-172)	29.71 (23.3-36.0)

Table 1: Age distribution and anthropometric measures distribution among studied group (N=40).

Age was distributed as 52.42±3.80 with minimum 45 and maximum 59 years. Weight was distributed as 80.30±10.65 with minimum 65 and maximum 100 Kg and height was distributed as 164.12±5.04 with minimum 155 and maximum 172 cm and regard BMI it was distributed as 29.83±3.89 with minimum 23.3 and maximum 36.0 (Table 1).

		N	%
DM	Not	32	80.0
	Diabetic	8	20.0
HTN	Not	34	85.0
	Hypertensive	6	15.0
Total		40	100.0
Operation type	CBS	11	27.5
	MRM	29	72.5
Total		40	100.0

Table 2: Co-morbidities, Operation type distribution among studied group (N=40).

20.0% were diabetic and 15.5 were hypertensive. 72.5% of studied group managed by MRM and 27.5% by CBS (Table 2).

		N	%
Axillary vein	Above	10	25.0
	Below	25	62.5
	Not detected	5	12.5
Thoraco-dorsal nerve	Lateral	23	57.5
	Medial	12	30.0
	Not detected	5	12.5
	Total	40	100.0

Table 3: Stain site distribution among studied group (N=40).

Majority were below axillary vein 62.5% and lateral to thoraco-dorsal nerve 57.5% and we had 5 cases not detected regard stain (Table 3).

		N	%
Anaphylaxis	-VE	40	100.0
	+VE	0	0.0
Infection	-VE	36	90.0
	+VE	4	10.0
Ulceration	-VE	38	95.0
	+VE	2	5.0
Overall	-VE	34	85.0
	+VE	6	15.0
	Total	40	100.0

Table (4): Complication distribution among studied group (N=40).

No case had anaphylaxis, 4 cases had infection, and 2 cases with ulceration and overall complicated cases were 6 (15.0%) (Table 4).

			Not	Complication	t/ X ²	P
Age			51.76±3.61	56.16±2.63	2.836	0.007*
	Weight		79.05±9.52	88.33±14.73	2.104	0.042*
			163.29±5.0	165.83±1.32	1.667	0.085
	Height		28.69±3.70	32.63±5.18	2.139	0.039*
BMI						
DM	-VE	N	30	2		
		%	88.2%	33.3%		
	+VE	N	4	4	9.60	0.002*
		%	11.8%	66.7%		
HTN	-VE	N	28	6		
		%	82.4%	100.0%		
	+VE	N	6	0	1.24	0.26
		%	17.6%	0.0%		
Operation type	CBC	N	8	3		
		%	23.5%	50.0%		
	MRM	N	26	3	1.79	0.18
		%	76.5%	50.0%		
Site_stained1	Above	N	7	3		
		%	20.6%	50.0%		
	Below	N	22	3	2.82	0.24
		%	64.7%	50.0%		
	NOT	N	5	0		
		%	14.7%	0.0%		
Site_stained2	Lateral	N	21	2		
		%	61.8%	33.3%		
	Medial	N	8	4	4.76	0.092
		%	23.5%	66.7%		
	NOT	N	5	0		
		%	14.7%	0.0%		
Total		N	34	6		
		%	100.0%	100.0%		

Table 5: Relation of complication with other parameters.

Complicated cases significantly elder and higher regard weight and BMI also significantly associated with DM (Table 5).

DISCUSSION

The goal of this research was to judge the feasibility and associated morbidity of ARM with patent blue dye in women having breast cancer who had positive axillary lymph nodes while maintaining arm lymphatics

Breast has been the most frequent cancer in women around the world and the most fatal malignancy, accounting for roughly 23% of all women's cancers and over 1,000,000 new instances each year.^{1,2}

For decades, axillary lymph node dissection (ALND) was considered a beneficial procedure for ultimate axillary staging and loco-regional management in carcinoma patients. On the other hand, ALND is thought to be associated with morbidity, such as numbness, pain, or paraesthesia, arm and/or shoulder motion limitation, and, in particular, upper limb lymphedema.³

The biopsy of sentinel lymph nodes (SLN) has been a generally established approach for the operative staging of axillary lymph nodes for carcinoma. In node-negative patients, this procedure may reduce arm lymphedema by avoiding unnecessary axillary lymph gland dissection (ALND). SLN biopsy, however, is disliked by node-positive individuals undergoing ALND; additionally, SLN biopsy doesn't completely remove arm lymphedema.⁶

The purpose of axillary reverse mapping (ARM) is to distinguish the lymphatics and arm lymph nodes from those of the breast during an axillary operation, allowing arm lymphatics to be preserved and decreasing arm lymphedema in node-positive patients.⁷

The axillary reverse mapping (ARM) method involves injecting blue dye into the arm to define the lymph node(s) and or lymph channels draining the arm.¹⁰

The ARM method is predicated on the idea that the lymphatics in the arm aren't engaged in carcinoma metastasis.¹¹

The anatomy of arm-breast lymphatic connection is yet unknown. Arm and breast lymphatic drainage to the axilla are thought to have their own lymphatic systems. The lack of detection technologies, the small lymphatic channels, and poor access make evaluating the lymphatic systems problematic. Hama et al.¹² used two-color spectral fluorescence lymphangiography to demonstrate two distinct drainage systems in a mouse model.

There have been differences in the placement of lymphatics from the arm in past research about the arm SLN. They both revealed a lack of lymphatic drainage concordance in the arm and breast.¹³

Except in patients having a high N stage, the arm node can be safely retained.¹⁴

Thompson et al.⁷ first proposed the ARM procedure in an attempt to distinguish a distinct arm lymphatic drainage system from the sentinel lymphatic pathway

The arm lymphatic pathway does not interact with the sentinel lymphatic pathway, which supports the arm node preservation strategy. Different reports have been published since then.¹⁵

We utilized patent blue dye in our work since injecting staining dye into the subcutaneous tissues or dermis can cause serious skin reactions such as necrosis and dermolysis.

Within the arm, dye was injected subcutaneously along the medial intermuscular groove in the upper inner portion of the ipsilateral arm.

We selected this location for the blue dye injection since it had the fastest drainage, with a mean flow of 2.0 cm/min, and it also neatly concealed the dye injection tattoo mark.¹⁶

The detection rate for arm lymphatic tissue using blue dye ranged from 61 to 78.3%.¹⁷ This poor discovery rate is related to a brief period between dye injections and operation, a deeper placement of the arm node that renders it difficult to locate the arm node inside the operative area, and a reduced detection rate of blue dye when compared to radioisotopes. In recent research, the utilization of radioisotopes or fluorescence has been reported to increase the detection rate by 88-100%.¹⁸

In our research, arm nodes were identified at a rate of 80%. The arm node took an average of 30.5±11.53 minutes to detect. In fair-skinned people, we are able to notice the flow of the dye in the dermal lymphatics

When given intravenously, Patent blue dye's plasma half-life was found to be 5–6.5 hrs.¹⁹ The pharmacokinetics of patent blue dye in the vascular system and lymph nodes, on the other hand, have received little attention.

Despite the fact that the duration of time to detect the arm node in the majority of patients was > 35 min, it did not appear to impair the washing out of blue dye in our research. More research is required to determine the best timing to detect of arm nodes

When a surgeon feels that an arm node might be involved in metastasis in the surgery field, all arm nodes cannot be saved. The ability of the surgeon to preserve the arm nodes is largely dependent on his experience. Thus, we use clinical suspicion for metastasis in arm nodes during the operation as per their size and consistency. Patients with significantly swollen arm nodes as well as those with a high operative N stage are excluded.

CONCLUSION

Arm lymphatic drainage identification and preservation is more challenging than simple biopsy and discovery of an SLN, and it likely needs a lengthier learning curve than breast SLNB. This discrepancy is supported by earlier published findings for the detection rate and lymphatic drainage dissection (71% versus 47%).

Conflict of interest : none

REFERENCES

- 1- Torre LA, Islami F, Siegel RL, Ward EM, Jemal A, Global cancer in women: burden and trends. *Cancer Epidemiology and Prevention Biomarkers*. 2017; 26(4):444-57.
- 2- Parkin LM, Fernández Use of statistics to assess the global burden of breast cancer. *Breast J*. 2016; 12 (1): S70-80.
- 3- Beek MA, Gobardhan PD, Klompenhouwer EG, Menke-Pluijmers MB, Steenvoorde P, Merkus JW, Rutten HJ, Voogd AC, Luiten EJ, A patient-and assessor-blinded randomized controlled trial of axillary reverse mapping (ARM) in patients with early breast cancer. *European Journal of Surgical Oncology*. 2020; 46(1):59-64.
- 4- Zou L, Liu FH, Shen PP, Hu Y, Liu XQ, Xu YY, Pen QL, Wang B, Zhu YQ, Tian Y, The incidence and risk factors of related lymphedema for breast cancer survivors post-operation: a 2-year follow-up prospective cohort study. *Breast Cancer*. 2018;25(3):309-14.
- 5- Ribeiro RJ and Koifman A, Bergmann Incidence and risk factors of lymphedema after breast cancer treatment: 10 years of follow-up. *Breast*. 2017; 36: 67-73.
- 6- Sakorafas GH, Peros G, Cataliotti L, Vlastos G, Lymphedema following axillary lymph node dissection for breast cancer. *Surg Oncol*.2006; 15:153–65.
- 7- Thompson M, Korourian S, Henry-Tillman R, et al, Axillary reverse mapping (ARM): a new concept to identify and enhance lymphatic preservation. *Ann Surg Oncol*.2007; 14(6):1890–5.
- 8- Klompenhouwer EG, Gobardhan PD, Beek MA, Voogd AC, Luiten EJ, The clinical relevance of axillary reverse mapping (ARM): study protocol for a randomized controlled trial. *Trials*. 2013; 14: 111.
- 9- Beek MA, Gobardhan PD, Schoenmaeckers EJ, et al, Axillary reverse mapping in axillary surgery for breast cancer: An update of the current status. *Breast Cancer Res Treat*. 2016;158(3):421–32.
- 10- Seema K, Axillary Reverse Mapping to Prevent Lymphedema After Breast Cancer Surgery: Defining the Limits of the Concept. *JCO*. 2009;27(33): 5494-6.
- 11- Britton TB, Solanki CK, Pinder SE, Mortimer PS, Peters AM, Purushotham AD, Lymphatic drainage pathways of the breast and the upper limb. *Nucl Med Commun*. 2009; 30:427-430.
- 12- Hama Y, Koyama Y, Urano Y, Choyke PL, Kobayashi H, Simultaneous two-color spectral fluorescence lymphangiography with near infrared quantum dots to map two lymphatic flows from the breast and the upper extremity. *Breast Cancer Res Treat*. 2007; 103:23-8.
- 13- Nos C, Lesieur B, Clough KB, Lecuru F, Blue dye injection in the arm in order to conserve the lymphatic drainage of the arm in breast cancer patients requiring an axillary dissection. *Annals of Surgical Oncology*. 2007; 14(9):2490-6.
- 14- Choi JE, Jeon YS, Kang SH, Lee SJ, Preservation of lymphatic drainage of arm during axillary procedure in breast cancer patients. *J Breast Cancer*. 2009; 12:179-85
- 15- Bedrosian I, Babiera GV, Mittendorf EA, Kuerer HM, Pantoja L, Hunt KK, et al, A phase I study to assess the feasibility and oncologic safety of axillary reverse mapping in breast cancer patients. *Cancer*. 2010; 116:2543-8
- 16- Uren RF, Hawman-Giles R, Thompson JF, Variation in cutaneous lymphatic flow rates. *Ann Surg Oncol*. 1997; 4:279-81.
- 17- Casabona F, Bogliolo S, Valenzano Menada M, Sala P, Villa G, Ferrero S, Feasibility of axillary reverse mapping during sentinel lymph node biopsy in breast cancer patients. *Ann Surg Oncol*. 2009; 16:2459-63
- 18- Noguchi M, Yokoi M, Nakano Y, Axillary reverse mapping with indocyanine fluorescence imaging in patients with breast cancer. *J Surg Oncol*. 2010; 101:217-221
- 19- Walter-Sack I, Rengelshausen J, Oberwittler H, Burhenne J, Mueller O, Meissner P, High absolute bioavailability of patent blue dye given as an aqueous oral formulation. *Eur J Clin Pharmacol*. 2009; 65:179-89.