

The Implication of Cardiac Telocytes, Inflammation, and Apoptosis in Carvedilol Protective Effect Against Aluminum Chloride Induced Myocardial Toxicity in Male Wistar Rats

Original
Article

Hoda M. Elsayed¹, Walaa I. Mohammed², Sahar M Gebri¹ and Sanaa A. Ahmed²

¹Department of Histology and Cell Biology, ²Department of Clinical Pharmacology, Faculty of Medicine, Sohag University, Egypt

ABSTRACT

Introduction: Aluminum is a widespread metal in the environment and linked to several diseases, including cardiovascular disease. Regenerative cardiac telocytes can potentially alleviate numerous heart diseases.

Aim of the Work: This study investigated the potential protective effect carvedilol on aluminum trichloride (AlCl₃)-induced cardiac toxicity by examining its antioxidative, anti-inflammatory, anti-apoptotic and its impact on cardiac telocytes.

Materials and Methods: Thirty adult male Wistar rats were randomly divided into three (10-rats) groups. Control group: saline. AlCl₃ group: after two weeks of saline, (70 mg/kg/day) AlCl₃ for four weeks. The Carvedilol+ AlCl₃ group: (1 mg/kg day) carvedilol for two weeks followed by AlCl₃ for four weeks. All drugs were received as a single dose daily I.P. At the end of the experiment, blood biochemical antioxidants, inflammatory and aluminum level were assessed. Additionally cardiac tissue histology, immunohistochemistry (active caspase 3 and CD117 markers) and histomorphometry were performed.

Results: Administration of AlCl₃ significantly increase in cardiac malonaldehyde, nitric oxide, and tumor necrosis factor-alpha levels as well as both serum and cardiac aluminum levels. Heart and body weights and cardiac catalase levels were significantly decreased. Histologically AlCl₃ induced degenerative and apoptotic changes in cardiac myocytes with a significant increase in apoptotic cells number and collagen fibers area percentage., However, myocardial telocytes is significantly decreased. Carvedilol administration ameliorated these abnormal biochemical, histological and immunohistochemical parameters.

Conclusion: Carvedilol prophylactic administration protected against ALCL3 induced cardiotoxicity via downregulating cardiomyocyte apoptosis and fibrosis due to its antioxidant, anti-inflammatory, and anti-apoptotic effects and increased cardiac telocytes number and its regenerative capacity.

Received: 17 June 2022, **Accepted:** 31 July 2022

Key Words: Cardiac toxicity, carvedilol, caspase 3, oxidative stress, telocytes.

Corresponding Author: Hoda M. Elsayed, MD, Department of Histology and Cell Biology, Faculty of Medicine, Sohag University, Egypt, **Tel.:** +20 10 9388 2036 - 11 5456 4107, **E-mail:** hoda_abdelrasowl@med.sohag.edu.eg

ISSN: 1110-0559, Vol. 46, No. 4

INTRODUCTION

Cardiovascular disorders are the 1st cause of death worldwide. The number of deaths increases annually with high prevalence in low-income countries than in others^[1].

Exposure to aluminum chloride has been implicated as a possible causative factor in many disorders including the cardiovascular system^[2,3]. The human body can be exposed to aluminum via numerous products such as food packaging and storage products^[4] and in some medications, deodorants, sunscreens cosmetics, and makeup products^[5].

Carvedilol is a non-selective third-generation β -adrenoreceptor antagonist that holds many cardioprotective and therapeutic capabilities in many disorders. It was used for the prevention of cardiotoxicity associated with chemotherapy, myocardial infarction, and viral myocarditis^[6]. Carvedilol's antioxidant, anti-inflammatory, and anti-apoptotic capabilities account for a large portion of its beneficial effects^[7]. It produced its anti-inflammatory effect in different tissue by reducing the expression of cyclooxygenase enzyme and proinflammatory cytokines^[8].

A stromal interstitial cells called telocytes (TCs) has been described in the last decade^[9]. The precise features of TCs are containing long projections called telopodes, organelles such as the endoplasmic reticulum, mitochondria, and intermediate filaments (vimentin) which distinguish these cells from others^[10]. TCs are also shown to express a variety of markers, including c-kit (CD117), CD34, PDGFR, PDG, CD29, and vimentin^[11,12].

The regeneration potential of TCs was one of the earliest postulated benefits, particularly in cardiac disorders such as myocardial infarction and heart failure^[13,14]. The previous effect of these cells has been proven by their role in the organogenesis of the heart scaffold in the developing human heart, which helps and nurses cardiomyocyte progenitors during their proliferation and differentiation^[9]. So, the objective of this study was to explore the role of carvedilol in the protection against AlCl₃-induced cardiac toxicity through its action as an anti-inflammatory, anti-apoptotic, and antioxidant in addition to its effect on cardiac TCs.

MATERIALS AND METHODS

Animals

Adult male Wistar rats (n=30) weighing 200-230 grams were used. They were got from animal residence, Faculty of Medicine, Sohag University, with room temperature kept at 22-28°C. Animals were kept in the normal light/dark cycle and were fed an ordinary animal diet with a free supply of water. The experiment was done in the Pharmacology department, and the protocol was approved by the Scientific Research Ethical Committee of the Faculty of Medicine, Sohag University, Egypt (Approval No. 5/2019), in conformity with the EU Directive 2010/63/EU on animal research.

Drugs and chemicals

Aluminum chloride (AlCl₃) was obtained from Alpha Chemika (Mumbai, India). AK Scientific, Inc, (USA) was the source of carvedilol. Catalase (CAT), lipid peroxidation; malondialdehyde (MDA), and nitric oxide (NO) kits were gained from Bio-diagnostic Co. Egypt. Wuhan EIAab Science Co. Ltd (China) provided a kit for measuring tumor necrosis factor-alpha (TNF- α). Kits for measuring total protein levels were purchased from the Egyptian Company for Biotechnology, Egypt. Cleaved caspase-3 primary antibody (E-AB-22115) and CD 117 (Cat #MA5-15894.) were purchased from Thermo scientific company, Neomarks, Fremont, USA

Experimental design

Rats were randomly classified into three groups (10 animals each). The Control group was daily treated with normal saline intraperitoneally (i.p.) for the all-time of the study. AlCl₃- treated group was daily injected with normal saline i.p. for two successive weeks followed by daily administration of AlCl₃ at a dose of 70 mg/kg/day i.p. for four successive weeks^[15]. The carvedilol+ AlCl₃ treated group received carvedilol 1 mg/kg i.p.^[16] for two consecutive weeks followed by carvedilol simultaneously with AlCl₃ for a further four successive weeks in the same previous doses and route.

Sample collection

Blood sample

At the completion of the experimental time, the studied animals of all groups were weighed and sacrificed by decapitation after anesthetization by inhaled diethyl ether. Blood samples were collected in labeled centrifuge tubes for measuring Al levels. The serum was separated following centrifugation of blood at 3500 rpm for 10 min and stored quickly at -20°C until the analysis time.

Tissue samples

The heart of each animal was rapidly dissected, washed with cold isotonic saline, and weighed. The hearts were divided into three portions. The first one was minced and homogenized in ice-cold sodium and potassium phosphate buffer (50mM, pH 7.4) per gram tissue (v/w) using

(Wise Tis HG-15D- Korea) Homogenizer. The homogenate was centrifuged at 10,000 rpm for 15 min at 4°C; the supernatant was separated for biochemical analysis. The second part was balanced and dehydrated in an oven at 80°C to determine the cardiac Al concentration. The third one was used for histopathological studies.

Determination of heart weight/body weight ratio

Heart and body weights were estimated then heart weight/body weight ratio was determined according to^[17] using the following formula:

$$\text{Heart weight / Bodyweight ratio} = \frac{(\text{Heart weight (mg)})}{(\text{Body weight (g)})}$$

Biochemical analysis

Determination of catalase (CAT) activity

Cardiac CAT activities were measured by the colorimetric method. The assay depends on the reaction of CAT with a known amount of H₂O₂. In the presence of peroxidase, the reaction is stopped using CAT inhibitor, and the remaining H₂O₂ interacts with 3,5-Dichloro-2-hydroxybenzene sulfonic acid and 4- amino-phenazone to produce a chromophore. The absorbance change was estimated at 510 nm. The activity of CAT in cardiac tissues was measured in U/mg tissue protein^[18].

Estimation of malondialdehyde (MAD)

According to Ohkawa and his coworkers, A colorimetric approach was used to evaluate MDA levels in cardiac tissues as a marker of oxidative stress^[19]. At 534 nm, changes in absorbance were recorded. However, the MDA level was estimated as nmol/ mg of tissue protein.

Determination of nitric oxide (NO) level

The concentrations of NO were measured in heart tissues by a colorimetric procedure^[20]. Variations in the absorbance were estimated at 540 nm. The concentration of Nitrite was demonstrated in $\mu\text{mol/mg}$ tissue protein.

Evaluation of tumor necrosis factor- α (TNF- α) level

The levels of TNF- α were measured using the monoclonal double-antibody sandwich ELIZA method as described by the manufacturer's prescriptions. TNF- levels in the cardiac tissue were measured using a Stat fax 2600 microplate reader (Awareness Technologies, Palm City, USA). TNF- levels were assessed in pg/mg tissue protein.

Determination of aluminum (Al) concentration

A PerkinElmer Atomic Absorption spectrometer (Analyst 4000, USA) with a 309.3 nm hollow cathode lamp was employed to measure Al levels in serum and cardiac tissues. At 80 degrees °C, 200 μl of serum or 1 g of heart tissue were dehydrated. For digestion, 2.5 ml of perchloric acid (HClO₄) and 30% nitric acid HNO₃ 4:1 were added to the samples at 100 °C for 5 minutes. The amounts of Al in the serum and cardiac tissue were expressed in $\mu\text{g/ml}$ and $\mu\text{g/mg}$ tissue, respectively^[21].

Measurement of total protein

The total protein level in cardiac tissue was measured by the Biuret technique and was used to demonstrate the concentration of different cardiac parameters per mg protein^[22].

Histological and immunohistochemical examination

Heart specimens were formalin-fixed and processed for histological and immunohistochemical examination according to^[23] as follows:

Histological studies

- Hematoxylin and eosin for general histological examination^[23].
- Masson trichrome for collagen fibers demonstration^[23].
- Toluidine blue for TCs demonstration^[24].

Immunohistochemical studies

- Active caspase 3 for apoptosis^[25].
- CD 117 for TCs immunostaining^[26].

Protocol for the immunohistochemical reaction

Slides were deparaffinized and rehydrated then retrieval of antigen was done by boiling the sections in citrate buffer (pH 6.2) in a microwave oven for 10 minutes. Endogenous peroxidase blocking was carried out by 2% hydrogen peroxide for 5 min. Sections were incubated overnight in the refrigerator with the primary CD117 (1:100) and for active caspase-3 antibody (1:150). Negative control was carried out by neglecting the primary antibodies. On the next morning, biotinylated secondary antibodies in a humid chamber were applied to sections. Enzyme conjugate streptavidin was added. The slides were stained with a substrate-chromogen mixture and then counterstained using a Hematoxylin reagent. The slides were rinsed in distilled water and dehydrated in ascending grades of alcohol. Clearing in xylene and mounting with coverslip were done. Positive cells for active caspase 3 showed brown nuclear coloration. CD 117 positive cells showed brown cytoplasmic coloration in the cell body and processes.

Morphometric study

The number of active caspase 3 positive cardiomyocytes, as well as the CD117 positive TCs were counted in 10 non-overlapping fields at x 400Magnification [25,26]. Area percentage of collagen fibers stained by masson trichrome were measured in heart sections tissue, in 18 non-overlapping fields at x 200Magnification^[27] using image software. All images were captured by Leica Microscope DFC310 FX 1.4-megapixel digital colour camera (Leica ICC50) and LAS EZ V 3.4.0 software application (Leica Microsystems), Germany Histology Department, Faculty of Medicine, Sohag University

Statistical analysis

All statistical examinations were done using the SPSS software package, version 25. Mean and standard deviation (S.D) were used to describe the data. The data were statistically examined using a one-way analysis of variance (ANOVA). A Tukey post hoc test was also employed to analyze differences between individual groups. The result was considered significant when the *P-value* was < 0.05.

RESULTS

Changes in heart and body weights

The heart weight in the AIC13-treated group significantly decreased ($P < 0.001$) compared to the control group, and administration of carvedilol produced a significant increase ($P < 0.001$) in the heart weight compared to the AIC13 -treated group (Table 1). Moreover, the final body weight decreased significantly ($P < 0.001$) in the AIC13-treated group compared to the control group. However, the carvedilol-treated group showed a significant increase ($P < 0.001$) in the final body weight compared to the AIC13 -treated group (Table 1).

Effect on heart weight /body weight ratio

The AIC13-treated group showed an insignificant change ($P = 0.962$) in heart weight /body weight ratio compared to the control group. Moreover, the carvedilol-treated group produced insignificant changes ($P = 0.838$) in heart weight /body weight ratio in comparison with the AIC13-treated group (Table 1).

Change in cardiac tissue catalase (CAT) activity

Cardiac tissue CAT activity significantly ($P < 0.001$) decreased in the AIC13-treated group compared to the control group. Administration of carvedilol produced a significant ($P < 0.001$) increase in the cardiac activity of tissue CAT compared to the AIC13 -treated group. On the other hand, there was a significant difference ($P = 0.0239$) between the Carvedilol+AIC13 and the control group (Figure 1).

Change in malondialdehyde (MDA) levels

As shown in (Figure 2), administration of AIC13 for four successive weeks produced a significant ($P < 0.001$) increase in cardiac tissue MDA level. Furthermore, administration of carvedilol for two weeks before and four weeks associated with AIC13 showed a significant ($P < 0.001$) decrease in MDA level in cardiac tissue. On the contrary, carvedilol administration simultaneously with AIC13 produced an insignificant change ($p = 0.0585$) in the MDA level compared to the control group.

Change in nitric oxide (NO) level

The AIC13-treated group showed a significant ($P < 0.001$) increase in cardiac tissue NO level compared to the control group. However, the carvedilol-treated group exhibited a significant ($P < 0.001$) decrease in cardiac tissue NO level. On the other side, carvedilol administration

concurrently with AlCl₃ resulted in a nonsignificant change ($p=0.0624$) in NO level compared to the control group (Figure 3).

Effect on tumor necrosis factor- α (TNF- α) level

The cardiac tissue level of TNF- α was significantly elevated ($P < 0.001$) in the AlCl₃-treated group in comparison to the control group. Treatment of the rats with carvedilol significantly ($P < 0.001$) decreased cardiac tissue TNF- α . On the other hand, there was a significant variation ($P < 0.05$) between the Carvedilol+AlCl₃ and the control group (Figure 4)

Change in aluminum (AL) concentration

Serum and cardiac AL concentrations in the AlCl₃-treated group were increased significantly ($P < 0.001$) compared to the corresponding control group. In the carvedilol-treated group, both serum and cardiac Al concentrations were decreased significantly ($P < 0.001$) and ($P < 0.05$) respectively compared to the corresponding AlCl₃-treated group, although, there was still a significant difference ($p < 0.001$) in serum and cardiac AL levels compared to the corresponding control group (Figures 5 A,B)

Histological results

H&E staining

The control group's H&E stained sections showed regularly arranged muscle fibers that appear branching and anastomosing. They have central vesicular nuclei and acidophilic sarcoplasm (Figures 6. A,D). AlCl₃ treated group examination revealed irregularly arranged muscle fibers with some fibers having pyknotic nuclei and vacuolated cytoplasm and focal disruption in some areas. Other fibers have dense pyknotic nuclei and deeply stained acidophilic cytoplasm. There was congestion of blood capillaries with perivascular inflammatory cell infiltration (Figures 6 B,E). carvedilol and AlCl₃ treated group examination revealed that most of the fibers appeared near the control group distinctly from inflammatory infiltrate in some areas and some fibers with pyknotic nuclei and deeply stained cytoplasm (Figures 6 C,F).

Masson trichrome staining

Masson trichrome stained sections examination of the control group showed few fine collagen fibers surrounding the cardiac fibers and blood vessels (Figure 7A). In the AlCl₃ treated group, there was an apparent increase in the area percentage of collagen fibers around muscle fibers and blood vessels compared to the control group (Figure 7B). carvedilol and AlCl₃ treated group examination showed an apparent decrease in area percentage of collagen fibers

compared to the previous group and near to the control group (Figure 7C).

Toluidine blue-staining

Toluidine blue-stained sections examination of the control group revealed cardiac TCs as oval cells with small cell bodies and long thin processes (Figure 8A). In the AlCl₃ treated group, there was an obvious reduction in their number compared to the control group, while both carvedilol and AlCl₃ treated group revealed an obvious increase in their number compared to the previous group and near to the control group (Figures 8B,C).

Immunohistochemical results

Active caspase-3

Examination of immunostained sections for active caspase 3 of the control group showed a few positive myocytes (Figure 9A). In the AlCl₃ treated group, there was a significant increase in their number compared to the control group, while the carvedilol and AlCl₃ treated group showed a significant decrease in their number compared to the previous group (Table 2, Figures 9 B,C).

CD 117 for Telocytes (TCs)

Examination of CD 117 immunostained sections of the control group showed TCs with brown coloration in the cytoplasm of their cell bodies and processes (Figure 10 A). AlCl₃ treated group examination exhibited a significant reduction in their number compared to the control group ($P < 0.001$) while AlCl₃ and carvedilol treated group showed a significant increase in their number compared to AlCl₃ ($P < 0.001$) (Table 2, Figures 10 B,C).

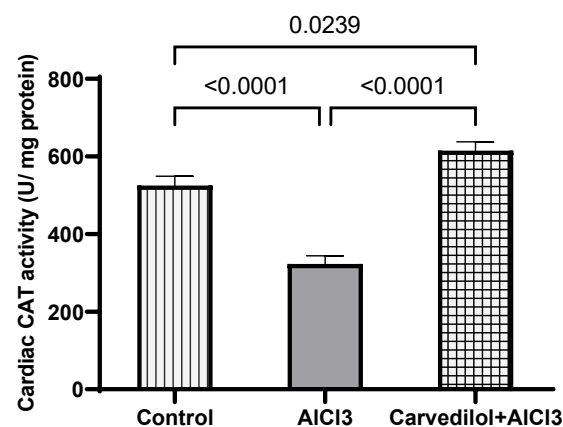


Fig. 1: Effect of carvedilol administration on cardiac CAT activity in the different experimental groups. All results are presented as the mean \pm SD ($n = 10$). Results were evaluated by one-way ANOVA accompanied by a post hoc Tukey test. $P < 0.05$ was considered as significant. CAT=catalase, AlCl₃=aluminum chloride.

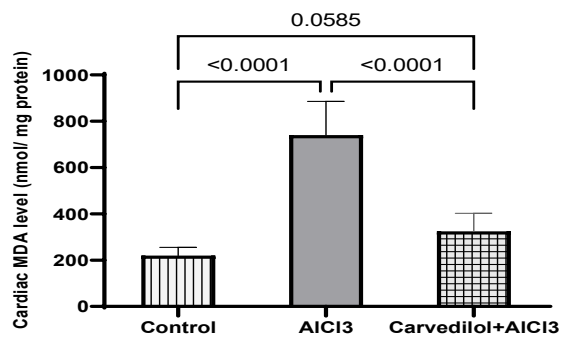


Fig. 2: Effect of carvedilol administration on cardiac MDA level in the different experimental groups All results are presented as the mean \pm SD (n = 10). Results were evaluated by one-way ANOVA accompanied by a post hoc Tukey test. $P < 0.05$ was considered as significant. AICl3=aluminum chloride. MDA= malondialdehyde.

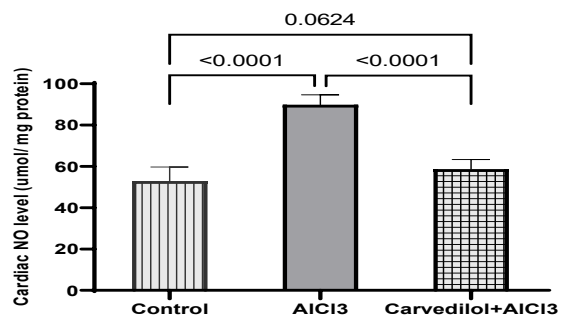


Fig. 3: Effect of carvedilol administration on cardiac NO level in the different experimental groups All results are presented as the mean \pm SD (n = 10). Results were evaluated by one-way ANOVA accompanied by a post hoc Tukey test. $P < 0.05$ was considered as significant. AICl3=aluminum chloride. NO= nitric oxide.

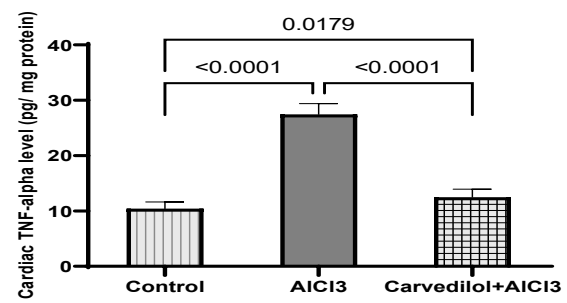


Fig. 4: Effect of carvedilol administration on cardiac TNF- α level in the different experimental groups All results are presented as the mean \pm SD (n = 10). Results were evaluated by one-way ANOVA accompanied by a post hoc Tukey test. $P < 0.05$ was considered as significant. AICl3=aluminum chloride. TNF- α = tumor necrosis factor-alpha.

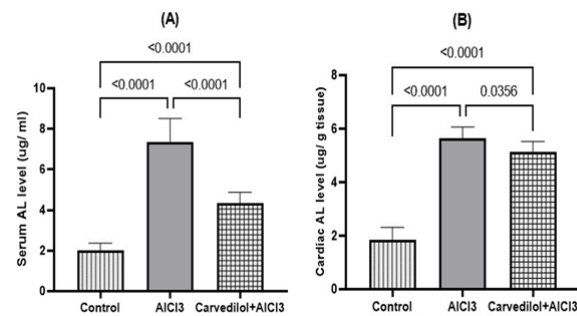


Fig. 5: Effect of carvedilol administration on serum and cardiac Aluminium levels in the different experimental groups. All results are presented as the mean \pm SD (n = 10). Results were evaluated by one-way ANOVA accompanied by a post hoc Tukey test. $P < 0.05$ was considered as significant. AICl3=aluminum chloride. AL= aluminum.

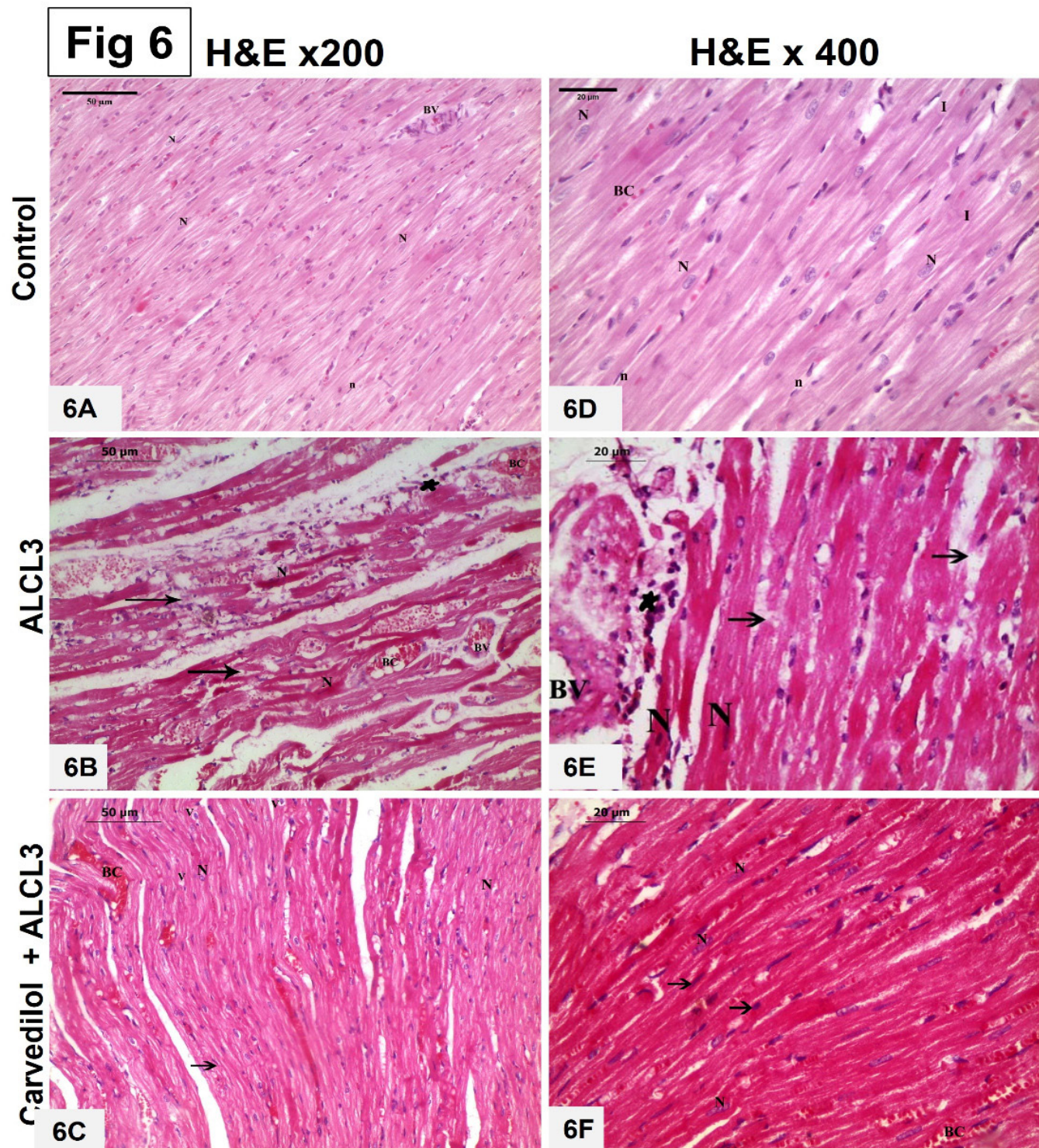


Fig. 6: Photomicrographs of H&E-stained Longitudinal sections in the myocardium of: the control group (6A & 6D) **6A:** Showing regular striated cardiac muscle fibers with central oval vesicular nuclei and acidophilic cytoplasm (N). Note, blood vessel (BV), nucleus of connective tissue cells in between cardiac myocytes (n) (Magnification x200 scale bar 50 μ m) **6D:** Higher magnification of the previous section of the control rat showing cardiac myocytes with central vesicular nuclei (N) and acidophilic cytoplasm. Blood capillaries (BC) and connective tissue cell nucleus (n) (Magnification x400, scale bar 20 μ m). AIC13 treated group (6B& 6E) **6B:** Showing irregular arranged cardiac myocytes with focal disruption (arrow), pyknotic nuclei(N) and deeply stained cytoplasm. Other myocytes have pyknotic nuclei (thin arrow) and vacuolated cytoplasm (V). Sections show dilated congested blood vessels and capillaries (BV, BC) respectively. Inflammatory cellular infiltration around the blood vessel and in between cardiac myocytes (*) (Magnification x200, scale bar 50 μ m). **6E:** Higher magnification of the previous section of AIC13 treated rat showing focal disruption of muscle fibers (arrow), perivascular inflammatory cell infiltration (*) and cardiac myocytes with deeply stained cytoplasm and dense pyknotic nuclei (N) (Magnification X400, scale bar 20 μ m). Carvedilol and AIC13 group (6C & 6F) **6C:** Showing regularly arranged cardiac myocytes with central vesicular nuclei and acidophilic cytoplasm. Some myocytes have pyknotic nuclei (arrow) and vacuolated cytoplasm (V). Some blood capillaries are dilated and congested (BC) (Magnification x 200, scale bar 50 μ m). **6F:** Higher magnification of the previous section showing myocytes with vesicular nuclei (N), some fibers with pyknotic nuclei and deeply stained cytoplasm (arrow). (Magnification x400, scale bar 20 μ m)

Fig 7

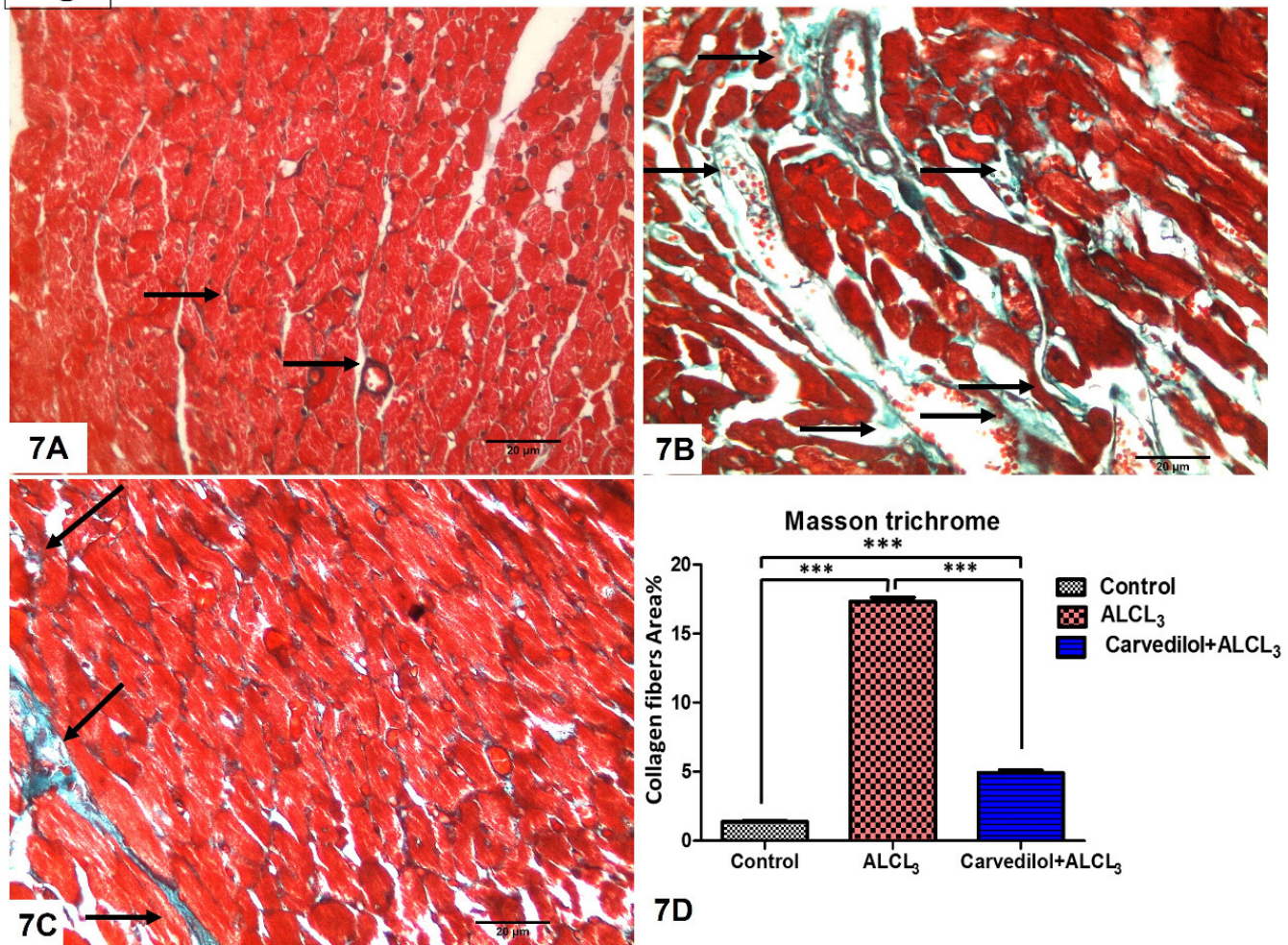


Fig. 7: Photomicrographs of TS sections in the myocardium stained with Masson trichrome: **7A:** The control group: showing few fine collagen fibers (green color) in between myocytes and blood vessels (arrow). **7B:** AlCl₃ treated group showing apparent increase in the area percentage collagen fibers (green color) around myocytes and blood vessels (arrow). **7C:** Carvedilol and AlCl₃ group showing apparent decrease in the area percentage of collagen fibers (green color) around myocytes and blood vessels (arrow) (Magnification x400, scale bar,20 μm) **7D:** graphical presentation of the mean percentage area of collagen fibers deposition in the different groups.

Fig 8

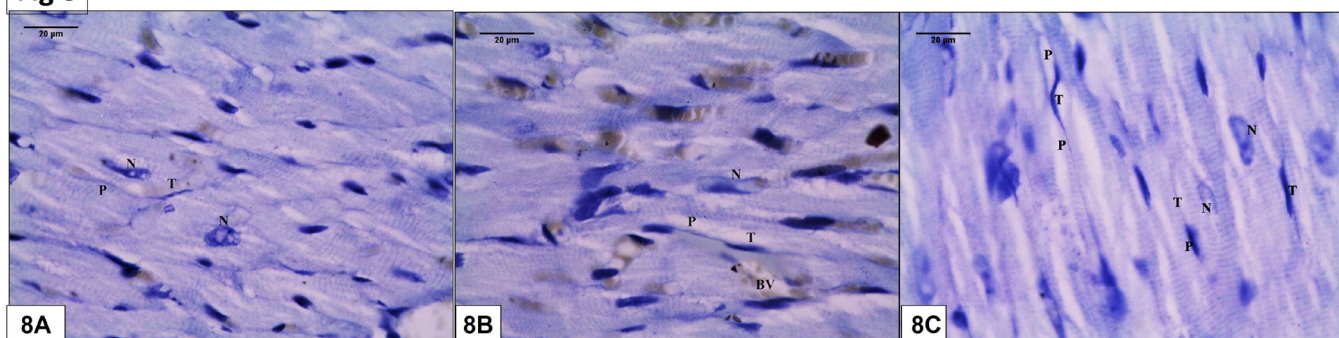


Fig. 8: Photomicrographs of longitudinal sections in the myocardium stained by toluidine blue: **8A:** Control group showing small elongated branched telocytes with small cell body (T) and long thin processes (P) in between the myocytes. Note, nucleus of cardiac myocytes (N). **8B:** AlCl₃ treated group apparently showing fewer number of telocytes compared to the control group. **8C:** Carvedilol and AlCl₃ group showing apparently increased number of telocytes compared to AlCl₃ treated group (TB magnification X400, scale bar 20 μm).

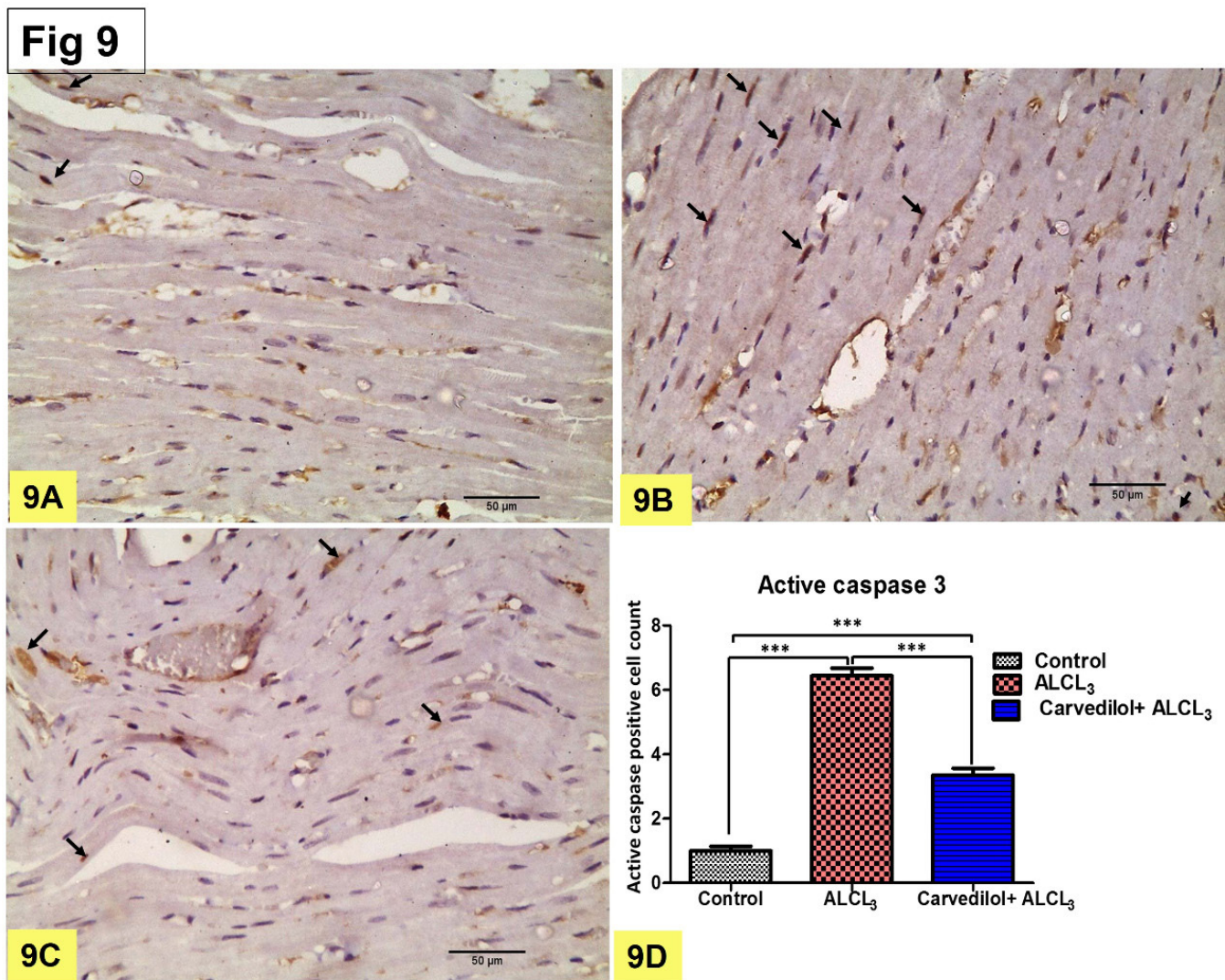


Fig 9: Photomicrographs of longitudinal sections in the myocardium stained by anti-active caspase3 immunohistochemistry: **9A:** control group, showing brown positive nuclear immune reaction in some myocytes (arrow). **9B:** ALCL₃ group, showing increased number of active caspase positive cardiac myocytes. **9C:** Carvedilol and ALCL₃ group, showing decreased number of positive myocytes (arrow). (Active Caspase 3 IHC x 400, scale bar 20 μm). **9D-**graphical presentation of the mean number of active caspase 3 positive cardiac myocytes in the different groups.

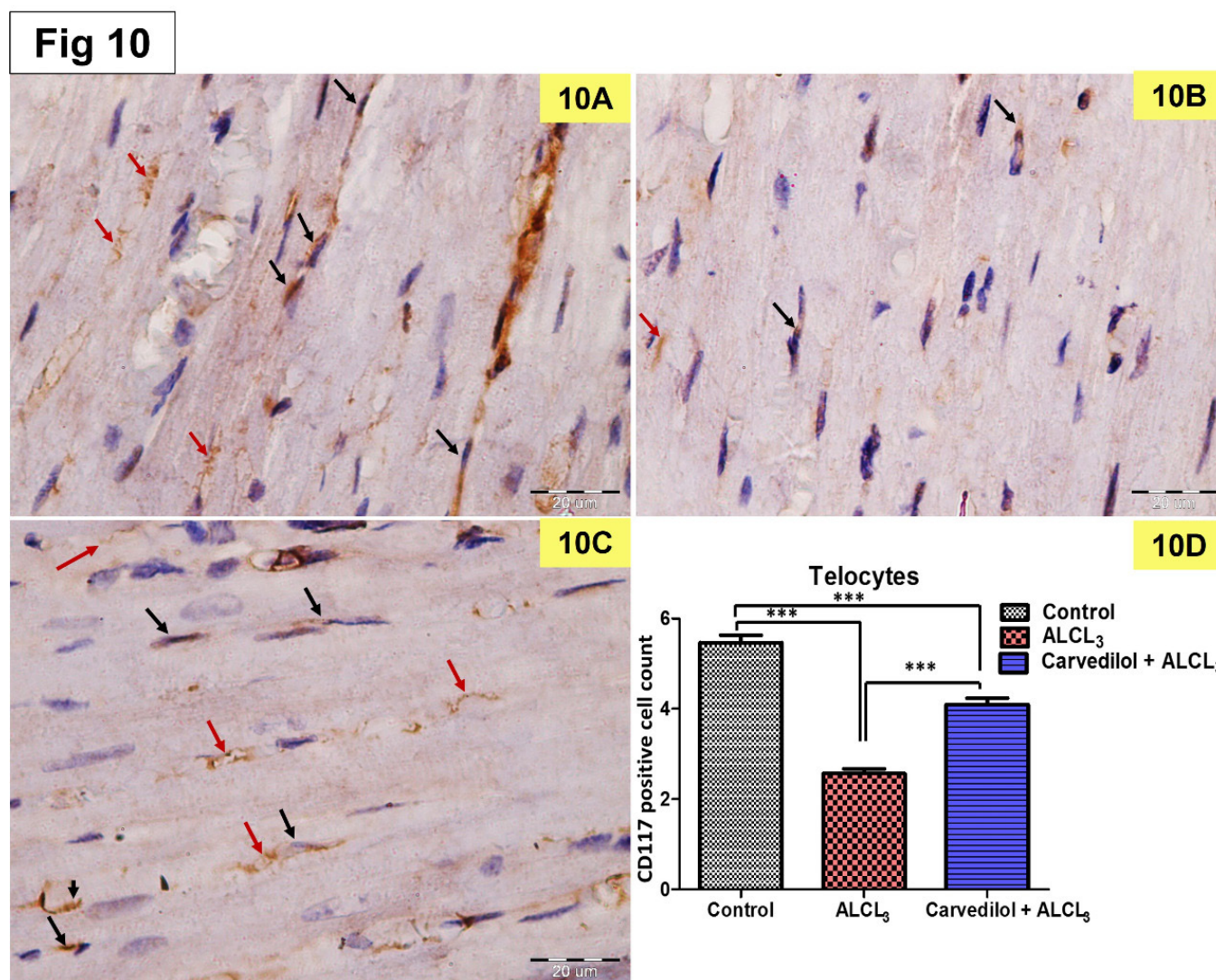


Fig. 10: Photomicrographs of longitudinal sections in the myocardium stained by anti CD117 antibody for telocytes: **10A:** control group showing brown positive cytoplasmic immunoreaction of telocytes cell body (black arrow) and their processes (red arrow). **10B:** AlCl₃ treated group apparently showing fewer number of immunoreactive telocytes compared to the control group. **10C:** Carvedilol and AlCl₃ group showing apparently increased number of telocytes compared to AlCl₃ treated group. (CD 117 IHC x400, scale bar 20 μm) **10D;** graphical presentation for the mean number of CD117 positive telocytes in the different groups.

Table 1: Effect of carvedilol administration on body weight, heart weight, and heart weight /body weight ratio in AlCl₃ -induced cardiac toxicity in rats

	Control	AlCl ₃	Carvedilol+AlCl ₃
Body weight (g)	339.20 ±8.59	250.10 ±16.58 (<i>P</i> =0.000) ^a	338.40 ±20.31 (<i>P</i> =0.993) ^a (<i>P</i> =0.000) ^b
Heart weight (mg)	1084.30 ±140.30	811.30 ±85.78 (<i>P</i> =0.000) ^a	1059.40 ±139.41 (<i>P</i> =0.896) ^a (<i>P</i> =0.000) ^b
Heart weight / body weight ratio (mg/g)	3.20 ±0.46	3.25 ±0.37 ^{ns} (<i>P</i> =0.962) ^a	3.14 ±0.48 ^{ns} (<i>P</i> =0.951) ^a (<i>P</i> =0.838) ^b

All results are presented as the mean ± SD (n = 10). Results were evaluated by one-way ANOVA accompanied by a post hoc Tukey test. *P* < 0.05 considered significant. a Significant versus the control group. b Significant versus AlCl₃-treated group. AlCl₃=aluminum chloride. ns= insignificant.

Table 2: Morphometric study and statistical analysis of the area percentage of collagen fibers, active caspase 3, and CD 117 positive cells

Parameters	Groups		
	Control group	AlCl ₃ treated group	Carvedilol+ AlCl ₃ treated group
Area percentage of collagen fibers	1.38±0.45	17.31±1.59 ^{***}	4.92±1.00 ^{###}
Active caspase 3 positive cells	1.00±0.79	6.4±1.33 ^{***}	3.30±1.18 ^{###}
CD 117 (c kit) positive cells	5.47±0.89	2.57±0.57 ^{***}	4.10±0.76 ^{###}

All results were compared as means ± SD , analyzed by SPSS one-way ANOVA test from all groups . Significant difference in AlCl₃ treated groups in comparison to control.(****P* < 0.001). Carvedilol treated ates group show significant difference in comparison to AlCl₃ group (### *P* < 0.001).

DISCUSSION

Aluminum has a wide environmental biological availability and extensive use with a common hazardous health problem^[4]. This research study was done to clarify the underlying biochemical and histological changes in heart tissue induced by AlCl₃ and the possible protective role of carvedilol with special insight on myocardial TCs. The present study showed that AlCl₃ administration led to a considerable decrease in the body and heart weights in comparison to the control group and carvedilol ameliorated these effects, which agree with the results of^[28,29]. These effects can be attributed to the effect of AlCl₃ on the bioavailability of some nutrients, and also may be due to dwindling appetite which affects the food intake of rats^[30].

On the other hand, the present results showed that AlCl₃ intake induced oxidant/antioxidant imbalance in the form of a significant decrease in catalase activity and increased NO and lipid peroxidation levels in the heart tissue. Our results are in harmony with the result of^[31,32]. Catalase is considered one of the main cellular safeguards against free radical-mediated oxidative stress and that could be attributed to reduced synthesis due to a decline in the expression of mRNA of endogenous antioxidants^[33]. Lipid peroxidation is the fundamental cause of aluminum-induced cell damage^[34]. The increased NO concentration in our study may be due to enhancing the expression of iNOS by AlCl₃^[35]. Carvedilol administration significantly amended the previous results that are in accordance with^[36,37], which demonstrated the ability of carvedilol to attenuate daunorubicin or anthracycline-induced oxidative stress by decreased cardiac and renal MDA levels and enhanced glutathione peroxidase activities. Furthermore, Ahmed & Mohammed, 2021 reported carvedilol decreased MDA and NO levels in serum and testicular tissue and explained that by induction of Nrf2 which controls the antioxidant system^[29]. Carvedilol's antioxidant action is due to the carbazole moiety in its molecule, which is about 10-fold more powerful than vitamin E as an antioxidant^[38].

Moreover, the present study revealed that AlCl₃ administration elevated TNF- α level in cardiac tissue compared to the control group which is significantly decreased by carvedilol. TNF- α can activate nuclear factor-B and raise intracellular ROS levels in endothelial cells, causing the expression of a wide range of pro-inflammatory genes^[39]. Our results agree with the results of^[40,41] who explained the cardioprotective effect of carvedilol through its anti-inflammatory effect via the reduction in the expression of TNF- α protein in cardiac tissue.

In the present study, AlCl₃ administration to the rats increased serum and heart tissue aluminum concentration compared to the control group, and the addition of carvedilol significantly decreased serum and cardiac tissue aluminum concentration. These results agree with^[42,43]. Nevertheless, the present findings are in disagreement with a study done by Ahmed & Mohammed (2021), who

showed that carvedilol treatment for 20 consecutive days couldn't affect aluminum levels where this effect may be explained by the short duration of carvedilol treatment^[29].

However, histological and morphological changes revealed AlCl₃-induced degeneration and apoptosis of cardiomyocytes and diffuse inflammatory cellular infiltration in the interstitial tissue between them. These findings are similar to previous studies on different organs^[3,44-46]. In addition, Masson's trichrome-stained cardiac sections revealed areas of massive collagen deposition between intercellular and perivascular interstices in the AlCl₃-treated group that decreased in the carvedilol-treated group. These results came in parallel with those^[47]. These effects can be explained by aluminum disrupting tissue mineral homeostasis, inducing excessive oxidative reactions, DNA damage, and cell death^[47]. Cardiomyocyte apoptosis represents the milestone in aluminum-induced cardiac toxicity and is indicated through caspase-3 activation. AlCl₃ administration revealed significant cardiomyocyte apoptosis which is proved by the immunohistochemical study of cleaved caspase-3. This effect is explained via the ability of AlCl₃ to induce both oxidative stresses^[48,49] and Ca²⁺ overload causing mitochondrial over-swelling and liberating cytochrome C (proapoptotic) to the cytoplasm. Cytochrome c activating caspase-proteins cascades initiate irreversible cardiomyocyte injury and apoptosis^[50].

In the present work, carvedilol ameliorates aluminum-induced cardiac inflammatory and fibrotic effects which confirmed our previous biochemical findings. These effects agree with other studies that were done on cardiomyopathy hereditary TO-2 hamster^[51] and heart failure with ischemia/reperfusion damage rats^[52]. These results can be explained via carvedilol's suppressive effect on pro- and anti-apoptotic proteins^[53].

Telocytes (TCs) "telopodic cells", are peculiar phenotypic stromal interstitial cells that have diverse physiological and structural functions^[54]. TCs gain increasing importance in regenerative medicine through their roles in intercellular communication, anti-apoptotic and pro-proliferative potentials^[55,56].

In this work, we focused on myocardial TCs' number and its affection along with degenerative and apoptotic changes by AlCl₃ induced intoxication. We found a significant decrease in cardiac TCs (CD117 positive immunoreactive cells) number in AlCl₃-supplied group with increased apoptosis and fibrosis. Similar results were obtained in cardiomyopathy-associated heart failure which showed absent TCs in areas of severe collagen deposition with increased apoptosis^[57].

Our results are inconsistent with other studies on different organs^[58,59], where cardiac fibrosis could be attributed to TCs down-regulation. However, carvedilol treatment increased the TCs number with subsequent reduction in cardiac apoptotic cells and fibrosis. This is similar to a significant decrease in the area of fibrosis of the infarction after TCs transplantation in post-infarcted rats^[58].

TCs can release different types of extracellular vesicles (ectosomes, exosomes, and multivesicular cargos) that are essential for myocardial cells to interplay in normal cardiac physiology and injury responses^[60]. Interestingly, intramyocardial delivery of exosome-derived factors reduced cardiomyocyte apoptosis and fibrosis and increased neovascularization in experimental myocardial infarction^[57,61–63].

CONCLUSION

In summary, our results have demonstrated that the heart is a potential target of AlCl₃-induced toxic accumulation and histological damage that could be primarily due to oxidative stress, inflammatory, and apoptotic effects of AlCl₃. However, carvedilol treatment produced protection through its antioxidant, antiapoptotic, and antiinflammatory combined with its regenerative role on myocardial TCs. These beneficial effects could be a therapeutic strategy for heavy metal deposition and intoxication in different vulnerable organs. One of the limitation of our study is lack of ultrastructural and *invitro* studies on telocytes. It is recommended in future studies to delineate the effect of heavy metal intoxication upon telocyte secretome and ultrastructure.

CONFLICT OF INTERESTS

There are no conflicts of interest.

REFERENCES

- Dagenais GR, Leong DP, Rangarajan S, Lanas F, Lopez-Jaramillo P, Gupta R, Diaz R, Avezum A, Oliveira GBF, Wielgosz A. Variations in Common Diseases, Hospital Admissions, and Deaths in Middle-Aged Adults in 21 Countries from Five Continents (PURE): A Prospective Cohort Study. *Lancet* 2020; 395(10226): 785–794. DOI: doi.org/10.1016/S0140-6736(19)32007-0
- Muselin F, Cristina RT, Igna V, Dumitrescu E, Brezovan D, Trif A. The Consequences of Aluminium Intake on Reproductive Function in Male Rats: A Three-Generation Study. *Turkish J. Med. Sci.* 2016; 46(4): 1240–1248. doi.org/10.3906/sag-1501-101
- Saad HM, Hassieb MM, Oda SS, Tohamy HG, Khafaga AF. Histopathologic Study on The Toxic Effect of Aluminium Chloride on the Heart, Liver and Kidneys of Rabbits. *Alexandria J. Vet. Sci.* 2018; 56(1). Doi: 10.5455/ajvs.2683
- Sivakumar S, Khatiwada CP, Sivasubramanian J. Studies the Alterations of Biochemical and Mineral Contents in Bone Tissue of Mus Musculus Due to Aluminum Toxicity and the Protective Action of Desferrioxamine and Deferiprone by FTIR, ICP-OES, SEM and XRD Techniques. *Spectrochim. Acta Part A Mol. Biomol. Spectrosc.* 2014; 126: 59–67. Doi. org/10.1016/j.saa.2014.01.136
- Martinez CS, Vera G, Ocio JAU, Peçanha FM, Vassallo DV, Miguel M, Wiggers GA. Aluminum Exposure for 60 Days at an Equivalent Human Dietary Level Promotes Peripheral Dysfunction in Rats. *J. Inorg. Biochem.* 2018; 181: 169–176. Doi.org/10.1016/j.jinorgbio.2017.08.011
- Avila MS, Ayub-Ferreira SM, de Barros Wanderley MR, das Dores Cruz F, Gonçalves Brandão SM, Rigaud VOC, Higuchi-dos-Santos MH, Hajjar LA, Kalil Filho R, Hoff PM. Carvedilol for Prevention of Chemotherapy-Related Cardiotoxicity: The CECCY Trial. *J. Am. Coll. Cardiol.* 2018; 71(20): 2281–2290. doi: 10.1016/j.jacc.2018.02.049.
- Dandona P, Ghanim H, Brooks DP. Antioxidant Activity of Carvedilol in Cardiovascular Disease. *J. Hypertens.* 2007; 25(4): 731–741. DOI: 10.1097/HJH.0b013e3280127948
- Araújo Júnior RF de, Souza TO, Medeiros CAX de, Souza LB de, Freitas M de L, de Lucena HF, do Socorro Costa Feitosa Alves M, de Araújo AA. Carvedilol Decrease IL-1 β and TNF- α , Inhibits MMP-2, MMP-9, COX-2, and RANKL Expression, and up-Regulates OPG in a Rat Model of Periodontitis. *PLoS One* 2013; 8(7): e66391. Doi.org/10.1371/journal.pone.0066391
- Díaz-Flores L, Gutiérrez R, Díaz-Flores Jr L, Gómez MG, Sáez FJ, Madrid JF. Behaviour of Telocytes during Physiopathological Activation. In: *Semin. Cell Dev. Biol.*, vol. 55. Elsevier 2016; 50–61. https://doi.org/10.1016/j.semcdb.2016.01.035
- Kostin S. Cardiac Telocytes in Normal and Diseased Hearts. In: *Semin. Cell Dev. Biol.*, vol. 55. Elsevier 2016; 22–30. Doi.org/10.1016/j.semcdb.2016.02.023
- Kucybala I, Janas P, Ciuk S, Cholopiak W, Klimek-Piotrowska W, Holda MK. A Comprehensive Guide to Telocytes and Their Great Potential in Cardiovascular System. *Bratisl. Lek. Listy* 2017; 118(5): 302–309. https://doi.org/10.4149/bll_2017_059
- Sanches BDA, Maldarine JS, Zani BC, Tamarindo GH, Biancardi MF, Santos FCA, Rahal P, Góes RM, Felisbino SL, Vilamaior PSL. Telocytes Play a Key Role in Prostate Tissue Organisation during the Gland Morphogenesis. *J. Cell. Mol. Med.* 2017; 21(12): 3309–3321. Doi.org/10.1111/jcmm.13234
- Vannucchi M-G, Bani D, Fausson-Pellegrini M-S. Telocytes Contribute as Cell Progenitors and Differentiation Inductors in Tissue Regeneration. *Curr. Stem Cell Res.* DOI: 10.2174/1574888x10666150528142741
- Aleksandrovych V, Pasternak A, Basta P, Sajewicz M, Walocha JA, Gil K. Telocytes: Facts, Speculations and Myths. *Folia Med. Cracov.* 2017; 57(1).15

15. Ali AA, Ahmed HI, Khalil MG, Alwakeel AI, Elfotuh KA. Comparative Study on the Influence of Epigallocatechin-3-Gallate and/or Coenzyme Q10 against Alzheimer's Disease Induced by Aluminium in Normally-Fed and Protein Malnourished Rats. *J Alzheimers Dis Park.* 2016; 6(240): 460–2161. DOI: 10.4172/2161-0460.1000240
16. Veerendra Kumar MH, Gupta YK. Effect of Centella Asiatica on Cognition and Oxidative Stress in an Intracerebroventricular Streptozotocin Model of Alzheimer's Disease in Rats. *Clin. Exp. Pharmacol. Physiol.* 2003; 30(5–6): 336–342. /doi.org/10.1046/j.1440-1681.2003.03842.x
17. Anandh Babu P V., Sabitha KE, Shyamaladevi CS. Green Tea Extract Impedes Dyslipidaemia and Development of Cardiac Dysfunction in Streptozotocin-Diabetic Rats. *Clin. Exp. Pharmacol. Physiol.* 2006; 33(12): 1184–1189.
18. Aebi H. [13] Catalase in *Vitro*. *Methods Enzymol.* 1984; 105: 121–126.
19. Ohkawa H, Ohishi N, Yagi K. Assay for Lipid Peroxides in Animal Tissues by Thiobarbituric Acid Reaction. *Anal. Biochem.* 1979; 95(2): 351–358.
20. Montgomery H, Dymock JF. Determination of Nitrite in Water. *Analyst* 1961; 86(102): 414.
21. Zhu YZ, Sun H, Fu Y, Wang J, Song M, Li M, Li YF, Miao LG. Effects of Sub-Chronic Aluminum Chloride on Spermatogenesis and Testicular Enzymatic Activity in Male Rats. *Life Sci.* 2014; 102(1): 36–40.
22. Gornall AG, Bardawill CJ, David MM. Determination of Serum Proteins by Means of the Biuret Reaction. *J. Biol. Chem.* 1949; 177(2): 751–766.
23. Suvarna KS, Layton C, Bancroft JD. Bancroft's Theory and Practice of Histological Techniques E-Book. Elsevier Health Sciences 2018.
24. Popescu LM, Fausone-Pellegrini M. TELOCYTES—a Case of Serendipity: The Winding Way from Interstitial Cells of Cajal (ICC), via Interstitial Cajal-Like Cells (ICLC) to TELOCYTES. *J. Cell. Mol. Med.* 2010; 14(4): 729–740. /doi.org/10.1111/j.1582-4934.2010.01059.x
25. Gebril SM, Ito Y, Shibata M, Maemura K, Abu-Dief EE, Hussein MRA, Abdelaal UM, Elsayed HM, Otsuki Y, Higuchi K. Indomethacin Can Induce Cell Death in Rat Gastric Parietal Cells through Alteration of Some Apoptosis-and Autophagy-associated Molecules. *Int. J. Exp. Pathol.* 2020; 101(6): 230–247. doi.org/10.1111/iep.12370
26. Hussein MM, Mokhtar DM. The Roles of Telocytes in Lung Development and Angiogenesis: An Immunohistochemical, Ultrastructural, Scanning Electron Microscopy and Morphometrical Study. *Dev. Biol.* 2018; 443(2): 137–152. https://doi.org/10.1016/j.ydbio.2018.09.010
27. Abdel-Motaleb AA, Zedan H, Mostafa MM, Abu-Dief EE, Gebril SM, Abdelwahed Hussein MR. Combined Microneedling with Topical Application of Platelet-Rich Plasma versus Microneedling Alone in the Treatment of Stria Distensae: Clinicopathological Analysis. *J. Dermatolog. Treat.* 2022; 33(2): 836–847. https://doi.org/10.1080/09546634.2020.1782323
28. Sajjad S, Malik H, Saeed L, Hashim I, Farooq U, Manzoor F. Synergistic Potential of Propolis and Vitamin E Against Sub-Acute Toxicity of AlCl₃ in Albino Mice: In *Vivo* Study. *Physiol. Res.* 2019; 68(1): 67–74. doi: 10.33549/physiolres.933863
29. Ahmed SA, Mohammed WI. Carvedilol Induces the Antiapoptotic Proteins Nrf2 and Bcl2 and Inhibits Cellular Apoptosis in Aluminum-Induced Testicular Toxicity in Male Wistar Rats. *Biomed. Pharmacother.* 2021; 139: 111594. https://doi.org/10.1016/j.biopha.2021.111594
30. Aita NAA. Hepatoprotective Effect of Spirulina Platensis against Aluminum Chloride Induced Liver Damage in Rats. *Glob. Vet.* 2014; 13(4): 552–559.
31. Azad A, Lall SB, Mittra S. Effect of N-Acetylcysteine and L-NAME on Aluminium Phosphide Induced Cardiovascular Toxicity in Rats. *Acta Pharmacol. Sin.* 2001; 22(4): 298–304.
32. Ghorbel I, Elwej A, Chaabane M, Jamoussi K, Zeghal N. Protective Effect of Selenium against Aluminium Chloride Induced Cardiotoxicity in Rats. *Pharm. Biomed. Res.* 2017; 3(2): 19–25. DOI: 10.29252/pbr.3.2.19
33. Gonzalez MA, Alvarez M del L, Pisani GB, Bernal CA, Roma MG, Carrillo MC. Involvement of Oxidative Stress in the Impairment in Biliary Secretory Function Induced by Intraperitoneal Administration of Aluminum to Rats. *Biol. Trace Elem. Res.* 2007; 116(3): 329–348 doi: 10.1007/BF02698017
34. Newairy A-SA, Salama AF, Hussien HM, Yousef MI. Propolis Alleviates Aluminium Induced Lipid Peroxidation and Biochemical Parameters in Male Rats. *Food Chem. Toxicol.* 2009; 47(6): 1093–1098. DOI: 10.1016/j.fct.2009.01.032
35. Al- Olayan EM, El- Khadragy MF, Abdel Moneim AE. The Protective Properties of Melatonin against Aluminium- induced Neuronal Injury. *Int. J. Exp. Pathol.* 2015; 96(3): 196–202. doi: 10.1111/iep.12122
36. Arozal W, Watanabe K, Veeraveedu PT, Ma M, Thandavarayan RA, Sukumaran V, Suzuki K, Kodama M, Aizawa Y. Protective Effect of Carvedilol on Daunorubicin Induced Cardiotoxicity and Nephrotoxicity in Rats. *Toxicology* 2010; 274(1–3): 18–26. DOI: 10.1016/j.tox.2010.05.003

37. Kalay N, Basar E, Ozdogru I, Er O, Cetinkaya Y, Dogan A, Oguzhan A, Eryol NK, Topsakal R, Ergin A. Protective Effects of Carvedilol against Anthracycline-Induced Cardiomyopathy. *J. Am. Coll. Cardiol.* 2006; 48(11): 2258–2262 <https://doi.org/10.1016/j.jacc.2006.07.052>
38. Kumar A, Dogra S. Neuroprotective Effect of Carvedilol, an Adrenergic Antagonist against Colchicine Induced Cognitive Impairment and Oxidative Damage in Rat. *Pharmacol. Biochem. Behav.* 2009; 92(1): 25–31. DOI: 10.1016/j.pbb.2008.10.005
39. Lin P-Y, Shen H-C, Chen C-J, Wu S-E, Kao H-L, Huang J-H, Wang DL, Chen S-C. The Inhibition in Tumor Necrosis Factor- α -Induced Attenuation in Endothelial Thrombomodulin Expression by Carvedilol Is Mediated by Nuclear Factor-KB and Reactive Oxygen Species. *J. Thromb. Thrombolysis* 2010; 29(1): 52–59 DOI: 10.1007/s11239-009-0318-2
40. Cinquegrana G, D'Aniello L, Landi M, Spinelli L, Grande G, De Prisco F, Petretta M. Effects of Different Degrees of Sympathetic Antagonism on Cytokine Network in Patients with Ischemic Dilated Cardiomyopathy. *J. Card. Fail.* 2005; 11(3): 213–219. DOI: 10.1016/j.cardfail.2004.07.006
41. Sari FR, Arozal W, Watanabe K, Harima M, Veeravedu PT, Thandavarayan RA, Suzuki K, Arumugam S, Soetikno V, Kodama M. Carvedilol Attenuates Inflammatory-Mediated Cardiotoxicity in Daunorubicin-Induced Rats. *Pharmaceuticals* 2011; 4(3): 551–566. doi: 10.3390/ph4030551
42. Kumar A, Prakash A, Dogra S. Neuroprotective Effect of Carvedilol against Aluminium Induced Toxicity: Possible Behavioral and Biochemical Alterations in Rats. *Pharmacol. Reports* 2011; 63(4): 915–923. DOI: 10.1016/s1734-1140(11)70607-7
43. Singh T, Goel RK. Neuroprotective Effect of *Allium Cepa L.* in Aluminium Chloride Induced Neurotoxicity. *Neurotoxicology* 2015; 49: 1–7. DOI: 10.1016/j.neuro.2015.04.007
44. Cheng D, Zhu C, Cao J, Jiang W. The Protective Effects of Polyphenols from Jujube Peel (*Ziziphus Jujube Mill*) on Isoproterenol-Induced Myocardial Ischemia and Aluminum Induced Oxidative Damage in Rats. *Food Chem. Toxicol.* 2012; 50(5): 1302–1308. DOI: 10.1016/j.fct.2012.01.026
45. Kutlubay R, Oğuz EO, Güven C, Can B, Sinik Z, Tuncay ÖL. Histological and Ultrastructural Evidence for Protective Effects on Aluminium-Induced Kidney Damage by Intraperitoneal Administration of α -Tocopherol. *Int. J. Toxicol.* 2007; 26(2): 95–101 DOI: 10.1080/10915810701221173
46. Geyikoglu F, Türkez H, Bakir TO, Cicek M. The Genotoxic, Hepatotoxic, Nephrotoxic, Haematotoxic and Histopathological Effects in Rats after Aluminium Chronic Intoxication. *Toxicol. Ind. Health* 2013; 29(9): 780–791. Doi.org/10.1177/0748233712440140
47. Novaes RD, Mouro VGS, Gonçalves R V, Mendonça AAS, Santos EC, Fialho MCQ, Machado-Neves M. Aluminum: A Potentially Toxic Metal with Dose-Dependent Effects on Cardiac Bioaccumulation, Mineral Distribution, DNA Oxidation and Microstructural Remodeling. *Environ. Pollut.* 2018; 242: 814–826. Doi.org/10.1016/j.envpol.2018.07.034
48. Zhou L, He M, Li X, Lin E, Wang Y, Wei H, Wei X. Molecular Mechanism of Aluminum-Induced Oxidative Damage and Apoptosis in Rat Cardiomyocytes. *Biol. Trace Elem. Res.* 2022; 200(1): 308–317. DOI: 10.1007/s12011-021-02646-w
49. Zhang M, Zhu J, Qin X, Zhou M, Zhang X, Gao Y, Zhang T, Xiao D, Cui W, Cai X. Cardioprotection of Tetrahedral DNA Nanostructures in Myocardial Ischemia-Reperfusion Injury. *ACS Appl. Mater. Interfaces* 2019; 11(34): 30631–30639. <https://doi.org/10.1021/acsami.9b10645>
50. Weiss JN, Korge P, Honda HM, Ping P. Role of the Mitochondrial Permeability Transition in Myocardial Disease. *Circ. Res.* 2003; 93(4): 292–301. <https://doi.org/10.1161/01.RES.0000087542.26971.D4>
51. Nanjo S, Yamazaki J, Yoshikawa K, Ishii T, Togane Y. Carvedilol Prevents Myocardial Fibrosis in Hamsters. *Int. Heart J.* 2006; 47(4): 607–616. <https://doi.org/10.1536/ihj.47.607>
52. Bellenger NG, Rajappan K, Rahman SL, Lahiri A, Raval U, Webster J, Murray GD, Coats AJS, Cleland JGF, Pennell DJ. Effects of Carvedilol on Left Ventricular Remodelling in Chronic Stable Heart Failure: A Cardiovascular Magnetic Resonance Study. *Heart* 2004; 90(7): 760–764. DOI: 10.1136/hrt.2003.015552
53. Endo R, Bahrudin U, Notsu T, Tanno S, Onohara T, Yamaguchi S, Ikeda N, Surastrri B, Nakayama Y, Ninomiya H. Carvedilol Suppresses Apoptosis and Ion Channel Remodelling of HL-1 Cardiac Myocytes Expressing E334K CM β PC. *Drug Res. (Stuttg.)* 2016; 66(03): 126–129. DOI: 10.1055/s-0035-1555772
54. Cretoiu SM, Popescu LM. Telocytes Revisited. *Biomol. Concepts* 2014; 5(5): 353–369. DOI: 10.1515/bmc-2014-0029
55. Bei Y, Wang F, Yang C, Xiao J. Telocytes in Regenerative Medicine. *J. Cell. Mol. Med.* 2015; 19(7): 1441–1454. Doi.org/10.1111/jcmm.12594
56. Ibba-Manneschi L, Rosa I, Manetti M. Telocytes in Chronic Inflammatory and Fibrotic Diseases. *Telocytes* 2016; 51–76. Doi: 10.1007/978-981-10-1061-3_4
57. Bei Y, Zhou Q, Sun Q, Xiao J. Telocytes in Cardiac Regeneration and Repair. In: *Semin. Cell Dev. Biol.*, vol. 55. Elsevier 2016; 14–21. DOI: 10.1007/978-981-10-1061-3_4

58. Zhao B, Liao Z, Chen S, Yuan Z, Yilin C, Lee KKH, Qi X, Shen X, Zheng X, Quinn T. Intramyocardial Transplantation of Cardiac Telocytes Decreases Myocardial Infarction and Improves Post-infarcted Cardiac Function in Rats. *J. Cell. Mol. Med.* 2014; 18(5): 780–789. DOI: 10.1111/jcmm.12259
59. Fu S, Wang F, Cao Y, Huang Q, Xiao J, Yang C, Popescu LM. Telocytes in Human Liver Fibrosis. *J. Cell. Mol. Med.* 2015; 19(3): 676–683. DOI: 10.1111/jcmm.12542
60. Cervio E, Barile L, Moccetti T, Vassalli G. Exosomes for Intramyocardial Intercellular Communication. *Stem Cells Int.* 2015; 2015. DOI: 10.1155/2015/482171
61. Barile L, Lionetti V, Cervio E, Matteucci M, Gherghiceanu M, Popescu LM, Torre T, Siclari F, Moccetti T, Vassalli G. Extracellular Vesicles from Human Cardiac Progenitor Cells Inhibit Cardiomyocyte Apoptosis and Improve Cardiac Function after Myocardial Infarction. *Cardiovasc. Res.* 2014; 103(4): 530–541. Doi.org/10.1093/cvr/cvu167
62. Teng X, Chen L, Chen W, Yang J, Yang Z, Shen Z. Mesenchymal Stem Cell-Derived Exosomes Improve the Microenvironment of Infarcted Myocardium Contributing to Angiogenesis and Anti-Inflammation. *Cell. Physiol. Biochem.* 2015; 37(6): 2415–2424. Doi.org/10.1159/000438594
63. Wang Y, Zhang L, Li Y, Chen L, Wang X, Guo W, Zhang X, Qin G, He S, Zimmerman A. Exosomes/Microvesicles from Induced Pluripotent Stem Cells Deliver Cardioprotective MiRNAs and Prevent Cardiomyocyte Apoptosis in the Ischemic Myocardium. *Int. J. Cardiol.* 2015; 192: 61–69. Doi.org/10.1016/j.ijcard.2015.05.020

الملخص العربي

دور الخلايا المذيلة القلبية والالتهاب وموت الخلايا المبرمج في تأثير كارفيديلول الوقائي ضد سمية عضلة القلب التي يسببها كلوريد الألمونيوم في ذكور جرذان ويستار

هدى محمد السيد^١، ولاء ابراهيم محمد^٢، سحر محمد جبريل^١، سناء عبدالعال أحمد^٢

^١قسم علم الأنسجة وبيولوجيا الخلية، ^٢قسم الفارما الاكلينيكية - كلية الطب- جامعة سوهاج

المقدمة: يعتبر الألمونيوم من المعادن الأكثر انتشاراً في البيئة وقد ارتبط التعرض لهذا المعدن بمجموعة متنوعة من الأمراض، بما في ذلك أمراض القلب والأوعية الدموية. تمثل القدرة التجديدية لخلايا القلب المذيلة الأمل في علاج بعض أمراض القلب.

الهدف: ركز هذا العمل على تقييم دور عقار الكارفيديلول في الحماية ضد سمية القلب التي تسببها مادة ثلاثي كلوريد الألمونيوم من خلال عمل هذا العقار كمضاد للأكسدة ومضاد للالتهابات وأيضاً قدرته على تنظيم موت الخلايا المبرمج وبالإضافة إلى تأثيره على الخلايا المذيلة (تيلوسيتس) القلبية.

المواد والطرق: تم تقسيم ثلاثين من ذكور الجرذان البالغة بشكل عشوائي إلى ثلاث مجموعات تحتوي كل مجموعة على عشرة جرذان. المجموعة الأولى الضابطة: تم حقنها بمحلول ملحي. كما تلقت المجموعة الثانية محلول ملحي لمدة أسبوعين متتاليين يليها ٧٠ ملجم / كجم / يوم من مادة ثلاثي كلوريد الألمونيوم لمدة أربعة أسابيع متتالية. كما تلقت المجموعة الثالثة كارفيديلول لمدة أسبوعين متتاليين متبوعاً بالكارفيديلول ١ مجم / كجم متزامناً مع ثلاثي كلوريد الألمونيوم لمدة أربعة أسابيع متتالية. ولقد تم حقن جميع الأدوية بالغشاء البريتوني. في نهاية التجربة، تم تقييم مستوى مضادات الأكسدة البيوكيميائية في الدم، ومستوى الالتهابات والألمونيوم بالإضافة إلى ذلك، تم عمل فحص أنسجة القلب والكيمياء المناعية (كاسباسيز ٣ و CD١١٧ النشطة) وقياساتها.

النتائج: أدى تناول ثلاثي كلوريد الألمونيوم إلى أحداث زيادة ذات دلالة احصائية في مستويات المالونداهيد القلبية، وأكسيد النيتريك، ومستويات عامل نخر الورم ألفا. إلى جانب ذلك، تم أحداث زيادة في مستويات الألمونيوم في الدم والقلب بشكل كبير. وعلى النقيض من ذلك، انخفضت بشكل ملحوظ أوزان القلب والجسم ومستويات إنزيم القلب كاسبيز. علاوة على ذلك، أظهرت الدراسة النسيجية أن ثلاثي كلوريد الألمونيوم تسبب في حدوث تغيرات تنكسية وموت الخلايا المبرمج في عضلات القلب مع ارتفاع معنوي في النسبة المئوية لمساحة ألياف الكولاجين. بالإضافة إلى ذلك، لوحظ زيادة كبيرة في الخلايا الميتة وانخفاض في خلايا عضلة القلب. كما استطاع عقار الكارفيديلول من تحسين القياسات الكيميائية وتحسين التغيرات النسيجية.

الخلاصة: تمكن عقار الكارفيديلول من حماية القلب ضد زيادة موت الخلايا المبرمج والتليف في عضلة القلب وقد ارجع هذا إلى تأثيراته المضادة للأكسدة والمضادة للالتهابات ومضادات موت الخلايا المبرمج بالإضافة إلى قدرته على زيادة الخلايا المذيلة القلبية وقدرتها على التجدد.