

## ROLE OF MRI DIFFUSION TENSOR IMAGING IN ASSESSMENT OF RESPONSE OF NORMAL APPEARING WHITE MATTER IN CASE OF MULTIPLE SCLEROSIS.

*Mona M. Alsherif, Eman Soliman, Remon Z. Elia and Mona A. Nagi*

---

### ABSTRACT:

Department of Radio-diagnosis,  
Faculty of Medicine, Ain Shams  
University, Cairo, Egypt.

**Corresponding author:**

Mona Mahmoud Hassan Alsherif  
**Mobile:** +201002850795

**E.mail:**

mmmmma2830@gmail.com

Received: 5/4/2022

Accepted: 10/5/2022

**Online ISSN: 2735-3540**

**Background:** Multiple sclerosis (MS) is an autoimmune inflammatory demyelinating disease of brain & spinal cord. Conventional MRI (T1, T2, FLAIR, enhancedT1) provides information of morphology of demyelinating plaques, but irrelevant to give details about normal WM tracts which are involved pathologically in the MS process. Diffusion MRI, DTI are widely used non-conventional MRI techniques which provide better solution for studying normal appearing white matter. Diffusion tensor imaging (DTI) reflects water diffusion within tissues therefore any white matter fibers alterations will be visible within it before conventional techniques.

**Aim of the work:** evaluation of normal appearing white matter of the brain in MS patients by diffusion tensor imaging examination thus assessing its ability to detect early abnormalities.

**Patients & Methods:** the study included 30 patients; 21 females and 9 males having MS (between 22 and 48 years of age) with 25 years control healthy volunteer. MR examination was in standard 3 Tesla units (Acheiva, Philips). Technique included: Conventional MR examination and Diffusion Tensor imaging.

**Results:** our study showed that DTI provide details about early affection of normal appearing white matter in MS cases when no visible plaques are detected in conventional MRI.

**Conclusion:** There is a strong relationship between clinical status of patients & diffusion tensor imaging readings especially in case of deterioration in course of disease & no new visible changes can be detected in conventional MRI.

**Keywords:** Multiple sclerosis, MRI-Diffusion tensor imaging, Fractional anisotropy, Apparent diffusion coefficient, normally appearing white matter.

---

### INTRODUCTION:

Multiple sclerosis (MS) is a chronic inflammatory demyelinating disease of the central nervous system, it is the most common cause of non-traumatic disability in middle-age individuals. MS is estimated to affect more than 2 million worldwide. In Egypt, a study was conducted in 2019 revealed that MS cases were 1.4% of all neurological diseases<sup>[1]</sup>.

Although the role of clinical management & scientific investigation of MS increasing, but still conventional magnetic resonance imaging (MRI) is of limited association with clinical progression of cases, also it has low sensitivity & specificity in normal-appearing white matter affection, but diffusion tensor imaging (DTI) technique found to be more sensitive in identifying the tissue damage (normally

appearing white matter in conventional techniques of MRI<sup>[2]</sup>.

Fractional anisotropy (FA) (one of DTI quantitative indices) evaluate widespread tissue damage outside the lesions seen by conventional MRI, it measures the directionality of diffusion inside tissues<sup>[3]</sup>.

Micro structural changes in NAWM (normal appearing white matter ) in early stages of MS detected by diffusion tensor image technique are seen in all types of MS, however diffusion parameters differ according to MS phenotype (MS subtypes demonstrate different diffusivity patterns), So diffusion indices represent important markers of MS phenotype. In addition, combination of diffusion measures & other conventional MRI findings & clinical progression of cases give complementary information on different types of pathological damage according to MS type, so DTI measures have been identified as prognostic markers of disease course and as a means of monitoring anatomical changes over time<sup>[4]</sup>.

---

## **MATERIAL AND METHODS:**

The current study conducted on Thirty patients 19 females and 11 males having MS (between 22 and 48 years old) referred from Neurologists to Ain Shams University Radiodiagnosis Department and 25 ages' matched healthy control volunteer over a period of 24 months (February 2020–February 2021).

Each patients included in the study subjected to:

- Written informed consent before participation.
- Fullhistory taking.
- Reviewing medical sheet whenever available.
- Revise of theirs laboratory results including renal function tests and

previous radiological investigation.

- Inclusion criteria: Known cases of MS.
- Exclusion criteria: Claustrophobic patients and MS patients with another brain parenchymal pathology, e.g. brain neoplasm.
- MR examination using a 3 Tesla unit (Philips, Achieva), Which include:

1. Conventional MR sequences: T1WI in axial plane, T2WI in axial, sagittal and coronal planes, and FLAIR in axial and sagittal planes. T1WI: TR 450, TE 15, matrix  $80 \times 81$ , FOV  $230 \times 177$ , slice thickness 5 mm. T2WI: TR 3612, TE 100, matrix  $208 \times 127$ , FOV  $230 \times 177$ , slice thickness 5 mm. FLAIR: TR 6000, TE 120, matrix  $240 \times 111$ , FOV  $230 \times 184$  slice thickness 5 mm.

2. Diffusion Tensor imaging sequence: The DTI data were obtained using a single-shot echoplanar imaging sequence (TR = 10.4 s/TE = 100 ms) in 25 encoding directions. Diffusion gradient: 40 mT/m, using a b value of  $800 \text{ s/mm}^2$ . A FOV =  $256 \times 256 \text{ mm}^2$  and a data matrix =  $128 \times 128$  were used. Image resolution =  $2 \times 2 \times 2 \text{ mm}^3$ , number of slices = 30, with a thickness of 2 mm, with no gap, and with the total scan time = 10–12 min.

- Post processing image analysis:-All the diffusion-weighted images were transferred to the workstation supplied by the manufacturer (Achieva R2.5 workstation, Philips). Images were post-processed using the Philips software devised for tractography. The maps obtained were: FA 2D grey maps and Directionally-encoded color FA maps and fused FLAIR/DTI maps.

The study was done after approval of ethical board of Ain Shams University.

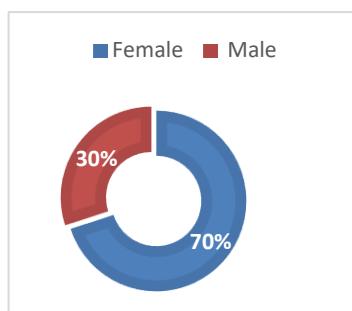
## **Statistical analysis:**

The collected data was analyzed using Microsoft Office Excel 2003 and SPSS program (Statistical Package for Social

Sciences) for Windows Version 20. Quantitative data were presented as mean ± standard deviation (SD). For quantitative data, comparison between groups was done by t test for independent samples. For qualitative data, relation between groups was done using the Pearson correlation. A P value of 0.05 was chosen as a level of significance.

**RESULTS:**

Thirty patients were included in this study. Their age ranged from 20 to 52 years with a mean of age (mean=32.8 SD = 9.5), they were 19 females and 11 males (Diagram 1).



Diagram(1): Doughnut chart reveals distribution of patients according to gender.

We placed round-shaped ROIs in FA and ADC maps, measuring the FA and ADC values from NAWM of our patient group which compared to the normal value form normal control volunteer which revealed

lower FA values in the NAWM of the patients (average FA value 0.51, SD 0,07) in comparison to the respective FA values in controls (average FA value 0.73, SD 0,06) (Diagram 2).

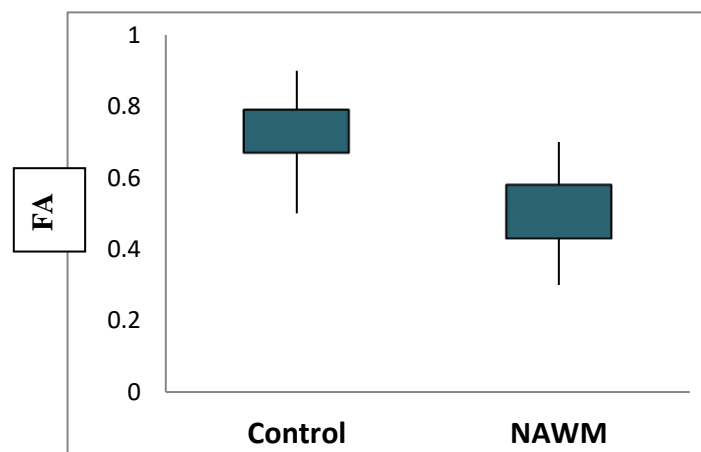
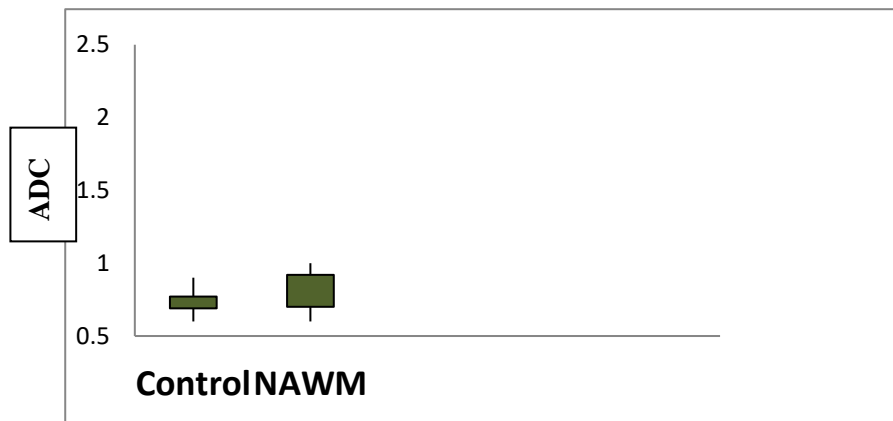


Diagram (2) :Stock chart display statistic correlation between FA measurements in NAWM of MS patients and in the respective WM of control volunteer.

**FA** fractional anisotropy, **NAWM** normal appearing white matter, **MS** multiple sclerosis.

Higher ADC value were also found in the NAWM of the patients (average ADC value  $0.81 \cdot 10^{-3} \text{ mm}^2/\text{s}$ , S 0,11) in comparison

to the respective WM ADC values in control (average ADC value  $0.73 \cdot 10^{-3} \text{ mm}^2/\text{s}$ , SD 0,04)(Diagram 3).



**Diagram. (3)** Stock chart display statistic correlation between ADC measurements in NAWM of MS patients and in the respective WM of control volunteer. The graph displays the significant differences in ADC measurements control.

**ADC** Apparent diffusion coefficient, **NAWM** normal appearing white matter, **MS** multiple sclerosis.

**Case (1):** RR-MS 21 year's old female patient with recurrent bouts of clinical symptoms as well as scattered periventricular & subcortical plaques of

altered signal intensity more evident at right fronto-parietal region on conventional MRI sequence (Fig1).

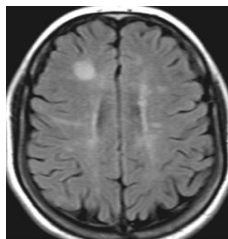


Fig 1: Axial FLAIR MRI show scattered foci of high signal intensity are seen periventricular & subcortical regions mainly of the right fronto-parietal region.

**DTI findings:** Fused FLAIR/ DTI axial images show heterogeneous color maps of the fronto-parietal white matter (Fig 5) denoting affection of normal appearing

white matter with its FA and ADC values as follows (table 1).

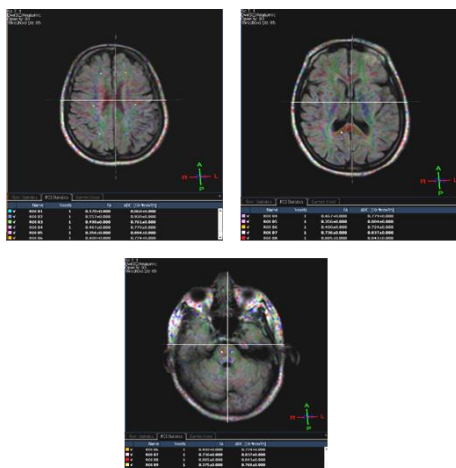


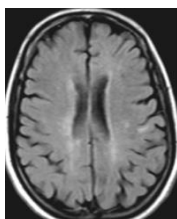
Fig 2: Fused FLAIR/ DTI axial images show ROI-based FA and ADC values .

Table 1: FA and ADC value of NAWM

White matter region	FA	ADC
Right frontal	0.3	0.7
Left frontal	0.3	0.8
Right parietal	0.6	0.9
Left parietal	0.4	0.7
Right occipital	0.6	0.8
Left occipital	0.5	0.7
Corpus callosum	0.7	0.8
Brain stem	0.7	0.9
Right corona radiata	0.6	0.8
Left corona radiata	0.5	0.7

**Case (2):** SP- MS 40 year's old male patient with deteriorated clinical symptoms as well as scattered periventricular &

subcortical plaques of altered signal intensity of the left parieto-occipital region on conventional MRI sequence (Fig 3).



**Fig 3:-**Axial FLAIR show scattered foci of abnormal white matter signal intensity mostly seen in the region.

**DTI findings:** Fused FLAIR/DTI axial images show heterogeneous color maps of the left parieto-occipital region(Fig 4)

denoting affection of normal appearing white matter with its FA and ADC values as follows (table 2).

Fig.4: Fused FLAIR/ DTI axial images show ROI-based FA and ADC values.

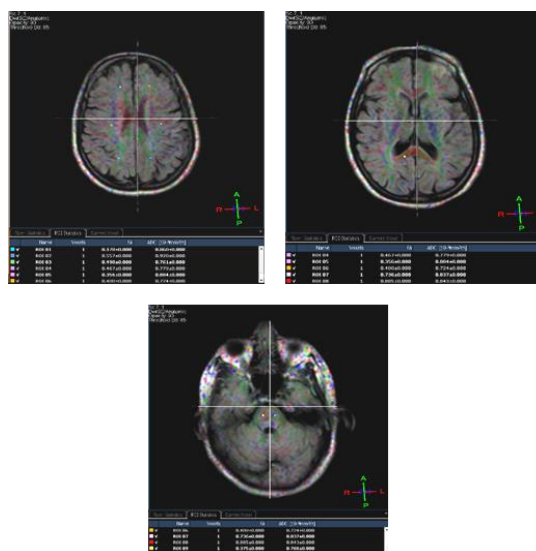


Table 2:- FA and ADC value of NAWM

White matter region	FA	ADC
Right frontal	0.4	0.9
Left frontal	0.4	0.8
Right parietal	0.5	0.8
Left parietal	0.5	0.8
Right occipital	0.2	0.9
Left occipital	0.6	0.9
Corpus callosum	0.75	0.8
Brain stem	0.4	0.8
Right corona radiata	0.6	0.8
Left corona radiata	0.7	0.7

## DISCUSSION:

Multiple sclerosis (MS) is an autoimmune, chronic disease of the central nervous system that is characterized by focal and diffuse inflammation and neurodegeneration leading to axonal loss [5].

Conventional MRI sequences (including T2-weighted, pre- and post-contrast T1-weighted scans) has had an important role on earlier diagnosis of MS, and monitoring response to current disease-modifying treatments and upcoming experimental agents. Yet is limited as regard low pathological specificity and low sensitivity to occult damage in normal-appearing white matter (NAWM). As well as limited associations with clinical status [6].

Seventy percent of the current study population were female which agree with Dahlke. F , et al<sup>[7]</sup> that MS is approximately twice as common among women as men , it has highly variable individual disease courses & different phenotypes (RRMS 85 %, PPMS 15 %, SPMS)<sup>[7]</sup>.

Pathologically the degree of axon loss in WMLs (white matter lesions) correlates with the extent of peripheral immune or resident glial inflammation, also anterograde axonal loss by Wallerian degeneration can occur in normal-appearing WM either adjacent or distal to the lesion and occurs early in MS<sup>[8]</sup>.

Altering the structural organisation of nerve bundles is responsible on the reduction of FA; even the reparative phenomena of the reactive gliosis may decrease the FA, since glial cells do not have the same organisation in space as the cells that they replace <sup>[9]</sup>.

In this study MR DTI parameters take the advantage than conventional MRI sequences in detection the early NAWM affection before its clinical or other conventional MRI parameters appearance (by giving information about diffusion of water in brain tissue within three main directions, decreased perpendicularly to the myelin sheaths and cell membranes of white-matter axons) , which agree with ElSayed et al.<sup>[10]</sup>, Fujimori, Juichi, et al.<sup>[11]</sup>, Cercignani, Mara, et al.<sup>[12]</sup>, Chen et al. <sup>[13]</sup> and Fatehi et al<sup>[14]</sup>. Studies that show significantly lower average fractional anisotropy values of NAWM as compared to normal controls indicate the presence of occult damage to the NAWM .

The current study results are in accordance with those of previous study done by Yurtsever et al. <sup>[15]</sup> which demonstrate that ADC values of NAWM in MS patients were higher than the values of normal population.

## Conclusion:

The current study concludes that MR

DTI indices (FA and ADC) are superior than conventional MR imaging with high sensitivity in MS clinical & pathological progression expectation by early detection of microstructural changes in NAWM in conventional parameters, & so greatly helpful in early management of these patients.

## REFERENCES:

1. Hassan, Amr, Nahla Merghany, Fatima Ouchkat, Wafa Rezagui, Hanaa Kedah, Sherif M. Hamdy, Maged Abdel-Naseer et al. "Impact of Ramadan fasting on disease activity in patients with multiple sclerosis: a multicenter study." *Nutritional Neuroscience* (2021): 1-10.
2. Testaverde, Lorenzo, Laura Caporali, Eugenio Venditti, Giovanni Grillea, and Claudio Colonnese. "Diffusion tensor imaging applications in multiple sclerosis patients using 3T magnetic resonance: a preliminary study." *European radiology* 22, no. 5 (2012): 990-997.
3. Razek, Ahmed Abdel Khalek Abdel, Lamiaa El-Serougy, Mohamed Abdelsalam, Gada Gaballa, and Mona Talaat. "Differentiation of residual/recurrent gliomas from postradiation necrosis with arterial spin labeling and diffusion tensor magnetic resonance imaging-derived metrics." *Neuroradiology* 60, no. 2 (2018): 169-177.
4. Sbardella, Emilia, Francesca Tona, Nikolaos Petsas, and Patrizia Pantano. "DTI measurements in multiple sclerosis: evaluation of brain damage and clinical implications." *Multiple sclerosis international* 2013 (2013).
5. Sanai, Shaik Ahmed, Vasu Saini, Ralph HB Benedict, Robert Zivadinov, Barbara E. Teter, Murali Ramanathan, and Bianca Weinstock-Guttman. "Aging and multiple sclerosis." *Multiple Sclerosis Journal* 22, no. 6 (2016): 717-725.
6. Brex, Peter A., Olga Ciccarelli, Jonathon I. O'Riordan, Michael Sailer, Alan J. Thompson, and David H. Miller. "A longitudinal study of abnormalities on MRI and disability from multiple sclerosis." *New England Journal of Medicine* 346, no. 3 (2002): 158-164.
7. Dahlke, Frank, Douglas L. Arnold, Piet Aarden, Habib Ganjgahi, Dieter A. Häring, Jelena Čuklina, Thomas E. Nichols, Stephen Gardiner, Robert Bermel, and Heinz Wiendl. "Characterisation of MS phenotypes across the age span using a novel data set integrating 34 clinical trials (NO. MS cohort): Age is a key contributor to presentation." *Multiple Sclerosis Journal* 27, no. 13 (2021): 2062-2076.
8. Dunham, Jordon, and Kedar R. Mahajan. "Pathology of Multiple Sclerosis." In *Neuroimmunology*, pp. 105-116. Springer, Cham, 2021.
9. Ceccarelli, Antonia, Maria A. Rocca, Andrea Falini, Paola Tortorella, Elisabetta Pagani, Mariemma Rodegher, Giancarlo Comi, Giuseppe Scotti, and Massimo Filippi. "Normal-appearing white and grey matter damage in MS." *Journal of neurology* 254, no. 4 (2007): 513-518.
10. ElSayed, Mohamed ElSayed Kamel Abdulaziz, Mohamed Mohamed Badawy El-Toukhy, Ramy Edward Asaad, and Omar Amin El-Serafy. "Diffusion tensor imaging for assessment of normally appearing white matter of the brain and spinal cord in cases of multiple sclerosis: a multi-parametric correlation in view of patient's clinical status." *Egyptian Journal of Radiology and Nuclear Medicine* 50, no. 1 (2019): 1-10.
11. Fujimori, Juichi, Kengo Uryu, Kazuo Fujihara, Mike P. Wattjes, Chihiro Suzuki, and Ichiro Nakashima. "Measurements of the corpus callosum index and fractional anisotropy of the corpus callosum and their cutoff values are useful to assess global brain volume loss in multiple sclerosis." *Multiple sclerosis and related disorders* 45 (2020): 102388.
12. Cercignani, Mara, Matilde Inglese, Elisabetta Pagani, Giancarlo Comi, and Massimo Filippi. "Mean diffusivity and fractional anisotropy histograms of patients with multiple sclerosis." *American Journal*

- of *Neuroradiology* 22, no. 5 (2001): 952-958.
13. Chen, Jiafeng, Chunkui Zhou, Lijun Zhu, Xiuli Yan, Yonghong Wang, Xin Chen, and Shaokuan Fang. "Magnetic resonance diffusion tensor imaging for occult lesion detection in multiple sclerosis." *Experimental and Therapeutic Medicine* 13, no. 1 (2017): 91-96.
14. Fatehi, Daryoush, Farhad Naleini, Mohammad Gharib Salehi, Alireza Gharib, Mohammad Farzizadeh, and Ayoob Rostamzadeh. "Evaluation of multiple sclerosis patients through structural biomarkers of diffusion tensor magnetic imaging and correlation with clinical features." *Journal of Chemical and Pharmaceutical Sciences* 9, no. 2 (2016): 830-837.
15. Yurtsever, Ismail, BahattinHakyemez, OzlemTaskapilioglu, Cuneyt Erdogan, Omer FarukTuran, and MufitParlak. "The contribution of diffusion-weighted MR imaging in multiple sclerosis during acute attack." *European journal of radiology* 65, no. 3 (2008): 421-426.

## دور الرنين المغناطيسي الانتشاري في تقييم مادة الدماغ البيضاء التي تبدو سليمة في حالات التصلب المتعدد

منى محمود حسن الشريف، إيمان سليمان، ريمون إيليا زاهر، منى على محمد على  
قسم الأشعة التشخيصية - كلية الطب- جامعة عين شمس

**مقدمة:** التصلب المتعدد هو أحد أمراض المناعة الذاتية المزيلة لطبقة للميالين التي تصيب الجهاز العصبي المركزي . يوفر التصوير بالرنين المغناطيسي التقليدي معلومات عن شكل اللويحات المزيلة للميالين ، ولكن لا علاقة له بإعطاء تفاصيل حول مناطق المادة البيضاء للرب الداخلي للمخ الغير مصابة ظاهريا بالتصوير التقليدي للرنين التي هي تشارك بشكل مرضي عند تأثرها في عملية مرض التصلب العصبي المتعدد. التصوير بالرنين المغناطيسي الانتشاري تقنيات غير التقليدية المستخدمة على نطاق واسع والتي توفر حلاً أفضل لدراسة المادة البيضاء الطبيعية. يعكس تصوير موتر الانتشار انتشار الماء داخل الأنسجة ، وبالتالي فإن أي تغييرات في ألياف المادة البيضاء ستكون مرئية داخلها قبل التقنيات التقليدية.

**الهدف من هذا البحث:** تقييم التأثير المبكر للمادة البيضاء في المخ والتي تبدو ظاهريا طبيعية في فحص الرنين التقليدي في مرضى التصلب المتعدد عن طريق تحليل قيم عدة أماكن فيها بعد تصوير الرنين المغناطيسي الانتشاري وعوامله المشتقة منه وبالتالي تقييم قدرته على اكتشاف التأثير المبكر للمادة البيضاء الطبيعية في مرضى التصلب المتعدد.

**النتائج:** أظهرت دراستنا التي أجريت على ثلاثون مريض يعانون من التصلب المتعدد بالتصوير الانتشاري للرنين المغناطيسي تفاصيل عن التأثير المبكر للمادة البيضاء لبعض الحالات و التي تظهر بشكل طبيعي في حالات التصلب المتعدد عندما لا يتم اكتشاف تأثيرات مرئية في التصوير بالرنين المغناطيسي التقليدي مما يساهم بدوره في إعادة تقييم المرضى من طرق علاج مبكرة تؤثر على السير المرضي بالوقاية المبكرة من بعض المضاعفات الاكلينيكية للمريض .

**الخاتمة:** هناك علاقة قوية بين الحالة السريرية للمرضى وقراءات تصوير الرنين المغناطيسي الانتشاري خاصة في حالة التدهور في مسار المرض حين لا يمكن اكتشاف تغييرات مرئية جديدة في التصوير بالرنين المغناطيسي التقليدي.