

Arthrocentesis with Hyaluronic Acid versus Platelet-rich Plasma in Case of Temporomandibular Joint Anterior Disc Displacement with Reduction

Marwa A. Maher, Basem F. Michel, Ismael A. Elmofty, Mohamed E. Hassan

Department of Otorhinology,
Benha faculty of medicine,
Benha University, Egypt

Correspondence to:
Marwa A. Maher,
Department of otorhinology,
Benha faculty of medicine,
Benha University, Egypt.

Email:

moromaher78@gmail.com

Received: 15 February 2022

Accepted: 2 August 2022

Abstract

Background: Temporomandibular joint (TMJ) anterior disc displacement (ADD) is one of the most common TMJ disorders. The current study was conducted to compare arthrocentesis with hyaluronic acid versus arthrocentesis with Platelet-rich plasma (PRP) on the outcome of patients with TMJ-ADD regarding pain and mouth opening. **Patients and Methods:** The present study is a prospective randomized comparative study that was conducted during the period of one year at Benha University Hospital. A total of 40 patients were included; they were randomly allocated into two groups: the first group included 20 patients who underwent PRP injection, and the second group included the remaining 20 patients who underwent **the hyaluronic acid (HA)** injection. **Results:** The current results demonstrated that the mean age of the studied subjects is 30.80 ± 9.512 years in the PRP group, and 33.85 ± 10.353 years in the HA group. The current findings showed higher prevalence of female gender in both groups. Both interventions were associated with a significant decrease in pain visual analog score (VAS score), and both of them were statistically comparable at baseline and through the scheduled follow-up visits. At the final follow-up, all patients showed good maximal inter-incisal opening (MIO) in both study groups. All patients showed TMJ stability at the three-month visit. Significant improvement of protrusive movement was detected in the two studied groups, with no significant difference between the two applied interventions. **Conclusion:** Both arthrocentesis with HA and that with PRP have similar outcome on TMJ-ADD, regarding joint stability and protrusive movement.

Keywords: Viscosupplementation, Platelet-rich plasma, anterior disc displacement

Introduction

Temporomandibular joint (TMJ) anterior disc displacement (ADD) is one of the most common TMJ disorders. It can occur in all age groups, with a high prevalence in adolescents [1 & 2]. The prevalence of ADD increases during childhood and reaches up to 35% in asymptomatic adults [3 & 4]. While ADD in asymptomatic young adults has been found to mostly reduce on open mouth images and is often considered an anatomic variant rather than a pathologic condition, non-reducing complete disk displacement is almost only observed in symptomatic patients with a peak incidence in puberty and female preponderance [5]. ADD often presents with clicking, joint pain, a limited range of mouth opening, and masticatory difficulty. Furthermore, ADD might lead to osteoarthritis and decrease in condylar height [6].

In patients with symptomatic ADD, associated MRI findings include flattening of the mandibular condyle, erosions and joint effusion, as well as bone productive changes in older patients, which may resemble the characteristic features of late-stage TMJ arthritis in juvenile idiopathic arthritis (JIA) patients [7 & 8].

Since ADD of the TMJ can lead to various harmful outcomes, how to manage ADD is considered a key problem for most TMJ experts. It has been difficult for most clinicians to select a suitable method for ADD patients with different grades of severities [6]. Initially, these conditions can be managed conservatively by employing techniques such as occlusal splint therapy, physiotherapy, pharmacotherapy, and occlusal treatments [9]. If conservative management fails, minimally invasive (sodium hyaluronate or corticosteroid infiltrations and arthrocentesis) and invasive treatments (arthroscopy, arthroplasty, arthrotomy, discectomy, condylotomy) are performed [10 & 11].

Sodium hyaluronate is a buffered solution of hyaluronate acid sodium salt, which is an essential component of the cartilage and the synovial fluid. It acts against the disintegration of the extracellular matrix. It activates reparation processes of the cartilage, improves the condition of chondrocytes, and the viscosity of the synovial fluid (it reduces friction), and it features an anti-inflammatory effect (through the inhibition of inflammatory cytokines). The hyaluronate has chondrotropic and lubrication effects. It is indicated for the treatment of osteoarthritic

symptoms, inflammatory degenerative joint disease, and discopathy [12]. Intra-articular hyaluronic acid injection alone or after arthrocentesis provides long-term palliative effects on subjective symptoms and clinical signs of TMJ pain [13].

Platelet-rich plasma (PRP) could be also used in the management of such condition. The principle of the treatment consists in the growth factors contained in the blood platelets that cause changes in the cell proliferation, regulate the cellular metabolism, and affect chondrogenous activities [14]. PRP has been found to have several advantages over the use of corticosteroids in the treatment of TMJ degenerative and inflammatory conditions, the most remarkable being its lack of serious and/or irreversible adverse effects. Treatment with PRP injections has reported anti-inflammatory, analgesic and antibacterial properties and, at the same time, restores intra-articular levels of hyaluronic acid, increases glycosaminoglycan chondrocyte synthesis, balances joint angiogenesis and induces stem cell migration [15]. So, the aim of this study was to compare arthrocentesis with hyaluronic acid versus arthrocentesis with PRP on the outcome of patients with TMJ-ADD regarding pain and mouth opening.

Patients and Methods

This is a prospective randomized comparative study that was conducted during the period of one year, starting from November 2020 till November 2021 at otorhinolaryngology department –Faculty of Medicine- Benha University, in Benha city in Egypt.

This study included 40 cases and they were randomly allocated using the closed envelope method into two groups, **hyaluronic acid group** that included 20 cases whom were subjected to arthrocentesis with hyaluronic acid injection and **PRP group** that include the remaining 20 cases whom had been subjected to arthrocentesis with PRP injection. We included the cases whom were more than 18 years. We included both genders. The cases were clinically (limitation of mouth opening, pre-auricular pain, headache, temporal, and occipital tenderness) or radiologically (MRI) diagnosed as ADD. The patients had symptom durations for more than 3 months. Patients had disc displacement on one side, with the other side being normal were included and the patients whom did not respond to conservative management (pain medications and gnathological treatment) were also included. But we excluded patients with uncontrolled systemic comorbidities (diabetes, hypertension, or ischemic heart

disease), with arthritis or history of condylar trauma, with previous TMJ surgery, with degenerative change of the condylar head and with facial asymmetry, retrognathism, or prognathism.

The all cases were subjected to **detailed history taking in form of age, comorbidities, special habits and presence of any symptoms (pain, noise, and/or locking).** The **clinical examination was done to them to assess tenderness, noise on joint movement, asymmetry of the mandible, decreased translation and reduction of mouth opening.** The MRI **investigation was done to the cases.** Joint status was first assessed by determining whether the disc is positioned normally, defined as the superior location (12 o'clock position) of the posterior band of the disc relative to the condyle, or whether ADD is present. Deformity was then assessed by evaluating biconcave disc morphology, enlargement of the posterior band, and thickness. Disc dynamics was categorized as mobile or immobile (fixed or “stuck” in closed and open positions) [16]. The presence of joint effusion (JE) was also evaluated. On T2-weighted images, JE was identified as an area of high signal intensity in the region of the joint space. Bone marrow oedema (BMO) was defined by the presence of a hypointense signal on T1-weighted images and a

hyperintense signal on T2-weighted images [16]. (Fig. 1)

An informed written consent was obtained from all cases before the procedure, after complete explanation of the benefits and drawbacks of each technique. Besides, the study was approved by the local ethical committee- faculty of Medicine- Benha University.

The procedure

This procedure was done under local anesthesia. The patient was seated inclined at a 45° angle with the head turned to contralateral side.

Injection site

The points of needle insertion on the skin, according to the method reported by Gurung and his associates [17], was as follows: a line is drawn from the middle of the tragus to the outer canthus of the eye. The posterior entrance point is located along the canthotragal line, 10 mm from the middle of the tragus line and 2 mm below, the anterior entrance point is placed 10 mm further forward (total 20 mm) along the line and 10 mm below it. Lidocaine 2% with adrenaline 1:100,000 was injected at the planned entrance points. An 18-gauge needle

connected to a 5 ml syringe with the Ringer's lactate solution was then inserted into the superior compartment at the articular fossa (posterior point), and solution was injected to distend the upper joint space. Another 18-gauge needle was then inserted into the distended compartment in the area of articular eminence to enable the free flow of Ringer's lactate solution through the superior compartment. Approximately 100–300 ml of Ringer's lactate solution was allowed to pass through the joint space. During the lavage, the mandible was moved through opening, excursive, and protrusive movements to facilitate lysis of adhesions.

In the hyaluronic acid group, once arthrocentesis is completed, an ampule of sodium HA (Hyalgan 1 ml) was connected to the needle in situ and 0.5 ml injected into the superior joint space. Pressure dressing was placed in site of injection.

In the PRP group, the injections were preceded by the collection of the patient's peripheral blood from the ulnar vein into a glass tube with sodium citrate as an anticoagulant. After mixing the blood with the citrate, using rotating movements, and the tubes were centrifuged at 3200 rpm for 12 min. After careful aspiration of platelet-rich plasma into a syringe, 2 ml of PRP was

injected into the joint instead of HA [18] (Fig. 2)

Follow up

Follow up visits was scheduled at 1-week, 1-month, and 6-months after injection. Pain was evaluated by the visual analogue scale (VAS). Also, patients were also invited to complete an original satisfaction form, assessing treatment effectiveness (benefit to the patient) and tolerability on scales ranging from 0 to 4 (0, poor; 1, mild; 2, moderate; 3, good; 4, very good) (Fig. 3). MRI was ordered after 6 months to detect the presence of disc interference, change in the position or conditions of the articular disc, and change in the relationship with the mandibular condyle. (Fig. 4)

Results

This study is a comparative prospective comparative study included 40 patients. The mean age of the studied subjects was 30.80 ± 9.512 years in the PRP group, and 33.85 ± 10.353 years in the HA group, with no significant difference between the two groups ($p > 0.05$). The current results showed higher prevalence of female gender in both groups, with no significant difference between them ($p > 0.05$). The majority of the studied subjects (90.0% of the PRP group,

and 70.0% of the HA group) had no history of chronic systemic diseases, with no significant difference between the two groups ($p>0.05$). The disease duration had mean value of 2.20 ± 1.218 and 2.88 ± 1.716 years in the PRP and HA groups respectively, with no significant difference between the two groups ($p>0.05$). In the PRP group, 50.0% of the studied patients showed unilateral joint affection and the other 50.0% had bilateral joint affection, while in the HA group, the percentages of unilateral and bilateral joint affection were 55.0% and 45.0%, respectively, with no significant difference between the two groups ($p>0.05$). According to the current results, joint sounds were present in 60.0% and 75.0% of cases in the PRP and HA groups, respectively, with no significant difference between the two groups ($p>0.05$). Joint locking was present in 40.0% and 70.0% of patients in the PRP and HA groups, respectively. There was no significant difference between the two groups regarding that parameter ($p>0.05$). Frequent headache was reported in 65% of patients in the two studied groups ($p>0.05$). Chronic ear pain was experienced in 60.0% and 80.0% of the studied patients in the PRP and HA groups, respectively. No significant difference was noted between the two groups regarding this perspective ($p>0.05$). Previous head injury

was reported in 35.0% and 50.0% of patients in the PRP and HA groups, respectively, with no significant difference between the two groups ($p>0.05$). The results showed that grinding or clenching was present in 25.0% and 45.0% of patients in the PRP and HA groups, respectively, with no significant difference between the two groups ($p>0.05$) (table 1).

Both interventions were associated with a significant decrease in VAS score, and both of them were statistically comparable at baseline and through the scheduled follow-up visits ($p>0.05$). In the PRP group, VAS decreased from 5.3 before injection down to 3.4, 1.8, and 0.6 at two-week, one-month, and three-month follow-up visits, respectively. In the HA group, the same parameter decreased from 5.2 before operation down to 3.85, 2.2, and 0.5 at the same scheduled visits, respectively (table 2).

Maximal inter-incisal opening (MIO) was good in 85.0% and 60.0% of patients in the PRP and HA groups, respectively at two-week follow-up. This was observed in 85.0% and 80.0% of patients in the same groups at one-month visit. At the final follow-up, all patients showed good MIO in both study groups. It was evident that both interventions

showed comparable benefit regarding that parameter ($p>0.05$) (table 3).

Joint stability was present in 30.0% and 40.0% of patients in the PRP and HA groups, respectively at two-week follow-up visit. Although the incidence of stability decreased down to 10.0% and 25.0% of patients in the same groups, respectively at one-month follow up, all patients showed TMJ stability at the three-month visit. The incidence of stability did not show any statistically significant differences between the two groups at the three follow-up visits ($p>0.05$) (table 4).

Significant improvement of protrusive movement was detected in the two studied groups, with no significant difference between the two applied interventions ($p>0.05$). However, a better improvement was observed in association with HA despite its insignificance. Good movement was observed in 85.0%, 90.0% and 100.0% of patients at two-week, one-month, and three-month visits in the PRP group, while all patients in the other group showed good movement throughout the scheduled visits (table 5).

Table (1): Demographic and clinical data.

		PRP group (n= 20)	Hyaluronic group (n= 20)	P
Age		30.80 ± 9.512	33.85 ± 10.353	0.338
Gender	Male	15.0% (3)	25.0% (5)	0.429
	Female	85.0% (17)	75.0% (15)	
	None	90.0% (18)	70.0% (14)	
Chronic systemic diseases	DM	10.0% (2)	15.0% (3)	0.184
	Hypertension	0.0% (0)	15.0% (3)	
Stressful life situations		90.0% (18)	65.0% (13)	0.058
Disease duration (years)		2.20 ± 1.218	2.88 ± 1.716	0.160
Affected side	Unilateral	50.0% (10)	55.0% (11)	0.752
	Bilateral	50.0% (10)	45.0% (9)	
Joint sounds		60.0% (12)	75.0% (15)	0.311
Locking		40.0% (8)	70.0% (14)	0.057
Frequent headache		65.0% (13)	65.0% (13)	1
Chronic ear pain		60.0% (12)	80.0% (16)	0.168
Injuries to the head		35.0% (7)	50.0% (10)	0.337
Grinding or clenching		25.0% (5)	45.0% (9)	0.185

Table (2): Visual analog score (VAS) of the studied groups

VAS	PRP group (n= 20)	Hyaluronic group (n= 20)	p
Basal	5.30 ± 0.923	5.20 ± 0.894	0.730
Two weeks	3.40 ± 0.821	3.85 ± 1.182	0.170
One month	1.80 ± 1.005	2.20 ± 0.768	0.165
Three months	0.60 ± 0.940	0.50 ± 0.513	0.679

Table (3): Maximal inter-incisal opening (MIO) assessment in the studied groups

MIO		PRP group (n= 20)	Hyaluronic group (n= 20)	p
Two weeks	Poor	15.0% (3)	40.0% (8)	0.077
	Good	85.0% (17)	60.0% (12)	
One month	Poor	15.0% (3)	20.0% (4)	0.677
	Good	85.0% (17)	80.0% (16)	
Three months	Poor	0.0% (0)	0.0% (0)	1
	Good	100.0% (20)	100.0% (20)	

Table (4): Joint stability in the studied groups.

Dislocation	PRP group (n= 20)	Hyaluronic group (n= 20)	p
Two weeks	30.0% (6)	40.0% (8)	0.507
One month	10.0% (2)	25.0% (5)	0.212
Three months	100.0% (20)	100.0% (20)	1

Table (5): Progress in protrusive movement in the studied groups.

Protrusive movement		PRP group (n= 20)	Hyaluronic group (n= 20)	p
Two weeks	Poor	15.0% (3)	0.0% (0)	0.072
	Good	85.0% (16)	100.0% (20)	
One month	Poor	10.0% (2)	0.0% (0)	0.147
	Good	90.0% (18)	100.0% (20)	
Three months	Poor	0.0% (0)	0.0% (0)	1
	Good	100.0% (20)	100.0% (20)	

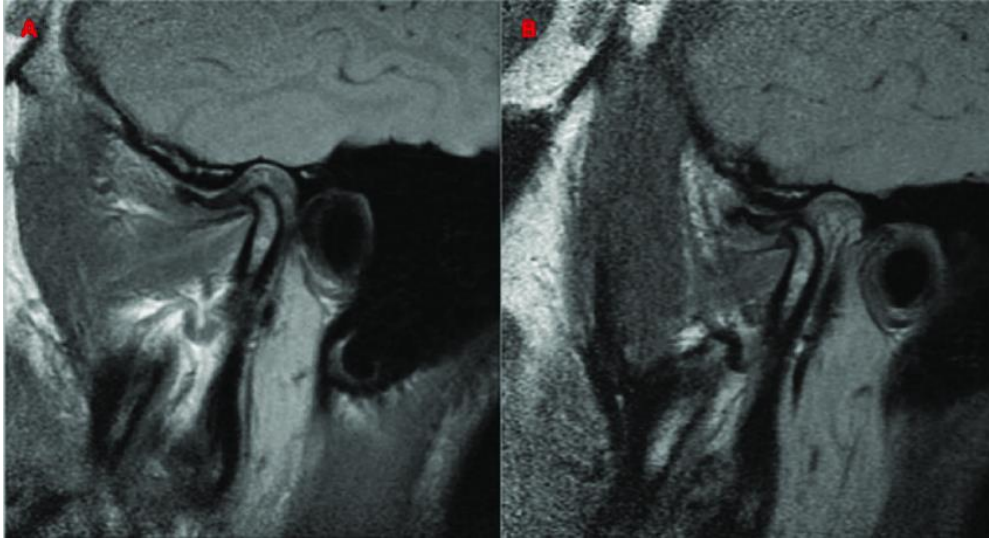


Figure 1: (A) before arthrocentesis (B) 6 months after arthrocentesis

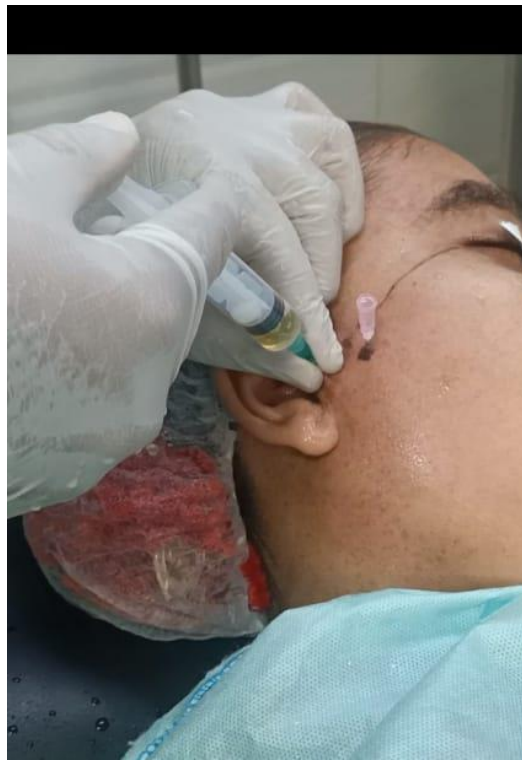

Figure (2) Injection with platelet rich plasma

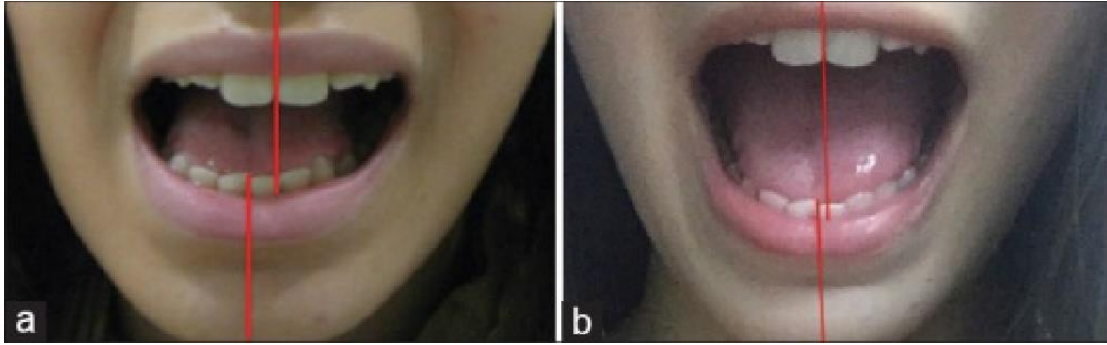


Figure (3):A: pre-procedure picture showing patient with intense right TMJ pain and mouth opening limitation to 12 mm right deviation. B: post-procedure picture showing patient after TMJ arthrocentesis with 36mm mouth opening and partial correction of mouth deviation.

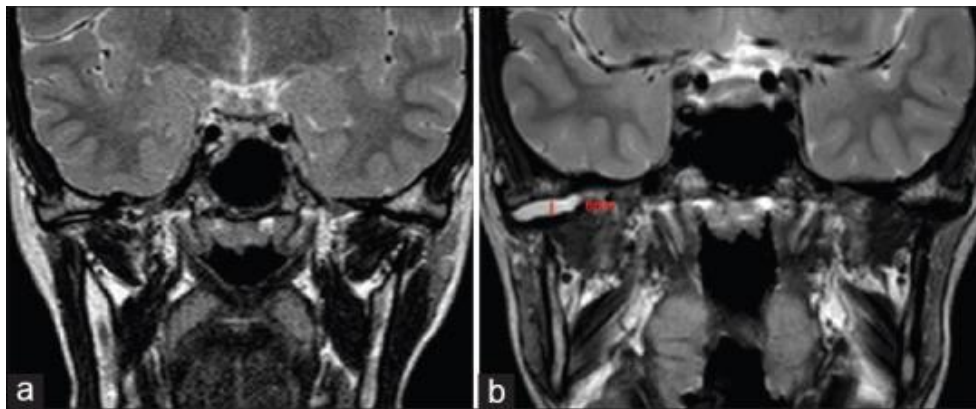


Figure (4): A:coronal T2 magnetic resonance imaging (close mouth) before temporomandibular joint arthrocentesis. B: coronal T2 (close mouth) after procedure upper joint space increased 6 mm.

Discussion

In the current study, both interventions were associated with a significant decrease in VAS score, and both of them were statistically comparable at baseline and through the scheduled follow up visits ($p > 0.05$). In the PRP group, VAS decreased from 5.3 before injection down to 3.4, 1.8, and 0.6 at two-week, one-month, and three-month follow up visits respectively. In the HA group, the same parameter decreased from 5.2 before

operation down to 3.85, 2.2, and 0.5 at the same scheduled visits respectively.

Researchers [19] confirmed the previous findings regarding pain, as VAS decreased from 5.7 down to 1.02 in the PRP group, whereas it declined from 5.71 down to 0.54 after HA injection. No significant difference was noted between the two groups neither at baseline nor at follow up ($p > 0.05$). This confirms our findings.

Furthermore, it was reported that the same parameter had mean values of 5.22 and 6.28 in the PRP and HA groups at three-month follow up, which was significantly decreased compared to baseline values (8.35 and 8.14 in the same groups respectively) [20].

In our study, joint stability was present in 30% and 40% of patients in the PRP and HA groups respectively at two-week follow up visit. Although the incidence of stability decreased down to 10% and 25% of patients in the same groups respectively at one-month follow up, all patients showed TMJ stability at the three-month visit. The incidence of stability did not show any significant differences between the two groups at the three follow up visits ($p > 0.05$).

In 2016, it was noted that there was no significant difference between HA and PRP regarding the masticatory efficiency, neither at baseline nor at follow up, with a significant improvement in the two groups compared to baseline values. This indicates the beneficial impact of both interventions on joint stability [19].

In our study, maximal interincisal opening (MIO) were good in 85% and 60% of patients in the PRP and HA groups respectively at two-week follow up. This was observed in

85% and 80% of patients in the same groups at one-month visit. At the final follow up, all patients showed good MIO in both study groups. It was evident that both interventions showed comparable benefit regarding that parameter.

This is in agreement with a previous study [19] which stated that both treatment techniques resulted in significant clinical improvements for painless MIO ($p > 0.05$). The mean change in painless MIO was 6.06 mm (SD 6.97) in the PRP group and 2.62 (SD 9) in the HA group.

Additionally, it was reported that comparable maximal mouth opening at three-month follow up visit. It had mean values of 30.52 and 29.28 mm in the PRP and HA groups at three-month follow up after having values of 27.74 and 27.92 mm in the same groups respectively at baseline [20].

In the same context, it was reported that there were significant increases in the median maximal voluntary mouth opening MVMOs through all study periods in the PRP group. In the HA group, significant improvements were observed in the median MVMO after 3 months and between 3 and 6 months. From 6 months to 12 months, a statistically significant decrease in the median MVMO

was observed (40.0 and 39.0 mm, respectively). However, at 12 months, the MVMO was significantly greater than that at 1 month. When comparing the two therapeutic interventions, the PRP group exhibited significantly lower median MVMOs than the HA group after 1, 3, and 6 months (median MVMOs: 34.0, 37.0, and 39.0 mm, respectively). After 12 months, the PRP group exhibited a significantly higher median MVMO than the HA group. Although the previous authors agreed with our findings regarding the efficacy of both methods in mouth opening, they disagreed with ours regarding the significant difference between the two modalities. One could attribute these differences to differences in the application techniques and PRP compositions which make comparisons of the efficacy results difficult [14].

Our findings showed significant improvement of protrusive movement in both study groups, with no significant difference between the two applied interventions ($p > 0.05$). However, a better improvement was observed in association with HA despite its insignificance. Good movement was observed in 85%, 90% and 100% of patients at two-week, one-month, and three-month visits in the PRP group, while all patients in the other

group showed good movement throughout the scheduled visits.

Some researchers reported that protrusive movement had mean values of 6.83 and 6.92 mm in the PRP and HA groups at baseline ($p > 0.05$), which increased up to 7.72 and 7.92 mm in the same groups respectively after intervention, without any significant differences between the two groups on statistical analysis ($p > 0.05$) [19].

Conclusion

From the findings of this work, it can be concluded that both arthrocentesis with HA and that with PRP can have similar outcome on TMJ-ADD, regarding joint stability and protrusive movement.

References

1. Ikeda K, Kawamura A, Ikeda R. Prevalence of disc displacement of various severities among young preorthodontic population: a magnetic resonance imaging study. *Journal of Prosthodontics* 2014. p. 397-401.
2. Kellenberger CJ, Bucheli J, Schroeder-Kohler S, Saurenmann RK, Colombo V, Ettlin DA, et al. Temporomandibular joint magnetic resonance imaging findings in adolescents with anterior disk displacement compared to those with juvenile idiopathic arthritis. *Journal of Oral Rehabilitation*. 2019 Jan;46(1):14-22.

3. Larheim TA, Westesson P, Sano T. Temporomandibular joint disk displacement: comparison in asymptomatic volunteers and patients. *Radiology*. 2001/02/13 ed2001. p. 428-32.
4. Haiter-Neto F, Hollender L, Barclay P, Maravilla KR. Disk position and the bilaminar zone of the temporomandibular joint in asymptomatic young individuals by magnetic resonance imaging. *Oral Surgery, Oral Medicine, Oral Pathology, Oral Radiology, and Endodontology*. 2002 Sep 1;94(3):372-8.
5. Cortés D, Exss E, Marholz C, Millas R, Moncada G. Association between disk position and degenerative bone changes of the temporomandibular joints: an imaging study in subjects with TMD. *CRANIO®*. 2011 Apr 1;29(2):117-26..
6. Shen P, Xie Q, Ma Z, Abdelrehem A, Zhang S, Yang C, et al. . Yang's classification of juvenile TMJ anterior disc displacement contributing to treatment protocols. *Scientific Reports*. 2019 Apr 4;9(1):1-8.
7. Kellenberger CJ, Junhasavasdikul T, Tolend M, Doria AS. Temporomandibular joint atlas for detection and grading of juvenile idiopathic arthritis involvement by magnetic resonance imaging. *Pediatric radiology*. 2018 Mar;48(3):411-26.
8. Arvidsson LZ, Smith HJ, Flatø B, Larheim TA. Temporomandibular joint findings in adults with long-standing juvenile idiopathic arthritis: CT and MR imaging assessment. *Radiology*. 2010 Jul;256(1):191-200.
9. Neeli AS, Umarani M, Kotrashetti SM, Baliga S. Arthrocentesis for the treatment of internal derangement of the temporomandibular joint. *Journal of maxillofacial and oral surgery*. 2010 Dec;9(4):350-4.
10. Sharma A, Rana AS, Jain G, Kalra P, Gupta D, Sharma S. Evaluation of efficacy of arthrocentesis (with normal saline) with or without sodium hyaluronate in treatment of internal derangement of TMJ—A prospective randomized study in 20 patients. *journal of oral biology and craniofacial research*. 2013 Sep 1;3(3):112-9.
11. Yilmaz O, Korkmaz YT, Tuzuner T. Comparison of treatment efficacy between hyaluronic acid and arthrocentesis plus hyaluronic acid in internal derangements of temporomandibular joint. *Journal of Cranio-Maxillofacial Surgery*2019. p. 1720-7.
12. Tatli U, Machon V. Internal Derangements of the Temporomandibular Joint: Diagnosis and Management. In: Emes Y, Dergin G, Aybar B, editors. *Temporomandibular Joint Pathology-Current Approaches and Understanding*: IntechOpen; 2017. p. 47-67.
13. Korkmaz YT, Altıntas NY, Korkmaz FM, Candırlı C, Coskun U, Durmuslar MC, et al. Is hyaluronic acid injection effective for the treatment of temporomandibular joint disc displacement with reduction?. *Journal of Oral and Maxillofacial Surgery*. 2016 Sep 1;74(9):1728-40.
14. Hegab AF, Ali HE, Elmasry M, Khallaf MG. Platelet-rich plasma injection as an effective

- treatment for temporomandibular joint osteoarthritis. *Journal of Oral and Maxillofacial Surgery*. 2015 Sep 1;73(9):1706-13.
15. Civinini R, Macera A, Nistri L, Redl B, Innocenti M. The use of autologous blood-derived growth factors in bone regeneration. *Clinical Cases in Mineral and Bone Metabolism*. 2011 Jan;8(1):25.
16. De Riu G, Stimolo M, Meloni SM, Soma D, Pisano M, Sembronio S, et al. Arthrocentesis and temporomandibular joint disorders: clinical and radiological results of a prospective study. *International journal of dentistry*. 2013 Nov 11;2013.
17. Gurung T, Singh RK, Mohammad S, Pal US, Mahdi AA, Kumar M, et al. Efficacy of arthrocentesis versus arthrocentesis with sodium hyaluronic acid in temporomandibular joint osteoarthritis: A comparison. *National Journal of Maxillofacial Surgery*. 2017 Jan;8(1):41.
18. Macedo De Sousa B, López-Valverde N, López-Valverde A, Caramelo F, Flores Fraile J, Herrero Payo J, et al. Different treatments in patients with temporomandibular joint disorders: A comparative randomized study. *Medicina*. 2020 Mar;56(3):113.
19. Kiliç SC, Güngörmüş M. Is arthrocentesis plus platelet-rich plasma superior to arthrocentesis plus hyaluronic acid for the treatment of temporomandibular joint osteoarthritis: a randomized clinical trial. *International journal of oral and maxillofacial surgery* 2016. p. 1538-44.
20. Fernández-Ferro M, Fernández-Sanromán J, Blanco-Carrión A, Costas-López A, López-Betancourt A, Arenaz-Bua J, et al. Comparison of intra-articular injection of plasma rich in growth factors versus hyaluronic acid following arthroscopy in the treatment of temporomandibular dysfunction: A randomised prospective study. *Journal of Cranio-Maxillofacial Surgery*. 2017 Apr 1;45(4):449-54.

To cite this article: Marwa A. Maher, Basem F. Michel, Ismael A. Elmofty, Mohamed E. Hassan. Arthrocentesis with Hyaluronic Acid versus Platelet-rich Plasma in Case of Temporo-mandibular Joint Anterior Disc Displacement with Reduction. *BMFJ* 2023;40 (surgical issue):68-81