

Penetrating Keratoplasty Versus Deep Anterior Lamellar Keratoplasty In Management Of Keratoconus In Zagazig University Hospitals .

Mohammed Mahmoud Abdul Kadir, Hossam El Din Mohammed Hassanin, Mohammed Ahmed Mostafa Ibrahim Hegab, Sameh Mosaad Fouda

Department of Ophthalmology Faculty of Medicine, Zagazig University

Correspondence to Mohammed
hegab MD,
Zagazig, Sharqeya
Email:
drmohammedhegab24@yahoo.com

ABSTRACT

Aim : To evaluate the visual , refractive , topographic outcomes and potential complications of penetrating keratoplasty versus deep anterior lamellar keratoplasty in treatment of keratoconus cases.

Patients and Methods : In this prospective interventional comparative clinical study, 40 eyes of patients with keratoconus needing keratoplasty either DALK or PKP were enrolled . The primary outcome measure after both groups was the BSCVA 12 months postoperatively .The secondary outcome measures included UCVA , mean spherical equivalent, mean manifest refractive cylinder ,mean keratometric readings, mean topographic astigmatism ,endothelial cell count and endothelial cell loss .

Results : 40 eyes of 35 patients with keratoconus were enrolled : 20 eyes had undergone DALK , and 20 eyes had undergone PKP . The follow up period for both groups was 12 months. Both study groups demonstrated a comparable outcome in terms of the BSCVA: 0.545 ± 0.095 and 0.55 ± 0.095 ($P = 0.868$), UCVA: 0.335 ± 0.093 and 0.306 ± 0.112 ($P = 0.379$), mean manifest refractive cylinder : -3.08 ± 0.494 and -3.35 ± 1.339 ($P = 0.394$) , mean K: $45.26 \pm 1.473D$ and $45.07 \pm 1.755D$ ($P = 0.713$) and topographic astigmatism: 3.725 ± 1.017 and 4.095 ± 1.466 ($P = 0.359$) in DALK and PKP respectively . However, the postoperative endothelial cell density in DALK (2768.6 ± 213.101) differs significantly from it in PKP (2375.65 ± 192.25) ($P < 0.001$) and the percentage of endothelial cell loss was statistically significant higher in PKP 14.206 ± 2.278 compared to DALK 1.533 ± 0.792 ($P < 0.001$). Also, there was a statistically significant difference in mean spherical equivalent between both groups with myopic shift in DALK group -4.663 ± 0.915 and -3.413 ± 2.049 $P = 0.013$. The endothelial graft rejection rate in PKP was 15 % while in DALK it was 0 %.

Conclusion: Deep anterior lamellar keratoplasty is an effective and safe alternative surgical technique to the standard penetrating keratoplasty in treatment of keratoconus.

Keywords:

Penetrating keratoplasty , Deep anterior lamellar keratoplasty , big bubble and Keratoconus .

INTRODUCTION

Keratoconus is an ectatic corneal disorder characterized by corneal thinning and weakness due to structural and biomechanical abnormalities⁽¹⁾. There are different methods of classifications of keratoconus depending on morphology, disease evolution, ocular signs and index- based system ⁽²⁾ Penetrating keratoplasty was considered the gold standard method for treatment of severe stages of keratoconus⁽³⁾. Complications of penetrating keratoplasty (PKP) include graft rejection and graft failure ⁽⁴⁾. The concept of Deep Anterior Lamellar Keratoplasty (DALK) is targeted to

deep lamellar replacement of corneal stroma down to the Descemet's membrane (DM) leaving the host endothelial cell layer intact thus reducing the risks of graft rejection and intraocular complications⁽⁵⁾ . However, the disadvantages of deep lamellar keratoplasty are long learning curve , DM perforation and interface haze ⁽⁶⁾ . Anwar and Teichmann proposed the big-bubble technique, which allows the surgeon to gain safe access, reducing risk of perforation, and exposing a smooth, even surface of excellent optical quality⁽⁶⁾. In the literature the two techniques have been compared several times. Most of

the studies have reported comparable outcomes in terms of vision, refractive error and graft survival⁽⁷⁻¹⁰⁾. In this study we wanted to compare the visual acuity, refraction, keratometry, endothelial cell density and complications of PKP and DALK in keratoconus patients.

PATIENTS AND METHODS

This prospective clinical study was conducted in Zagazig university hospitals. Forty eyes of thirty five patients with keratoconus that underwent either PKP or DALK between 2014 and 2016 were enrolled in this study. The patients were divided randomly into two groups; the first group included patients who had undergone deep anterior lamellar keratoplasty (20 eyes) the second group included patients who had undergone penetrating keratoplasty (20 eyes). The corneo-scleral donor buttons were obtained from the eye bank (New Orleans, LA, USA).The storage media is Optisol-GS preservative media (Bausch & Lomb, Rochester, NY) at 31°C. Patients with moderate to severe keratoconus with the following criteria were included: clear cornea or with faint apical superficial corneal opacity, intolerance to rigid gas permeable contact lenses, failed previous ICRs implantation and unsuitable to collagen cross linking and or ICRs due to either the thinnest corneal thickness < 400 µm or the mean topographic K > 58 D. Exclusion criteria were corneal hydrops and any other eye diseases that may affect the visual outcome of the surgery such as retinal pathology, glaucoma or cataract. A preoperative full ophthalmologic examination was done including measurement of best spectacle corrected visual acuity (BSCVA), uncorrected visual acuity (UCVA) ,manifest refraction, slit lamp biomicroscopy, tonometry and dilated funduscopy. Preoperative corneal topography was done using Pentacam (OCULUS Optikgeräte GmbH, Germany), reporting the mean K reading and topographic astigmatism. Preoperative Specular microscopy was done using specular microscope model SP-3000P (TOPCON) for recording endothelial cell count. The primary outcome measure in both groups was the BSCVA measured at 12 months

postoperatively .The secondary outcome measures included UCVA , mean spherical equivalent, mean manifest refractive cylinder ,mean keratometric readings, mean topographic astigmatism ,endothelial cell count and endothelial cell loss . The study, the informed consent form and any other written information to be given to patients was reviewed and approved by the Ethics Committee of the Zagazig University Hospital.

Preoperative preparation for both groups:

Topical antibiotics (moxifloxacin) (0.3%) eye drops were given to patients 48 hours prior to operation 4 times daily. All operations were performed under general anesthesia .A 7.50 - 7.75 mm Hessburg-Barron Vacuum trephine (Katena, Denville, USA) for the patient was chosen according to the cone size , and 7.75 - 8.00 mm Barron Donor Cornea Punches (Katena, Denville, USA) were used.

Surgical technique:

First group: Deep Anterior Lamellar Keratoplasty Using the modified Big Bubble Technique:

Proper centration of the corneal trephine over the recipient cornea was done. After trephination to about 80% of corneal thickness , a paracentesis was done with injection of air . A 27 gauge needle, attached to a 5-cc syringe, bent at 100 degrees (bevel facing downward) was inserted into the stroma up to the center of the cornea. Air was injected gently into the midstroma until a big-bubble formed extending to the border of trephination. If the big bubble is not formed after the first attempt, the injection was repeated until the big-bubble is formed. Removal of the anterior two-thirds of the corneal stroma with a crescent blade was done. The bubble was punctured with a 15° slit-knife to allow escape of the air and collapse of the bubble. A viscoelastic material was injected into the potential space to protect the DM . The residual stromal layers were incised with a sharp blade over the spatula into four quadrants and each quadrant was completely excised. The endothelium of donor buttons was peeled after staining with trypan blue dye. The button was secured in place using 16 interrupted 10/0 nylon sutures.

Second Group (Penetrating Keratoplasty)

Marking the geometric center of the cornea and the cornea itself with 16 radial colored marks as done. An anterior chamber (AC) paracentesis was done using MVR blade, a viscoelastic substance was injected into the AC. A Hessburg- Barron suction trephine (Katena Products, Denville, NJ, USA) was used and complete rotation of the white spokes was performed followed by re-injection of methylcellulose into the AC. Using a fine toothed forceps, the cut part of the recipient cornea was elevated and complete excision was done using the right and the left vertical cutting scissors. Preparation of the graft was performed before cutting the recipient cornea. The donor corneo-scleral button was punched out from the endothelial side with the Barron donor punch (Katena Products, Denville, NJ, USA). After that the cutting blade was centralized on the button. Firm steady pressure was done over the head of the cutting blade to produce even uniform central cutting of the corneo-scleral graft.

The donor graft in both groups was cut 0.25 mm larger than the recipient site to ensure better wound coaptation. The graft was sutured to the recipient bed using 16 interrupted sutures of 10/0 monofilament nylon. At the end of surgery in both groups, contact lens was used and topical antibiotic (moxifloxacin 0.3%) plus topical steroid (prednisolone 0.5%) were instilled then the eye was covered with a sterile eye patch.

Regimen for postoperative medications for both groups:

Absolute bed rest was recommended, all eye patches were removed and replaced with a new one in the 1st day. The contact lens was removed 4 days postoperative. All eyes were treated with topical antibiotic moxifloxacin(0.3%) every 2 hours in the first 2 days, 5 times a day for 3 weeks, then 3 drops per day for another month. In both groups, topical steroid in the form of prednisolone acetate eye drops 1% was applied every 2 hours in the first 3 days. and 5 to 6 times a day for the next month then 4 times for the subsequent two months and the patient was maintained on 3 times daily for another 3 months. In the second group (PKP) topical steroid was continued in the form of

Fluoromethelone eye drops one to two drops daily for another 3 months then once daily for the last 3 months of the one year postoperative of follow up. Systemic steroids and systemic antibiotics were given also to all patients for two weeks. A cycloplegic eye drop was also given in the form of one drop daily for one week postoperative. An artificial tear preparation was given 4 times daily for 3 months. Topical IOP lowering drugs (Dorzolamide 2% / Timolol 0.5%) twice daily were also given.

Follow up and postoperative evaluation:

We examined all cases of both groups by slit-lamp examination at the 1st day postoperative, at the third post-operative day, every week for the first 2 months, every month for the next 3 months and every 2 months for one year postoperative to check the graft, wound healing, corneal sutures, corneal vascularization, signs of infection or rejection (epithelial, stromal or endothelial) especially in the second group and IOP by applanation tonometer. Also the following was done for all patients in both groups in the 1st week, 1st month, 3 months, 6 months and one year postoperative which was the follow up period: test for unaided visual acuity, refraction to detect manifest spherical equivalent and manifest refractive cylinder and best spectacle corrected visual acuity which is the primary outcome measure of this study. Pentacam was also done 3 months, 6 months and one year postoperatively to evaluate the corneal surface irregularities, mean keratometric readings, topographic astigmatism and selective sutures removal was performed by detecting the steepest K value and its axis. We did not remove any suture for all cases in both groups before one postoperative year except if there were complications like loose or tight suture, vascularization or infiltration around suture. Specular microscopy was done at the 3rd, 6th month and one year postoperatively to assess endothelial cell count and endothelial cell loss in both groups.

RESULTS

Results of 40 eyes of 35 patients with keratoconus needing corneal transplantation who came to the outpatient clinic in the department of ophthalmology of Zagazig

University, were included in our study. They were divided randomly and equally into two groups . The first group was treated with DALK and the second one was treated with PKP .We followed up these patients for one year after performing the operation.

As regards the demographic data (gender and age), there was no statistically significant difference between both groups as demonstrated in table (1)

Table (1): Age and sex distribution of both study groups:

	DALK	PKP	P
Age			
mean±SD	27.5±4.9	28.5±5.33	0.54*
Range	18-36	18-37	
Sex			
Male n(%)	8(40)	9(45)	0.749^
Female n(%)	12(60)	11(55)	

* independent sample t test is used.

^ Chi square test is used.

Regarding the mean preoperative data including the UCVA, BSCVA , spherical equivalent , manifest cylinder , K ,topographic astigmatism and endothelial cell count, there were no statistically significant differences between both groups as demonstrated in table (2)

Table (2): Preoperative clinical data of both study groups:

Variables	Study groups		
	DALK	PKP	P
	X±SD	X±SD	
UCVA	0.061±0.022	0.062±0.022	0.941 [#]
BSCVA	0.076±0.023	0.07±0.025	0.499 [#]
SE	-15.71±3.89	-16.06±3.503	0.751 ⁺
MRC	-8.66±1.03	-8.74±1.12	0.83 [#]
K	64.06±3.167	64.53±3.249	0.646 [#]
TA	6.05±2.33	6.43±2.63	0.627 [#]
ECC	2817.68±208.13	2767.55±188.829	0.435 [#]

[#] Independent sample t test is used

⁺ Mann Whitney test is used

*P is significant at <0.05

In the first group (DALK), we obtained a successful big bubble in 20 eyes (90.9%) of a total 22 eyes .Two cases (9.09 %) were converted to PKP: One case (4.45%) was converted to PKP due to development of macro-perforation (air did not maintained in the AC). The other case (4.45%) was converted due to failure to get a successful big bubble and we did not perform the manual method for dissection to obtain a bare DM to avoid interface haze. The two cases were included in the second group . Two cases (10%) developed an accidental

microperforation during removal of the residual stroma .The air was injected into the AC at the end of operation to push the DM up against the graft to avoid the double AC. In the second group (PKP) there was no intraoperative complications. At 12 months postoperatively , there was statistically significant improvement in the mean (BSCVA and UCVA) in both groups as compared to the preoperative value demonstrated in figure (1). There was also statistically significant reduction in the mean (spherical equivalent, manifest refractive

cylinder, K, and topographic astigmatism) in both groups in comparison to the preoperative

data.

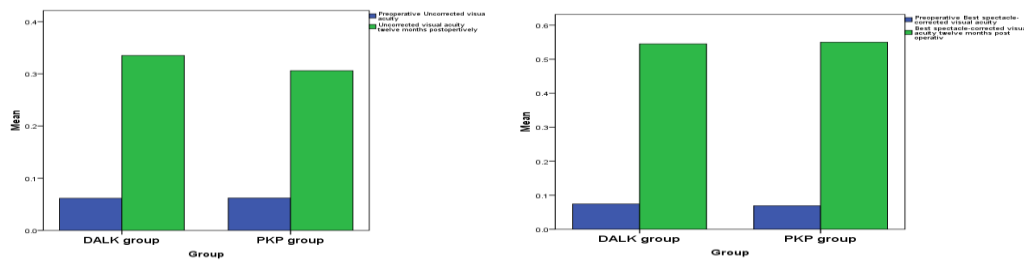


Figure 1 : 2 bar graph showing the change in the UCVA (the first one) and BSCVA (the second one) in both groups preoperative and 12 month postoperative denoting highly significant improvement in both groups

On the other hand, there was statistically significant difference between both study groups regarding mean spherical equivalent and endothelial cell count. Meanwhile, no statistically significant difference was present

between both groups regarding UCVA, BSCVA, MRC, K values or topographic astigmatism at 12 months postoperatively as presented in table (3).

Table (3): 12 months postoperative clinical data of both study groups:

Variables	Study groups		
	DALK X±SD	PKP X±SD	p
UCVA	0.335±0.093	0.306±0.112	0.379 [#]
BSCVA	0.545±0.095	0.55±0.095	0.868 [#]
SE	-4.663±0.915	-3.413±2.049	0.013 ^{*+}
MRC	-3.08±0.494	-3.35±1.339	0.394 [#]
K	45.26±1.473	45.07±1.755	0.713 ^{#*}
TA	3.725±1.017	4.095±1.466	0.359 [#]
ECC	2768.6±213.101	2375.65±192.25	<0.001 ^{#*}

[#] Independent sample t test is used, ⁺ Mann Whitney test is used,

*P is significant at <0.05

There was a statistically significant difference between both groups as regard to the mean percentage of endothelial cell loss 3, 6 and 12 months postoperatively. As illustrated in table (4) and figure (2).

Table (4): Percentage of endothelial cell loss at 3, 6 and 12 months postoperatively in both study groups:

Variables	Study groups		P [#]
	DALK X ± SD	PKP X ± SD	
Percentage Endothelial cell loss 3 months postop	0.825±0.525	6.796±1.385	<0.001 [*]
Percentage Endothelial cell loss 6 months postop	1.076±0.682	10.68±2.415	<0.001 [*]
Percentage Endothelial cell loss 12 months postop	1.533±0.792	14.206±2.278	<0.001 [*]

[#] Mann Whitney test is used, *P is significant at <0.05.

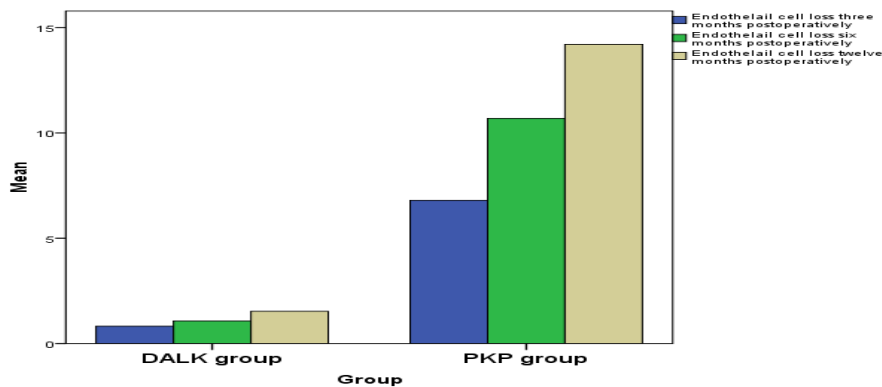


Figure (2) : Combined bar chart showing mean percentages of endothelial cell loss 3 months, 6 months and 12 months postoperatively

Postoperative complications in both groups:

In the first group (DALK), three cases (15%) developed folds in the DM. These folds started early in the first postoperative day then disappeared gradually over the next months. It was found that these folds did not affect the visual acuity. So, just follow up of these cases was done. One case was complicated with double AC formation (5%) in the first postoperative day. This case was treated immediately by reinjection of air into the AC through the limbal paracentesis in the operating room. The DM re-attached to the graft, the double AC disappeared and the final visual acuity did not differ from those cases that did not develop double AC. Loose stitch occurred in two (10%) cases. The first case developed two loose sutures one month postoperatively and managed by removal of these sutures and replacing the with two new ones with adequate tension. The other case developed loose stitch at the 7th month, so the suture was removed only. Stitch infiltration developed in one case (5%) at the 4th postoperative month ;this case was treated with removal of the suture in the operating room and intensive topical antibiotic(moxifloxacin 0.3% drops every two hours and fucidic acid ointment twice per day for 1 week). Suture vascularization developed in one case (5%) and treated with topical steroids eye drops and subconjunctival injection of antiVEGF therapy (Bevacisumab, Avastin in dose of 2.5 mg/0.1cc) near the site of vascularization twice with one week apart . No cases developed an episode of graft rejection

during the follow up period (one year). The graft rejection in the DALK group was (0%).

In the second group (PKP), three cases (15%) developed endothelial graft rejection, the first case occurred after 4 months, the second case occurred after 8 months and the last case occurred after 12 months. All cases were treated with aggressive topical and systemic steroids. Two cases improved and the rejection attack was overcome but only one case did not improve and complicated with a graft failure (5%). Loose suture occurred in two (10%) cases. One eye developed one loose sutures 5 months postoperatively and managed by removal of the suture. The other case developed loose stitch 10 months postoperative and the suture was also removed. Stitch infiltration and abscess formation developed in one case (5%) at the 5th postoperative month; the patient was treated with removal of the suture in the operating room followed by topical antibiotic(moxifloxacin 0.3% drops every two hours , fucidic acid ointment twice per day and systemic antibiotic for 1 week). Suture and graft vascularization developed in two cases (10%) and treated with the same treatment as in the first group (DALK) (i.e. topical steroids eye drops and subconjunctival injection of antiVEGF therapy (Bevacisumab, Avastin in dose of 2.5 mg/0.1cc) beside the site of vascularization twice one week apart) . Steroid induced glaucoma developed in one patient (5%) at the third month postoperatively; the case was treated with topical anti-glaucoma (combined Timolol 0.5% + Dorzolamide 0.1%) twice daily .Prednisolone acetate was also replaced

with a soft steroid like Fluoromethelone three time daily.

DISCUSSION

DALK became an alternative surgical procedure to PKP in the treatment of different corneal diseases that did not involve the endothelium and DM. This is because DALK avoids the open sky complications, reduces the rate of graft rejection, allows early tapering of steroid and thus reducing the incidence of steroid induced glaucoma that may occur with PKP⁽¹¹⁾. DALK using the big bubble technique seems to be safe and effective technique in treating patients with moderate to advanced KC. It allows achievement of a bare DM with a smooth regular interface⁽¹²⁾. In our study, we compared the visual, refractive outcomes and potential complications of PKP and DALK (using modified big bubble technique) operations performed for keratoconus patients. At the end of follow up, 17 out of 20 cases who had undergone DALK (85%), and 17 out of 20 cases who had undergone PKP (85%) achieved a final BSCVA ≥ 0.5 . These results matched with those that were reported by *Kim et al., 2011*⁽¹³⁾ in which, percentages of keratoconus patients having a BSCVA of ≥ 0.5 ranged between 73% and 91% after PKP. Also, these results were consistent with those reported by *Feizi et al., 2010*⁽¹⁴⁾, in which the percentages of keratoconus patients having a BSCVA of ≥ 0.5 ranging between 75% and 94% using the same technique (big bubble technique) after DALK. There were no statistically significant differences in the mean BSCVA at different time points between both groups but the DALK group was associated with early visual recovery compared to the PKP group due to better and early wound healing. This is consistent with a number of studies e.g *Silva CA et al., 2007*¹⁵, *Han DC et al., 2009*¹⁶ and *Krumeich JH et al., 2008*¹⁷ that did not find any significant differences between both groups at different time periods of follow up. On the other hand, our results in mean BSCVA were not consistent with *Watson SL, et al., 2006*¹⁸, *Ardjomand N, et al., 2007*¹⁹ and *Bahar, et al., 2008*²⁰. They reported that DALK was inferior to PKP in term of BSCVA. However, they used the manual

method of dissection after failure in obtaining a big bubble leading to irregularity at recipient-graft interface (interface haze and scarring) which reduced the BSCVA after DALK. It was found that the mean preoperative BSCVA in the DALK group was 0.076 while it was 0.07 in the PKP group. One year postoperatively, the mean BSCVA increased to 0.54 in the DALK group and to 0.55 in the PKP group; this indicates a marked improvement in BSCVA after both DALK and PKP for keratoconus. This is consistent with *Watson et al., 2006*¹⁸ who found that the final mean spherical equivalent in the DALK group was $-4.663D \pm 0.915$ while in the PKP group it was $-3.413D \pm 2.049$. There was statistically significant difference between both groups regarding mean spherical equivalent (P value = 0.013). This denotes a postoperative myopic shift in the DALK group. Our results in postoperative myopic shift in DALK more than PKP group were consistent with *Watson et al., 2006*¹⁸, *Oh et al., 2013*²¹ and *Huang et al., 2015*²². They noted a final mean spherical equivalent of ($-4.13 D$) in the DALK group, compared with ($-1.63 D$) in the PKP group. *Oh et al., 2013*²¹ explained the postoperative myopia in DALK to three factors including axial length, preoperative corneal steepening, and residual bed thickness in comparison to PKP in which the whole cornea was replaced with another graft with a new curvature. But, our results in myopic shift after DALK were inconsistent with *Krumeich et al., 2008*¹⁷ and *Han et al., 2009*¹⁶ who did not find any significant refractive error difference between both groups at each time point interval. In our study, there was no statistically significant difference between both groups as regard the change in the mean manifest refractive cylinder values in preoperative and 12 months postoperative (P value was 0.394). The final results after one year showed that the mean cylinder was $-3.08 \pm 0.494 DC$ and $-3.35 \pm 1.339 DC$ in DALK and PKP groups respectively. On comparing this postoperative result to the preoperative value in both groups, there was a reduction in the mean manifest refractive cylinder. Our results were consistent with *Esin Sogultu Sari et al.,*

2012²³ who reported no statistically significant difference between both groups as regard the mean manifest refractive cylinder (-3.25 D and -3.00 D in DALK and PKP groups respectively). There was no statistically significant difference noticed between both groups as regard the mean postoperative keratometric power at different periods of follow up. At 12 months postoperatively, the mean keratometric power in the first group was 45.26 ± 1.47 D and in the second group was 45.07 ± 1.75 D. ($P = 0.713$). Moreover, there was no statistically significant difference between both groups in the mean postoperative topographic astigmatism; at 12 months postoperatively, the mean topographic astigmatism in the first group was 3.72 ± 1.01 and in the second group was 4.09 ± 1.46 at one year ($P = 0.359$).

The main issue of a successful keratoplasty surgery is to get a clear corneal graft and maintain its survival. Many studies reported the importance of endothelial cell density (ECD) in maintaining the clarity of a corneal graft and its survival after keratoplasty (*Patel SV., 2005*)²⁴. The loss of endothelial cells after DALK appears to be similar to the physiological loss (*Torun et al., 2011*)²⁵. In our study, although there was no statistically significant difference between both groups as regard ECD preoperatively; it was found that ECD at 3, 6, and 12 months in PKP group was significantly lower than that in DALK group ($P < 0.001$). The estimated cell loss (as a percentage) from the original endothelial cell count at 3, 6 and 12 months was 0.82%, 1.07%, and 1.53% in DALK group respectively. On the other hand, it was 6.79%, 10.68%, 14.20% in PKP group. There was a statistically significant difference between the percentage of cell loss between both groups ($p < 0.001$) at 3, 6, and 12 months postoperative respectively. This result is consistent with *Torun et al., 2011*²⁵ who found that the reduction in corneal ECD in the PKP group was 7.4%, 15.2% and 23.5% but after DALK it was 3.0%, 6.7%, and 7.2% at 3, 6, and 12 months respectively.

As regard to the first group (DALK) in our study, we obtained a successful big bubble in 20 eyes (90.9%) of a total 22 eyes whether

from the first injection or injection twice or three times. This is consistent with *Feizi S et al., 2010*¹⁴ and *Kubaloglu A et al., 2011*¹¹ in which the rate of successful big bubble formation was 82%. Intraoperative DM microperforation occurred in 2 cases (10%) and conversion to PKP due to DM macroperforation occurred in one case (4.54%). This is consistent with results of *Yüksel B et al., 2017*²⁶ in which the intraoperative DM microperforation occurred in 15.8% and conversion to PKP due to DM macroperforation occurred in 7.9%. One of the two cases that developed intra operative microperforation and continued DALK, was complicated with double AC formation (5%) in the first postoperative day. This is consistent with the rate of double AC in other studies for example: *Fontana et al., 2007*²⁷ (4%) and *Han et al., 2009*¹⁶ (4%).

After one year of PKP, clear grafts were obtained in 17 of 20 cases (85%), three cases (15%) in PKP group developed endothelial graft rejection. All cases were treated with aggressive topical and systemic steroids. Two cases showed improvement and the rejection attack was aborted but the remaining case did not improve and complicated with a graft failure (5%). On the other hand, after one year of DALK surgery, clear grafts were obtained in 20 of 20 cases (100%), No cases (0%) developed a graft rejection. Our results are consistent with *Rahman I et al., 2009*²⁸ who reported that the incidence of graft rejection reaction after PKP was 23.0% in which 6.3% of patients showed graft failure. Endothelial rejection episodes were detected in 10.5% of the PKP cases performed by *Yüksel B et al., 2017*²⁶ while *Cohen et al., 2010*²⁹ found that the rate of rejection was 13.3% and *Donoso et al., 2015*³⁰ reported this rate as 8%. Many studies reported that the incidence of rejection episodes in DALK for keratoconus cases ranged between 0% and 14.3%; being reversible in most cases with appropriate therapy e.g., (*Sarnicola et al., 2010*)³¹ and (*Kubaloglu et al., 2011*)¹¹.

In conclusion, deep anterior lamellar keratoplasty is an effective and safe alternative technique to the standard penetrating keratoplasty in treatment of keratoconus.

REFERENCES

- 1- **Ambekar R, Toussaint Jr KC, and Wagoner Johnson A, 2011.** The effect of keratoconus on the structural, mechanical, and optical properties of the cornea. *Journal of the Mechanical Behavior of Biomedical Materials* 4(3):223-236.
- 2- **Romero-Jiménez M., Santodomingo-Rubido J, and Wolffsohn JS, 2010.** Keratoconus: A review. *Contact Lens and Anterior Eye* 33(4):157-166.
- 3- **Cassidy D, Beltz J, Jhanji V, and Loughnan MS, 2013.** Recent advances in corneal transplantation for keratoconus. *Clin Exp Optom* 96(2):165-172.
- 4- **Feder SR, and Gan TJ, 2011.** Non-inflammatory ectatic disorders cornea. *In Cornea and external disease: clinical diagnosis and management.* Third Edition edition. M.J.M. Jay H Krachmer, Edward J Holland, ed. Pp. 1091-1106: MOSBY 978 0 323 06387 6.
- 5- **Aylin K U and Orkun M .**Advances in Keratoconus Treatment. *Expert Rev Ophthalmol.* (2011);6(1):95-103
- 6- **Anwar M, and Teichmann K D, 2002.** Big-bubble technique to bare Descemet's membrane in anterior lamellar keratoplasty. *J Cataract Refract Surg* 28(3):398-403.
- 7- **Han DC, Mehta JS, Por YM, Htoon HM, Tan DT (2009)**Comparison of outcomes of lamellar keratoplasty and penetrating keratoplasty in keratoconus. *Am J Ophthalmol*148(5):744–751
- 8- **Kim MH, Chung TY, Chung ES (2013)** A retrospective contralateral study comparing deep anterior lamellar keratoplasty with penetrating keratoplasty. *Cornea* 32(4):385–389
- 9- **Zhang YM, Wu SQ, Yao YF** Long-term comparison of full-bed deep anterior lamellar keratoplasty and penetrating keratoplasty in treating keratoconus. *J Zhejiang Univ Sci B* 2013 14(5):438–450
- 10 - **Tan DT, Anshu A, Parthasarathy A, Htoon HM**
Visual acuity outcomes after deep anterior lamellar keratoplasty: a case-control study. *Br J Ophthalmol* 2010 94(10):1295–1299.
- 11- **Kubaloglu A, Sari ES, Unal M, Koytak A, Kurnaz E, Cinar Y, Ozertürk Y.** Long-term results of deep anterior lamellar keratoplasty for the treatment of keratoconus. *Am J Ophthalmol*2011;151(5):760-767
- 12- **Fogla R, Padmanabham P.** Results of deep lamellar keratoplasty using the big bubble technique in patients with keratoconus. *Am J Ophthalmol.* 2006;141(2):254 –259.
- 13- **Kim KH, Choi SH, Chung ES, Chung TY.** Comparison of refractive changes after deep anterior lamellar keratoplasty and penetrating keratoplasty for keratoconus. *JPN J Ophthalm.* 2011;55(2):93-97.
- 14 - **Feizi S, Javadi MA, Jamali H, Mirbabaee F.** Deep anterior lamellar keratoplasty in patients with keratoconus: big bubble technique. *Cornea.* 2010;29(2):177–182.
- 15- **Silva CA, Schweitzer de Oliveira E, Souza de Sena Junior MP, Barbosa de Sousa L.** Contrast sensitivity in deep anterior lamellar keratoplasty versus penetrating keratoplasty. *Clinics (Sao Paulo).* 2007;62:705-8.
- 16- **Han DC, Mehta JS, Por YM, Htoon HM, Tan DT.** Comparison of outcomes of lamellar keratoplasty and penetrating keratoplasty in keratoconus. *Am J Ophthalmol.* 2009;148(5):744–751.
- 17- **Krumeich JH, Knülle A, Krumeich BM.** Deep anterior lamellar (DALK) vs. penetrating keratoplasty (PKP): a clinical and statistical analysis [in German]. *Klin Monbl Augenheilkd.* 2008;225:637-48.
- 18- **Watson SL, Tuft SJ, Dart JK.** Patterns of rejection after deep lamellar keratoplasty. *Ophthalmology.* 2006;113:556-60.
- 19 - **Ardjomand N, Hau S, Mc Alister JC.** Quality of vision and graft thickness in deep anterior lamellar and penetrating corneal allografts. *Am J Ophthalmol.* 2007;143:228-35.
- 20- **Bahar I, Kaiserman I, Srinivasan S, Ya-Ping J, Slomovic AR, Rootman DS.** Comparison of three different techniques of corneal transplantation for keratoconus. *Am J Ophthalmol.* 2008;146(6):905–912.
- 21- **Baek Lok Oh, MeeKum Kim, Won Ryang Wee.** Comparison of Clinical Outcomes of Same-size Grafting between Deep Anterior Lamellar Keratoplasty and Penetrating Keratoplasty for Keratoconus. *Korean J Ophth.* 2013;27(5):322-30
- 22 - **Huang T, Hu Y, Gui M, Hou C, Zhang H.** Comparison of refractive outcomes in three corneal transplantation techniques for keratoconus *Graefes Arch Clin Exp Ophthalmol*2015;253(11):1947-1953.
- 23- **Esin Sogultu Sari, Anil Kubaloglu, Mustafa unal, David Pinero Lorens, Arif Koytak, Ali Nihat Ofluoglu, Yusuf ozerturk.** Penetrating Keratoplasty versus Deep Anterior Lamellar

- Keratoplasty. Br J Ophthalmol. 2012;96(8):1063-1067.
- 24- Patel SV, Hodge DO, Bourne WM.** Corneal endothelium and postoperative outcomes 15 years after penetrating keratoplasty. Am J Ophthalmol. 2005;139(2):311-319.
- 25 - Banu Torun, Acar, Ece Turan Vural, Suphi Acar. Changes in endothelial cell density following penetrating keratoplasty and deep anterior lamellar keratoplasty. Int J Ophthalmol. 2011; 4(6): 644-647.
- 26 - Bora Yüksel, Baran Kandemir, Umut Duygu Uzunel, Ozan Çelik, Sezgin Ceylan, Tuncay Küsbeci :** Comparison of visual and topographic outcomes of deep-anterior lamellar keratoplasty and penetrating keratoplasty in keratoconus Int J Ophthalmol, Vol. 10, No. 3, Mar.18, 2017
- 27- Fontana L, Parente G, Tassinari G.** Clinical outcomes after deep anterior lamellar keratoplasty using the big bubble technique in patients with keratoconus. Am J Ophthalmol. 2007;143(1):117-124.
- 28 - Rahman I, Carley F, Hillarby C.** Penetrating keratoplasty: indications, outcomes, and complications. Eye (Lond). 2009;23:1288-94.
- Cohen AW, Goins KM, Sutphin JE, Wandling GR, Wagoner MD** 29- Penetrating keratoplasty versus deep anterior lamellar keratoplasty for the treatment of keratoconus. Int Ophthalmol 2010;30(6):675-681.
- 30 - Donoso R, Díaz C, Villavicencio P.** Comparative study of keratoconus between Anwar's deep anterior lamellar keratoplasty versus converted penetrating keratoplasty. Arch Soc Esp Oftalmol 2015;90(6):257-263.
- 31 -Sarnicola V, Toro P, Gentile D, Hannush SB.** Descemet DALK and predescemet DALK: outcomes in 236 cases of keratoconus. Cornea. 2010;29(1):53-59.