

## Management of wide facial pores by topical microbotox with microneedling

S.A.Salah, R.M.Salem and S.E.Ibrahim

Dermatology and Andrology, Dept., Faculty of Medicine, Benha Univ., Benha, Egypt

E-mail: drsarah871@yahoo.com

### Abstract

**Introduction:** We provide a case on care of large facial pores and seborrhea in 20-years old female with history of acne vulgaris and sun exposure (outdoor employment), non- smoker, no pregnancy or breastfeeding. **presentation of case:** Our patient appeared with broad facial pores and seborrhea, with history of acne vulgaris. **Discussion:** Calvani et al. reported correcting, in a session, laxity of the chinrest region and skin folds of the neck. However, in our selective case we used mesobotox topically with dermapen in treatment of wide facial pores based on the fact that calvani et al. mentioned in their study that the microtrauma induces the production of growth factors by multiplication of fibroblasts and the synthesis of collagen and elastin. Therefore, the approach given has this dual action and this technique was not employed previously in any research. **Conclusion:** Topical microbotox with microneedling demonstrated to have a reduction in facial pores and seborrhea after 1 month of treatment although this effect was transient and gone entirely at the 4 month follow up appointment.

**Key words:** facial pores, microbotox, microneedling.

### 1.Introduction

Microneedling was used in a research by Calvani and colleagues.

Enhancing the skin texture, reducing horizontal wrinkles and reducing vertical banding were all achieved with the application of Botulinum toxin, which was also employed to enhance cervicomenal angle contouring.

Reductions in skin laxity in the chin rest region and neck skin folds were seen in every patient who had the treatment, as well as a reduction in skin imperfections(2) (1).

In our case, a single session of topical microbotox and microneedling was used to treat wide facial pores and seborrhea in a patient with pore scores of 2 and sebum scores of 2, and the pore and sebum scores were significantly reduced after one month of treatment, but returned to baseline levels after four months (p0.001).

### 2.Statement of the facts

As a result of pore and sebum scores, a 20-year-old female patient, a non-smoker who spends most of her time outside, was categorised as a score 2.

A dermatologist was consulted by her for three years because of her large pores and oily skin.

A thorough medical history was taken to determine the patient's age, disease duration, occupation, smoking, sun exposure, allergy to any medical treatment, especially botox, marital status and subsequently pregnancy or lactation, history of previous procedures for wide facial pores in the last six months.

Any possible skin condition, systemic illness or autoimmune disorder was checked out throughout the general and local evaluations.

A 13MP mobile phone camera (Huawei Y7 Prime) was used to take photographs for the study (Huawei Y7 Prime).

The patient was assessed at the beginning of the study and again at the end of the study, which lasted four months.

The patient had dermoscopic examination utilising (Dermalite 4 Gen Pro II) before to therapy, one month after treatment ended, and then four months afterwards.

a fixed point was shot on both sides of one's face at the place where two lines, one from the lateral canthus to one from the angle of one's mouth, intersected.

There were two scores used to measure changes in sebum and pore size over time: a baseline score and a score after one month, then a score after four months.

Patients were given a sebum score ranging from 0 to 3, with 0 representing dry skin, 1 representing mild oiliness, 2 representing moderate oiliness, and 3 representing severe oiliness.

Patient's pores were graded from 0 to 3, with 0 representing no visible pores, 1 representing visible pores, 2 indicating bigger pores, and 3 representing black heads buried in the pore openings on the face.

Assessment of face pores and sebum production by two blinded examiners was carried out (2).

One mL of mesobotox solution, which was resuspended, was dropped onto the skin, and the dermapen was held firmly above it for three seconds before being removed.

Using the gadget, a little pressure was delivered to the skin.

Until the therapy was complete, this technique was repeated all over the designated treatment area.

The DermaPen A6 was utilised for the procedure.

A dermapen with a 24-needle head and a depth of 0.5 mm was utilised for the procedure.

Repeated use of the roller ensured the greatest results.

As each fine needle punctures the skin, it creates a channel or micro-wound stimulating skin cell regeneration. After this, microbotox was applied to the skin.

Remaining upright for at least four hours after a procedure, avoiding strenuous physical activity for at least 24 hours, and not taking ibuprofen, aspirin, fish oil, or vitamin E supplement were all recommended post-procedure instructions for the patient. She was also advised not to use noncomedogenic skin products and make-up for at least 24 hours after treatment, apply ice

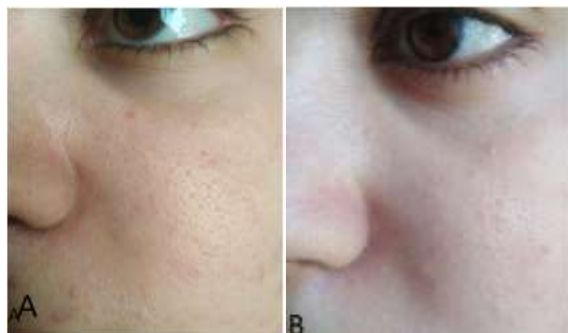packs to reduce swelling and discomfort, and wear SPF for several weeks.

We assessed the patient's pore and sebum scores at one-month intervals using a dermoscope, and found that they had dramatically decreased to a score of 1.

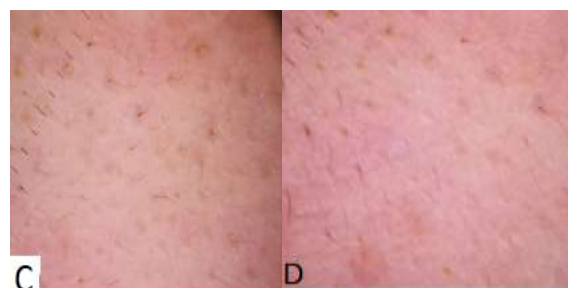
The Likert scale (1-5 scale) (3) was used to gauge patient satisfaction: 1 = Very unhappy, 2 = Unsatisfied, 3 = Neither satisfied nor dissatisfied, 4 = Pleased, and 5 = Very satisfied(3).

Our patient score was score 4 at 1 month evaluation that unfortunately became score 2 at 4 months duration as the effect was lost completely. In order to address large facial pores, the patient did not advocate topical microbotox with microneedling.

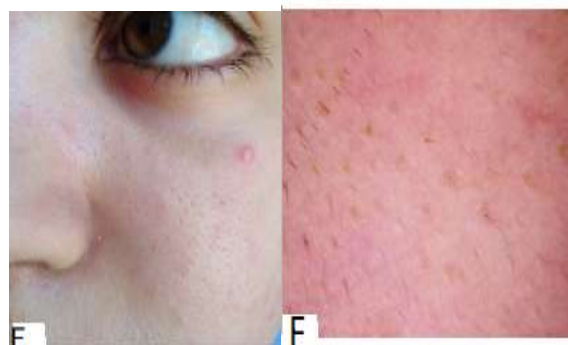
End-of-treatment evaluations included immediate and long-term side effects such as discomfort, erythema, and edoema.



**Fig. (1)** (A) Before topical microbotox with microneedling (B) improvement after 1 month



**Fig. (2)** (C)dermoscopic image at baseline with enlarged pores most of which are imbeded with sebum (D) dermoscopic image one month after treatment with less reduction in visibility of pores.



**Fig. (3)** (E) A photo after 4 months showing how the effect of treatment was lost (F) Dermoscopic image after 4 months of treatment

### 3. Discussion

It has been established by Aust et al. that mechanical skin insults induce the formation of collagen fibres, which might have an impact on tissue flexibility (4).

For large facial pores and seborrhea, topical microbotox plus microneedling has never been utilised in a clinical research.

One month following treatment, pore and sebum scores were significantly reduced in this research (p0.001).

The findings of Aust et al. show that mechanical puncturing of the skin with small needles fractures the skin's continuity, allowing greater penetration of BoNT/A into the skin.

There is evidence that fine needles may separate cells without harming them, according to histopathological examinations.

Calvani et al. demonstrated that percutaneous needle pricks themselves have been reported to create several microbruises in the dermis, and they really initiate a complex cascade of growth factors that eventually result in collagen production (1).

The patient had edoema and erythema that persisted for 48 hours as an initial adverse effect.

There have been no reports of late adverse effects (scarring or dyspigmentation).

According to Calvani and colleagues, there were no major issues.

There was a reddening of the treated regions, with mild swelling lasting from one to four hours, depending on the kind of skin that was being treated.

During the 48-hour period, the skin developed a reddish hue.

After treatment, patients returned to work without experiencing any difficulty (1).

In our situation, the therapy's impact on pore and sebum scores was totally gone by the fourth month of treatment.

When Calvani et al. employed BONT/A in the treatment of neck skin folds and reported that all patients were followed up every month for six months, this explains why

All patients had to start again from the beginning after the follow-up period since the benefits had faded entirely (1).

These findings are in line with those of Amer et al., who looked into dermapen's effectiveness and safety in treating facial creases caused by ageing skin and cigarette smoking.

All patients in the ageing group(6) showed statistically significant improvements in skin texture and tightness.

#### 4. Conclusion

This case has demonstrated that topical microbotox with microneedling has a temporary effect on management of wide facial pores and seborrhea. This effect showed great improvement 1 month after treatment however, it was lost completely at the 4 months follow up visit.

#### Conflicts of interest

The authors have no financial and personal relationships with other people or organisations that could inappropriately influence this submission.

Funding \sThe authors have no extra or intra-institutional funding to declare.

#### Ethical approval

The study was approved by the local ethics committee on research involving human subjects of Benha Faculty of Medicine.

#### Consent

Informed consent was obtained from the patient before enrolment in the study.

#### References

- [1] F.Calvani, S.Santini, E. Bartoletti, A A.lhadeff. Personal Technique of Microinfiltration With Botulin Toxin: The SINB Technique (Superficial Injection Needling Botulinum).Plast Surg (Oakv).VOL. 27(2),pp.156-161,2019.
- [2] KS.Sayed, R.Hegazy, HI.Gawdat, RM. Abdel Hay, Ahmed MM, Mohammed FN, R.Allam, A.Fahim. The efficacy of intradermal injections of botulinum toxin in the management of enlarged facial pores and seborrhea: a split face-controlled study. J Dermatolog Treat.vol. 32(7),pp.771-777,2021.
- [3] N.Saedi, K.Petrell, K.Arndt, J. Dover. Evaluating facial pores and skin texture after low-energy non-ablative fractional 1440-nm laser treatments.J Am Acad Dermatol.vol. 68,pp.113-118,2013.
- [4] MC.Aust, D.Fernandes, P.Kolokythas, HM.Kaplan, PM.Vogt. Percu-taneous collagen induction therapy: an alternative treatment for scars, wrinkles, and skin laxity.Plast Reconstr Surg.vol. 121,pp.1421-1429,2008.
- [5] K.Zduńska, A.Kołodziejczak, H. Rotsztein. Is skin microneedling a good alternative method of various skin defects removal? Dermatol Ther.vol. 31(6),pp.e12714,2018.
- [6] M.Amer, F.Farag, A.Amer, R. ElKot, R. Mahmoud. Dermapen in the treatment of wrinkles in cigarette smokers and skin aging effectively. J Cosmet Dermatol.vol.17(6),pp.1200-1204,2018.