



## Histopathological and Scores Assessment of Using Omega-3 for Improvement Gingival Wound Healing Process in Rabbit Model

Omar Kh. Mahmoud\*<sup>1</sup>, Jawnaa K. Mammdoh<sup>1</sup> and Mohammed G. Saeed<sup>2</sup>

<sup>1</sup>Department of Dental Basic Sciences, College of Dentistry, University of Mosul, Mosul, Iraq.

<sup>2</sup>Department of Pathology and Poultry Diseases, College of Veterinary Medicine, University of Mosul, Mosul, Iraq.



CrossMark

**T**HE aim of this trail is to using omega-3 as a prophylactic or curative, or both on gingival injury healing in rabbits. To attain this objective has been employed 36 rabbits, were divided into 3 groups, each with 12 animals. The first group were considered as a control group, receiving normal saline for 10 days, while the second group received omega-3 for 10 days before gingival incision. The third group received omega-3 for 10 days before and continuous treatment for 10 days after the gingival incision. An incision was done in the gingival (0.5 cm) in all groups. The group given Omega-3 for 10 days before and after the woundperforming had the superior results of the preceding therapies. It enhanced re-epithelization score and substantial increase in granulation tissue formation and angiogenesis, and decreaseinflammation scores. The histopathological section (3 days post-surgery) showed the site of the wound with re-epithelialization (score 4), granulation tissue (score 2), angiogenesis (score 3), and without inflammation (score 0), as well as 7 days post-surgery were the same scores except the score of granulation tissue was 3. Using omega-3 has a superior effect, especially when used for both prophylactic and treatment, and it helped to reduce inflammatory markers while improving healing indications such as re-epithelialization, granulation tissue, and angiogenesis. As a result, omega-3 can be considered a beneficial value as antimicrobial agent in the treatment of wounds and gingivitis.

**Keywords:** Omega-3, Gingival wound, Inflammation, Histopathological changes.

### Introduction

Wound healing is a three-stage biological process that is both intricate and sequential [1]. Inflammation and molecular and cellular processes occurrence wound healing begins during the inflammatory phase and is aided by a class of protein mediators known as proinflammatory cytokines [2-4].

In reaction to stimuli such as a cut or bruise, arachidonic acid is released from the phospholipid bilayer of cell membranes [5]. Interleukin-1b (IL-1b), IL-6, and tumor necrosis factor-a are the main proinflammatory cytokines (TNF-a) (6). Neutrophils, macrophages, mast

cells, fibroblasts, and endothelial cells release these hormones, which have autocrine, paracrine, and endocrine functions [7].

This network of proinflammatory cytokines helps control infection and prepare tissues for further repair by enhancing phagocytic activity [8]. Stimulating migration of keratinocytes at wound edges, fibroblast chemotaxis and proliferation [9], and the breakdown of extracellular matrix proteins, and they can be a pathway for the regulation and formation of collagen by binding to receptors on the combined target cells [10].

Gingivitis is a common periodontal disease caused by a combination of host immune

Corresponding author: omar.20dep54@student.uomosul.edu.iq, <https://orcid.org/0000-0001-9486-6144>

2 jawnaakhalid@uomosul.edu.iq, <https://orcid.org/0000-0002-3849-2501>

3 mgsaeed@uomosul.edu.iq, <https://orcid.org/0000-0002-9433-8293>

(Received 27/06/2022; accepted 22/07/2022)

DOI.10.21608/EJVS.2022.147321.1358

©2022 National Information and Documentation Centre (NIDOC)

responses and biofilm lipopolysaccharide (LPS) is an endotoxin produced by Gram-negative bacteria that increases arachidonic acid metabolism [11]. The inflammatory pathways are then activated. TNF- and IL-1 are two pro-inflammatory cytokines that can be affected by LPS [12]. These are some of the most common pro-inflammatory cytokines, and they play a key role in the degradation of periodontal tissue, alveolar bone, and tooth loss. IL-1 and TNF- can also cause connective tissue damage [13,14].

Omega-3 fatty acids are found in the highest concentration in fish oil. Eicosapentaenoic acid (EPA) and docosahexaenoic acid (DHA) are the most common polyunsaturated fatty acids (DHA) [15,16]. Cold-water fish, such as salmon and mackerel, are the main sources of PUFAs [17].

The number of carbon double bonds in the chain of fatty acids is categorized as follows: polyunsaturated fatty acids (PUFAs) with more than one unsaturated bond; saturated fatty acids with only one unsaturated bond. The metabolites of omega-3 play an important role in the synthesis of different inflammatory mediators such as prostaglandins (PG), leukotrienes (LT), thromboxanes (TX), protectins, and resolvins. Omega-3 FA (fatty acid) plays a role in the host cellular membrane which regulates membrane fluidity and intricate lipid raft assembling in the cell membrane [18-20].

The aim of this study was to examine the role of omega-3 as a prophylactic agent to overcome the gingival wound affections in rabbit.

## **Material and Methods**

### *Drugs used*

Omega-3 was capsulated pure oil obtained from Beauty and Health Co., Ukraine.

### *The animals*

This experiment included thirty six adult local rabbits their weighting and aging were (0.5 and 1 kg), (4 months), respectively. They were raised in dedicated cages with enough food and water for the duration of the experiment, as well as appropriate environmental parameters like temperature, lighting, and cleanliness. When working with animals, the known humane rules were observed.

### *Ethical approval*

The Laboratory Animal Handling Ethics Committee of the University of Mosul provided

ethical and humane authorization for handling animals, and the form number is UOM.Dent\AEN\A.L.9\22.

### *Experiment Design*

The rabbits were divided into three equal groups, each with 12 animals. The first group considered as a control group, receiving normal saline for 10 days, while the second group received omega-3 300mg/rabbit for 10 days before gingival incision. The third group received omega-3 300mg/rabbit for 10 days before and continuous treatment for 10 days after the gingival incision. The incision was made in the gums (0.5 cm) with a sterile scalp in all groups, and the animals were sacrificed after 3 and 7 days for sample collections.

The rabbits were anesthetized with anesthetic ether before being euthanased by it and tissue samples were obtained from the site of the gum wound in the rabbit euthanasia periods (3 and 7 days). The gum wound site tissues were fixed in a neutral 10% formalin solution.

### *Statically analysis*

Using one-way ANOVA, Duncan test to analyze the data at a level of significance less than 0.05,  $p < 0.05$ .

## **Results**

In consideration of re-epithelization scores, the treatment with Omega-3 before and after the wounding operation showed a significant difference as a compare with control group and the other groups. A substantial difference was observed in the Omega-3 group before the surgery for 3 and 7 days when compared to the control group (Table 1).

We found a substantial increase in granulation tissue formation at the wound site in the omega-3 group before and after including the wound as compare to the control group and the other groups (Table 2).

When it came to angiogenesis, the two groups that were given Omega-3 before or before and after the wound surgery had a substantial difference from the other groups (Table 3).

As for the levels of inflammation scores in the groups treated with Omega-3 before and after the wounding procedure, there was a significant difference represented by a decrease in the number of levels of inflammation compared with therest of the groups (Table 4).

**TABLE 1. The scores of re-epithelialization of rabbit gingival surgical wound healing process of all groups.**

	Groups/ Periods	Control group(N.S pre-surgical wound)	Control group(N.S pre & post- surgical wound)	Omega-3 (pre-surgical wound treat) group	Omega-3 (pre & post- surgical wound treat) group	P- Value
<b>Scores of re- epithelialization</b>	After 3 days	1.3 ± 0.28 <sup>Aa</sup>	1.3 ± 0.25 <sup>Aa</sup>	2.6 ± 0.25 <sup>Ba</sup>	3.3 ± 0.28 <sup>Ba</sup>	0.006
	After 7 days	2.3 ± 0.57 <sup>Ab</sup>	2.3 ± 0.33 <sup>Ab</sup>	3.6 ± 0.33 <sup>Bb</sup>	3.6 ± 0.33 <sup>Ba</sup>	0.026

N. Total specimens (rabbits) = 3

Data expressed as Mean ± Stander error

The Capital letters mean there are significant differences between groups at  $p \leq 0.05$

The Small letters mean there are significant differences between periods at  $p \leq 0.05$

**TABLE 2. The scores of granulation tissue of rabbit gingival surgical wound healing process of all groups.**

	Groups/ Periods	Control group(N.S pre-surgical wound)	Control group(N.S pre & post-surgical wound)	Omega-3 (pre-surgical wound treat) group	Omega-3 (pre & post- surgical wound treat) group	P- Value
<b>Scores of granulation tissue</b>	After 3 days	1.33 ± 0.33 <sup>Aa</sup>	1.6 ± 0.33 <sup>Aa</sup>	2 ± 0.0 <sup>ABa</sup>	2.6 ± 0.33 <sup>Ba</sup>	0.055
	After 7 days	1.3 ± 0.40 <sup>Aa</sup>	1.6 ± 0.25 <sup>Aa</sup>	2 ± 0.0 <sup>Aa</sup>	3 ± 0.0 <sup>Ba</sup>	0.05

N. Total specimens (rabbits) = 3

Data expressed as Mean ± Stander error

The Capital letters mean there are significant differences between groups at  $p \leq 0.05$

The Small letters mean there are significant differences between periods at  $p \leq 0.05$

**TABLE 3. The scores of angiogenesis of rabbit gingival surgical wound healing process of all groups.**

	Groups/ Periods	Control group(N.S pre-surgical wound)	Control group(N.S pre & post- surgical wound)	Omega-3 (pre-surgical wound treat) group	Omega-3 (pre & post- surgical wound treat) group	P- Value
<b>Scores of angiogenesis</b>	After 3 days	1.3 ± 0.33 <sup>Aa</sup>	1.6 ± 0.33 <sup>Aa</sup>	2 ± 0.57 <sup>Aa</sup>	2.6 ± 0.33 <sup>Aa</sup>	0.201
	After 7 days	1.6 ± 0.33 <sup>Aa</sup>	1.6 ± 0.33 <sup>Aa</sup>	2.3 ± 0.28 <sup>Ba</sup>	2.6 ± 0.25 <sup>Ba</sup>	0.160

N. Total specimens (rabbits) = 3

Data expressed as Mean ± Stander error

The Capital letters mean there are significant differences between groups at  $p \leq 0.05$

The Small letters mean there are significant differences between periods at  $p \leq 0.05$

**TABLE 4. The scores of inflammation of rabbit gingival surgical wound healing process of all groups.**

	Groups/ Periods	Control group(N.S pre-surgical wound)	Control group(N.S pre & post- surgical wound)	Omega-3 (pre-surgical wound treat) group	Omega-3 (pre & post- surgical wound treat) group	P- Value
<b>Scores of inflammation</b>	After 3 days	2 ± 0.57 <sup>Aa</sup>	2 ± 0.57 <sup>Aa</sup>	1.3 ± 0.66 <sup>Aa</sup>	0.3 ± 0.33 <sup>Ba</sup>	0.188
	After 7 days	1.6 ± 0.47 <sup>Aa</sup>	1.3 ± 0.4 <sup>Aa</sup>	1.3 ± 0.4 <sup>Aa</sup>	0.6 ± 0.28 <sup>Ba</sup>	0.268

N. Total specimens (rabbits) = 3

Data expressed as Mean ± Stander error

The Capital letters mean there are significant differences between groups at  $p \leq 0.05$

The Small letters mean there are significant differences between periods at  $p \leq 0.05$

The result of the histopathological sections of the rabbit gingiva of the negative control group (without wound) revealed the normal architecture of gingival tissue represented by epithelial cells of mucosa, submucosa and muscular layer (Fig. 1). The positive control group administrated normal saline pre-surgical wound after 3 days showed the site of wound with re-epithelialization (score 2), granulation tissue (Score 1), angiogenesis (Score 1) and inflammation with infiltration of inflammatory cells (score 3) (Fig. 2-A & B), whereas in the same group but after 7 days revealed the site of wound with re-epithelialization (Score 3), granulation tissue (Score 2), angiogenesis (Score 2) and inflammation with infiltration of inflammatory cells (Score 2) (Fig. 2-C & D).

The sections of the administrated normal saline (pre and post- surgical wound after 3 days revealed the site of wound with re-epithelialization (Score 2), granulation tissue (Score 1), angiogenesis (Score 2), and inflammation with infiltration of inflammatory cells (Score 2) (Fig. 3-A & B), while after 7 days revealed re-epithelialization (Score 3), granulation tissue (Score 2), angiogenesis (Score 1), and inflammation with infiltration of inflammatory cells (Fig. 3-C & D)

The rabbit gingiva of the administration Omega-3 pre-surgical wound group after 3 days revealed the site of the wound, with re-epithelialization (Score 3), granulation tissue (Score 2), angiogenesis (score 1), and inflammation with infiltration of inflammatory cells (Score 2) (Fig. 4-A & b), whereas after 7 days showed the site of wound with re-epithelialization (Score 4), granulation tissue (Score 1), angiogenesis

(Score 2), and inflammation with infiltration of inflammatory cells (Score 1) (Fig. 4-C & D).

The group of rabbit gingiva of administration Omega-3 pre and post-surgical wound group after 3 days recorded the site of wound with re-epithelialization (score 4), granulation tissue (Score 2), angiogenesis (Score 3), and without inflammation (Score 0) ( Fig. 5-A & B), whereas after 7 days revealed the site of the wound with re-epithelialization (Score 4), granulation tissue (Score 3), angiogenesis (Score 3), and without inflammation (Score 0). (Fig. 5-C & D).

### Discussion

Wound healing is a complicated process in which several structured and chain reactions overlap to restore what has been damaged by a wound. Hemostasis, inflammation, proliferation, reorganization, and arrangement are the mechanisms involved [21- 23].

Wound healing refers to a living organism's replacement of destroyed or damaged tissue by newly produced tissue wound healing [24,25].

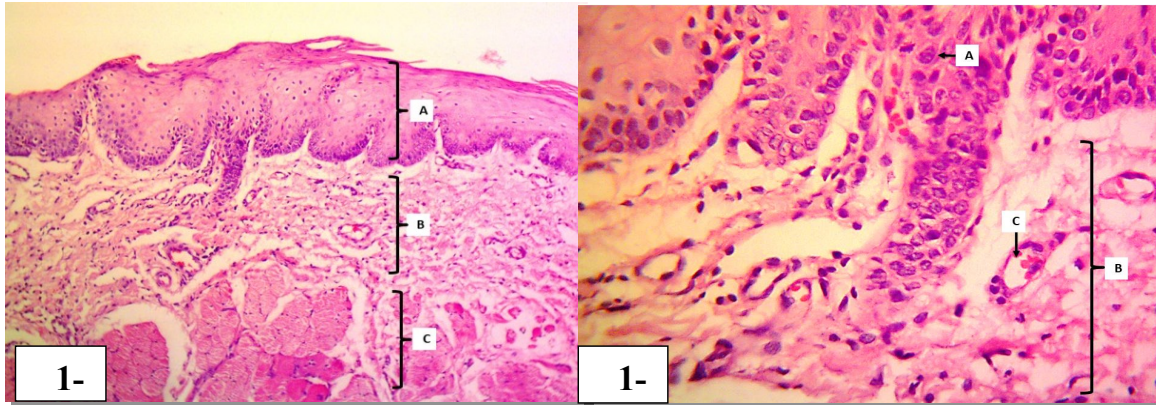
Omega-3 acids, which are made up of two types of unsaturated fatty acids called EPA and DHA [26], were employed in this study, and they were given to one group prophylactically before causing the wound, and to another group before and after executing the wound. The researchers compared the treated groups and the treatment periods of 3 and 7 days after incision done.

Our findings revealed that Omega-3 treatment before and after the wound procedure had a definite favorable effect on wound healing, as

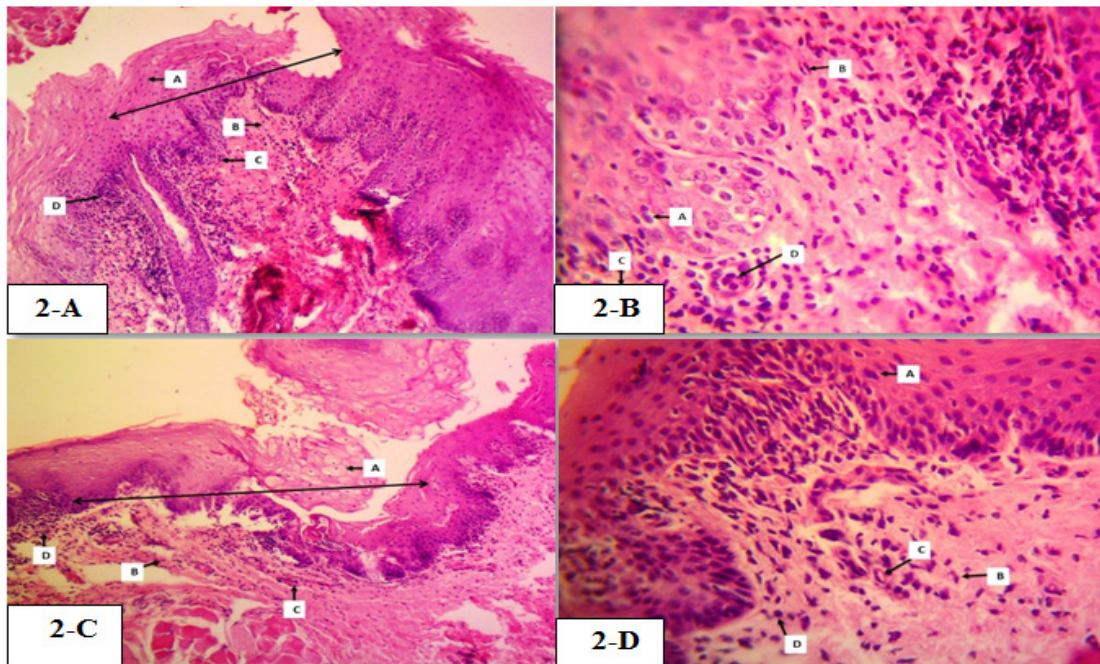


seen by tissue samples collected from the wound site, particularly after 7 days of treatment, which shows re-epithelialization (score 4), granulation tissue (score 3), angiogenesis (scoring 3) and no inflammation at the wound site (score 0). And among the results of various tissue slices, this was the best. Our findings are in line with those of comparative studies in which omega-3

was used as an anti-inflammatory drug, with one study reporting that omega-3 supplementation is a simple strategy to improve the long-term treatment of periodontitis[27]. Another literature review reporting that using omega-3 as a treatment can significantly increase gum tissue regeneration while decreasing bleeding on examination[28-30].

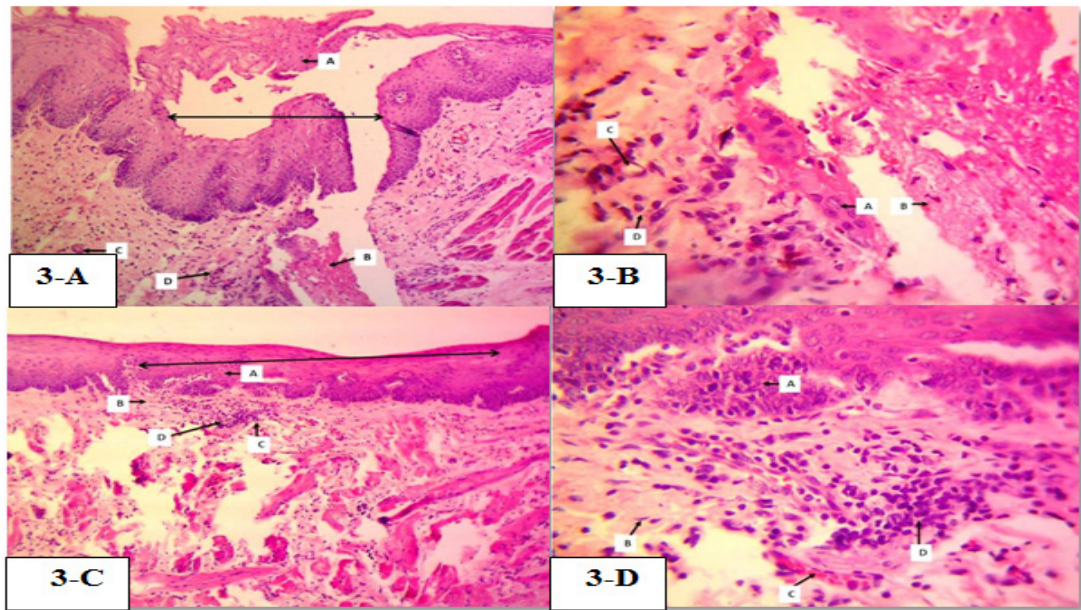


**Fig. 1.** Photomicrograph of rabbit gingiva of negative control group (without wound) shows the normal architecture of gingival tissue representing by epithelial cells of mucosa (A), submucosa (B) and muscular layer (C). H & E stain, (1-A 100X, 1-B 400X).

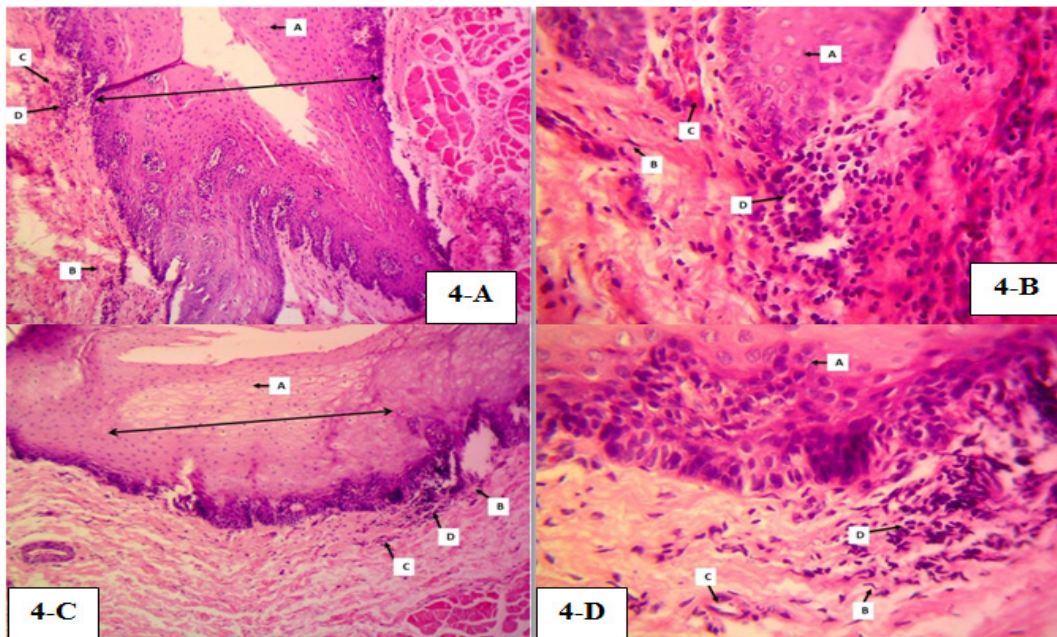


**Fig. 2.** Photomicrograph of rabbit gingiva of positive control (pre-surgical wound normal saline administration) group, (2-A & B): (after 3 days) shows the site of wound with ( $\leftrightarrow$ ), with re-epithelialization (score 2) (A), granulation tissue (score 1) (B), angiogenesis (score 1) (C) and inflammation with infiltration of inflammatory cells (score 3) (D). (2-C & D): (after 7 days) shows the site of wound with ( $\leftrightarrow$ ), with re-epithelialization (score 3) (A), granulation tissue (score 2) (B), angiogenesis (score 2) (C) and inflammation with infiltration of polymorph and mono nuclear inflammatory cells (score 2) (D). H&E stain, (2-A & C 100X), (2-B & D 400X).



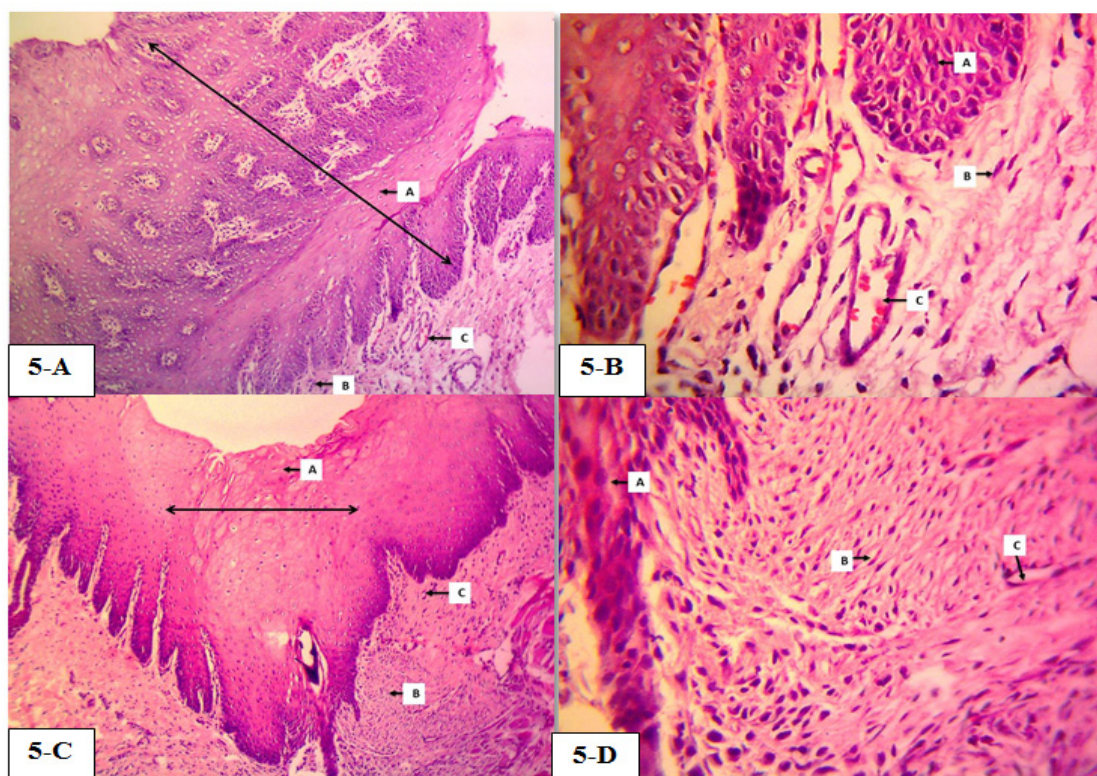


**Fig. 3.** Photomicrograph of rabbit gingiva of positive control (surgical wound with normal saline pre-treatment) group (after 3 days) shows the site of wound with ( $\leftrightarrow$ ), with re-epithelialization (Score 2) (A), granulation tissue (Score 1) (B), angiogenesis (Score 1) (C) and inflammation with infiltration of inflammatory cells (Score 3) (D). H&E stain, 100X.



**Fig. 4.** Photomicrograph of rabbit gingiva of administration Omega-3 pre-surgical wound group after 3 days. (4-A & B) (after 3 days) shows the site of wound with ( $\leftrightarrow$ ), with re-epithelialization (Score 3) (A), granulation tissue (Score 2) (B), angiogenesis (Score 1) (C) and inflammation with infiltration of inflammatory cells (Score 2) (D). (4-C & D) (after 7 days) shows the site of wound with re-epithelialization (Score 4) (A), granulation tissue (Score 1) (B), angiogenesis (score 2) (C) and inflammation with infiltration of inflammatory cells (Score 1) (D) H & E stain, (4-A & C 100X), (4-B & D 400X).





**Fig. 5.** photomicrograph of rabbit gingiva of Omega-3 pre and post-treatment (surgical wound) groups. (5-A & B) (After 3 days) shows the site of wound with re-epithelialization (Score 4) (A), granulation tissue (Score 2) (B), angiogenesis (Score 3) and without inflammation (Score 0) (C). (5-C & D) (After 7 days) shows the site of wound with re-epithelialization (score 4) (A), granulation tissue (Score 3) (B), angiogenesis (Score 3) (C) and without inflammation (Score 0). H & E stain, (5-A & C 100X), (5-B & D 400X).

Arachidonic acid is considered a pro-inflammatory since it is a mediator of inflammation and can operate as a vasodilator, and it is found in phospholipids[31]. Omega-3 competes with it when it is provided in the metabolic process [32]. Inflammation is influenced by the ratio of  $\omega$ -3 to  $\omega$ -6 arachidonic acid (AA) and  $\omega$ -3 EPA in tissues, plasma, and cell membranes [33].

More eicosanoids that are biologically less effective for inducing cellular responses than those produced by AA metabolism are produced with higher dietary levels of EPA and DHA derived metabolites, which impacts the generation of proinflammatory cytokines[34,35]. Furthermore, cell membrane fluidity, cell-to-cell signalling, cell motility, receptor contact with its agonist, membrane function such as capping position, and secondary signal generation are thought to affect proinflammatory cytokine gene expression at the transcriptional level[36].

Our findings are in line with one of the research that looked at the effect of EPA and DHA supplementation on wound healing in rabbit gingiva and the relationship between inflammation markers at wound sites[28]. Collagen production improved as a result of this investigation. Primary IL-1 expression also promotes keratinocyte development. It promotes re-epithelialization, boosts the generation of IL-6, and enhances blood vessel contraction[37].

Tian *et al.*(2020) observed that EPA greatly increased IL-6 release in MCL cells in a comparable investigation. A substantial linear relationship between IL-6 levels and collagen synthesis was also discovered by the researchers[38]. This shows that EPA supplementation could help tissues that benefit from higher collagen formation recover faster[39].

Several studies have found that adding omega-3 fatty acids to one's diet can help to

modulate inflammatory and immunological responses. Fatty acids can also impact natural killer cells, raising the CD4/CD8 ratio[40]. PUFAs have been shown to be beneficial in the treatment of a variety of inflammatory disorders in humans and animals, including rheumatoid arthritis, cardiovascular disease, diabetes, and autoimmune diseases. Omega-3, on the other hand, can be utilized to try to prevent gum tissue deterioration by suppressing cytokines[28].

The study found that using unsaturated omega-3 acids has a positive effect, especially when used for both prevention and treatment, and that it helped to reduce inflammatory markers while improving healing indications such as re-epithelialization, and granulation tissue, and angiogenesis. As a result, omega-3 can be considered a feasible alternative to antibiotics in the treatment of wounds and gingivitis.

#### Acknowledgment

We extend our sincere thanks to the College of Veterinary Medicine and College of Dentistry, University of Mosul for the facilities they provided to conduct this research

#### Conflicted interest

Noconflictinterest with self-funding statement.

*Funding statement:* Self-funding

#### References

1. Krzyszczyk, P., Schloss, R., Palmer, A. and Berthiaume, F. The role of macrophages in acute and chronic wound healing and interventions to promote pro-wound healing phenotypes. *Front. Physio.*, **1**(9),419(2018).<https://doi.org/10.3389/fphys.2018.00419>
2. Kim, S.Y. and Nair, M.G. Macrophages in wound healing: activation and plasticity. *Immun. cell bio.*, **97**(3),258-267(2019).<https://doi.org/10.1111/imcb.12236>
3. Carullo, G., Sciubba, F., Governa, P., Mazzotta, S., Frattaruolo, L., Grillo, G., Cappello, A.R., Cravotto, G., Di Cocco, M., E. and Aiello, F. Mantonico and pecorello grape seed extracts: Chemical characterization and evaluation of in vitro wound-healing and anti-inflammatory activities. *Pharma.*, **13**(5),97(2020).<https://doi.org/10.3390/ph13050097>
4. Ellis, S., Lin, E., J. and Tartar, D. Immunology of wound healing. *Current Derma. Reports.* **7**(4):350-358(2018) .<https://doi.org/10.1007/s13671-018-0234-9>
5. Tallima, H. and El Ridi, R. Arachidonic acid: physiological roles and potential health benefits-a review. *J. Advanced Rese.*, **1**(11):33-41(2018).  
<https://doi.org/10.1016/j.jare.2017.11.004>
6. Nishimura, M., Segami, N., Kaneyama, K., Suzuki T., and Miyamaru, M. "Proinflammatory cytokines and arthroscopic findings of patients with internal derangement and osteoarthritis of the temporomandibular joint." *British Journal of Oral and Maxillofacial Surgery*, **40**, 68-71(2002).  
<https://doi.org/10.1054/bjom.2001.0742>
7. Diegelmann, Robert F., and Melissa, C. Evans. "Wound healing: an overview of acute, fibrotic and delayed healing." *Front Biosci.*, **9** (1), 283-289(2004).<https://doi.org/10.2741/1184>
8. Jaggi, Ujjaldeep, Mingjie Yang, Harry H., Matundan, Satoshi Hirose, Prediman K., Shah, Behrooz, G., Sharifi, and Homayon Ghiasi. "Increased phagocytosis in the presence of enhanced M2-like macrophage responses correlates with increased primary and latent HSV-1 infection." *PLoS Pathogens*, **16** (10), e1008971(2020).<https://doi.org/10.1371/journal.ppat.1008971>
9. Li, L. J., Xu, X. H., Yuan, T. J., Hou, J., Yu, C. L., and Peng, L. H. Periplaneta Americana L. as a novel therapeutics accelerates wound repair and regeneration. *Biomedicine & Pharmacotherapy*, **114**, 108858,(2019). <https://doi.org/10.1016/j.biopha.2019.108858>
10. Theocharis A.D., Skandalis S.S., Gialeli C. and Karamanos N.K. Extracellular matrix structure. *Advanced Drug Delivery Reviews*. **1**(97):4-27(2016).<https://doi.org/10.1016/j.addr.2015.11.001>
11. MacDonald, K. W., Chanyi, R. M., Macklaim, J. M., Cadieux, P. A., Reid, G. and Burton, J. P. Streptococcus salivarius inhibits immune activation by periodontal disease pathogens. *BMC Oral Health*, **21**(1), 1-16(2021).<https://doi.org/10.1186/s12903-021-01606-z>



12. Chen, Y., Yu, C. Y. and Deng, W. M. The role of pro-inflammatory cytokines in lipid metabolism of metabolic diseases. *International Reviews of Immunology*, **38**(6),249-266(2019).<https://doi.org/10.1080/08830185.2019.1645138>
13. Casili, G., Ardizzone, A., Lanza, M., Gugliandolo, E., Portelli, M., Militi, A. and Paterniti, I. Treatment with Luteolin Improves Lipopolysaccharide-Induced Periodontal Diseases in Rats. *Biomedicines*, **8**(10), 442(2020).<https://doi.org/10.3390/biomedicines8100442>
14. Ghoshal, K. and Bhattacharyya, M. Overview of platelet physiology: its hemostatic and nonhemostatic role in disease pathogenesis. *The Scientific World Journal*, **2014**, Article ID 781857 (2014). <https://doi.org/10.1155/2014/781857>
15. Sprynsky, M., Monedeiro, F., Monedeiro-Milanowski, M., Nowak, Z., Krakowska-Sieprawska, A., Pomastowski, P. and Buszewski, B. Isolation of omega-3 polyunsaturated fatty acids (eicosapentaenoic acid-EPA and docosahexaenoic acid-DHA) from diatom biomass using different extraction methods. *Algal Research*, **62**, 102615 (2022).<https://doi.org/10.1016/j.algal.2021.102615>
16. Tocher, D. R., Betancor, M. B., Sprague, M., Olsen, R. E. and Napier, J. A. Omega-3 long-chain polyunsaturated fatty acids, EPA and DHA: bridging the gap between supply and demand. *Nutrients*, **11**(1), 89(2019). <https://doi.org/10.3390/nu11010089>
17. Saini, R. K. and Keum, Y. S. Omega-3 and omega-6 polyunsaturated fatty acids: Dietary sources, metabolism, and significance—A review. *Life Sciences*, **203**, 255-267 (2018). <https://doi.org/10.1016/j.lfs.2018.04.049>
18. Akanbi, T. O., Marshall, S. N. and Barrow, C. J. Polydatin-fatty acid conjugates are effective antioxidants for stabilizing omega 3-containing bulk fish oil and fish oil emulsions. *Food Chemistry*, **301**, 125297, (2019). <https://doi.org/10.1016/j.foodchem.2019.125297>
19. Mittal, S., Ali, J. and Baboota, S. Enhanced anti-psoriatic activity of tacrolimus loaded nanoemulsion gel via omega 3-Fatty acid (EPA and DHA) rich oils-fish oil and linseed oil. *Journal of Drug Delivery Science and Technology*, **63**, 102458 (2021).<https://doi.org/10.1016/j.jddst.2021.102458>
20. AlAmmar, W. A., Albeesh, F. H., Ibrahim, L. M., Algindan, Y. Y., Yamani, L. Z. and Khatlab, R. Y. Effect of omega-3 fatty acids and fish oil supplementation on multiple sclerosis: a systematic review. *Nutritional Neuroscience*, **24**(7), 569-579(2021).<https://doi.org/10.1080/1028415X.2019.1659560>
21. Kushwaha, A., Goswami, L. and Kim, B. S. Nanomaterial-based therapy for wound healing. *Nanomaterials*, **12**(4), 618,(2022).<https://doi.org/10.3390/nano12040618>
22. Wang, M., Huang, X., Zheng, H., Tang, Y., Zeng, K., Shao, L. and Li, L. Nanomaterials applied in wound healing: Mechanisms, limitations and perspectives. *Journal of Controlled Release*, **337**, 236-247(2021).<https://doi.org/10.1016/j.jconrel.2021.07.017>
23. Freedman, B. R., & Mooney, D. J. Biomaterials to mimic and heal connective tissues. *Advanced Materials*, **31**(19), 1806695(2019). <https://doi.org/10.1002/adma.201806695>
24. Mc Kittrick, A., Gustafsson, L., Hodson, T. and Di Tommaso, A. Exploration of individuals perspectives of recovery following severe hand burn injuries, *Burns*, **48** (2), 471-472(2022).<https://doi.org/10.1016/j.burns.2022.04.026>
25. Potter, D. A., Veitch, D. and Johnston, G. A. Scarring and wound healing. *British Journal of Hospital Medicine*, **80**(11), C166-C171(2019).<https://doi.org/10.12968/hmed.2019.80.11.C166>
26. Barta, D. G., Coman, V. and Vodnar, D. C. Microalgae as sources of omega-3 polyunsaturated fatty acids: Biotechnological aspects. *Algal Research*, **58**, 102410(2021).<https://doi.org/10.1016/j.algal.2021.102410>
27. Kruse, A. B., Kowalski, C. D., Leuthold, S., Vach, K., Ratka-Krüger, P. and Woelber, J. P. What is the impact of the adjunctive use of omega-3 fatty acids in the treatment of periodontitis? A systematic review and meta-analysis. *Lipids in Health and Disease*, **19**(1), 1-16 (2020). <https://doi.org/10.1186/s12944-020-01267-x>
28. Heo, H., Bae, J.H., Amano, A., Park, T. and Choi, Y.H. Supplemental or dietary intake of omega-3 fatty acids for the treatment of periodontitis: A meta-analysis. *J. Clin. Period.*, **49**(4):362-377(2022). <https://doi.org/10.1111/jcpe.13603>

29. Doğan, B., KemerDoğan, E. S., Özmen, Ö., Fentoğlu, Ö., Kırzioğlu, F. Y. and Calapoğlu, M. Synergistic Effect of Omega-3 and Probiotic Supplementation on Preventing Ligature-Induced Periodontitis. *Probiotics and Antimicrobial Proteins*, **14**(1), 114-120 (2022). <https://doi.org/10.1007/s12602-021-09803-6>
30. Mora, I., Arola, L., Caimari, A., Escoté, X. and Puiggròs, F. Structured Long-Chain Omega-3 Fatty Acids for Improvement of Cognitive Function during Aging. *International Journal of Molecular Sciences*, **23**(7), 3472(2022). <https://doi.org/10.3390/ijms23073472>
31. Innes, J. K. and Calder, P. C. Omega-6 fatty acids and inflammation. *Prostaglandins, Leukotrienes and Essential Fatty Acids*, **132**, 41-48(2018). <https://doi.org/10.1016/j.plefa.2018.03.004>
32. Saini, R. K. and Keum, Y. S. Omega-3 and omega-6 polyunsaturated fatty acids: Dietary sources, metabolism, and significance-A review. *Life Sciences*, **203**, 255-267(2018). <https://doi.org/10.1016/j.lfs.2018.04.049>
33. Punia, S., Sandhu, K. S., Siroha, A. K. and Dhull, S. B. Omega 3-metabolism, absorption, bioavailability and health benefits-A review. *Pharma. Nutrition*, **10**, 100162(2019). <https://doi.org/10.1016/j.phanu.2019.100162>
34. Balić, A., Vlašić, D., Žužul, K., Marinović, B. and Bukvić Mokos, Z. Omega-3 versus omega-6 polyunsaturated fatty acids in the prevention and treatment of inflammatory skin diseases. *International Journal of Molecular Sciences*, **21**(3), 741(2020). <https://doi.org/10.3390/ijms21030741>
35. Zhu, K., Liang, W., Ma, Z., Xu, D., Cao, S., Lu, X. and Yuan, J. Necroptosis promotes cell-autonomous activation of proinflammatory cytokine gene expression. *Cell death & disease*, **9**(5), 1-16(2018). <https://doi.org/10.1038/s41419-018-0524-y>
36. Dipasquale, D., Basiricò, L., Morera, P., Primi, R., Tröschler, A. and Bernabucci, U. Anti-inflammatory effects of conjugated linoleic acid isomers and essential fatty acids in bovine mammary epithelial cells. *Animal*, **12**(10), 2108-2114 (2018). <https://doi.org/10.1017/S1751731117003676>
37. Ellis, S., Lin, E. J. and Tartar, D. Immunology of wound healing. *Current Dermatology Reports*, **7**(4), 350-358(2018). <https://doi.org/10.1007/s13671-018-0234-9>
38. Tian, Y., Liu, Y., Xue, C., Wang, J., Wang, Y., Xu, J. and Li, Z. The exogenous natural phospholipids, EPA-PC and EPA-PE, contribute to ameliorate inflammation and promote macrophage polarization. *Food & Function*, **11**(7), 6542-6551(2020). <https://doi.org/10.1039/D0FO00804D>
39. Rawson, E. S., Miles, M. P. and Larson-Meyer, D. E. Dietary supplements for health, adaptation, and recovery in athletes. *International Journal of Sport Nutrition and Exercise Metabolism*, **28**(2), 188-199(2018). <https://doi.org/10.1123/ijsem.2017-0340>
40. Ververs, F. A., Engelen, S. E., Nuboer, R., Vastert, B., van der Ent, C. K., van't Land, B. and Schipper, H. S. Immunometabolic factors in adolescent chronic disease are associated with Th1 skewing of invariant Natural Killer T cells. *Scientific Reports*, **11**(1), 1-11 (2021). <https://doi.org/10.1038/s41598-021-99580-7>

## التغيرات النسيجية المرضية وتقييم نتائج استخدام أوميكا-3 في تحسين عملية التئام جروح اللثة في الأرانب

عمر خالد محمود<sup>1</sup>، جونا خالد ممدوح<sup>1</sup> و محمد غسان سعيد<sup>2</sup>

<sup>1</sup> فرع علوم طب الأسنان الأساسية - كلية طب الأسنان - جامعة الموصل - الموصل - العراق .  
<sup>2</sup> فرع الأمراض وامراض الدواجن - كلية الطب البيطري - جامعة الموصل - الموصل - العراق .

تمت دراسة تأثير أوميكا-3 كوسيلة وقائية او علاجية أو كليهما على شفاء جرح اللثة في الأرانب في هذه الدراسة، ولتحقيق هذا الهدف اشتملت الدراسة على 36 أرنبًا ، قسمت إلى 3 مجاميع ، كل مجموعة تضم 12 أرنب. استخدمت المجموعة الأولى كمجموعة سيطرة أعطيت المحلول الملحي الطبيعي لمدة 10 أيام ، بينما تلقت المجموعة الثانية أوميكا-3 لمدة 10 أيام قبل اجراء الجرح والمجموعة الثالثة تلقت أوميكا-3 لمدة 10 أيام قبل وبعد اجراء الجرح. تم عمل شق في اللثة (0,5 سم) في كافة المجاميع. سجلت المجموعة التي أعطيت أوميكا-3 لمدة 10 أيام قبل وبعد عملية الجرح أفضل النتائج من بين المعاملات السابقة. ولوحظ ظهور إعادة الظهارة وزيادة كبيرة في تكوين النسيج الحبيبي وتكوين الأوعية وانخفاض درجات الالتهاب. اظهر الفحص النسيجي (بعد 3 أيام) في موقع الجرح إعادة تكوين النسيج الظهاري (الدرجة 4) والنسيج الحبيبي (الدرجة 2) وتكوين الأوعية (الدرجة 3) وبدون حدوث الالتهاب (الدرجة 0) بعد 7 أيام ظهر في موقع الجرح إعادة تكوين النسيج الظهاري (الدرجة 4) والنسيج الحبيبي (الدرجة 3) وتكوين الأوعية (الدرجة 3) وبدون التهاب (الدرجة 0). خلصنا الى إن استخدام أحماض أوميكا-3 له تأثير إيجابي خاصة عند استخدامه للوقاية والعلاج معاً، كما أنه يساعد في تقليل علامات الالتهاب مع تحسين مؤشرات الشفاء مثل إعادة تكوين النسيج الظهاري والحبيبي وتكوين الأوعية الدموية الجديدة وتقليل نسبة الالتهاب، نتيجة لذلك يمكن اعتبار أوميكا-3 بديلاً مجدياً للمضادات الحيوية في علاج الجروح والتهاب اللثة.

**الكلمات المفتاحية:** أوميكا-3، جرح اللثة، الالتهاب ، التغيرات النسيجية المرضية.