

# Dexamethasone versus Dexmedetomidine as Adjuvant to Bupivacaine in Ultrasound Guided Erector Spinae Plane Block for Analgesia in Total Abdominal Hysterectomy

Doaa Shaaban Mohammed Ali\*, Ahmed Mohammed Salama, Kamelia Ahmed Abaza, Fatma Mahmoud Ahmed

Department of Anesthesia, Surgical intensive care and Pain Management, Faculty of Medicine Zagazig University, Egypt

\*Corresponding author: Doaa Shaaban Mohammed Ali, Mobile: (+20)1096006562, Email: amrdody83@gmail.Com

## ABSTRACT

**Background:** Local anesthetic adjuvants prolong analgesia duration with single shot interfascial plane blocks. They potentiate the analgesic effect of the local anesthetics. These adjuvants include several groups and different mechanisms of action such as dexamethasone and dexmedetomidine.

**Objectives:** This study was aimed at achievement of better analgesia for total abdominal hysterectomy patients via prolongation of sensory block duration and reducing opioid consumption.

**Patients and Methods:** This study was carried out at Zagazig University Hospitals where 84 female patients scheduled for total abdominal hysterectomy aged from 40 to 60 years, ASA physical status grade I, II and body mass index (BMI) 18.5-30 kg/m<sup>2</sup>. Patients were classified into three groups (28 each), group C (received bilateral ESPB with 20 ml bupivacaine 0.25% plus 1ml saline), group O (received bilateral ESPB with 20 ml bupivacaine 0.25% plus 1ml dexamethasone (4mg)), group D (received bilateral ESPB with 20 ml bupivacaine 0.25% plus 1 ml dexmedetomidine (0.5ug/kg) in saline). They underwent history taking, general examination, laboratory investigations, preoperative erector spinae plane block (ESPB) and GA.

**Results:** There was statistically significant difference between three groups regarding visual analog scale (VAS) and nalbuphine consumption where D group had better pain control than other groups.

**Conclusions:** It could be concluded that dexmedetomidine as an adjuvant to 0.25% bupivacaine in ultrasound guided erector spinae plane block is more efficacious than dexamethasone in hastening the onset, prolonging sensory blockade, delaying the time for request of rescue analgesia, and decreasing total nalbuphine consumption.

**Keywords:** ESPB, dexamethasone, dexmedetomidine, VAS, opioids, TAH.

## INTRODUCTION

Total abdominal hysterectomy (TAH) is a very common cause of postoperative pain. Uncontrolled postoperative pain can lead to long stay in recovery room, delayed mobilization, prolonged hospital stay and patient discomfort<sup>(1)</sup>. ESPB was first described by Forero *et al.* in 2016 for chronic and post-operative thoracic pain<sup>(2)</sup>.

ESPB is performed through injecting local anesthetic deep to erector spinae muscle and above the transverse process (TP). Local anesthetic then reaches the paravertebral space through spaces between adjacent vertebrae and blocks both the dorsal and ventral rami<sup>(3)</sup>. ESPB at low thoracic levels provides effective analgesia for gynecologic and abdominal surgery in previous studies<sup>(4-5)</sup>.

Local anesthetic adjuvants prolong analgesia duration with single shot interfascial plane blocks<sup>(6)</sup>. They potentiate the analgesic effect of the local anaesthetics. These adjuvants include several groups and different mechanisms of action such as dexamethasone and dexmedetomidine<sup>(7)</sup>.

Dexamethasone has anti-inflammatory function and inhibits potassium channel of C-fibers. It is an effective local anesthetic adjuvant in different blocks<sup>(7)</sup>. Dexmedetomidine can prolong the duration of the nerve block when used with local anesthetic<sup>(6)</sup>. It produces analgesia by different mechanism of action<sup>(8)</sup>.

This double-blind randomized control study was designed to compare the ESPB characteristics and side effects following erector spinae plane block with bupivacaine versus erector spinae plane block with bupivacaine supplemented with either dexamethasone or dexmedetomidine in patients scheduled for total abdominal hysterectomy.

## PATIENTS AND METHODS

This prospective randomized comparative clinical trial included 84 female patients scheduled for TAH under general anesthesia. The study was done from 2020 to 2022 at Zagazig University Hospitals.

**Inclusion criteria:** age between 40-60 years old, ASA I, II, BMI 18.5-30 kg/m<sup>2</sup> and patient acceptance.

**Exclusion criteria:** Patient refusal, known sensitivity or contraindication to any of study drugs, contraindications for regional anesthesia, uncooperative patients, history of psychological disorders or chronic pain and significant liver or renal disease.

The included 84 female patients were randomly divided into three groups: Group C (control): 28 Patients received bilateral ESPB with bupivacaine 21 ml (20 ml bupivacaine 0.25% + 1ml saline), group O: 28 Patients received bilateral ESPB with 21 ml (20 ml bupivacaine 0.25% + 4mg dexamethasone (1ml)) and

group **D**: 28 patients received bilateral ESPB with 21 ml (20 ml bupivacaine 0.25% + 0.5 ug/kg dexmedetomidine in saline(1ml)).

Postoperative onset of sensory block, intraoperative fentanyl consumption, VAS was recorded 30 min, 2, 4,8, 12, 18. 24 h postoperative, time tofirst nalbuphine request, total amount of nalbuphine consumption in the first 24 hours postoperative, duration of sensory block, any side effects (nausea, vomiting, others) and hospital stay were recorded.

**Ultrasound guided ESPB:** while patient in sitting position, linear ultrasound probe was placed 2-3 cm lateral to midline. Transverse process (TP 9) was identified. The erector spinae muscle was superficial to it. Then 22 g needle was inserted in-plane cranial-caudal direction until touching TP and 2ml normal saline was injected to confirm needle position. After that local anesthetic solution was injected and block assessment was done before general anesthesia.

**General anesthesia management:**

Intravenous induction drugs included: fentanyl 1ug/kg, propofol 2mg/kg, cisatracurium 0.15-0.2mg/kg. Endotracheal tube with suitable size was used to intubate the trachea. Anesthesia was maintained with oxygen air mixture (1:1) and 1 MAC isoflurane. Additional doses of cisatracurium 0.03 mg/kg were given on need. Fentanyl 1mcg/kg IV was given if heart rate and/or blood pressure increase 20% or more above basal readings. Volume controlled mechanical ventilation was used to maintain end tidal carbon dioxide at 35 to 37 mmHg. At the end of operation isoflurane was discontinued, residual neuromuscular blockade was antagonized using neostigmine and atropine administered intravenously and the patient was extubated. Immediate after recovery paracetamol 1gm

was infused and repeated every 8 hours. All patients received postoperative IV Paracetamol 1000mg (1gm) q 8 hours and rescue analgesia IV nalbuphine titrated according to severity of pain and physical status of the patient, when VAS ≥3 or on need.

**Ethical Consideration:**

An approval of the study was obtained from Zagazig University Academic and Ethical Committee. Every patient signed an informed written consent for acceptance of the operation. This work has been carried out in accordance with The Code of Ethics of the World Medical Association (Declaration of Helsinki) for studies involving humans.

**Statistical Analysis**

All data were collected, tabulated, and statistically analyzed using SPSS 26.0 for windows (SPSS Inc., Chicago, IL, USA). Quantitative data were expressed as the mean ± SD & median (interquartile range), and qualitative data were expressed as absolute (number) & relative frequencies (percentage).

One way ANOVA-test was used to compare between more than two groups of normally distributed variables while Kruskal Wallis test was used to compare between more than two independent groups of non-normally distributed variables. Percent of categorical variables were compared using Chi-square test. All tests were two sided. p-value < 0.05 was considered statistically significant (S), p-value ≥ 0.05 was considered statistically insignificant (NS).

**RESULTS**

There was no significant difference between the studied groups regarding demographic data (age, BMI, ASA) (Table 1).

**Table (1): Patients’ demographic data in the three studied groups**

Variable	Group C (n=28)		Group O (n=28)		Group D (n=28)		P Value
Age (years) <sup>a</sup> mean±SD	53.11±4.95 41-60		54.75±4.31 47-60		54.32±5.12 45-60		0.419
BMI (kg/m <sup>2</sup> ) <sup>a</sup> mean±SD	25.08±3.2 (19.5-29.8)		25.27±3.02 (18.8-29.8)		25.01±3.02 (18.6-30)		0.948
ASA <sup>b</sup>	No.	%	No.	%	No.	%	0.714
-Normal health	15	53.6	14	50	17	60.7	
-Mild systemic disease	13	46.4	14	50	11	39.3	

No=number, BMI=body mass index

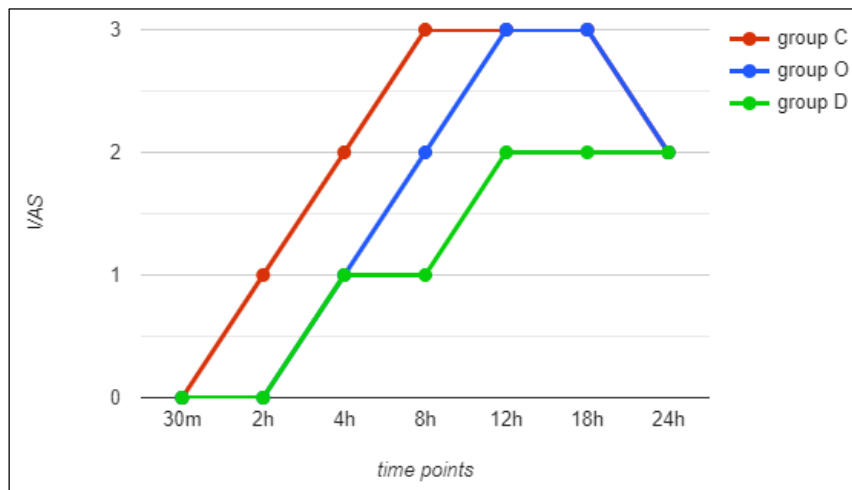
<sup>a</sup> One-Way ANOVA test, <sup>b</sup> Chi-square test.

C control group (bupivacaine alone)

O, dexamethasone group (bupivacaine plus dexamethasone)

D, dexmedetomidine group (bupivacaine plus dexmedetomidine).

VAS score was the lowest in D group at different postoperative time points 2, 4, 8, 12 and 18 h (Fig. 1).



**Fig. (1): Line graph illustrating postoperative VAS at different intervals**

As shown in table (2), there was statistically significant difference between the study groups regarding onset & duration of block where both the shortest onset and the longest duration of block was at D group. No significant difference regarding intraoperative fentanyl consumption

**Table (2): onset, duration of block and intraoperative fentanyl consumption among the studied groups**

Variable	Group C (n=28)	Group O (n=28)	Group D (n=28)	P value	Post hoc
Onset (min) <sup>a</sup> mean±SD	17.35±4.2	14.6±2.9	9.75±1.77	<0.001*	P1=0.002* P2<0.001* P3<0.001*
Duration of block (min) <sup>a</sup> mean±SD	604.14±27.9	832.21±78.4	1254.28±52.8	<0.001*	P1<0.001* P2<0.001* P3<0.001*
Intra-operative fentanyl(ug) <sup>c</sup> median & IQR	0 (0-77.5)	0 (0-73.5)	0 (0-65)	0.432	P1=0.907 P2=0.313 P3=0.352

<sup>a</sup> One-Way ANOVA Test, <sup>c</sup> Kruskal Wallis test

C, control group (bupivacaine alone)

O, dexamethasone group (bupivacaine plus dexamethasone)

D, dexmedetomidine group (bupivacaine plus dexmedetomidine)

P1=C versus O, P2=C versus D, P3=O versus D

\*=Statistical significance difference (p<0.05)

As shown in table (3), there was statistically significant difference between the studied groups regarding time of postoperative first nalbuphine (min) and total nalbuphine consumed (mg) where the latest time of 1<sup>st</sup> nalbuphine was in D group and the highest amount of total nalbuphine dose was in C group.

**Table (3): Nalbuphine, in the three studied groups**

Variable	Group C (n=28)	Group O (n=28)	Group D (n=28)	P value	Post hoc
First naluphine (postop) (min) <sup>c</sup> Median (IQR)	471.5(451.3-480)	720(480-720)	1080(540-1136.75)	<0.001*	P1=<0.001 P2=<0.001 P3=<0.001
Total naluphine (mg) <sup>c</sup> Median (IQR)	21 (18-26)	18 (16-20)	9 (3-13)	<0.001*	P1=<0.001 P2=0.002 P3=<0.001

<sup>c</sup> Kruskal Wallis test

C, control group (bupivacaine alone)

O, dexamethasone group (bupivacaine plus dexamethasone)

D, dexmedetomidine group (bupivacaine plus dexmedetomidine)

P1=C versus O, P2=C versus D, P3=O versus D

\*=Statistical significance difference (p<0.05)

As shown in table (4) there was statistically significant difference between the three studied groups regarding hospital stay with group D had significantly shorter duration than both group C and group O. There was no statistically significant difference between the three studied groups regarding side effects.

**Table (4): hospital stay and side effects in the studied groups**

Variable		Group C (n=28)	Group O (n=28)	Group D (n=28)	P value	Post hoc
<b>Hospital stay (days) <sup>a</sup></b>					0.002*	P1=0.602 P2=0.001* P3=0.005*
Mean±SD		2.60±0.49	2.53±0.50	2.14±0.52		
Range		(2-3)	(2-3)	(1-3)		
<b>SE<sup>b</sup></b>	No	25 (89.3%)	26 (92.9%)	27 (96.4%)	0.584	NS
	Yes	3 (10.7%)	2 (7.1%)	1 (3.6%)		

SE= side effects

C, control group (bupivacaine alone)

O, dexamethasone group (bupivacaine plus dexamethasone)

D, dexmedetomidine group (bupivacaine plus dexmedetomidine)

a= One-Way ANOVA Test

b= Chi square test

P1=C versus O, P2=C versus D, P3=O versus D

\*=Statistical significance difference (p<0.05)

NS = Non significant

## DISCUSSION

ESPB was introduced by **Forero et al.** (2), to manage thoracic neuropathic pain in 2016, then it has been applied in different kinds of surgeries. It has been part of multimodal analgesia regimen to achieve postoperative analgesia (5). Addition of adjuvants to LA in ESPB can prolong analgesia duration and achieve better pain control in the postoperative period. Dexmedetomidine can cause anxiolysis, sedation and analgesia. When used in nerve blocks it shortens onset time of block and prolong period of analgesia (9).

Using Dexmedetomidine in ESPB decreased VAS and analgesic consumption in the postoperative period when compared to plain ropivacaine without any adjunct (10). Few studies reported bradycardia, hypotension and sedation with dose of 1-2 mcg/kg (11).

Dexamethasone probably acts through decreasing perineural edema, decreasing systemic absorption of LA by inducing vasoconstriction, reducing neural discharge and suppressing pain transmission (12). **Fusco et al.** (13) reported better pain control when dexamethasone was used as an adjuvant with LA for bilateral ESPB. Dexamethasone was used in different doses in regional blocks (14). It can prolong the block duration with few to none perineural toxicity (15).

Regarding primary outcome, our study showed that VAS score at time-points 2,4,8,12, 18 h postoperatively decreased significantly in D group than O group while it was significantly higher in C group in 1<sup>st</sup> 18 h postoperatively and this come in line with **Ali et al** results when they concluded that VAS score in control group was higher than remaining groups when they compared dexmedetomidine versus dexamethasone as adjuvants to bupivacaine in Supraclavicular brachial plexus block (16). **Gad and**

**El-Metwally** (8) evaluated the effectiveness of adding dexmedetomidine 0.5 ug/kg to 0.5ml/kg levobupivacaine 0.25% in a US-guided serratus plane block for modified radical mastectomy. Their results concluded that using dexmedetomidine as adjuvant to levobupivacaine significantly decreased VAS at 8 and 12 h postoperatively.

However, **Basing et al.** (17) results were not similar to ours. They conducted a study comparing dexmedetomidine and dexamethasone as additives to ropivacaine in erector spinae plane block for patients undergoing breast surgery and concluded that p value was > 0.05% between the 2 groups in their statistical analysis of VAS at different time points with median was 2 in both groups.

The onset of sensory block was earlier in group D compared to group O. It was in dexmedetomidine and dexamethasone groups (9.75±1.77 min) and (14.6±2.9 min) respectively. This was found to be statistically significant. This is similar to the results obtained by **Verma et al** where they used 30 ml ropivacaine 0.5% with 50 ug dexmedetomidine in DM group and 30 ml ropivacaine 0.5% with 8mg dexamethasone in DX group. They showed that block onset time was earlier in group DM as compared to group DX (p<0.05) (18). Researchers had found that addition of dexmedetomidine (50 µg) to 30 ml ropivacaine 0.5% in ultrasound-guided supraclavicular brachial plexus block resulted in earlier onset of sensory block (19). Also, it was earlier in **Hassan et al** study with p value 0.007 between dexmedetomidine and dexamethasone as adjuvants to levobupivacaine for cervical plexus block in patients undergoing thyroid operation (20).

**Lee et al.** (21), observed that significant differences in onset time was not noticed among three groups in their study (dexamethasone or

dexmedetomidine as local anesthetic adjuvants for ultrasound guided axillary brachial plexus blocks with nerve stimulation) which may be attributable to the higher dose of dexamethasone (10mg).

On the contrary to our results **kumar et al.** (22), concluded that onset of action of interscalene block had no significant difference between three groups in their study that compared both 8 mg dexamethasone and 50ug dexmedetomidine as adjuvants to 0.25% bupivacaine in interscalene brachial plexus block and this may be due to lower dose of dexmedetomidine.

Also, postoperative hemodynamics results in **Thakur et al.** (23) study were similar to our results. They observed that HR and DBP showed significant difference at 2h and at 0,2,4,12,18,24 h postoperative respectively.

**Verma et al.** (18) found that comparison of pulse rate and mean arterial pressure were comparable in both groups (dexamethasone and dexmedetomidine) without any statistical significance.

**Singla et al.** (24) found that no significant difference between groups in the postoperative hemodynamic parameters in their study to assess analgesic efficacy of dexamethasone and dexmedetomidine when added to ropivacaine in ultrasound-guided transversus abdominis plane block to manage post-operative pain in caesarean section.

In accordance with our results **Gupta and Nasar** (25) and **Adinarayanan et al.** (26) documented that intraoperative opioid consumption was comparable between groups in their studies. Using dexmedetomidine as adjuvant to bupivacaine in our study prolonged the time to first nalbuphine request. Studies of (24-25, 27-29) concluded similar results. Postoperative nalbuphine consumption in D group was about half that in O and C groups. This was in line with (18-20, 30) results which showed more reduction in postoperative analgesic consumption when using dexmedetomidine as adjuvant to local anesthetics.

However **Margulis et al.** (31) and **Basing et al.** (17) contradict our results where they found that intraoperative opioid consumption was less in the dexmedetomidine group when compared to both the control and dexamethasone group when both drugs were used as adjuvant to (20) ml ropivacaine 0.5% in ultrasound guided interscalene block in arthroscopic shoulder surgery and there was no difference in total analgesic consumption and the demand for first rescue analgesia between the dexmedetomidine and dexamethasone group in their comparative study between dexmedetomidine and dexamethasone as adjunct to ropivacaine in erector spinae plane block for patients undergoing breast surgery respectively. This may be due to lower dexamethasone dose (4mg) in the 1st study and difference in dexmedetomidine dose they used (0.5ug/kg) in 2nd one.

Hospital stay was about 20% more in C and O groups than D group. **Gupta and Nasar** (25) proved that hospital stay was (4) days in dexmedetomidine group

which is less than dexamethasone group (6) days in their study in which group I patients received 0.375% ropivacaine 20 mL, group II patients received 0.375% ropivacaine 20 mL with 8 mg dexamethasone and group III patients received 0.375% ropivacaine 20 mL with 1 µg/kg dexmedetomidine in ESPB. Incidence of post-operative nausea vomiting was equivalent in all groups. No other side effects were recorded.

## CONCLUSION

It could be concluded that dexmedetomidine as an adjuvant to 0.25% bupivacaine in ultrasound guided erector spinae plane block is more efficacious than dexamethasone in hastening the onset, prolonging sensory blockade, delaying the time for request of rescue analgesia, and decreasing total nalbuphine consumption.

**Conflict of interest:** The authors declare no conflict of interest.

**Sources of funding:** This research did not receive any specific grant from funding agencies in the public, commercial, or not-for-profit sectors.

**Author contribution:** Authors contributed equally in the study.

## REFERENCES

1. **Suner Z, Kalayci D, Sen O et al. (2019):** Postoperative analgesia after total abdominal hysterectomy: Is the transversus abdominis plane block effective? *Nigerian Journal of Clinical Practice*, 22(4), 478-484.
2. **Forero M, Adhikary S, Lopez H et al. (2016):** The erector spinae plane block: a novel analgesic technique in thoracic neuropathic pain. *Reg Anesth Pain Med.*, 41:621-627.
3. **Ueshima H, Otake H (2017):** Similarities between the retrolaminar and erector spinae plane blocks. *Reg Anesth Pain Med.*, 42:123-24.
4. **Chin K, Adhikary S, Sarwani N et al. (2017):** The analgesic efficacy of pre-operative bilateral erector spinae plane (ESP) blocks in patients having ventral hernia repair. *Anaesthesia*, 72:452-460.
5. **Hamed M, Goda A, Basiony M et al. (2019):** Erector spinae plane block for postoperative analgesia in patients undergoing total abdominal hysterectomy. A randomized controlled study original study. *Journal of Pain Research*, 12: 1393-1398.
6. **Gao Z, Xiao Y, Wang Q et al. (2019):** Comparison of dexmedetomidine and dexamethasone as adjuvant for ropivacaine in ultrasound-guided erector spinae plane block for video-assisted thoracoscopic lobectomy surgery. A randomized, double-blind, placebo-controlled trial. *Ann Trans Med.*, 7(22):668-73.
7. **Swain A, Nag D, Sahu S et al. (2019):** Adjuvants to local anesthetics: Current understanding and future trends. *World J Clin Cases*, 5(8): 307-323.
8. **Gad M, Elmetwally M (2019):** Efficacy of adding dexmedetomidine as adjuvant with levobupivacaine in ultrasound-guided serratus plane block for modified radical mastectomy surgery. *Research and Opinion in Anesthesia & Intensive Care*, 6(2): 234-242.
9. **Rojas González A (2019):** Dexmedetomidine as an

- adjuvant to peripheral nerve block. *Rev Soc Esp Dolor.*, 26(2):103-15.
10. **Wang X, Ran G, Chen X et al. (2021):** The effect of ultrasound-guided erector spinae plane block combined with dexmedetomidine on postoperative analgesia in patients undergoing modified radical mastectomy. A randomized controlled trial. *Pain and Therapy*, 10(1):475- 84.
  11. **Al Nobani M, Ayasa M, Tageldin T et al. (2020):** The Effect of Different Doses of Intravenous Dexmedetomidine on the Properties of Subarachnoid Blockade. A Systematic Review and Meta-Analysis. *Local Regional Anesthesia*, 13:207-112.
  12. **Oliveira J (2015):** Does the addition of dexamethasone to local anesthetic used for peripheral nerve block prolong analgesia in the surgical patient? In *The Surgical Patient? Nurse Anesthesia Capstones*, 3:1- 22.
  13. **Fusco P, Volpe D, De Paolis V et al. (2019):** Dexamethasone as a local anesthetic adjuvant in bilateral ultrasound guided erector spinae plane block can provide a long-lasting analgesia in laparotomic abdominal surgery. *Minerva Anestesiologica*, 85(10):1144-5.
  14. **Zhang S, Song M, An W et al. (2021):** Effects of different doses of dexamethasone as local anesthetic adjuvant on brachial plexus block A protocol for systematic review and meta-analysis. *Medicine*, 30:100-17
  15. **Marty P, Bennis M, Legailard B (2018):** A new step toward evidence of in-vivo perineural dexamethasone safety: an animal study. *Regional Anesthesia Pain Med.*, 43:180-5.
  16. **Ali B, Hussain M, Jasim R (2020):** Comparative study between dexmedetomidine and dexamethasone as adjuvants to bupivacaine in supraclavicular brachial plexus block. *Sys Rev Pharm.*, 11(11):643-649.
  17. **Basing J, Deka A, Majumdar U (2021):** Dexmedetomidine versus dexamethasone as adjunct to ropivacaine in erector spinae plane block for patients undergoing breast surgery. A randomized, prospective, double blinded study. *International Journal of Research in Medical Sciences*, 9(10):3131-3136.
  18. **Verma N, Ranjan A (2016):** A clinical comparison of dexmedetomidine and dexamethasone as adjuvant to ropivacaine in supraclavicular brachial plexus blocks for upper arm surgeries. *Int J Adv Res Biol Sci.*, 3: 56-61.
  19. **Kathuria S, Gupta S, Dhawan I (2015):** Dexmedetomidine as an adjuvant to ropivacaine in supraclavicular brachial plexus block. *Saudi Journal of Anaesthesia*, 9: 148-154.
  20. **Hassan A, Amer I, Abdelkareem A (2021):** Comparative study between dexmedetomidine versus dexamethasone as adjuvants to levobupivacaine for cervical plexus block in patients undergoing thyroid operation. prospective-randomized clinical trial. *The Egyptian Journal of Hospital Medicine*, 84: 1638-164.
  21. **Lee M, Koo D, Choi Y et al. (2016):** Dexamethasone or dexmedetomidine as local anesthetic adjuvants for ultrasound-guided axillary brachial plexus blocks with nerve stimulation. *The Korean J Pain*, 29:29-33.
  22. **Kumar N (2014):** Comparative study between 0.25% Bupivacaine with 8 M.G Dexamethasone and 0.25% Bupivacaine with 50µg Dexmedetomidine as an adjuvant for interscalene brachial plexus Block: prospective clinical study. *Journal of Evolution of Medical and Dental Sciences*, 3(58): 13111-13119.
  23. **Thakur J, Gupta B, Gupta A et al. (2019):** A prospective randomized study to compare dexmedetomidine and dexamethasone as an adjunct to bupivacaine in transversus abdominis plane block for post-operative analgesia in caesarean delivery. *International Journal of Reproduction, Contraception, Obstetrics and Gynecology*, 8(12): 4903-4908.
  24. **Singla N, Garg K, Jain R et al. (2021):** Analgesic efficacy of dexamethasone versus dexmedetomidine as an adjuvant to ropivacaine in ultrasound-guided transversus abdominis plane block for post-operative pain relief in caesarean section: A prospective randomised controlled study. *Indian Journal of Anaesthesia*, 65(3): 31:36.
  25. **Gupta R, Nasar N (2021):** Comparison of dexamethasone and dexmedetomidine as an adjuvant to 0.375% ropivacaine in erector spinae plane block for lumbar spine surgery: A randomized, double-blind, placebo-control trial. *Academia Anestesiologica International*, 6(1): 2617-5479.
  26. **Adinarayanan S, Chandran R, Swaminathan S et al. (2019):** Comparison of dexamethasone and dexmedetomidine as adjuvants to bupivacaine in supraclavicular brachial plexus block: (2019) A prospective randomized study. *Indian Journal of Clinical Anaesthesia*, 6(4):523–527.
  27. **Dar F, Najar M, Jan N (2013):** Effect of addition of dexamethasone to ropivacaine in supraclavicular brachial plexus block. *Indian Journal of Pain*, 27(3): 165:169.
  28. **Patil B, Sonavdekar S, Mathur R (2019):** A Study on Effects of Dexmedetomidine Used as an Adjuvant in Epidural Post- Operative Analgesia. *Asian Journal of Medical Research*, 8 (3): 1-4.
  29. **Shekar M, Kanakalakshmi S, Mathew S et al. (2020):** Comparison of ultrasound guided interscalene brachial plexus block using 0.2% ropivacaine with dexmedetomidine and 0.2% ropivacaine with dexamethasone. A prospective observational study. *Journal of Anaesthesiology*, 28(2):114-118.
  30. **Elshal M, Gamal R, Ahmed A et al. (2021):** Efficacy of adding dexmedetomidine as adjuvant with bupivacaine in ultrasound-guided erector spinae plane block for post thoracotomy pain: Randomized controlled study. *Egyptian Journal of Anaesthesia*, 37(1): 425- 431.
  31. **Margulis R, Francis J, Tischenkel B et al. (2021):** Comparison of dexmedetomidine and dexamethasone as adjuvants to ultra-sound guided interscalene block in arthroscopic shoulder surgery. A double-blinded randomized placebo-controlled study. doi: 10.5812/aapm.117020.