

Fixator Assisted Internal Fixation of Paediatric Femoral Fractures

Ahmed A. Elsheikh^a, Ahmed E. Elsayed^a, Wael A. Kandel^a, Selvadurai Nayagam^b

^a Department of orthopedic surgery, Benha faculty of medicine, Benha University, Egypt. ^b Department of orthopedic surgery, Royal Liverpool Children's and Royal Liverpool University Hospital NHS Trust, Liverpool, UK.

Correspondence to: Ahmed E. Elsayed, Department of orthopedic surgery, Benha faculty of medicine, Benha University, Egypt.

Email:

ahmedelrabeay44@gmail.com

Received: 9 January 2022

Accepted: 14 August 2022

Abstract

Background: Femoral shaft fractures in children are serious injuries requiring hospitalisation. Different fixation methods were described.

Aim: We present a novel technique using external fixator to facilitate and control the reduction intraoperatively, which would allow for easier sub muscular plate application. **Methods:** We have retrospectively reviewed five boys and five girls. Polyaxial clamps and rods were applied to the sagittally-oriented bone screws, the reduction was done manually, and the clamps were tightened after achieving the proper alignment. The sub muscular plate was applied, and then clamps and bone screws were removed. **Results:** The mean age at surgery was 12 years. The mean body weight was 42 kg. There were six type A fractures, two type B and two type C. The mean preoperative haemoglobin concentration was 12.29 g/dl. No blood transfusion was needed. The operative time averaged 122 minutes, and the mean hospital stay after was 2 days. The patients reported no pain at a mean of 1.6 weeks. All fractures united, without neither malalignment nor length discrepancy, at a mean of 8.3 weeks (range 6-12 weeks). Neither wound healing problems nor deep infections happened. **Conclusion:** External fixator-assisted internal fixation of paediatric femoral fractures would facilitate the accuracy and control of fracture reduction and allow minimally invasive percutaneous osteosynthesis.

Keywords: Fixator-assisted; paediatric femoral fractures; flexible intramedullary nail; sub muscular plate; length-unstable fractures.

Introduction

Femoral shaft fractures represent 1.4%–1.7% of all fractures in children and are the most common paediatric bony injury needing hospitalisation. (18 & 2). Two-thirds of these occur in children between the ages of 6 to 18 years old, with males are affected mostly (70%) and motor vehicle accidents the most common mechanism of injury. Child abuse should always be suspected and ruled out, especially in younger children (3).

Treatment options for this age group range between open plating, minimally invasive plating, flexible intramedullary nailing, locked intramedullary nailing and external fixation (4, 5). Neither published evidence nor established global guidelines favour one method over the other. The National Institute for Health and Care Excellence (NICE) of the UK has advised using flexible intramedullary nailing for the ages 4 to 12 years provided that the child's weight is less than 50kg. In contrast, trochanteric-entry locked intramedullary nailing, or sub muscular plating is used more often in children older than 11 years old or heavier than 50 kgs (6).

The AAOS Clinical Practice Guideline on the Treatment of Paediatric Diaphyseal

Femur Fractures has presented limited evidence to support the use of flexible intramedullary nailing in the age group 5 to 11 years. There was limited evidence also to support minimally invasive plating, flexible intramedullary nailing (FIN), and trochanteric entry locked intramedullary nailing in the ages over 11 years (7).

Flexible intramedullary nailing, specifically elastic stable intramedullary nailing (ESIN), has been established as a method that entails a shorter operative time, less blood loss and a shorter hospital stay compared to the use of sub muscular plates (8-10). Good results are obtained in length stable fracture patterns, patients who are lighter than 50kg and after surgery with an optimal configuration of the nails in the medulla (11, 12). However, some reports have associated flexible nailing with more mal union, delayed weight-bearing and healing, and hardware irritation (13, 14).

Sub muscular plating is a more dependable option for fracture fixation in length-unstable or complex patterns and heavier children (15-17). The advantages of plating against FIN have been shown biomechanically, especially with comminuted and length-unstable fracture patterns. The clinical indications for this

technique are often extended due to the advantages of achieving better alignment and facilitating earlier weight-bearing(13, 14). Whilst the sub muscular plating technique is well described (18), surgical implementation can be challenging from controlling fracture reduction, length and rotation intraoperatively prior to insertion of the plate. Despite a decreased incidence of mal union reported with the classic technique (16 & 17), complex and unstable fracture patterns do not always spontaneously reduce on traction. We believe introducing an intraoperative tool to facilitate and control the reduction prior to fixation is paramount.

This report aims to describe a novel technique, used previously for deformity correction but not for trauma (19, 20), that overcomes problems of accurate fracture reduction and control prior to sub muscular plating. It facilitates the omission of a fracture (traction) table for these cases and, once practised, enables even the most complex fracture patterns to be handled. The functional, clinical, and radiological outcomes, as applied to a case series of paediatric femoral fractures, are included to emphasise the technique's usefulness.

Patients and methods

This **retrospective case series** included ten children and adolescents between six and 16 years-old with closed femoral shaft fractures of all patterns, treated in a single centre (**Benha University Hospitals**) between January 2020 and October 2020 by a single surgeon (**AAE**). Informed consent was obtained from the parent or guardian. Open fractures, fractures with vascular injuries, proximal and distal metaphyseal femoral fractures were excluded. Fractures older than 21 days were also excluded, as the technique is indicated for fresh fractures where a closed reduction is achievable.

A detailed clinical evaluation of the soft tissues, neurovascular integrity, and exclusion of any ipsilateral injuries was undertaken. The age, sex, weight and mechanism of injury were recorded. A radiological evaluation was done as per the ATLS protocol after stabilising the patient's condition. Standard anteroposterior (AP) and lateral views of the femur, hips and knees were obtained. Computerised Tomography (CT) was done in proximal or distal femoral fractures to exclude intraarticular extensions of fracture or a concomitant physeal injury.

This retrospective study was approved by the research ethics committee (REC) of the hospital. All procedures performed were in accordance with the ethical standards of the institution and the national research committee and with the 1964 Helsinki declaration and its later amendments.

Operative technique:

A traction table was not used. Under general anaesthesia, and in the supine position on a radiolucent table, one or two 6 mm half-pins (two if the bone segment was long) were introduced in the distal segment and one or two bone screws in the proximal segment. These pins were inserted in the sagittal plane with care taken not to over-penetrate the posterior cortex. Predrilling was done before the half-pin insertion. Although quadriceps penetration was necessary for the sagittal plane insertion of these half-pins, this would not translate to a postoperative problem as these were removed at the end of the surgery.

Polyaxial clamps and bars (Galaxy external fixation system, Orthofix SRL, Verona, Italy) were used to connect the pins in each segment. These were tightened securely. A third bar was then applied to connect the two bone segments. Fracture reduction was obtained using manual traction and manipulation with guidance from image

intensifier (C-arm) views. On achieving an acceptable reduction (axially aligned on orthogonal views and with contact between the fracture fragments), the clamps connecting the third bar to the proximal and distal bone segments were tightened. Just prior to final tightening, x-rays were used to check that over-distraction (with the ensuing reduction in fracture contact) had not occurred. If found to be present, one of the clamps connecting the third rod was loosened very slightly and slight tapping on this connecting rod with a mallet allowed the gap to close. Final tightening of all clamps then confirmed the stability of the assembled construct.

The sub muscular plate insertion was carried out as a fixation-in-situ, in the extraperiosteal and sub muscular plane (15). Through small incisions at the proximal and distal ends of the femoral shaft, the sub muscular plane was identified and entered and a track created by careful blunt dissection between the two incisions. The plate was then inserted gradually, taking care to ensure satisfactory plate positioning in the lateral view. Plate contouring was sometimes needed if the plate covered the proximal and distal third of the femoral shaft. Non-locking screws were applied initially at both ends of the plate to bring the

plate into contact with bone. Subsequent screws were applied in the near-near, far-far fashion in relation to the fracture. In one case with a segmental fracture, an extra small incision was needed to manipulate the segment percutaneously before fixation by screws (Figure 1 a, b, c &d).

On completing the fixation, the external fixator and half-pins were removed and the knee ranged to ensure there was unimpeded motion. No plaster casts or external knee immobilisers were used after wound closure. The inpatient after-care consisted of pain control and monitoring of the vital signs. Patient discharge was determined by the general condition, the level of post-injury and post-surgical discomfort and progress with rehabilitation.

Post-discharge rehabilitation:

The patient was instructed not to weight-bear for the first two weeks but maintain active and passive range of motion of the hip, knee and ankle joints. Partial weight-bearing (at 50 %) was commenced between two and six weeks and advancing to increased amounts after six weeks. Radiological evidence of progress in fracture union allowed

weight-bearing to be increased to ‘as-tolerated’ levels.

Follow up:

Regular follow up every two weeks allowed serial records of joint range of motion and for wound issues or signs of infection.

The following data were recorded. Patient demographics included the characteristics of the patients within the sample and the details of the injury. Logistic and treatment details included delays to surgery for the cases and data surrounding the actual operations. A visual analogue score (VAS – 10 cm scale) was used to record pain levels serially and the progress of healing recorded through radiographs at regular intervals.

Statistical Analysis

Data management and statistical analysis were done using SPSS version 25. (IBM, Armonk, New York, United States). Quantitative data were assessed for normality using the Shapiro-Wilk test and direct data visualisation methods. According to normality, numerical data were summarised as means and standard deviations. Categorical data were summarised as numbers and percentages. Correlations between time to union and

other parameters were done using Pearson's or Spearman's correlation. Time to union was compared according to different parameters using independent t-test. All statistical tests were two-sided. P values less than 0.05 were considered significant.

Results

The mean age at surgery was 12 years (range, 9 to 14). Five were boys (50%) and five girls (50%). The mean body weight at surgery was 41.6 kg (range, 30 to 66). The left femur was involved in eight patients and the right femur in two only. There were seven fractures affecting the middle part of the shaft, two in the proximal third and one in the distal third.

Fracture patterns and mechanisms of injury are presented in Table 1 (Table 1: Characteristics of the patients, mechanisms of injury and a classification of the fractures.). The mean delay to surgery was 7.2 days (range 1 to 18 days). The mean preoperative haemoglobin concentration of 12.18 g/dl (range 11.3 to 13 g/dl).

The operative time averaged 122 minutes (range, 100–150 minutes). A broad locked

LCP – DCP was used in all cases. The length depended on the segment of femoral shaft needing to be spanned (12 to 18-hole plates were used). No blood transfusion was needed intraoperatively or postoperatively. The pain levels (VAS) as recorded on the following postoperative day averaged 5 (range 2 to 9). Subsequent serial measurements showed patients reporting no pain (0) at a mean of 1.5 weeks (range, one to three weeks). The hospital stay after the surgery averaged 1.8 days (range 1 to 4 days).

On average, follow-up after surgery was 38 weeks (range 16 to 48 weeks). All fractures united at a mean of 9.5 weeks (range 6 to 12 weeks). Neither wound healing problems nor deep infections were encountered. The knee joint range of motion was full in all patients at six weeks postoperatively with no pain reported at this time. There was no mechanical irritation from the inserted plate. At final review, all fractures united fully without mal alignment nor length discrepancy (Figures 2 a, b and c).

Sex	Age (yrs)	Weight (kg)	Side	Site	Fracture pattern	AO class	Mechanism of injury
F	13	36	L	Mid shaft	Multifrag - Intact seg	32 C2	Road Traffic Accident
M	13	49	L	Mid shaft	Simple - Transverse	32 A3	Road Traffic Accident
M	14	44	R	Mid shaft	Simple - Oblique	32 A2	Road Traffic Accident
F	14	40	L	Distal third	Wedge - intact	32 B2	Fall (less than 5 feet)
M	9	30	L	Mid shaft	Wedge - fragmentary	32 B3	Direct Trauma
M	13	38	L	Proximal third	Simple - Spiral	32 A1	Direct Trauma
F	13	66	L	Mid shaft	Simple - Oblique	32 A2	Road Traffic Accident
F	10	33	L	Proximal third	Multifrag - fragmented segment	32 C3	Road Traffic Accident
F	12	43	L	Mid shaft	Simple - Transverse	32 A3	Direct Trauma
M	11	37	R	Mid shaft	Simple - Spiral	32 A1	Direct Trauma

Table 1: Characteristics of the patients, mechanism of injury and classification of the fractures

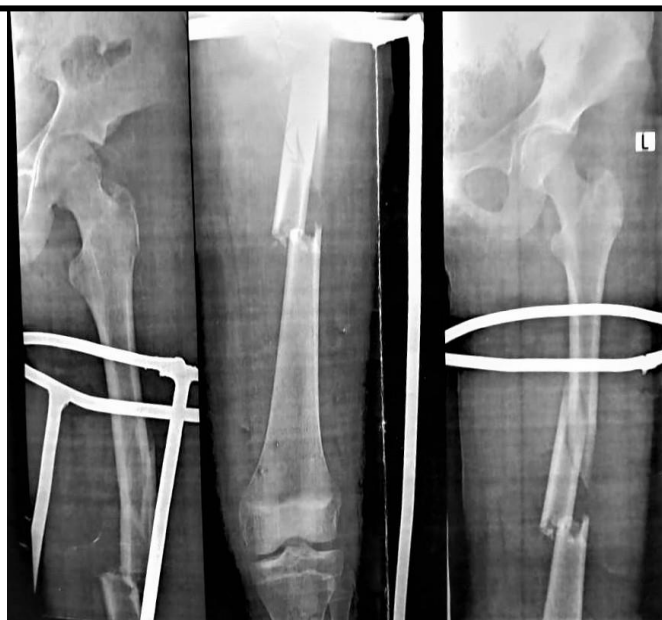

Fig. 1-a): Female,13 years old, had a road traffic accident (auto vs pedestrian), resulted in closed midshaft multifragmented fracture femur (32 C2).

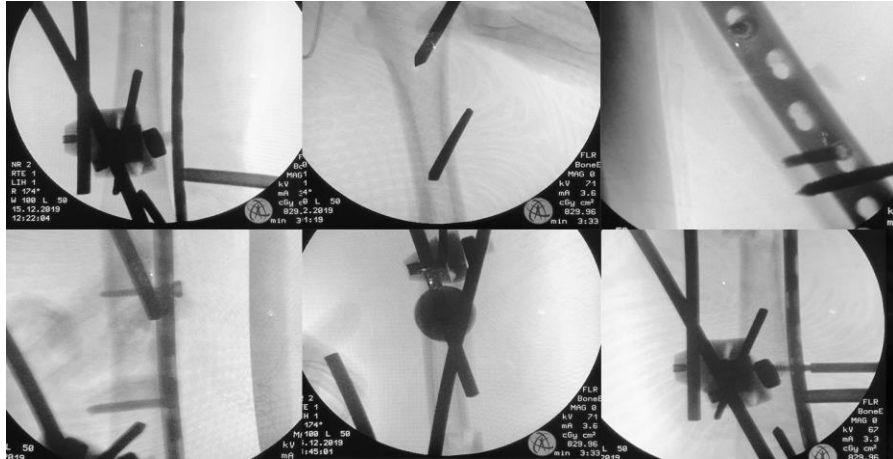


Fig. 1-b): Intraoperative fluoroscopy pictures of the reduction and fixation

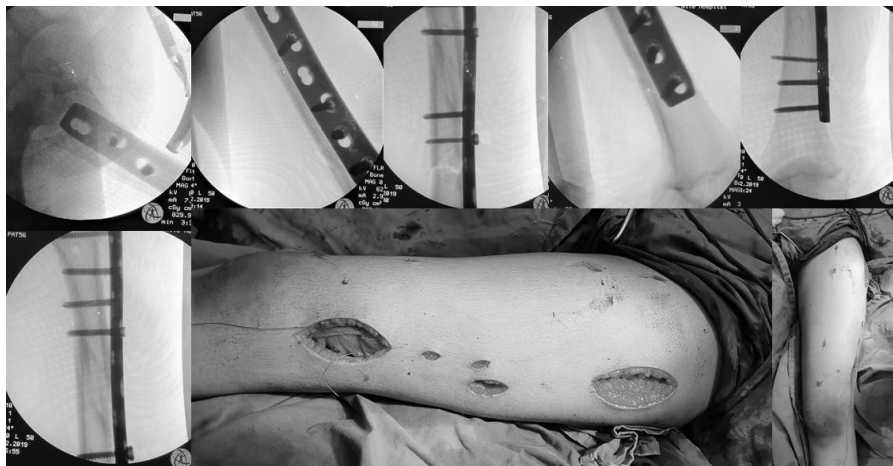

Fig. 1-c): Intraoperative fluoroscopy pictures of the reduction and fixation.

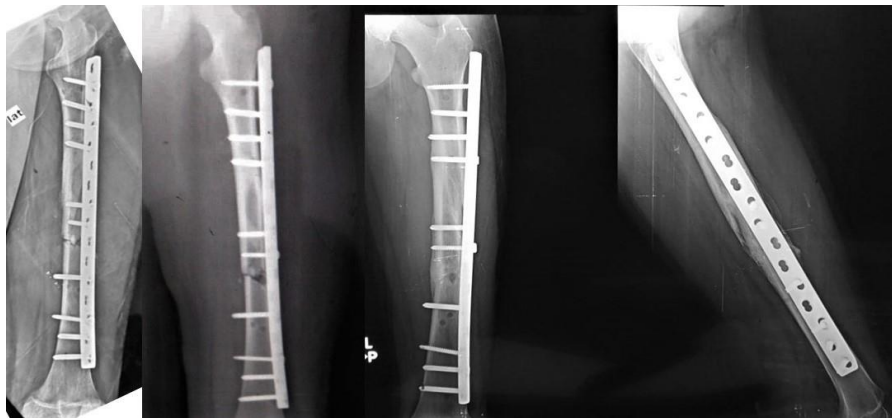


Fig. 1-d): (Left) postoperative x-rays, (Right) at final review five months postoperatively.

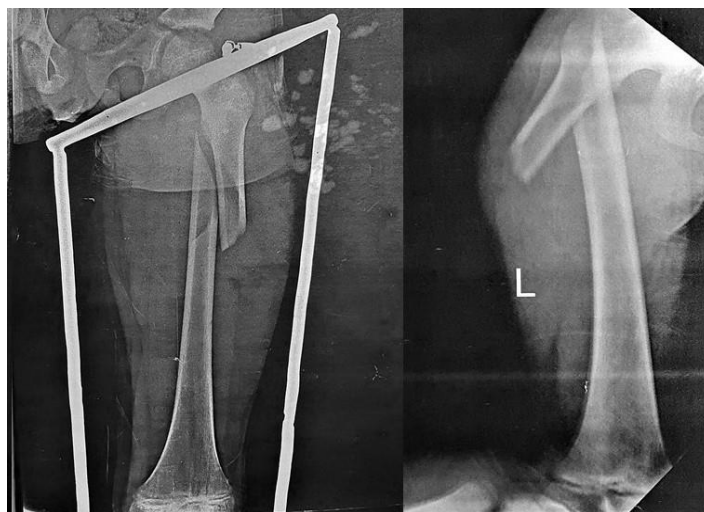

Fig. 2-a) Boy, 13 years old, had injury from a falling object, resulted in a spiral fracture proximal third femur (32 A1)

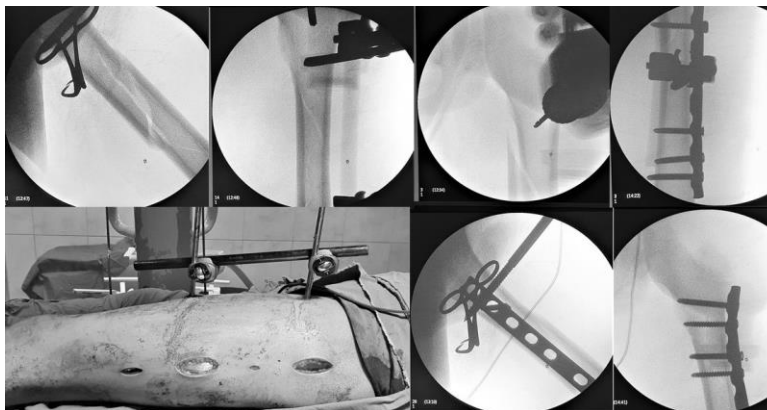


Fig. 2-b) Intraoperative fluoroscopy pictures of the reduction and fixation.

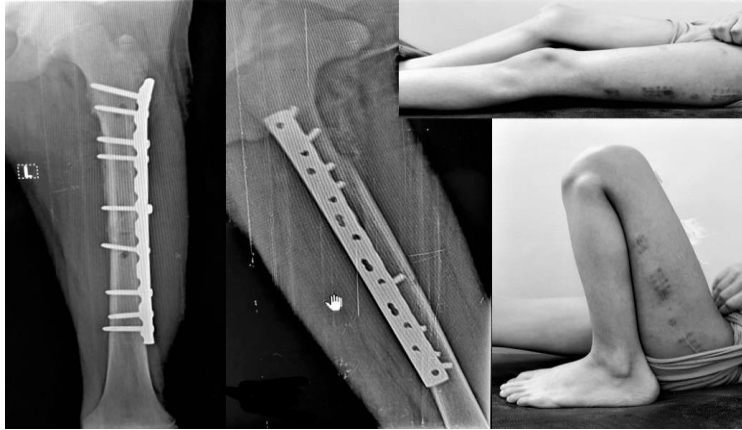

Fig. 2-c) Knee range of motion and radiological signs of union at six weeks postoperatively.

Discussion

The introduction of a plate in a sub muscular fashion represents an atraumatic method to stabilise a femoral shaft fracture. Whilst the external fixator-assisted technique has been used in conjunction with corrective osteotomies in deformity surgery, it is not used for acute fractures. (19 & 20). The advantages of this novel technique are several:

1. it avoids the use of a traction table, which takes time in setting up, patient positioning, and adjustment to gain fracture reduction.
2. it allows greater control over fracture reduction and prevents excessive use of traction and over-distraction of the

fracture segments which may lead to delays in union.

3. the sagittal application of pins and the fixator permit full access for the femur's lateral sub muscular plating (SMP).

A standard trauma fixator with poly-axial clamps was used (21, 22). Similar principles have been applied in studies in fracture fixation of tibial fractures in adults (23, 24). Femoral distractors have also been used to achieve traction for fracture reduction but, in comparison, there is less accurate control or the ability to ensure contact between the fracture fragments.

Joystick reduction techniques to facilitate intramedullary nail (locked and flexible) insertion have been reported for adult and

children's fractures (25, 26). A particular device was described to aid fracture reduction and facilitates FIN application in one study (27). An external fixator was used to facilitate the open reduction and internal fixation by plate of three supracondylar femoral fractures (28). However, the use of an external fixator as a fracture reduction and fracture control tool for minimally invasive plate osteosynthesis of fractures of the femoral shaft has not been reported previously.

Controversy remains over the optimum treatment method for femoral shaft fractures in children from the age of 6 to 16 years. Both AAOS and NICE guidelines (6, 7) do not favour one method over the other and consider FIN, trochanteric entry rigid nails or sub muscular plates as acceptable techniques in children above 11 years old. Both advocate use of FIN in younger children, provided the weight is less than 50kg. The fracture pattern and maintenance of length have not been commented upon specifically in these guidelines, both of which influence stability achieved after reduction and fixation.

The outcomes of using FIN in femoral and tibial fractures in children weighing more than 50 kg were investigated (29). The

authors concluded that length-unstable fracture patterns, older children and higher weight represented risk factors for poor outcomes. A recent meta-analysis compared the outcomes of flexible intramedullary nailing versus external fixation in paediatric femoral shaft fractures for the ages of 3 to 15 years (30). In this meta-analysis, external fixation had an increased overall complication rate; external fixation had a unique problem of pin site infections, while FIN had soft tissue irritation issues. Consequently, external fixators are reserved for complex open injuries and polytrauma patients (4 & 5).

Comparisons of FIN to plating (8-10) have shown that FIN produces less blood loss, takes less time to carry out, and incurs a shorter hospital stay than sub muscular plating in the age group 5 to 11 years old. A detailed appraisal of these studies indicates that in one study (10), they compared 50 FIN to 15 plates (5 open platings and 10 SMP), and there were only 14 length-unstable fractures in the FIN group, whereas half of the plated were length unstable.

In the second study, authors (9) compared 28 FIN to 30 SMP with unevenly distributed fracture patterns. In those fractures treated by FIN, the majority were transverse

patterns, while the SMP group had the majority of comminuted fractures. In the third one (8), they compared 29 patients treated by FIN to 22 open platings (LCP); there were comminuted fractures in 38% of the FIN group compared to 55% of the LCP group. These three studies, often quoted to support the continued dominance of FIN in treating femoral shaft fractures, have to be interpreted with caution.

Two recent studies have advocated the advantages of sub muscular plating (13 & 14). Treatment methods were compared in 198 children older than eight years; 61 patients were treated by FIN, 102 by intramedullary locked nails (ILN), and 35 by SMP. The study highlights the statistical correlation between the fracture pattern and the treatment type. Transverse fractures represented 67% of those in the FIN group, 48% of the rigid ILN group and only 9% of the SMP group. This reinforces the tendency to use SMP in length-unstable fracture patterns. In this study, the authors reported a higher mal union and hardware irritation issue with FIN, more limping and heterotopic ossification with rigid ILN and faster healing and weight-bearing with SMP (13).

Another second study compared 28 patients, of which fourteen were treated by FIN and another fourteen by SMP at the mean ages of 9.7 and 7.7 years, respectively. The authors reported that the SMP group had a shorter stay, earlier radiological union, decreased need for postoperative analgesia and a tendency for overall better outcomes than those in the FIN group. There were six open reductions in the FIN group and 11 open reductions in the SMP group; this may reflect the complex fracture patterns involved but was not reported clearly in the study (14).

This case series had a mean operative time of 122 minutes, shorter than one report (150 min) (10) and comparable to three other studies (94, 104 & 114 minutes) (8, 9 & 31). This series represented the first cohort for the treating surgeon, and the earlier cases represented experience at the start of the learning curve. This was borne out as there was a trend towards shorter operating times in the later cases.

Two studies estimated blood loss in the procedures (9 & 10). There was more estimated blood loss with plates than those treated by FIN. Another study (14) reported the need for transfusion in two of 14 patients treated in the SMP group compared to one

of 14 in the FIN group. There was no need for blood transfusion in any patient in our study.

Hospital stay (Length of stay, LOS) is another variable that has been investigated. Two studies reported shorter LOS with SMP (3.5 days and 6.3 days) than FIN (3.7 days and 7.8 days), respectively (10, 14). In contrast, one study reported shorter LOS with FIN (1 day compared to 2 days in the SMP group) (9). We had a mean LOS of 1.8 days which is comparable to the literature.

Postoperative pain and the need for analgesia were reported in a few studies. It was (14) reported less postoperative pain in the SMP group than FIN, (14) whereas others (10) did not find any statistical difference between SMP and FIN groups in their postoperative visual analogue scores (VAS). We found that patients made a rapid recovery after the surgery, and there was no pain after a mean of 1.5 weeks.

Speed to fracture union may favour one technique over the other. Some studies have used functional outcome measures (9 & 10) without reporting fracture union times. In one study, authors reported a mean time to the union at 2.2 months, with no difference between SMP and FIN groups (8). A shorter time to union in SMP (6.2 weeks) compared

to FIN (8 weeks) was reported (13) reported. A similar outcome was reported before, where it was found more united fractures at 12 weeks in the SMP group than the FIN group. In our study, all fractures united at a mean of 9.5 weeks (14).

A particular focus on treating complex femoral fractures using SMP was analysed (16); authors studied the outcomes of using SMP in 60 patients at a mean age of 9 years old (4 to 15), where 67% were unstable fracture patterns. Apart from one deep infection following fixation of an open fracture and one bent 3.5 mm plate, there were no other major complications.

The most recent meta-analysis published in 2020 (32) analysed 23 randomised controlled trials that compared different paediatric femoral fracture fixation methods, including cast application, flexible intramedullary nails, plate fixation, and external fixation. In terms of joint stiffness, FIN had the best outcomes followed by plate fixation. There was no statistically significant difference in malunion between the two groups. Patients treated by FIN take less time to the union than plate fixation. There are several concerns over this meta-analysis. Firstly, it is clear that classic plating methods were grouped together with

modern sub muscular techniques as ‘plate fixation’. Both techniques are markedly different in terms of operative time, blood loss, subsequent scarring and joint stiffness, and time to fracture union. The mean age of the patients ranged from 3.7 to 10.4 years old, essentially those in the prepubertal stages, and is lower than those patients in whom femoral shaft fractures pose surgical challenges to stabilise. Many of the included studies also failed to separate the fracture patterns into inherently stable ones from those not. Femoral shaft fractures in older children, heavier than 50kg, and with unstable patterns are the real challenges to surgical treatment and the results of the meta-analysis are therefore not applicable to this group.

Limitations:

This is a case series and of retrospective design. The sample is small and extrapolation of the findings into the population would need to take this into account. Other aspects of clinical relevance were also not recorded and may be important. This includes the fluoroscopy time, the estimated blood loss or functional scores postoperatively. This is part of an ongoing prospective observational study.

Conclusion:

External fixator-assisted internal fixation of paediatric femoral fractures would facilitate the accuracy and control of fracture reduction and allow plate application to be performed in the manner of minimally invasive percutaneous osteosynthesis. It has significant advantages over using a traction table or femoral distractor in surgery. Our study has shown a decrease in overall operative time and an accompanying reduction in length of inpatient stay, prolonged need for analgesia and postoperative rehabilitation. Used in conjunction with the sub muscular plating technique, it is a viable solution for older and heavier children with femoral fractures that have unstable complex patterns.

References:

1. Hunter JB. Femoral shaft fractures in children. *Injury*. 2005;36 Suppl 1:A86-93.
2. Agarwal-Harding KJ, Meara JG, Greenberg SL, Hagander LE, Zurakowski D, Dyer GS. Estimating the global incidence of femoral fracture from road traffic collisions: a literature review. *The Journal of bone and joint surgery American volume*. 2015;97(6):e31.
3. Loder RT, O'Donnell PW, Feinberg JR. Epidemiology and mechanisms of femur fractures in children. *Journal of pediatric orthopedics*. 2006;26(5):561-6.
4. Brousil J, Hunter JB. Femoral fractures in children. *Curr Opin Pediatr*. 2013;25(1):52-7.
5. Jain A, Aggarwal A, Gulati D, Singh MP. Controversies in orthopaedic trauma--management of fractures of shaft of femur in

- children between 6 and 12 years of age. Kathmandu University medical journal (KUMJ). 2014;12(45):77-84.
6. NICE. Limb and joint fractures in hospital [Pathways]. UK: National Institute for Health and Care Excellence; 2019 [updated 29/08/201901/07/2020]. 1-22]. Available from: <http://pathways.nice.org.uk/pathways/trauma>.
 7. Jevsevar DS, Shea KG, Murray JN, Sevarino KS. AAOS Clinical Practice Guideline on the Treatment of Pediatric Diaphyseal Femur Fractures. *The Journal of the American Academy of Orthopaedic Surgeons*. 2015;23(12):e101.
 8. Luo Y, Wang L, Zhao LH, Wang YC, Chen MJ, Wang S, et al. Elastic Stable Titanium Flexible Intramedullary Nails Versus Plates in Treating Low Grade Comminuted Femur Shaft Fractures in Children. *Orthop Surg*. 2019;11(4):664-70.
 9. Chen LK, Sullivan BT, Sponseller PD. Submuscular plates versus flexible nails in preadolescent diaphyseal femur fractures. *J Child Orthop*. 2018;12(5):488-92.
 10. Allen JD, Murr K, Albitar F, Jacobs C, Moghadamian ES, Muchow R. Titanium Elastic Nailing has Superior Value to Plate Fixation of Midshaft Femur Fractures in Children 5 to 11 Years. *Journal of pediatric orthopedics*. 2018;38(3):e111-e7.
 11. Vasilescu DE, Cosma D. Elastic Stable Intramedullary Nailing for Fractures in Children - Principles, Indications, Surgical Technique. *Clujul Med*. 2014;87(2):91-4.
 - Rozbruch SR. Fixator-Assisted Plating of Limb Deformities. *Operative Techniques in Orthopaedics*. 2011;21(2):174.
 20. Paley D, Herzenberg JE, Bor N. Fixator-Assisted Nailing of Femoral and Tibial Deformities. *Techniques in Orthopaedics*. 1997;12(4):260-75.
 21. Eidelman M, Keren Y, Norman D. Correction of distal femoral valgus deformities in adolescents and young adults using minimally invasive fixator-assisted locking plating (FALP). *Journal of pediatric orthopedics Part B*. 2012;21(6):558-62.
 22. Kovar FM, Jauregui JJ, Herzenberg JE. Accuracy of Distal Femoral Valgus Deformity Correction: Fixator-Assisted Nailing vs Fixator-Assisted
 23. Slongo T, Dwyer J. How to Optimise Elastic-Stable-Intramedullary-Nailing (ESIN) for the Treatment of Paediatric Femoral Fractures: What are the Options when the Method Reaches its Limits? *Trauma & Acute Care* 2016;1:16.
 13. Sutphen SA, Mendoza JD, Mundy AC, Yang JG, Beebe AC, Samora WP, 3rd, et al. Pediatric Diaphyseal Femur Fractures: Submuscular Plating Compared With Intramedullary Nailing. *Orthopedics*. 2016;39(6):353-8.
 14. Milligan D, Henderson L, Tucker A, Ballard J. Elastic nail fixation versus plate fixation of paediatric femoral fractures in school age patients - A retrospective observational study. *J Orthop*. 2020;19:153-7.
 15. Kanlic EM, Anglen JO, Smith DG, Morgan SJ, Pesantez RF. Advantages of submuscular bridge plating for complex pediatric femur fractures. *Clin Orthop Relat Res*. 2004(426):244-51.
 16. Abdelgawad AA, Sieg RN, Laughlin MD, Shunia J, Kanlic EM. Submuscular bridge plating for complex pediatric femur fractures is reliable. *Clin Orthop Relat Res*. 2013;471(9):2797-807.
 17. Sutphen SA, Beebe AC, Klingele KE. Bridge Plating Length-Unstable Pediatric Femoral Shaft Fractures. *Journal of pediatric orthopedics*. 2016;36 Suppl 1:S29-34.
 18. Li Y, Hedequist DJ. Submuscular plating of pediatric femur fracture. *The Journal of the American Academy of Orthopaedic Surgeons*. 2012;20(9):596-603.
 19. Locked Plating. *American journal of orthopedics*. 2018;47(6).
 23. Nada AA, Romeih M, El-Rosasy M. Fixator-assisted Percutaneous Plate Fixation of Complex Diaphyseal Tibial Fractures. *Strategies Trauma Limb Reconstr*. 2019;14(1):25-8.
 24. Semenisty AA, Litvina Ea EA, Fedotova AG, Gwam C, Mironov AN. Fixator-assisted nailing of tibial fractures: New surgical technique and presentation of first 30 cases. *Injury*. 2019;50(2):515-20.
 25. Georgiadis GM, Burgar AM. Percutaneous skeletal joysticks for closed reduction of femoral shaft fractures during intramedullary nailing. *J Orthop Trauma*. 2001;15(8):570-1.

- . Liu F, Ju L, Tang K, Lou Y. The use of percutaneous joystick reduction and limited open reduction techniques in pediatric femoral shaft fractures: a study of 63 cases. *Journal of pediatric orthopedics Part B*. 2016;25(4):375-80.
27. Xu H, Yin W, Hsu P, Qin H, An Z, Zhang C, et al. Improve the Efficiency of Surgery for Femoral Shaft Fractures with A Novel Instrument: A Randomized Controlled Trial. *PLoS One*. 2016;11(4):e0154332.
28. Bor N, Rozen N, Dujovny E, Rubin G. Fixator-Assisted Plating in Pediatric Supracondylar Femur Fractures. *Glob Pediatr Health [Internet]*. 2019 2019; 6:[2333794X19843922 p.]. Available from: <https://doi.org/10.1177/2333794X19843922>
29. Andreacchio A, Alberghina F, Marengo L, Canavese F. Pediatric tibia and femur fractures in patients weighing more than 50 kg (110 lb): mini-review on current treatment options and outcome. *Musculoskelet Surg*. 2019;103(1):23-30.
30. Guo YC, Feng GM, Xing GW, Yin JN, Xia B, Dong YZ, et al. A meta-analysis of flexible intramedullary nailing versus external fixation for pediatric femoral shaft fractures. *Journal of pediatric orthopedics Part B*. 2016;25(5):466-70.
31. Park KC, Oh CW, Byun YS, Oh JK, Lee HJ, Park KH, et al. Intramedullary nailing versus submuscular plating in adolescent femoral fracture. *Injury*. 2012;43(6):870-5.
32. Chen Z, Han D, Wang Q, Li L. Four interventions for pediatric femoral shaft fractures: Network meta-analysis of randomised trials. *Int J Surg*. 2020;80:53-60.
29. Andreacchio A, Alberghina F, Marengo L, Canavese F. Pediatric tibia and femur fractures in

To cite this article: Ahmed A. Elsheikh, Ahmed E. Elsayed, Wael A. Kandel, Selvadurai Nayagam. Fixator Assisted Internal Fixation of Paediatric Femoral Fractures. *BMFJ* 2023;40(surgical issue):157-172