

A Prospective Comparative Study of ALA Repair between Modified Tajima Suture and Cinch Suture in Unilateral Cleft Lip Patients

MOHAMMED K. IBRAHIM, M.B.B.Ch.; MOHAMED M. ABDEL HALIM, M.D.;
AHMED M. ABDELSALAM, M.D. and AMR A.R. MABROUK, M.D.

The Department of Plastic Surgery, Faculty of Medicine, Ain Shams University

ABSTRACT

Background: Despite previous concerns of growth disturbances, primary correction of the cleft nose deformity is an internationally accepted and approved concept. In the evolution of cleft lip and nose deformity surgery, a move from a protocol without primary nasal reconstruction to a second one, but the patients had to have secondary nasal reconstruction in the growing period due to insufficient primary repair.

Aim of the Work: The aim of this work is to assess Cinch suture as technique for ALA repair in unilateral cleft lip regarding aesthetic outcome in comparison with modified Tajima suture.

Patients and Methods: Prospective comparative study that was conducted on 20 children at Ain Shams University Hospitals throughout 6 months to assess Cinch suture.

Results: From the results presented of the comparison between Cinch group and Tajima group regarding post-operative assessment of the studied patients, there was no statistically significant difference found between Cinch and Tajima regarding assessment of the studied patients except patients with straight on the philtral border was found with higher percentage in Cinch than Tajima with p -value=0.010. In further comparison between Cinch and Tajima regarding nose results among the patients, there was statistically significant difference found between Cinch and Tajima regarding hypoplastic flattened ALA, excessive wrapping of ALA, Narrow sil, large sill and defect of upper rim with p -value=0.010, 0.001, 0.003, 0.025 and 0.010 respectively while no statistically significant difference found between both groups regarding septal deviation, insufficient wrapping of ALA, columellar base too wide, low position and high position. In addition, the relation between Mortier score post-operative and the other studied parameters in Tajima, there was no statistically significant relation found between Mortier score post-operative and the other studied parameters in Cinch except only relation with patients with straight on the philtral border with p -value =0.006. Finally, in relation between Mortier score post-operative and the other studied parameters in Cinch, there was no statistically significant relation found between Mortier score post-operative and the other studied parameters in Cinch except only relation with patients with low position with p -value=0.003.

Correspondence to: Dr. Muhammed Khaled Ibrahim Muhammed
E-Mail: prof.memo.doc@gmail.com

Key Words: ALA Repair – Tajima Suture – Cinch Suture – Unilateral Cleft LIP Patients.

Disclosure: The author confirms that there was no conflict of interest and that no financial support was obtained from anybody.

The study was approved by the Ethical Committee of Ain Shams University.

INTRODUCTION

The second most common congenital birth defect in the world is the Cleft lip and palate [1]. The incidence of oral clefts in any form occurs in about one in every 700 live births. Cleft lip is consistently more common in males at a 2:1 ratio, in contrast to cleft palate which has a similar ratio in favor of females [2].

Embryologic development of lip begins at 4th week of gestation to 7th week. Any disruption of the process of normal development can cause deformity of various severity and types. The severity is evaluated by the timing, degree and disruption [3].

Cleft lip is an immediately recognizable disruption of normal facial structure [4]. Beside the facial features, patients with cleft lip have serious functional problems with suckling and speaking [5]. It also has important psychological and socio-economic effects on patient's quality of life and requires a multidisciplinary team approach to be managed well [6].

Cleft lip can be classified into microform, a notch or groove in the soft tissues of the lip, and incomplete, dehiscence of the orbicularis oris with variable involvement of the skin, or complete cleft extend through the length of the lip and into the nasal sill, leading to abnormal insertion of the orbicularis oris onto the ALA of nose and columella [3].

Surgical repair of the cleft lip is preferred to be done at the first two to three month after birth [7]. Tennison repair is preferred for achieving aim. The aim of repair is recreation of a continuous lip, maintaining symmetrical cupid's bow and ALA, placing scars in hidden areas. Also, it is necessary for the permanent cosmetic outcome and function of the lip and mouth that the oral cavity opening is completely surrounded by a good reformed orbicularis muscle [8].

The Tajima method for clefted rhinoplasty was initially done for its usage in secondary repairs by utilizing an opposite U incision to reach and dissect all of the lower 66% of the nose. It is important to decrease flaring by reducing nasal width by the suspension of the lower lateral cartilage from the ipsilateral and contralateral upper lateral cartilage [9].

Millard invented an alar cinch procedure for the maintenance of the flaring nose requiring external entry in the nasal base. The procedure was invented by Collins and Epker, was done to make repairs of flaring of the alar base secondary to maxillary procedures. It does through stitching the fibro areolar tissue of the both alar bases across the midline utilizing a non-absorbable stitch embedded through the vestibular mucosa. This strategy uncovered a quick decrease in flaring of nose, The method utilized in our review was to reposition of lower lateral cartilage and fix transverse nasalis muscle [10,11].

Here we compare Modified Tajima suture with Cinch suture that aims to provide a better aesthetic outcome of alar flare and nostril width.

Aim of the work:

The aim of this work is to assess Cinch suture as technique for management of ALA repair in unilateral cleft lip regarding aesthetic outcome in comparison with repair of cleft lip by modified Tajima suture.

PATIENTS AND METHODS

This was a prospective comparative study that was conducted on 20 children at Ain Shams University Hospitals throughout 6 months to assess symmetry of two nostril opening after repair by Cinch suture.

The included patients (20) were divided into 2 groups:

Group A (Control group): 10 patients repaired by usual Tennison technique combined with mod-

ified Tajima suture. Group B: 10 patients repaired by usual Tennison technique combined with Cinch suture.

Ethical consideration: Oral and written consent were obtained from all the participants and the Ethical Committee approved the study.

Inclusion criteria: Children with unilateral cleft lip (only complete degree), all patient from 3 months to 6 years old, isolated unilateral cleft lip and compound cleft lip and palate.

Exclusion criteria: Children with bilateral cleft lip, patient older than 6 years and lip redo and children with craniofacial anomalies.

Methods: All patients included in the study was:

Pre-operative assessment: Careful history taking and general condition assessment.

Investigations: Routine preoperative investigations and echo for associated congenital heart anomalies.

Post-operative assessment: All patients were followed up clinically for 6 months and the results were evaluated after 6 months. The aesthetic evaluation was adopted rating scale of mortier.

This rating framework depends on the guideline of giving focuses to every component describing both cleft and nasal deformity. The all amounts of points showed the degree of rectification of disfigurements. The more troublesome adjustment of the optional distortion of congenital fissure or nose, the higher complete score is. The rating scale comprises of 2 unique gatherings of physical components of nasolabial triangle: Nose and dehiscence lip nose (Table 1) [12].

Surgical technique:

Tajima suture:

1- A conventional tip was used to treat the one-sided congenital cleft. The horizontal lips module's entrance site lies above the inferior turbinate on the inside of the nose. This allows medicalization of lower lateral cartilage on the clefted side by separating the anteriorly basis from the piriform aperture hole.

2- The nose is inserted through U-shaped incisions on the other side. The slightly bent incision was split off at the junction of the lateral part and septal initially, and the alar foundation was moved vertically to fix the shape of the non-cleft edge.

3- At the junction of the medial and central crura, this was advanced superiorly to or beyond















the anteriorly margin. The cut then turns ventrally and enters the nose once more, finishing at the interior webbing of the nasal ALA. The entry was able to subvert via the lowest 66% of the nose, over the top and bottom lateral septum on the clefted edge.

4- Dissection blades were used to release the ALA subcutaneous above the pericardium. The suspending thread might be used to realign the cartilages and enable the skin to re-drop over them once the skin membrane has been totally mobilized from the cartilage underneath.

5- Curved 25-check needles were used to construct this stitching, which was passed through the skin and anterolateral septum of the regular side before descending down and toward the clefted half. The needle was compressed, the septal was ignored anterior part, and it was repositioned ob-

liquely along the edge, penetrating the poster lateral septum of the deformity's clefted edge. At the level of alar vaults, the poster lateral ligament was pierced.

6- A 4-O polydioxanone (PDS) suture was placed through the orifice towards to the nasal dorsal aspect at the position where the syringe could be seen through the inwards nasal coverings. At every side, the thread was grasped, and the needles were pulled from the nose. When the slanted head is visible on the lateral skin, the extraction is halted, the needles are distorted 180 degrees, and the syringe is inserted through the nose in the same position as before. The twisting motion creates a stitching circular that runs across both laterally cartilages. This is also how a covered, horizontal mattress is finished by being maneuvered into the nose and linked to the next stitching end.

Nose (N)	Nd	Deviation of the septum		2	
	Ns+	Large sill		0.5	
	Ns-	Narrow sill		0.5	
	Nb+ Nb-		Columellar base too wide		0.5
			Columellar base too narrow		0.5
	Na-	Insufficient wrapping of ala		0.5	
	Na+	Excessive wrapping of ala		0.5	
	N^	Defect of upper part of nostril rim		0.5	
	Na!	High position of ala		0.5	
	NaI	Low position of ala		0.5	
	Nah	Flat and hypoplastic ala		3	
	Dehiscence lipnose	Nf	Nasolabial fistula		2
		Lrd	Dehiscence of vermillion		2
LDT		Total dehiscence of the lip		10	

Cinch suture:

- 1- An 18-gauge needle is inserted through the skin of non-clefted sided and exits at the fibro areolar tissue. A 3/0 nonabsorbable suture without a needle is inserted through the needle from the oral cavity to outside.
- 2- The needle is retracted through the skin point without leaving it and then returned to the oral cavity again in a medial position.
- 3- Finally, the needle is retracted from the skin leaving the suture through the soft tissues.
- 4- The same procedure is done through the skin point at the other side of the nose of ALA of clefted side. The 2 free ends of the sutures are then passed through gap and knot were made before repair of nasal floor.

RESULTS

The previous table shows that there was no statistically significant difference found between Cinch group and Tajima group regarding assessment of the studied patients except patients with straight on the philtral border was found with higher percentage in Cinch group than Tajima group with p -value=0.010.

The previous table shows that there was statistically significant difference found between Cinch group and Tajima group regarding hypoplastic flattened ALA, excessive wrapping of ALA, Narrow sil, large sill and defect of upper rim with p -value =0.010, 0.001, 0.003, 0.025 and 0.010 respectively while no statistically significant difference found between both groups regarding septal deviation, insufficient warping of ALA, columellar base too wide, low position and high position.

The previous table shows that there was statistically significant difference found between Cinch group and Tajima group regarding preoperative and postoperative Mortier score with p -value= 0.029 and <0.001 respectively.

Table (2): Nose (N) results among the studied patients.

Nose	No.	%
<i>Hypo plastic flattened ala:</i>		
No	5	25.0
Yes	15	75.0
<i>Septal deviation:</i>		
No	10	50.0
Yes	10	50.0
<i>Excessive wrapping of ala:</i>		
No	13	65.0
Yes	7	35.0
<i>Insufficient warping of ala:</i>		
No	18	90.0
Yes	2	10.0
<i>Narrow sil:</i>		
No	14	70.0
Yes	6	30.0
<i>Large sil:</i>		
No	16	80.0
Yes	4	20.0
<i>Columellar base too wide (Nb+):</i>		
No	18	90.0
Yes	2	10.0
<i>Columellar base too narrow (Nb-):</i>		
No	20	100.0
Yes	0	0.0
<i>Defect of upper rim:</i>		
No	15	75.0
Yes	5	25.0
<i>Low position:</i>		
No	17	85.0
Yes	3	15.0
<i>High position:</i>		
No	18	90.0
Yes	2	10.0

Table (3): Follow-up of Mortier score pre-operative and post-operative among the studied patients.

	Pre-operative No.=10	Post-operative No.=10	Test value	p - value	Sig.
Median (IQR)	8 (8-8)	2 (0-3.75)	-3.948	0.000	HS
Range	7-8	0-5			

p -value >0.05: Non significant (NS).
 p -value <0.05: Significant (S).
 p -value <0.01: Highly significant (HS).
 ‡: Wilcoxon Rank test.

Table (4): Comparison between Cinch group & Tajima group regarding assessment of the studied patients.

	Cinch group		Tajima group		Test value*	p-value	Sig.
	No.	%	No.	%			
<i>Septal deviation:</i>							
Positive	10	100.0	10	100.0	NA	NA	NA
<i>Alar deviation:</i>							
Positive	10	100.0	10	100.0	NA	NA	NA
<i>Dislocation of lateral crus:</i>							
Positive	10	100.0	10	100.0	NA	NA	NA
<i>Short columella:</i>							
Positive	10	100.0	10	100.0	NA	NA	NA
<i>Straight on the philtral border (LsO):</i>							
No	0	0.0	5	50.0	6.667	0.010	S
Yes	10	100.0	5	50.0			
<i>Straight, depressed (Ls-1):</i>							
No	10	100.0	8	80.0	2.222	0.136	NS
Yes	0	0.0	2	20.0			
<i>Straight, prominent (Ls+1):</i>							
No	10	100.0	7	70.0	3.529	0.060	NS
Yes	0	0.0	3	30.0			
<i>Early complication:</i>							
Non-complicated	10	100.0	8	80.0	2.222	0.136	NS
Disruption	0	0.0	2	20.0			
<i>Scar post operative:</i>							
Triangular flap of bad quality	3	30.0	3	30.0	0.000	1.000	NS
Triangular flap of good quality	7	70.0	7	70.0			
<i>Dehiscence:</i>							
No	10	100.0	10	100.0	NA	NA	NA
Yes	0	0.0	0	0.0			

p-value >0.05: Non significant (NS). p-value <0.05: Significant (S). p-value <0.01: Highly significant (HS).
*: Chi-square test.

Table (5): Comparison between Cinch group and Tajima group regarding nose (N) results among the studied patients.

Nose	Cinch group		Tajima group		Test value*	p-value	Sig.
	No.	%	No.	%			
<i>Hypoplastic flattened ala:</i>							
No	5	50.0	0	0.0	6.667	0.010	S
Yes	5	50.0	10	100.0			
<i>Septal deviation:</i>							
No	7	70.0	3	30.0	3.200	0.074	NS
Yes	3	30.0	7	70.0			
<i>Excessive wrapping of ala:</i>							
No	3	30.0	10	100.0	10.769	0.001	HS
Yes	7	70.0	0	0.0			
<i>Insufficient warping of ala:</i>							
No	10	100.0	8	80.0	2.222	0.136	NS
Yes	0	0.0	2	20.0			
<i>Narrow sil:</i>							
No	4	40.0	10	100.0	8.571	0.003	HS
Yes	6	60.0	0	0.0			
<i>Large sill (Ns+):</i>							
No	10	100.0	6	60.0	5.000	0.025	S
Yes	0	0.0	4	40.0			
<i>Columellar base too wide (Nb+):</i>							
No	10	100.0	8	80.0	2.222	0.136	NS
Yes	0	0.0	2	20.0			
<i>Columellar base too narrow (Nb-):</i>							
No	10	100.0	10	100.0	NA	NA	NA
Yes	0	0.0	0	0.0			
<i>Defect of upper rim:</i>							
No	10	100.0	5	50.0	6.667	0.010	S
Yes	0	0.0	5	50.0			
<i>Low position:</i>							
No	7	70.0	10	100.0	3.529	0.060	NS
Yes	3	30.0	0	0.0			
<i>High position:</i>							
No	10	100.0	8	80.0	2.222	0.136	NS
Yes	0	0.0	2	20.0			

p-value >0.05: Non significant (NS). p-value <0.05: Significant (S). p-value <0.01: Highly significant (HS).
*: Chi-square test.

Table (6): Comparison between Cinch and Tajima regarding Mortier score pre-operative and post-operative.

Mortier score	Cinch group No.=10	Tajima group No.=10	Test value	p- value	Sig.
<i>Pre-operative:</i>					
Median (IQR)	8 (7-8)	8 (8-8)	-2.179‡	0.029	S
Range	7-8	8-8			
Severe	10 (100.0%)	10 (100.0%)	NA	NA	NA
<i>Post-operative:</i>					
Median (IQR)	0 (0-1.5)	3.75 (2.5-5)	-3.891	0.000	HS
Range	0-1.5	2.5-5			
Good	0 (0.0%)	5 (50.0%)	20.000	0.000	HS
Very good	0 (0.0%)	5 (50.0%)			
Excellent	10 (100.0%)	0 (0.0%)			
Wilcoxon Rank test p-value	-2.877 0.004 (HS)	-2.831 0.005 (HS)	**	**	**

p-value >0.05: Non significant (NS). p-value <0.05: Significant (S). p-value <0.01: Highly significant (HS).
*:Chi-square test. ‡: Mann Whitney test.

Results Post-operative photos:

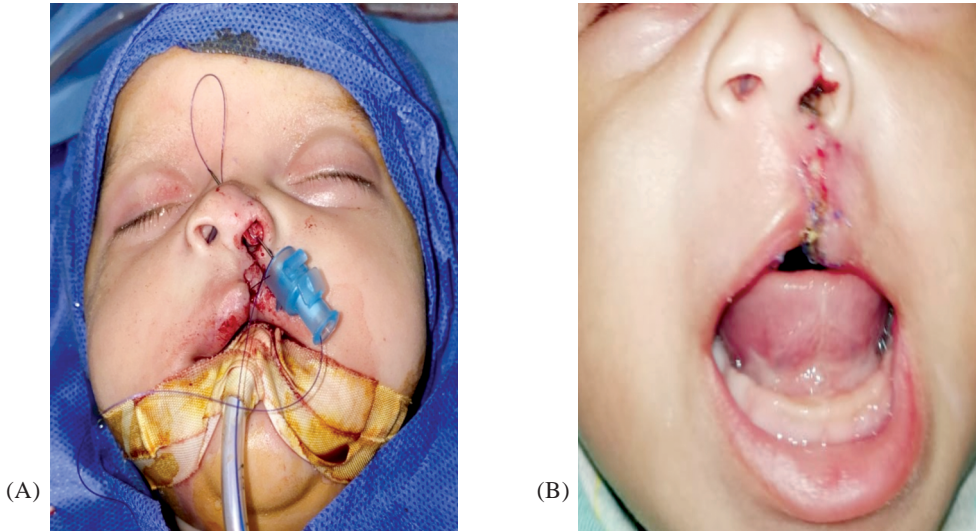


Fig. (1): (A): Show Tajima suture in left sided cleft lip patient through inverted u incision after undermining lower lateral cartilage, hanged over contralateral side, (B): Shows post operative repair of left cleft lip with Tajima suture with notch over dome, incomplete wrapping of ALA and flat ALA.

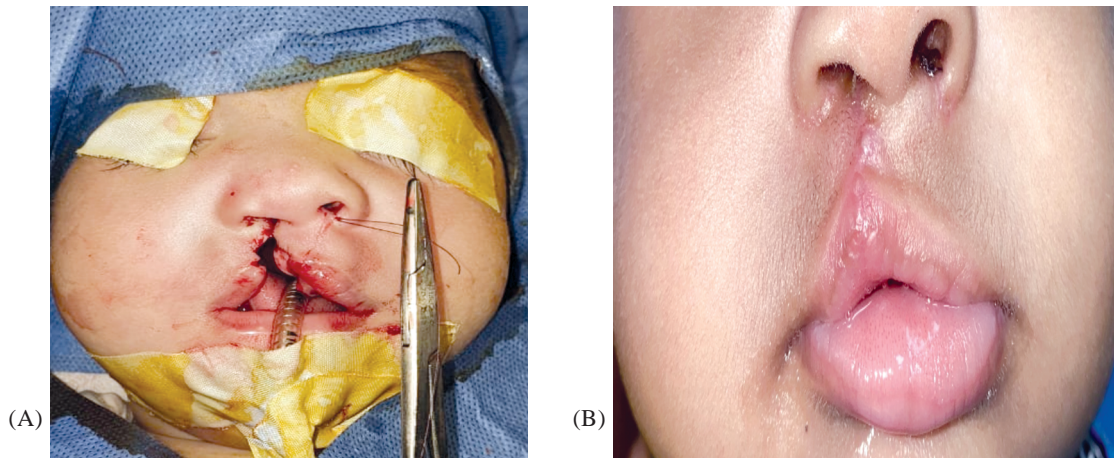


Fig. (2): (A): Shows repair of right sided cleft lip with cinch suture through Cinch suture, (B): Shows post-operative result after one month with no deviated septum or attenuated cartilage.

DISCUSSION

A cleft lip is the most predominant facial congenital defect with a low morbidity and mortality rate. It has serious effects on the patient's appearance and functions (sucking, speech, breathing, etc.). Furthermore, it causes an effect on facial growth of the new-born. Surgical repair of the oral cleft is fundamental to improve physiologic functions, aesthetics, and to establish social and psychological health in children with orofacial clefts [13].

Nowadays, multidisciplinary teamwork is considered as a recent route in the treatment of orofacial clefts to improve therapeutic outcomes. Over several years, many surgical techniques have been developed to normalized patient's aesthetics and functions. Despite cleft lip types (unilateral or bilateral cleft) and severity (mini/microform, incomplete/complete); different surgical techniques and modifications were developed to repair this defect [14].

All of these techniques were based on 3 principal ideas: Straight-line, rotation-advancement, geometric. There is a special concern about micro\mini-form unilateral cleft lip with little nasal asymmetry; where some surgeons preferred to use a double Z-plasty method to repair this type of cleft [15].

The primary goals of oral cleft treatment include: Closing of lip defect, reconstructing Orbicularis oris muscle with the establishment of muscle continuity, reconstructing aesthetic lip components (e.g. median tubercle, cupid's bow, white roll, lip height vertical/horizontal, vermilion volume beneath the cleft), creating a philtral ridge which mimics the non-cleft philtral ridge, developing the labial sulcus, correcting nasal asymmetry, closing the nasal floor, repositioning alar rim, elongating shorted columella, creating a Medline positioned columellar base, and finally improving psychosocial development [16].

The unrepaired or badly repaired orofacial cleft has serious social and psychological implications as it may cause social stigma and prevent the cleft-holder from good integration into society. Therefore, comparative studies about surgical techniques for cleft lip repair provide more evidence on advantages, disadvantages, and limitations of these techniques. Moreover, these researches suggest awareness and compare aesthetic outcomes of each technique [17].

The aim of this prospective comparative study was to assess Cinch suture as technique for management of ALA repair in unilateral cleft lip regarding aesthetic outcome in comparison with repair of cleft lip by modified Tajima suture.

In the present study; a total of 20 cleft children (aged between 4-11 months) participated in the study. They were 6 females (30.0%) and 14 males, in which most of the cases had complete left sided cleft.

It was found that both surgical techniques improve the nasolabial appearance by decreasing the nasal dimensions (total nasal width, cleft nostril width, and noncleft nostril width). The comparison between pre-operative and post-operative nasal cleft values showed a positive change in the values of nasal dimensions post-operatively.

A prospective study by Kuna et al. [18], compared the outcomes of Millard and Delaire functional method techniques and found that Millard incision has a better improvement of the lip length, whereas the Delaire method improved nasal symmetry.

In 2010; Reddy et al. [19] compared and evaluated nasolabial outcomes (The white roll, vermilion border, scar, Cupid's bow, lip length, nostril symmetry, and appearance of the alar dome and nasal base) between a rotation-advancement repair, Pfeifer wave line incision, and Afroze incision on 1200 patients; where they found that the labial improvement was better with Millard, whereas nasal symmetry was better with Pfeifer incision, and better labial and nasal results with Afroze incision (companion of Millard and Pfeifer) as it improves nasal symmetry, white roll approximation, vermilion repair, scar quality, lip length, and Cupid's bow symmetry by using Millard on medial lip side and Pfeifer on lateral lip side [20].

Besides, both Millard and Fisher are statistically significant in the increase and improvement of the lateral lip height with better results with Millard technique. Clinically, the lateral lip lengthening of the cleft side was better achieved by Millard's incision because of the use of "BACK CUT" which helps in more rotation of flap and overcome vertical lip shortness [18].

In 2017; Mbuyi-Musanazayi et al. [21] evaluated the surgical outcomes of 101 cases using the Fisher technique, the study showed that it increases the length of the medial and lateral lips with a fair scar.

In 2016, Funayama et al. [22] changed their cleft treatment protocol to use the Fisher technique instead of Millard, a scar improvement was found with the Fisher technique.

According to literature, Millard technique can be used in each cleft type with excellent results in micro-form and incomplete cleft. Millard's method increases lateral lip length and achieves white roll continuity with improvement in vermillion height if "BACK CUT" is used. Nasal asymmetry with Millard in severe complete cleft showed improvement, however a secondary rhinoplasty was needed [18].

The Fisher technique is based on precise measurements and equivalent dimensions of anatomical subunits preoperatively and intra operatively. For this reason, Fisher's postoperative nasolabial results are predictive in almost all cases [23].

The nasal dimensions (total nasal width, cleft nostril width, non-cleft nostril width) are improved with the Fisher method because it improves alar rim position and nostril width. Furthermore, it increases lateral lip height to produce an acceptable scar in an anatomical mirror to non-cleft philtral ridge [22].

In our study, when we compared between Cinch group and Tajima group regarding demographic data and characteristics of the studied patients, we found that there was no statistically significant difference found between Cinch group and Tajima group regarding age, sex and side while there was statistically significant difference found between both groups regarding palate.

This was in accordance with a study by Othman et al. [24], conducted a similar study of 3D analysis of facial morphology in Malaysia, comparing adult patients with repaired, non-syndromic, complete UCLP with a control group without clefts. They found that there was a significant difference in the intercanthal widths, whereby the intercanthal width was wider in the cleft group with a mean difference of 3.88mm, they have proposed 5mm as an appropriate threshold to indicate clinical relevance. Therefore, even though the difference in intercanthal width was statistically significant, it was deemed clinically irrelevant.

Ethnic Malay patients were used with older samples (18-25 years), and the quantitative values of measurements were assessed using proportion indices. Interestingly, it can be observed that UCLP adults of Malay ethnicity have a wider intercanthal dimension compared to UCLP children of Chinese

ethnic background. The discrepancy might be due to the difference in the age group, growth and ethnicity. The findings that UCLP patients have broader alar base width, wider alar base root width, flatter nose, and wider left nostril floor width are in keeping with several previous studies [25].

These concur with findings by Krimmel et al. [26], who reported that the highest degree of cleft deformity was seen in the horizontal dimensions of the nose.

In the comparison between Cinch group and Tajima group regarding assessment of the studied patients, we found that there was no statistically significant difference found between Cinch group and Tajima group regarding assessment of the studied patients except patients with straight on the philtral border was found with higher percentage in Cinch group than Tajima group.

This was in agreement with Chou et al. [27], that suggest that UCL patients have a lip tissue hypoplasia on the cleft side. Also, it has been suggested that cleft deformity reflects not only the varying extent of embryological failure, but is also the ultimate result of growth and development impairment.

Post-operative measurements of horizontal lip length, nostril width, vertical lip height, and philtral height on the cleft side showed marked improvements when compared to that of the non-cleft side. This indicates that surgical repair of a UCL is important and can provide hope to distressed parents and patients.

Our findings are consistent with those of Bilwatsch et al. [28] and Hakim et al. [29], who independently evaluated Millard's and Tennison-Randall techniques, respectively. Hakim et al., performed postoperative digital anthropometry on 18 patients who received UCL repairs with rotation-advance-ment and they compared these to normal controls. They found that there were improvements in the lip and nasal measurements. Similarly, Bilwatsch et al. reported improvements after repair with the Tennison-Randall technique.

In the comparison between Cinch group and Tajima group regarding nose (N) results among the studied patients, we found that there was statistically significant difference found between Cinch group and Tajima group regarding hypoplastic flattened ALA, excessive wrapping of ALA, Narrow sill, large sill and defect of upper rim while no statistically significant difference found between both groups regarding eptal deviation, insufficient

warping of ALA, columellar base too wide, low position and high position.

Comparisons of horizontal lip length, nostril width, vertical lip height, Cupid's bow, and philtral height of the cleft side between patients and controls were not significantly different. This might suggest that the non-cleft side is a poor control for the repaired cleft side, possibly due to a compensatory hypertrophy on the non-cleft side. Symmetry of the cleft side with the control but not with the non-cleft side has been reported in other studies. Consequently, it is now being speculated that the non-cleft side may not be an appropriate control for the cleft side. Similar to our results, several authors reported that the uppermost muscular stitch has been sutured to the caudal area of the nasal septum, above the anterior nasal spine and for simultaneous correction of the cleft lip and nose deformity at the time of labial rearrangement, the combination techniques were used [29].

Similar to Fisher and Sommerlad [30], in complete unilateral cleft lip in the first stage of surgery, unilateral vomer and partial inferior turbinate flap were used for closure of the hard palate, alveolar ridge and nasal floor according to a previous study.

The muscle layers were identically dissected along the skin boarder and abnormal muscle insertion below the columella, alar base and nasal floor was adequately released as described by Raymond [31].

Chen et al., [32] reported muscle cuff to be completely released from the skin mucosa and lip border to be bilaterally through the alar base on the cleft side and midline philtrum on the non-cleft side which are in line with our findings.

To secure the repositioned lower lateral cartilages, mattress sutures have been used by Tajima in 1977, holding the lower laterals to the Triangular cartilages, as part of their described approach to secondary correction of the cleft nose.

Kernahan et al. [33] presented their results with same technique of Tajima, who then presented their long-term results of the original approach with some additions.

McComb used mattress sutures to reposition the nasal cartilages after undermining nasal skin, securing them externally as bolster sutures. Those mattress sutures depend on dermal resistance to maintain their traction, and need to be removed approximately in 5 days. They demonstrated the technique initially in the UCLND and later pre-

sented their long term follow-ups in both Unilateral and Bilateral clefts. Abdulrauf et al., [34].

Stenstrom et al., [35] beside the rim incisions, he added a small external incision on the dorsum in order to lift the affected alar cartilages and securing them to the septal cartilage with non-absorbable sutures.

In the Correlation of postoperative Mortier score with age of the studied patients in both studied groups, we found that there was statistically significant negative correlation found between postoperative Mortier score and age of the studied patients in Cinch group while no statistically significant correlation found between postoperative Mortier score and age of the studied patients in Tajima group.

This was in agreement with Chow et al., [36], who stated that surgical repair of cleft lip preferred to be done at the first two to three month after birth.

The goals of repair are recreation of lip continuity, establishing symmetry of the cupid's bow and the ALA in a manner that places scars in less discernable areas. Also, Recreation of the orbicularis muscle to circumferentially surround the opening of the oral cavity is important for long-lasting cosmetic outcomes and lip and mouth function [37].

Conclusion:

The alar cinch suture brought in a significant reduction in alar flare where superior reposition was done without any adjuvant procedure especially when the suture is passed through the anterior nasal spine. It is a simple procedure that minimizes the option of a second surgery.

Cinch suture as an adjuvant procedure does not eliminate post-operative alar flare completely because it does not address the other contributing factors like the loss of pyriform depth and septal resection, which needs further evaluation.

REFERENCES

- 1- Parker S.E., Mai C.T., Canfield M.A., Rickard R., Wang Y., Meyer R.E. and National Birth Defects Prevention Network: Updated national birth prevalence estimates for selected birth defects in the United States, 2004-2006. Birth Defects Research Part A: Clinical and Molecular Teratology, 88 (12): 1008-1016, 2010.
- 2- James W.H.: Are oral clefts a consequence of maternal hormone imbalance? Evidence from the sex ratios of sibs of probands. Teratology, 62 (5): 342-345, 2000.

- 3- Dixon M.J., Marazita M.L., Beaty T.H. and Murray J.C.: Cleft lip and palate: Understanding genetic and environmental influences. *Nat. Rev. Genet.*, 12 (3): 167-78, 2011.
- 4- Desmedt D.J., Maal T.J. and Kuijpers M.A.: Nasolabial symmetry and esthetics in cleft lip and palate: Analysis of 3D facial images. *Clin. Oral Investig.*, 19: 1833-1842, 2015.
- 5- Millard T. and Richman L.C.: Different cleft conditions, facial appearance, and speech: Relationship to psychological variables. *The Cleft palate-craniofacial journal*, 38 (1): 68-75, 2001.
- 6- Lithovius R.H., Lehtonen V., Autio T.J., Harila V., Anttonen V., Sándor G.K. and Ylikontiola L.P.: The association of cleft severity and cleft palate repair technique on hearing outcomes in children in northern Finland. *Journal of Cranio-Maxillofacial Surgery*, 43 (9): 1863-1867, 2015.
- 7- Chow I., Purnell C.A., Hanwright P.J., A.K. J.P. Gosain and R. Surgery: "Evaluating the rule of 10s in cleft lip repair: do data support dogma?" *138 (3): 670-679*, 2016.
- 8- Mossey P.A., Little J., Munger R.G., Dixon M.J. and W.C. J.T.L.: "Cleft lip and palate", 374 (9703): 1773-1785, 2009.
- 9- Tajima S.A.D.A.O. and Maruyama M.A.S.A.R.U.: Reverse-U incision for secondary repair of cleft lip nose. *Plastic and Reconstructive Surgery*, 60 (2): 256-261, 1977.
- 10- Millard D.R.: The alar cinch in the flat, flaring nose. *Plastic and Reconstructive Surgery*, 65 (5): 669-672, 1980.
- 11- Collins P.C. and Epker B.N.: The alar base cinch: A technique for prevention of alar base flaring secondary to maxillary surgery. *Oral Surgery, Oral Medicine, Oral Pathology*, 53 (6): 549-553, 1982.
- 12- Mortier P.B., Martinot V.L., Anastassov Y., Kulik J.F., Duhamel A. and Pellerin P.N.: Evaluation of the results of cleft lip and palate surgical treatment: Preliminary report. *The Cleft palate-craniofacial journal*, 34 (3): 247-255, 1997.
- 13- Allam E., Windsor L. and Stone C.: Cleft lip and palate: Etiology, epidemiology, preventive and intervention strategies. *Anat. Physiol.*, 4 (3): 1-6, 2014.
- 14- Ammar H., Elprince N.H., Khalil A.A.F. and Sweedan A.O.: Comparison of rotation-advancement and straight-line methods for repairing of unilateral cleft lip (a randomized controlled clinical trial). *Alexandria Dental Journal*, 2022.
- 15- Losee J.E., Kirschner R.E., Smith D.M., Straub A.E. and Lawrence C. (Eds.): *Comprehensive Cleft Care: Family Edition*. CRC Press/Taylor & Francis Group, 2015.
- 16- Jackson I., Michael L. Bentz, Bruce S. Bauer, Ronald M. Zuker (Eds): *Principles and practice of pediatric plastic surgery*, 2008.
- 17- Marc C.S. and David M.F.: Cleft lip. In: Ross Farhadieh, Neil Bulstrode, Sabrina Cugno (ed) *Plastic and Reconstructive Surgery: Approaches and Techniques*, 1st ed. Pondicherry, India Wiley Blackwell, 2015.
- 18- Kuna S.K., Srinath N., Naveen B.S. and Hasan K.: Comparison of outcome of modified Millard's incision and Delaire's functional method in primary repair of unilateral cleft lip: A prospective study. *Journal of maxillofacial and oral surgery*, 15 (2): 221-228, 2016.
- 19- Reddy S.G., Reddy R.R., Bronkhorst E.M., Prasad R., Jagtman A.M.K. and Bergé S.: Comparison of three incisions to repair complete unilateral cleft lip. *Plastic and Reconstructive Surgery*, 125 (4): 1208-1216, 2010.
- 20- Roussel L.O., Myers R.P. and Giroto J.A.: The Millard rotation-advancement cleft lip repair: 50 years of modification. *The Cleft Palate-Craniofacial Journal*, 52 (6): 188-195, 2015.
- 21- Mbuyi-Musanazayi S., Katombe F.T., Tshilobo P.L., Kayamba P.K.M., Devriendt K. and Reyckler H.: Anthropometric and aesthetic outcomes for the nasolabial region in 101 consecutive African children with unilateral cleft lip one year after repair using the anatomical subunit approximation technique. *International Journal of Oral and Maxillofacial Surgery*, 46 (10): 1338-1345, 2017.
- 22- Funayama E., Yamamoto Y., Furukawa H., Murao N., Shichinohe R., Hayashi T. and Oyama A.: A new primary cleft lip repair technique tailored for Asian patients that combines three surgical concepts: Comparison with rotation-advancement and straight-line methods. *Journal of Cranio-Maxillofacial Surgery*, 44 (1): 27-33, 2016.
- 23- Patel T.A. and Patel K.G.: Comparison of the Fisher anatomical subunit and modified Millard rotation-advancement cleft lip repairs. *Plastic and Reconstructive Surgery*, 144 (2): 238e-245e, 2019.
- 24- Othman S.A., Majawit L.P., Wan Hassan W.N., Wey M.C. and Mohd Razi R.: Anthropometric study of three-dimensional facial morphology in Malay adults. *PloS one*, 11 (10): e0164180, 2016.
- 25- Zreaqat M., Hassan R. and Halim A.S.: Facial dimensions of Malay children with repaired unilateral cleft lip and palate: A three dimensional analysis. *International journal of oral and maxillofacial surgery*, 41 (6): 783-788, 2012.