

Effect of nasoalveolar molding therapy on the presurgical correction of maxillary arch and nasal deformity in unilateral cleft lip and palate

Original
Article

Mona S. Saad¹, Ahmed M.A. Habib²

¹Lecturer of Prosthodontics, Faculty of Dentistry Alexandria University, Egypt

²Assistant Professor of Maxillofacial & Plastic Surgery, Faculty of Dentistry, Alexandria University, Egypt

ABSTRACT

Introduction: The surgeons face challenges to restore and align the nasolabial and alveolar structures to the normal state making primary closure of the lip for unilateral cleft lip and palate (UCLP) very difficult. Nasoalveolar molding (NAM) represents a paradigm shift from the traditional methods of presurgical infant orthopedics (PSIO).

Objective: To study the outcomes of NAM therapy for the correction of maxillary arch alignment, decreasing the cleft gap severity and improving the nasal esthetics.

Material and methods: 12 UCLP infants (age < 1month) were presented for NAM therapy prior to surgical intervention. NAM appliance was constructed as two connected parts; intraoral plate for alveolar molding and nasal stent for nasal molding. Incremental addition and reduction to the appliance were performed to realign the deformed nasoalveolar structure. Measurements of intraoral and nasal casts were made, and statistical analyses were performed to compare the between pre and post NAM measurements.

Results: After NAM therapy there was a statistical significant decrease in intersegment distance, midline deviation, alar width. There was also a statistical significant increase in columellar length and angle.

Conclusion: By the selective realignment of UCLP nasoalveolar deformity, NAM therapy can achieve a foundation for more esthetic repair under minimal tension.

Key Words: Maxillary alignment, nasoalveolar molding, nasal deformity, palate and Unilateral cleft lip

Received:22 May 2018, **Accepted:**29 July 2018

Corresponding Author: Mona S. Saad, Lecturer of Prosthodontics, Faculty of Dentistry Alexandria University, Cairo, Egypt, **Tel.:** +2 01005126021, **E-mail:** mona.saad@dent.alex.edu.eg

ISSN: 2090-097X, May 2018, Vol. 9, No. 2

INTRODUCTION:

The cleft lip and palate (CLP) is the most common craniofacial anomalies with varying incidence from 1:500 to 1:2500 live births.⁽¹⁾ The etiology of cleft palate is not clear yet but it may have some hereditary, genetic factors, or gene-environment interaction.⁽²⁾

Unilateral clefts are nine times as common as bilateral clefts, and occur twice as frequently on the left than the right. The ratio of left:right:bilateral clefts are 6:3:1. Males are predominantly affected by cleft lip with or without cleft palate (M: F - 2:1) whereas females are more commonly affected by isolated cleft palate.⁽³⁾

The complete unilateral cleft lip and palate (CUCLP) deformity is characterized by a combined maxillary and nasolabial deformity. The maxillary deformity is

represented with a wide cleft gap, malaligned rotated maxillary segments, protruded and laterally displaced greater segment and collapsed lesser segment. While the nasolabial deformity is represented as; widely separated lip segments, concave ala at the cleft side of the nose, wide nostril base, deviated short columella, depressed nasal dome, and deviated nasal septum to the noncleft side with a shift of the nasal base.⁽⁴⁾

Since, the basic aim of treatment in cleft patients is to restore normal anatomy and function, the management of cleft patients is a multidisciplinary approach. A team of experienced pedodontists, prosthodontists, maxillofacial and plastic surgeons, orthodontists, psychologist and speech therapist are necessary for the proper cleft individual management since birth to adulthood.⁽⁵⁾

Considering that the UCLP deformity varies widely in its form and severity, cleft lip and palate has challenged generations of surgeons. Therefore, variety of surgical procedures has been advocated to achieve these goals. Therefore, surgery alone may not prove to be beneficial in all cases, especially where the separation between the cleft segments is large as the cleft gap makes the lip repair challenging without tension. Consequently, tension may cause scarring on the lips with bad esthetic outcomes and negative effect on the maxillary growth.⁽⁶⁾

Today because of increased knowledge of craniofacial growth, development of surgical procedures and improvement of prosthodontic and orthodontic treatment, cleft palate patients receive better care and less time, where prosthetic appliances or presurgical orthopedic appliances have been developing through history to facilitate the primary surgical repair.⁽⁷⁾

The concept of presurgical infant orthopedics (PISO) was first popularized by a Scottish prosthodontics McNeil⁽⁸⁾

Nasoalveolar molding therapy (NAM) as a presurgical infant orthopedics is one of the recent modalities in the presurgical management of UCLP management. The NAM therapy was developed by Grayson et al.,⁽⁹⁾ based

on the original research on neonatal molding of the nasal cartilage was performed by Matsuo using silicon tubes to mold the nostril for early auricular cartilage molding.⁽¹⁰⁻¹³⁾ The NAM appliance consists of an intraoral molding plate with extraoral nasal stents to mold the alveolar ridge and the nasal cartilage concurrently.⁽¹⁴⁾

Considering that the major goal of any introduced therapy in the early cleft lip and palate management is to improve nasolabial esthetic and restore maxillary alignment.

The objective of this study is to quantify the effect of NAM therapy on the improvement of the nasolalveolar deformity in the terms of: intersegment distance, midline deviation of the greater segment, bialar width, heminasal width, and columellar length and angle. The null hypothesis was that the presurgical NAM in unilateral cleft lip and palate patients does not affect the maxillary arch alignment and nasal deformity.

MATERIALS AND METHODS

The NAM therapy protocol was approved by the institutional review board of the faculty of Dentistry, Alexandria University. (Fig.1)

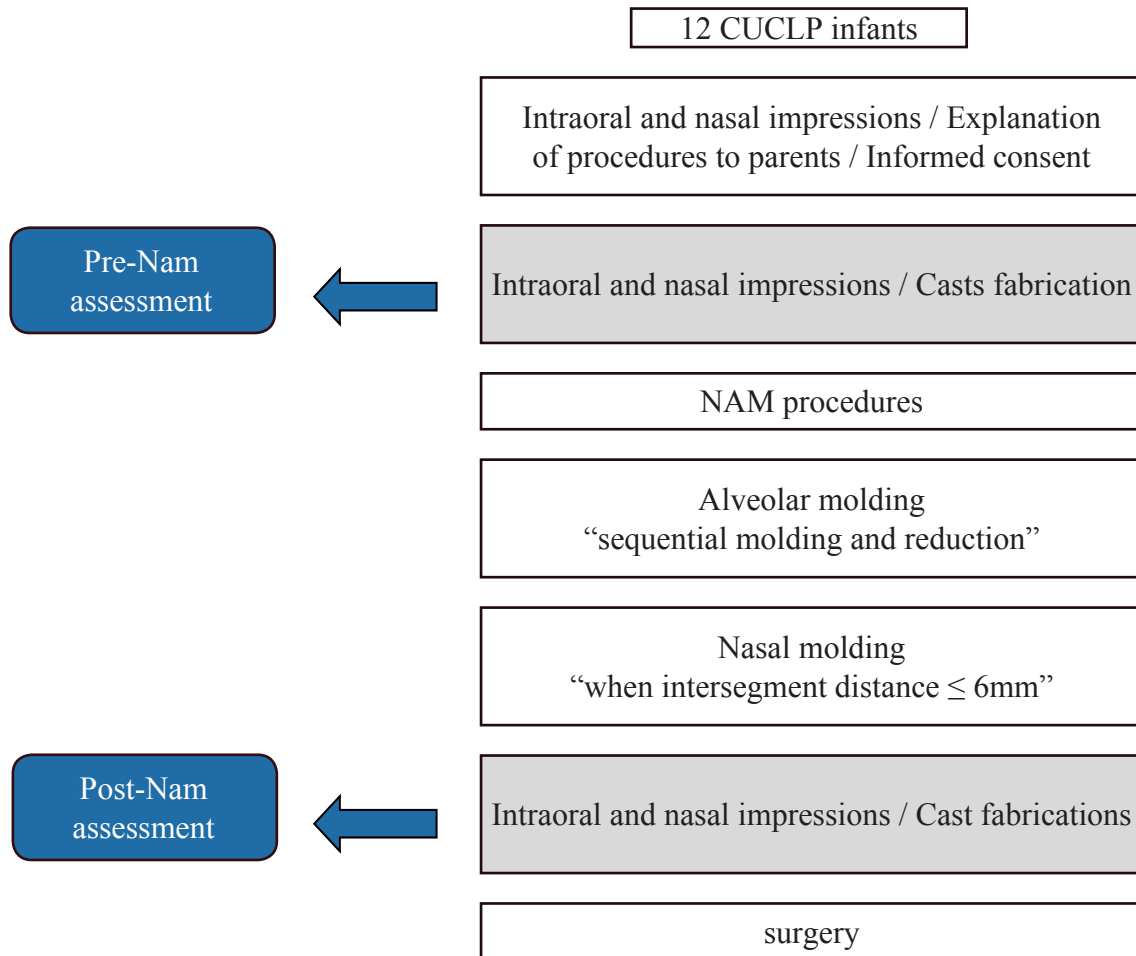


Fig. 1: Flow diagram of the approved NAM protocol.

The Helsinki Declaration guidelines have been also followed in this study.

Sample size:

Using a power of 80% to detect clinically meaningful difference at the intersegment distance before and after applying NAM therapy = 5.8, SD=3.4, effect size=1.2 and $\alpha=0.05$. The minimal required sample size was calculated to be twelve. The sample size was calculated using G*Power software.

History and examinations:

Twelve infants (age < 1 month, 5 males and 7 females) with CUCLP (Fig. 2) were presented to the Department of Prosthodontics (Alexandria University, Alexandria, Egypt). The inclusion criteria were as follows: (1) complete unilateral cleft lip and palate; (2) no other craniofacial malformations or systemic diseases; (3) newborn to 1-month-old.

Following examination and explanation of the treatment goals and the procedure to the parents, consents were obtained to start the molding procedure.

Impression procedures:

Intraoral impressions of alveolar defect were made at (pre- NAM), and (post-NAM) using a fast set alginate impression material (Kromopan, LSCOD, Italy). Wet cotton was packed into the narrow nasal undercuts to avoid unneeded flow of the impression material and subsequent tear during impression removal from mouth. The impression trays were seated carefully in the infants mouth while the infants were fully awake, without anesthesia, in an inverted position to allow escape of the saliva away from the airway space and to prevent possible aspiration of the impression material and regurgitation of stomach contents. After impression material setting, the infants were laid on their sides and the impression was removed. Care was taken to ensure that the material has registered the border regions of the maxilla as well as cleft region with checking for any torn or deficient parts.

Extraoral impressions included the upper lip and the nose were recorded at (pre- NAM), (post-NAM). The impressions were carefully poured in dental stone (Elit stone, zhermack- Germany), and the casts were recovered.

NAM procedures:

The fabrication of the NAM appliance was done following the technique described by Grayson et al. (9, 15). It includes an intraoral molding acrylic palatal plate and a nasal stent.

A. Alveolar molding

The intra oral part of the appliance was fabricated in 2 to 3 mm thickness to permit adjustments during the molding therapy. The appliance was finished and polished to ensure elimination of any sharp edges. Then it was retained extraorally by surgical tapes to the cheeks and bilaterally with orthodontic elastics at each end (Fig.3). The infants were observed for few minutes to insure that

she was able to suckle without gagging or struggling, then the nasogastric tube (Fig.2) was eliminated. Instructions for insertion, removal and cleanliness of the appliance were given to the caretakers. Instructions were given to keep plate in oral cavity for 24 h except during cleaning. At the next appointments, a 1-mm thick layer of soft liner (Acrostone, UK) was added to the labial surface of the of the greater alveolar segment while reducing the acrylic from the palatal aspect of the appliance to direct the greater segment inward toward the cleft. On the other hand, a 1 mm thickness of softliner was added to the palatal aspect of the lesser segment with subsequent acrylic reduction from the labial. The goal of this sequential addition and selective grinding away of material was carried out during recall appointments at 1- to 2-week intervals to progressively reduce the size of the intra-alveolar gap and to have the two alveolar segments in the configuration of a proper maxillary alveolar arch form.⁽¹⁶⁾

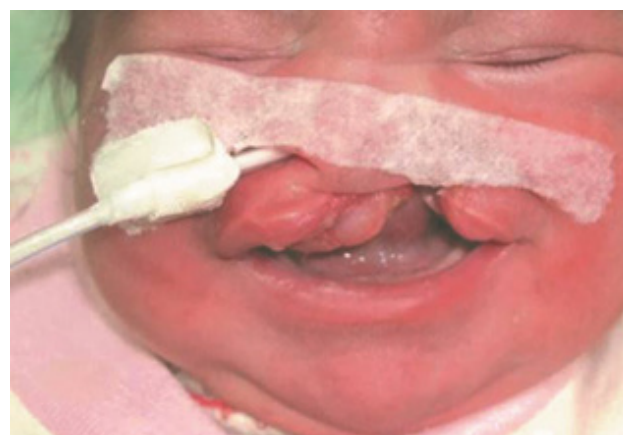

Fig. 2: Infant with unilateral cleft lip and palate defect. A nasogastric tube was being used for feeding before construction of NAM.

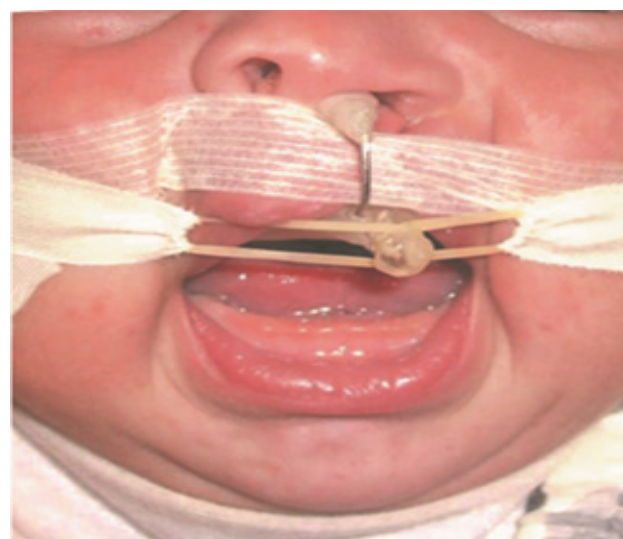

Fig. 3: NAM retained in place by extraoral tapping connected to the appliance via orthodontic elastics.

The selective molding procedures were planned by both the prosthodontists and the maxillofacial surgeon.

B- Nasal molding

A nasal stent was constructed from round stainless steel wire and secured to the labial flange of the appliance. It was extended forward and then curved backward in the form of a “swan neck” passing 3 to 4 mm past the nostril aperture.

The acrylic nasal part of the nasal stent is shaped as bilobed; the greater lobe extends beyond the nasal aperture and the smaller lobe is located out of the nostril aperture, while the nostril border was allowed to lie on the groove between the two lobes. Sequential addition of soft-liner on the greater lobe was performed to allow molding of the alar cartilage as well as the columella.

The procedures of both alveolar and nasal molding were continued till the intersegment distance was reduced to 34- mm, and the correction of the columella and alar cartilage were obtained.

The intraoral casts were measured for the intersegment width and the Midline deviation of the greater segment (Table. 1); (Fig. 4). While, the nasal casts were measured for bialar width (ala1- ala2), heminasal width in noncleft side (sn-ala1) and cleft side (sn-ala2), columellar height in noncleft side (cph1-C1) and cleft side (cph2-C2) (Table 2), (Fig. 5).

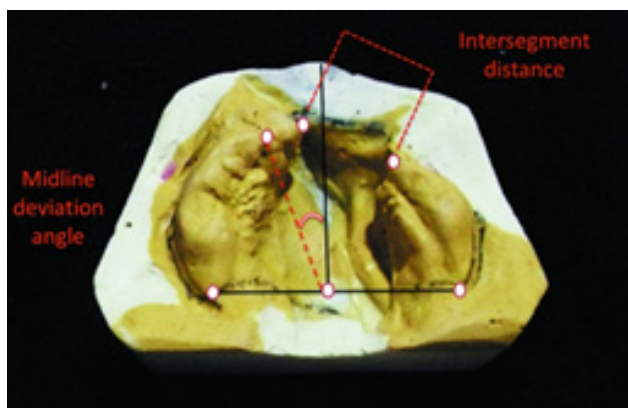


Fig. 4: Intraoral and nasal casts before and after NAM.

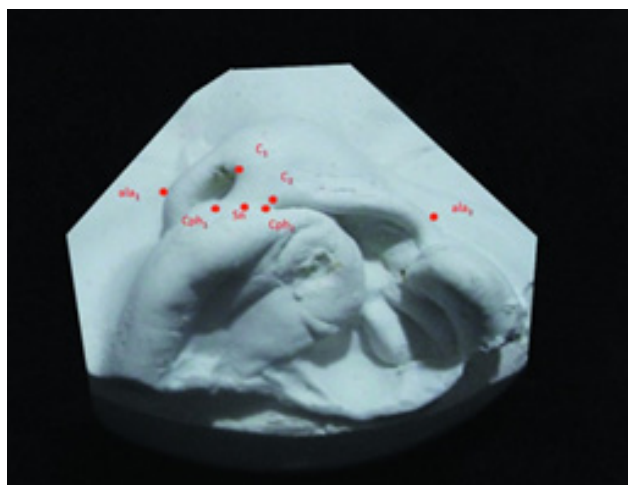


Fig. 5: Intraoral measurements.

Table. 1: intraoral measurements.

Measurements	Descriptions
Intersegment distance	Measurement between the tangents to the most medial curvature at the center of the ridges.
Midline deviation angle	Angle among Incisive papilla, midpoint on the horizontal line crossing tuberosities, and sagittal line perpendicular to the midpoint.

Table. 2: Nasal measurements.

Measurements	Descriptions
Bi-alar width nasal width (al-al)	Distance between the most lateral aspect of the right and left alar (al).
Heminasal width (sn-al)	Distance between the most lateral aspect of the alar (al) to the (sn) point.
Columellar length on each side (cph-c)	Distance between the (cph) point to the highest point of columella (c).
Columellar angle	Columella to a horizontal line connecting the alar base.

A set of (pre and post NAM) intraoral and nasal casts were labeled and saved for the measurements. (Fig. 6)

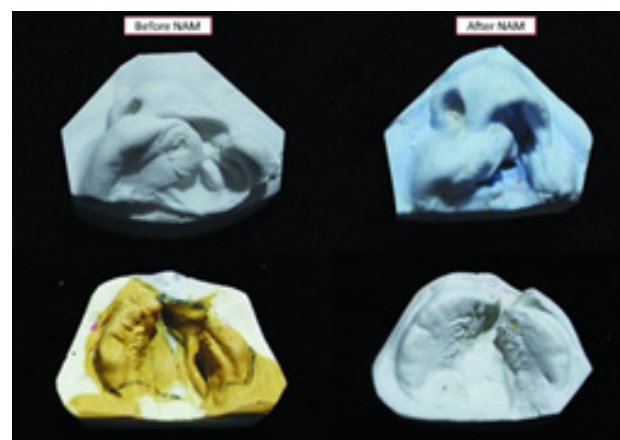


Fig. 6: Landmarks for nasal measurements; Alare (al) is the most lateral point of each ala, the highest point of columella (c) lies atop each hemicolumella, subnasale (sn) defines the angle between columellar base and upper lip, crista philtri (cph) is atop each philtral column at the same horizontal line drawn through sn. Suffix (1 and 2) refers to the noncleft and cleft side respectively.

Surgery:

The surgical technique was performed at 3 months of age according to Millard’s rotation/advancement technique⁽¹⁷⁾.

Statistical analysis

All data were analysed by statistical software package

IBM SPSS version 20.0. (Armonk, NY: IBM Corp) The Kolmogorov-Smirnov test was used to verify the normality of distribution. Quantitative data were described using range, minimum and maximum, mean, standard deviation and median. Significance of the obtained results was judged at the 5% level. Wilcoxon signed ranks test was

used to compare between two periods.

RESULTS:

Typical results are given in tables (3 and 4) and Figures (7 and 8).

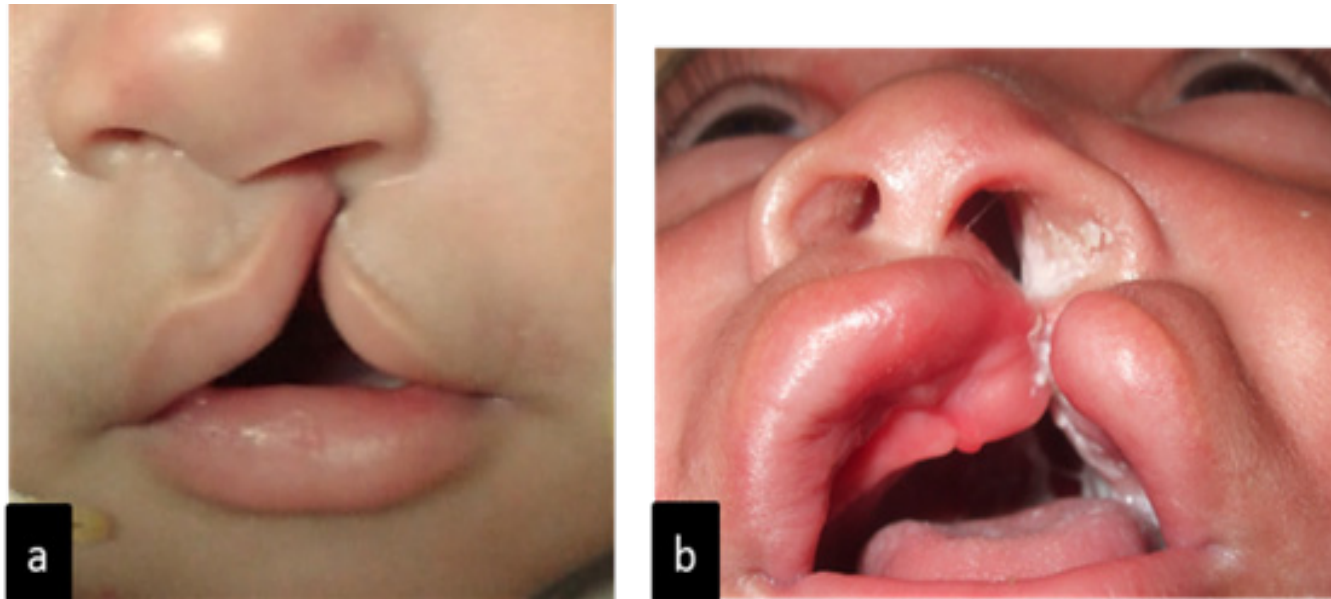


Fig. 7: Nasolabial and alveolar deformity after correction by NAM.

a: showing approximated labial segments after NAM.

b: showing approximated cleft maxillary segments, narrower bialar width, convex ala, elongated and upright columella.

c: after surgery: showing more symmetric nostrils.

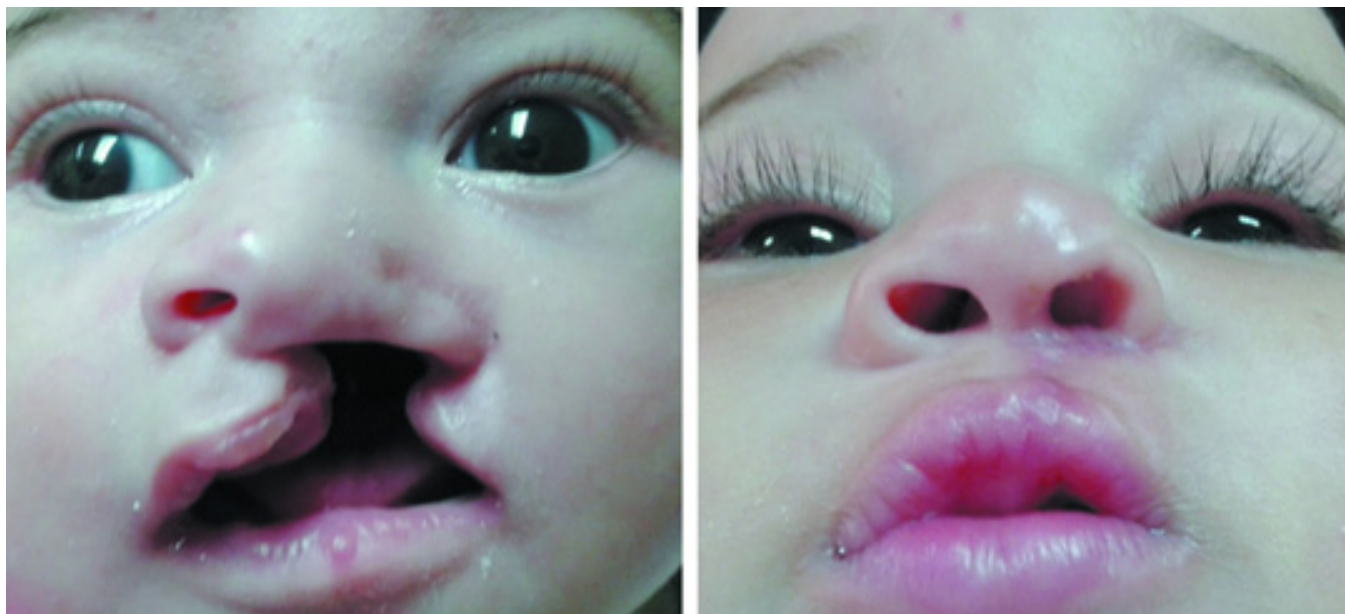

Fig. 8: An infant before NAM; showing wide bialar width, wide flattened ala, short and deviated columella and widely separated lip segments, while more esthetic outcomes are shown after surgical repair following NAM.

Table. 3: Intraoral casts measurements pre and post NAM therapy.

Intraoral cast measurements	Phase										Z (P)
	Pre-NAM					Post-NAM					
	Minimum	Maximum	Mean	SD	Median	Minimum	Maximum	Mean	SD	Median	
Intersegment distance	11.5	17.5	14.2	2.0	13.8	1.0	3.0	2.4	0.6	2.5	4.2 (0.001)*
Midline deviation	22.6	28.0	25.1	1.7	25.3	-5.2	5.0	0.7	2.8	1.0	4.2 (0.001)*

Z: Wilcoxon test

* P < 0.05 (significant)

Table. 4: Nasal casts measurements pre and post NAM therapy.

Intraoral cast measurements	Phase										Z (P)
	Pre-NAM					Post-NAM					
	Minimum	Maximum	Mean	SD	Median	Minimum	Maximum	Mean	SD	Median	
sn-al ₁	9.50	12.00	10.52	.80	10.50	11.50	13.50	12.56	.66	12.85	3.9 (0.001)*
sn-al ₂	22.70	25.00	23.75	.86	23.50	13.00	18.00	15.35	1.79	14.88	44.2 (0.001)*
all-al ₂	33.50	38.00	35.53	1.26	35.50	25.00	32.50	29.29	2.56	29.50	4.1 (0.001)*
Cph ₁ -C ₁	4.50	5.55	4.96	.39	5.00	5.80	7.00	6.50	.43	6.50	4.2 (0.001)*
Chp ₂ -C ₂	0.00	.75	.39	.22	.48	5.00	6.75	5.85	.53	5.88	4.2 (0.001)*
Columellar angle	39.00	49.00	44.55	3.56	44.50	83.50	87.00	84.86	1.15	84.79	4.2 (0.001)*

Considering the intraoral parameters; both the intersegment distance and the midline deviation angle showed a statically significant decrease after NAM therapy (p= 0.001).

Considering the extraoral parameters; the heminasal width at the noncleft side (sn-al1) was increased significantly (p=0.001), while the heminasal width at the cleft side (sn-al2) and the bialar width (all-al2) were decreased significantly (p=0.001). The columellar height at the noncleft (Cph1- C1) and cleft side (Cph2- C2) and the columellar angle were increased significantly (p=0.001).

DISCUSSION:

The PSIO is required to restore normal anatomy, and to reposition the malpositioned structures before surgical correction. Historically, the use of PSIO appliances has aided significantly in reducing the cleft size of the alveolus

and palate before surgery⁽¹⁸⁾. All orthopedic appliances mold only alveolar segments together but do not correct the nasal deformity. Therefore the addition of the nasal stent to the oral appliance has highly improved the nasal esthetics outcomes and helped the surgeon to restore the normal anatomy in the primary surgical repair with satisfying results to both the family and the surgeon.⁽¹⁴⁾

Matsuo et al.,⁽⁶⁾ stated that maternal estrogen level is highest shortly after birth. Maternal estrogen increases hyaluronic acid, a component of the proteoglycan intercellular matrix, found circulating in infants for several weeks after birth, in neonatal cartilage rendering a high degree of plasticity. Therefore, Grayson applied this concept to mold the alveolar segments and to diminish the cleft severity correct the position of the alar cartilage, in addition to elongate the columella.

According to the current study, the evaluation the intraoral casts revealed that the NAM therapy significantly decreased the cleft gap deformity along with realigning of the greater segment midline to the normal position; this means that the NAM normalized the arch configuration by rotation of the protruded greater segment inward and medially as well as the realignment of the midline that may allow eruption of the central incisors at the correct position. Fortunately, it was observed that the labial segments were markedly approximated and this may attributed to the mimization of the cleft gap severity along with the effect of labial tapping.

The evaluation of the nasal casts demonstrated that the NAM therapy significantly decreased in the alar width and it was attributed to the significant decrease in the heminasal width at the cleft side by the effect of the nasal molding. Since, the nasal stent pulls the cleft ala upward and forward.

The columellar height and angle were significantly increased which explains the value of the nasal stent in the stretching the columella superiorly and medially. Additionally, the up-righting of the columellar angle was improved by the intraoral repositioning of the greater maxillary segment.

Since, the current study quantified the effect of NAM therapy on UCLP; it can be stated that NAM guides the development and growth of the nasoalveolar segments in a normal pattern. Moreover, NAM served as an obturator to facilitate infant feeding and eliminates the need nasogastric tubes used for feeding. Since a negative pressure cannot be generated within the mouth for sucking without palatal plate.⁽¹⁹⁾ The improved feeding was apparently observed shortly after wearing the appliance and this eliminated the need for using the nasogastric tube. While some complications have been observed during the treatment procedure; first, in some patients, mucosal ulcer was found at the labial mucosa opposite to the soft liner, however it was not considered as an obstacle to proceed in the treatment procedure. Since, the mothers were instructed to remove the appliance for few days till complete healing was obtained. Then the appliance was relieved slightly at the opposite to the area of ulcer. Second complication is the lack of the parents compliance at the beginning of treatment but their compliance was improved by providing more explanation for the importance of the NAM through using audiovisual aids and showing them pre and post photographs for previously treated cases. Consequently the parents anxiety was decreased and they were greatly motivated to continue the treatment, whereas, the parental co-operation is a must for successful PNAM therapy⁽²⁰⁾.

Considering that surgical repair is normally done at 3 months after birth for cleft lip⁽²¹⁾ Thereby presurgical nasoalveolar molding can be performed during this period to realign the cleft segments providing better esthetic outcomes with easier approximation of tissues, better nostrils symmetry and shorter surgical time. Actually, it

was noticed that most of the patients were appreciating the dentist visit for their infants since they were not aware or even heard about by that type of presurgical treatment and its importance to their infants. Therefore, essential awareness and guidance among the health care providers as well as parents about the special needs of such patients is highly required as this will provide more satisfying outcomes and consequently improves the quality of CLP management⁽²²⁾.

CONCLUSION

Nasoalveolar molding (NAM) is an emerging technique which acts as a nonsurgical form of treatment that provides custom tissue realignment via correcting the alar pattern width, resolving the columellar deformity and alveolar segment malposition allowing for a more esthetic repair under minimal tension and less scar formation.

REFERENCES

1. Shafer WG, Hine MK, Levy BM: Shafer's Textbook of Oral Pathology (ed 6). St. Louis, Elsevier, 2009, pp. 1617-.
2. Bianchi F, Calzolari E, Ciulli L, Cordier S, Gualandi F, Pierini A, Mossey P. Environmental and genetics in the etiology of cleft lip and palate with reference to the role of folic acid. *Epidemiol preview.*: 2000; 24:217-.
3. Goodacre Y, Swan MC. Cleft lip and palate: Current management. *Paediatr Child Health* 2008; 18:28392-.
4. Lee CT, Grayson BH, Cutting CB, Brecht LE, Lin WY. Prepubertal midface growth in unilateral cleft lip and palate following alveolar molding and gingivoperiosteoplasty. *Cleft Palate Craniofac J* 2004;41:375380-.
5. Sischo L, Clouston SA, Phillips C, Broder HL. Caregiver responses to early cleft palate care: A mixed method approach. *Health Psychol*, 2016. 35: p. 47482-.
6. Kramer GJC, Hoeksma JB, Prah-Andersen B. Palatal changes after lip surgery in different types of cleft lip and palate. *Cleft Palate Craniofac J* 1994;31:376-84.
7. Kim JS, Kim YJ, Nam SH, Kim HJ. Effect of presurgical nasoalveolar molding in unilateral cleft lip and palate infants. *J Korean Acad Pediatr Dent* 2013;40:20915-.
8. McNeil C K. Oral and Facial Deformity. Pittman, London 1954 pp 81- 9.
9. Grayson BH, Cutting CB, Santiago PE, Brecht LE, Cutting CB. Presurgical nasoalveolar molding in infants with cleft lip and palate. *Cleft Palate Craniofac J* 1999;36:486498-.

10. Matsuo K, Hirose T, Tonomo T. Nonsurgical correction of congenital auricular deformities in the early neonate: a preliminary report. *Plast Reconstr Surg* 1984;73:3850-.
11. Matsuo K, Hirose T. Nonsurgical correction of cleft lip nasal deformity in the early neonate. *Ann Acad Med Singapore* 1988;17:358365-.
12. Matsuo K, Hirose T, Otagiri T, et al: Repair of cleft lip with nonsurgical correction of nasal deformity in the early neonate period. *Plast Reconstr Surg* 1989;83:2531-.
13. Matsuo K, Hirose T. Preoperative non-surgical overcorrection of cleft lip nasal deformity. *Br J Plast Surg* 1991;44:511-.
14. Pradip R. Shetye and Barry H. Grayson. NasoAlveolar Molding Treatment Protocol in Patients with Cleft Lip and Palate, Seminars in Orthodontics, <http://dx.doi.org/10.1053/j.sodo.2017.05.002>.
15. Grayson BH, Garfinkle JS. Nasoalveolar molding and columella elongation in preparation for the primary repair of unilateral and bilateral cleft lip and palate. In: Losee JE, Kirschner RA, editors. *Comprehensive cleft care*. New York: McGraw-Hill Medical; 2009. p. 70120-.
16. Taylor TD: *Clinical Maxillofacial Prosthetics* (ed 1). Chicago, Quintessence, 2000, pp. 6384-.
17. Lee TJ. Upper lip measurements at the time of surgery and followup after modified rotation-advancement flap repair in unilateral cleft lip patients. *Plast Reconstr Surg* 1999;104:911-915
18. Liou EJ, Subramanian M, Chen PK, Huang CS.: The progressive changes of nasal symmetry and growth after nasoalveolar molding: a three-year follow-up study. *Plast Reconstr Surg* 2004;114:858864-.
19. Choi BH, Kleinheinz J, Joos U, Komposch G. Sucking efficiency of early orthopaedic plate and teats in infants with cleft lip and palate. *Int J Oral Maxillofac Surg* 1991; 20: 167169-.
20. Brecht LE, Grayson BH, Cutting CB. Nasoalveolar molding in early management of cleft lip and palate. In: Taylor TD, editor. *Clinical maxillofacial prosthetics*. Chicago: Quintessence; 2000. p. 63-84.
21. Berkowitz S. *Cleft lip and palate*. 2. Springer: Berlin; 2006. pp. 381-407.
22. El-Kassaby, M. A.W. Overview of the level of cleft care received by a group of Egyptian patients: challenges and ways to improve. *Egyptian Journal of Oral & Maxillofacial Surgery*. 2012;3:5361-.