

# Validity of radical enucleation combined with peripheral ostectomy and Carnoy's solution for management of large mandibular keratocystic odontogenic tumors

Original  
Article

Rafic R. Pedar

Department of Oral and Maxillofacial Surgery, Faculty of Dentistry, Tanta University,  
Tanta, Egypt

## ABSTRACT

**Introduction:** There are different surgical techniques have been published for management of keratocystic odontogenic tumors (KCOT). The treatment modalities are divided into conservative, invasive and radical approaches. We aimed in this study to evaluate the validity of combinations of conservative approaches in an attempt to eliminate the recurrence rate of keratocystic odontogenic tumors.

**Materials and Methods:** This prospective study involves twelve patients with keratocystic odontogenic tumor (KCOT). All patients were examined clinically and radiographically. The entire cyst lining was radically enucleated in conjunction with any overlying mucosa en masse, followed by extensive cavity thoroughly curettage then Reformulated recipe for Carnoy's solution (alcohol, glacial acetic acid, ferric chloride and ethanol without the chloroform) according to Johnson et al, 2013 impregnated gauze applied on the bony bed away from the exposed vital structure for 3-5 minutes.

**Results:** A total of twelve patients with unilateral mandibular radiolucent lesion (50% related to impacted teeth) were diagnosed as parakeratinized KCOT by clinical, radiographical, aspirated biopsy and confirmed histologically. The most common site according to the present study was the posterior mandible (58%), the body and angle of the mandible (25%), followed by the anterior mandible (16.7%). All patients showing eventful and asymptomatic wound healing inferior alveolar nerve, two of them recovered in three months with oral neurotonic while one patient (8.3%) still not resolved at the end of the follow up period.

**Key Words:** Carnoy's solution, keratocystic odontogenic tumour, peripheral ostectomy.

**Received:** 28 June 2018, **Accepted:** 21 October 2018

**Corresponding Author:** Rafic R. Pedar, BDS, MSc, PhD, Department of Oral and Maxillofacial Surgery, Faculty of Dentistry, Tanta University, Tanta, Egypt, **Tel.:** + 20 1005010532, **E-mail:** raficramadan75@gmail.com

**ISSN:** 2090-097X, May 2018, Vol. 9, No. 2

## INTRODUCTION

Keratocystic odontogenic tumour (KCOT) was first coined in the literature by Philipsen in (1956) as benign developmental odontogenic keratocyst of the jaw that have a high potential for extensive infiltration and recurrence after simple excision.<sup>1</sup>

The most commonly occurring cysts are radicular cysts followed by follicular cysts and odontogenic keratocyst (OKC) and constituted 10.2% of all odontogenic cysts. This average annual incidence rate rose to 11.58%. Though, it has become the most common odontogenic tumor of the jaw after being reclassified as a tumor with 2:1 male predilection and 75% angle/ramus prevalence site.<sup>2</sup>

KCOT is a noncancerous uni- or multicystic, intraosseous tumour, which originates from the dental

lamina and its remnants with histopathological lining variant of para-keratinised squamous epithelium (90%). While the rarer and clinically less invasive ortho-keratinised variant (10%) still designed to odontogenic keratocyst of the jaw. While malignant transformation into a squamous cell carcinoma is very rare and limited to recurrent cases<sup>3-5</sup>

KCOT is a unique locally aggressive pathology, with ten characteristic features which include; high recurrence rate (13 - 63%), epithelial mitotic activity, thin uniform friable wall, fibrinolytic enzymes, ability to resorb bone and secondary teeth displacement, daughter cysts in their pericystic cavity, budding potential of the basal lining, its capability for antero-posterior sizeable enlargement and late discovery, Chromosomal abnormalities and genetic alteration<sup>6-15</sup>

Owing to its aggressive behaviour, high recurrence rates and specific histopathological features, the World Health Organization (WHO) in 2005 reclassified and referenced the odontogenic keratocyst as benign “keratocystic odontogenic tumour” (KCOT) of the jaw which better reflects its neoplastic nature.<sup>16</sup>

Different surgical techniques have been published, practiced and hotly debated for the management of KCOT. The treatment modalities are divided into conservative, invasive and radical approaches. The conservative methods include simple enucleation with or without extensive curettage or marsupialization/decompression, with or without secondary therapeutic measures. The invasive methods include peripheral ostectomy, chemical curettage with Carnoy's solution, cryotherapy or electrocautery. Radical approaches include either marginal or segmental resection. Nevertheless, all of these modalities accompanied by similar chances of overall recurrence rate.<sup>17-19</sup>

The line of therapy needs to be determined by numerous factors; affected individuals age group, overall size and site of the lesion, involvement of overlying soft tissue, cortical perforation, proximity to vital structure, primary or secondary recurrent tumors, as well as a histological variation of the disease. The actual objective would be to select a therapeutic method that bears the minimum likelihood of recurrence and the minimal morbidity to the patient.<sup>20,21</sup>

Al-Moraissi 2017 meta-analysis analyzed a total of 2287 KOTs in 35 studies aimed to seek the best surgical treatment with the least recurrence rate (RR). The weighted RR for various treatment techniques was as follows: enucleation alone (23.1%), enucleation with curettage (17.4%), enucleation and Carnoy's solution (11.5%), enucleation plus liquid nitrogen cryotherapy (14.5%), marsupialization alone (32.3%), decompression followed by residual cystectomy (14.6%), and resection (8.4%).<sup>22</sup>

Although resections have the high cure rate and lowest RR (8.4%) they produce significant morbidity such as facial disfigurement, loss of jaw continuity, neural affection, followed by complicated constructive staged procedures and psychological limitation. Available evidence does not demonstrate the radical approach as the most effective technique in terms of morbidity and recurrence prevention.<sup>23</sup>

The aim of this prospective study was to evaluate the predictability of radical enucleation and Carnoy's solution as adjuvant therapy in reduction of potential recurrence and morbidity for patient with keratocystic odontogenic tumor.

## **MATERIALS AND METHODS**

This prospective study involve twelve patients with keratocystic odontogenic tumor (KCOT) were presented to out-patient clinic of Oral and Maxillofacial Surgery Department, Faculty of Dentistry, Tanta University between March 2013 and April 2016.

The study was approved by the Research and Ethical Committee of the institution. Written consent of the patients was taken before starting surgical intervention. The histopathological examination was based on the histochemical and histological features of the lining and type of keratin done in the Oral Pathology Department, Faculty of Dentistry, Tanta University, based on the diagnostic criteria outlined by the World Health Organization (WHO).

All patients included in this study fulfill the following criteria

### **Inclusion criteria**

- Primary KCOTs
- Incisional biopsy proven parakeratinized variant
- Moderate to advanced sized mandibular lesion

### **Exclusion criteria**

- recurrent KCOTs
- inconsistent histopathological variant
- Nevoid Basal Cell Carcinoma Syndrome (Gorlin-Goltz Syndrome).

Patient demographic data including age, gender, site involved, medical history and patient's chief complain were collected in performa chart design.

All patients were examined clinically (swelling, pain, facial asymmetry, infection and nerve affection) and radiographically including orthopantomogram, axial, coronal, sagittal and three dimensional computerized tomography to assess uni/multilocular, mono/bicortical expansion, single/multiple location, involved site, related/displaced teeth and impacted/unerupted teeth. Figure 1

Aspiration biopsy taken under local anaesthesia and before the incisional biopsy using eighteen gauge plastic needle syringe was represented yellow cheesy fluid aspirate with keratin flakes which is confirmed diagnosis for KCOT.

All patients were underwent surgical excision under general anesthesia using endotracheal intubation with local infiltration of 2% articaine and 1:100,000 epinephrine. A wide gingival envelope incision was utilized to complete lesion exposure and overlying attached mucosa excision.

The entire cyst lining radically enucleated in conjunction with any overlying mucosa enemas, followed by extensive cavity thorough curettage with meticulous evaluation of any residual daughter cyst lining with reduction of the lingual and buccal undercut bony walls to remove residual macroscopic cystic epithelium. Figure 2

Using coarse carbide rounded surgical burr under copious normal saline irrigation peripheral ostectomy was carried out for all bony walls to remove the microscopic satellite cyst, with identification, isolation, retraction and preservation of the lingual and inferior alveolar nerve bundle. The bony septa were removed using rotary Lindmann fissure burr in case of multilocular advanced lesion.



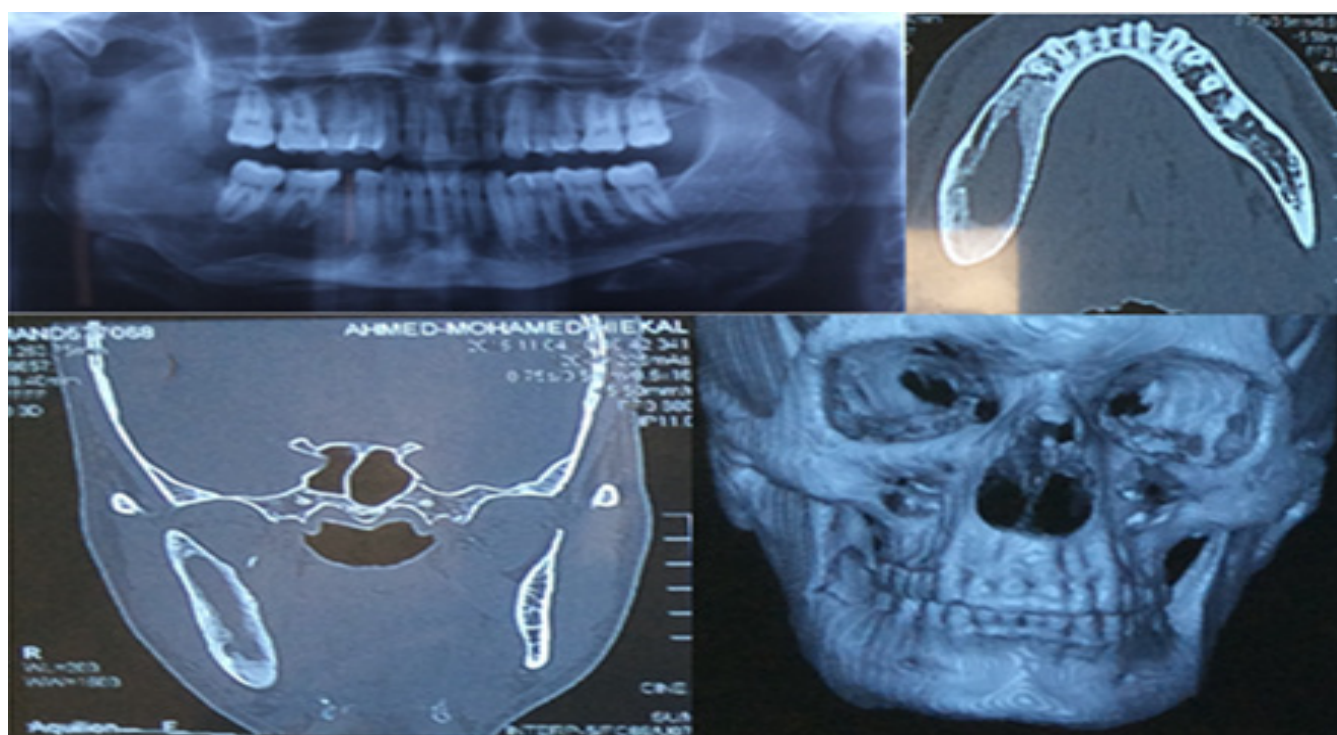


Fig 1: Preoperative radiographic examination

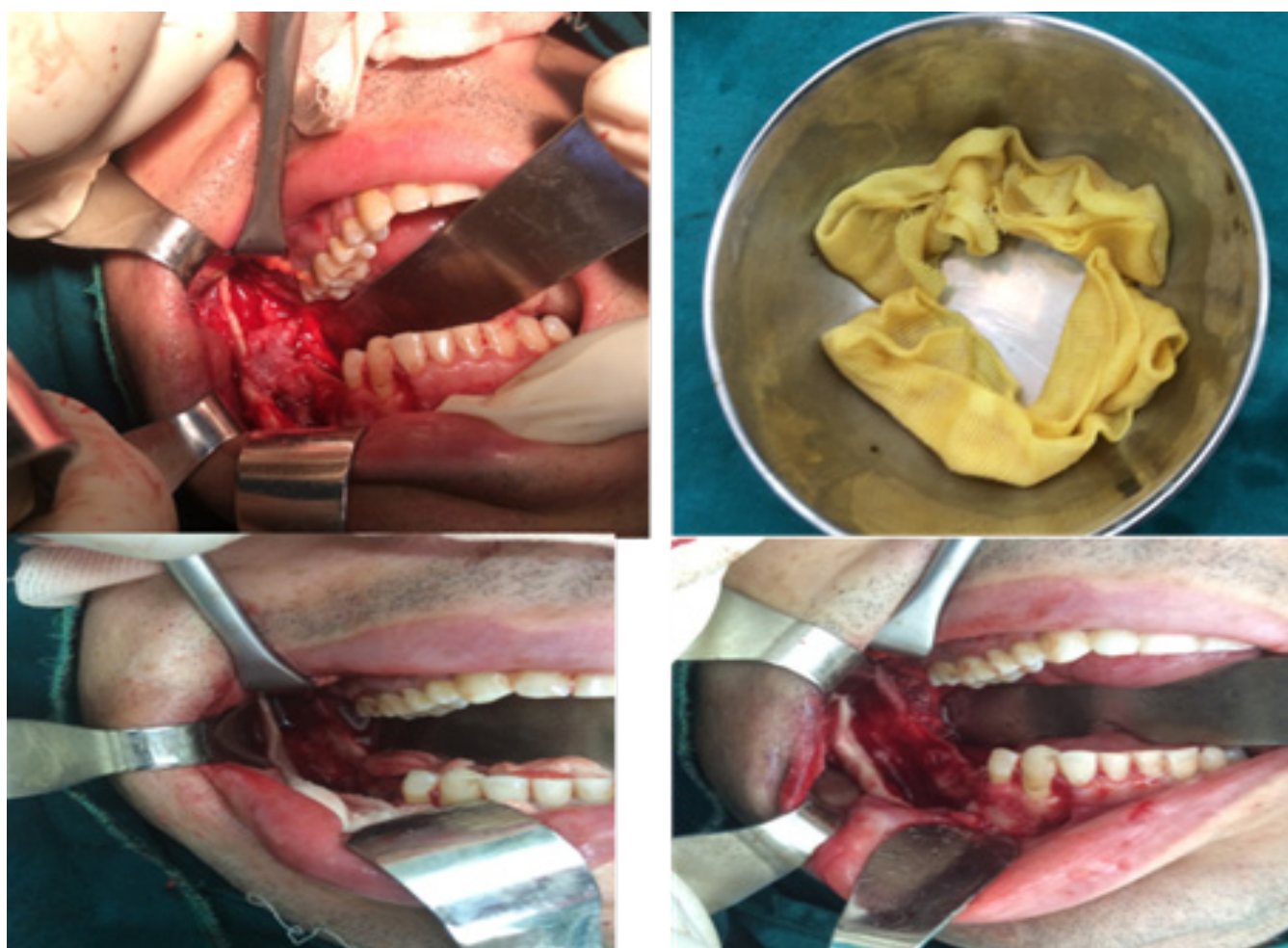

Fig 2: Intraoperative photos for lesion excision and application of Carnoy's solution

Reformulated recipe for Carnoy's solution (alcohol, glacial acetic acid, ferric chloride and ethanol without the chloroform) according to Johnson et al<sup>24</sup> impregnated gauze applied on the bony bed away from the exposed vital structure for<sup>3-5</sup> minutes then the cavity irrigated with 100 ml of physiologic saline. The surgical wound inspected and sutured primarily using interrupted 3o black braided silk.

Broad spectrum beta lactamase antibiotic, pain killer, enzymatic anti-inflammatory and antiseptic mouth wash was initiated and continue for ten days postoperatively

Patients reviewed clinically immediately and weekly for three months postoperatively to assess wound healing, pain symptoms and nerve dysesthesia and radiographically every three months during at least two years follow up period to evaluate bone healing and notice any potential lesion recurrence.

## RESULTS

A total of twelve patients with unilateral mandibular radiolucent lesion (50% related to impacted teeth) were diagnosed as parakeratinized KCOT by clinical, radiographical, aspirated biopsy and confirmed histologically.

The study population comprised nine males (75%) and three females (25%), with a male to female ratio of 3:1, representing male preponderance. Patient age at the time of diagnosis ranged from 19 to 51 years (mean: 30.25) Most of the patients were in their twenties (50%), followed by those in their thirties (33.3%), where as one patient were less than 20 (8.3%) and another more than 50 years old (8.3%).

The most common site according to the present study was the posterior mandible (58%), the body and angle of the mandible (25%), followed by the anterior mandible (16.7%). Radiologically most of the KCOT were predominantly multilocular (58.3%) while only (41.7%) were presented as unilocular cystic lesions.

While four lesions (33.3%) were diagnosed incidentally during routine dental examination with no previous symptoms, eight (66.7%) produced symptoms including swelling, pain and discharge that prompted the patient to come to the clinic.

There is no correlation between the age groups and radiologic and microscopic findings of KCOT ( $P > 0.05$ ). A statistically significant relationship was found between the radiographic appearance and impacted teeth related ( $P = 0.00$ ). Table (1)

**Table (1):** Correlation between the age groups and radiologic features

No	Gender	Sex	Location	Impacted teeth	Radiographic presentation	Status at last follow up
1	M	25	Angle-Ramus	Right wisdom	multilocular	NED
2	F	34	Ramus	Non	multilocular	NED
3	M	19	Body-Angle	Left wisdom	Unilocular	NED
4	M	29	Symphysis	Non	Unilocular	NED
5	M	33	Angle-Ramus	Non	multilocular	NED
6	M	22	Symphysis	Left canine	Unilocular	NED
7	M	24	Angle-Ramus	Left wisdom	multilocular	NED
8	F	51	Body-Angle	Non	multilocular	NED
9	F	26	Angle-Ramus	Right wisdom	Unilocular	NED
10	M	35	Angle-Ramus	Non	multilocular	NED
11	M	38	Body-Angle	Left wisdom	Unilocular	NED
12	F	27	Angle-Ramus	Non	multilocular	NED

NED (no evidence of disease)

All patients as evaluated clinically for 3 months, showing eventful and asymptomatic wound healing except three cases complaining from temporary dysesthesia of the inferior alveolar nerve, two of them recovered in three months with oral neurotonic while one patient (8.3%) still not resolved at the end of the follow up period.

Radiographic evaluation each 3 months postoperatively and extend for 2years showing good bone healing with gradually increasing of bone radio opacity at the site of excised lesions comparing with immediate postoperative radiographs. No radiologic signs of recurrence were found during the follow up period's figures 3&4.

## DISCUSSION

As the recurrence rates of the KCOT as excessive as 62.5% after enucleation and curettage owing to the slender, friable wall structure, which is hard to enucleate from the bone fragments successfully, as well as the satellite cysts inside the fibrous wall. So more than one adjunctive therapy utilized in our research to ensure clear margin and improve overall prognosis.<sup>16</sup>

The mean age group of this study (30 years) as most patients with KCOTs are young with high regenerative capacity and maximum esthetic needs. This go with our research hypothesis of minimally invasive and against the

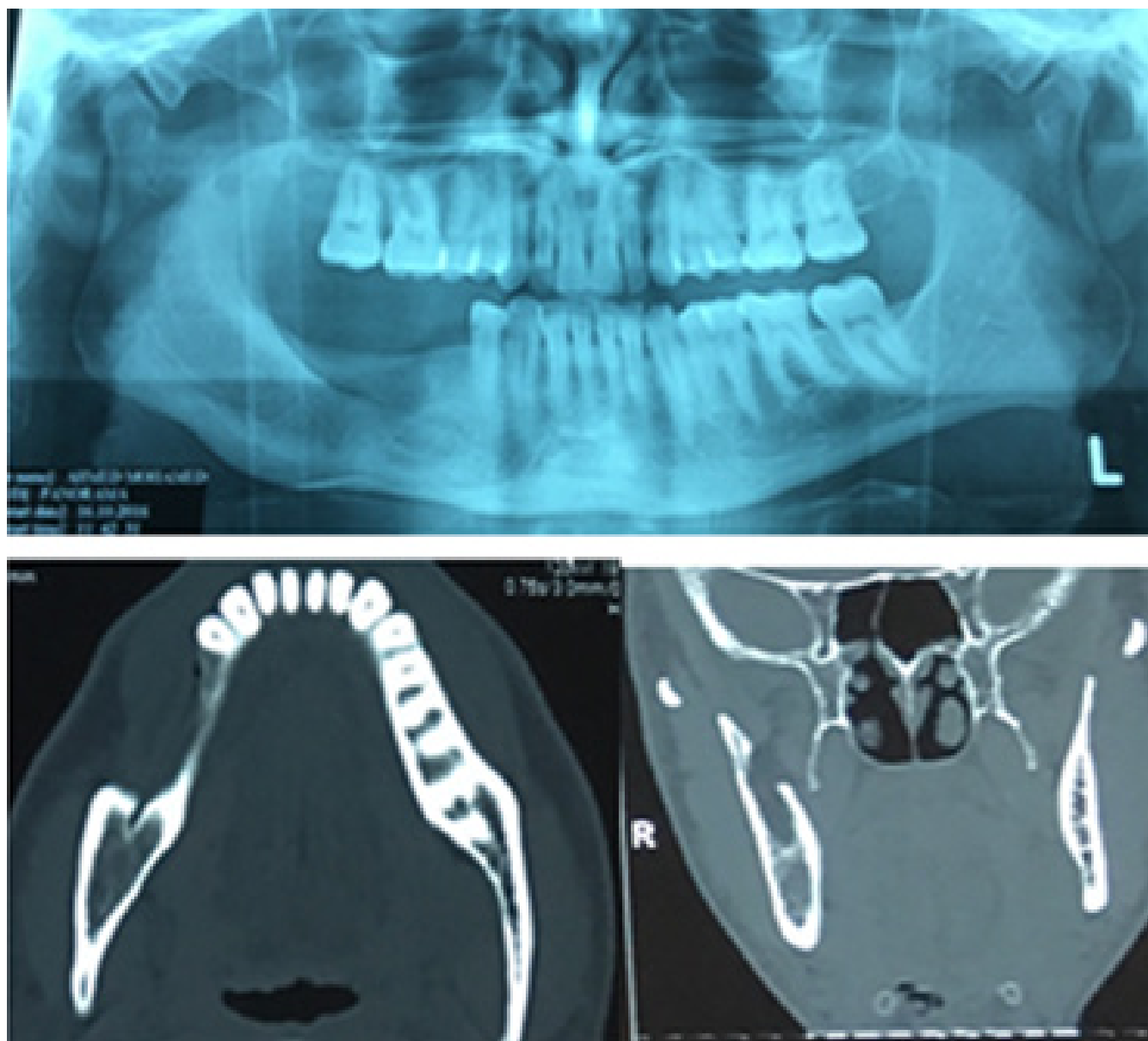
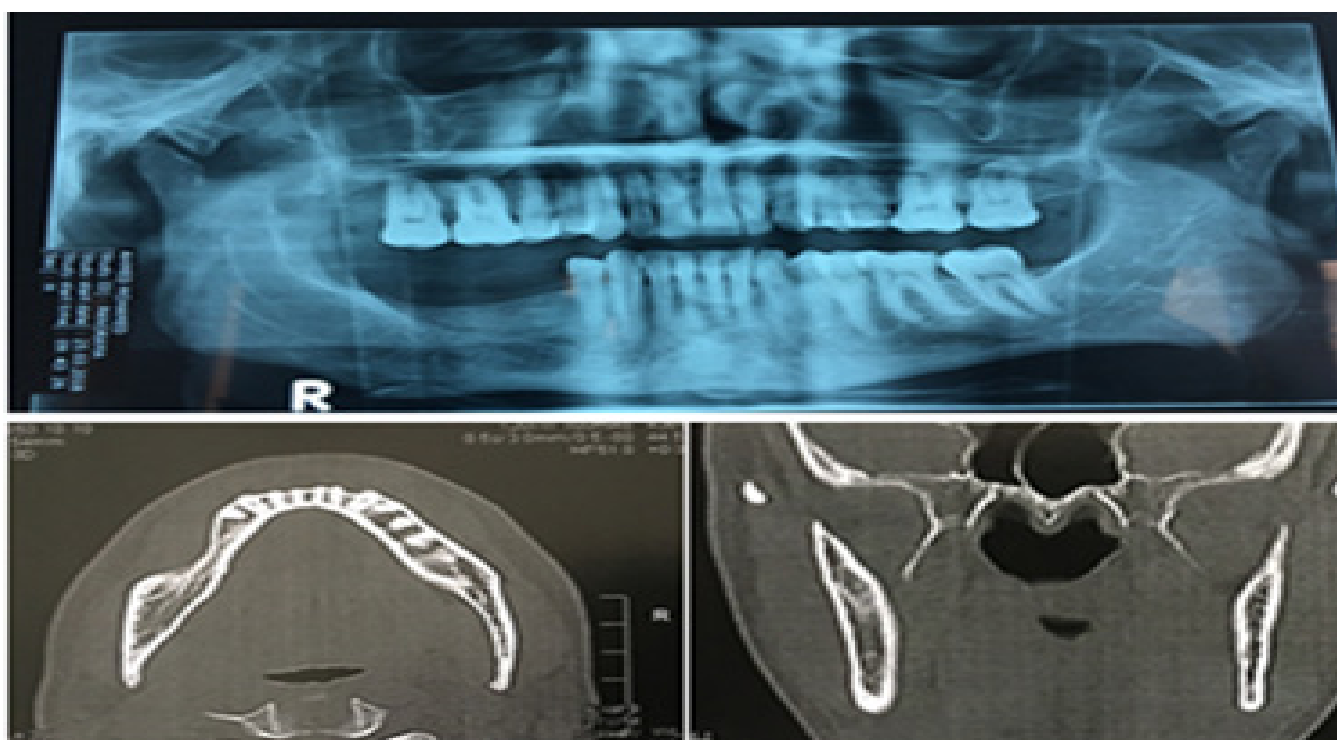


Fig. 3: Radiographs; panoramic and axial & coronal CT immediate postoperatively





**Fig. 4:** Radiographs; panoramic and axial & coronal CT 2 years postoperatively Radiographs; panoramic and axial & coronal CT 2 years postoperatively

aggressive radical approach with severe patient morbidity and necessitate complex staged unpredictable prolonged reconstructive maneuver through grafts and exceptional patient cooperation.

This investigation agree with Morgan et al <sup>25</sup> who excluded patients with orthokeratinized variant from their analysis because the two entities not only have different microscopic features, but their pathobiology is discrepant. KCOT (parakeratinized variant) demonstrates locally aggressive behavior and a high recurrence rate depending on the treatment modality ranging from 25% to 56%, while orthokeratinised odontogenic cyst (OKC) has a significantly lower recurrence rate of 2.2%.

The combination of peripheral ostectomy and application of carnoy's solution in this research was stated by Kaczmarzyk et al, 2012 in their systematic review on treatment for KCOTs and calculated (4.8%) recurrence while resection provides the lowest recurrence rate (1.85%), yet causes the most suffering to the patient. The nil recurrence (0%) in our research could be attributed to radical enucleation of the cyst enmass with the overlying mucosa followed by powered headpiece peripheral ostectomy and chemical curettage using reformulated carnoy's solution.<sup>26</sup>

The reformulated recipe for carnoy's solution without chloroform was utilized in our study according to Zecha et al <sup>27</sup> is currently effective in penetration to, devitalization and fixation of microscopic remaining daughter cysts. Cutler and Zollinger <sup>28</sup> stated in 1933 that " exposure to chloroform has been associated with cancer and reproductive toxicity"

Zhao et al <sup>29</sup> reported a recurrence rate of 6.7% in<sup>29</sup> patients treated with an application of Carnoy's solution into the lesion cavity followed by enucleation. This in contradict with our reformulated carnoy's solution application technique after radical enucleation and rotary peripheral ostectomy to ensure 1.5mm cancellous spaces penetration to devitalise and fix the remaining tumor cells

## CONCLUSION

Despite a relatively short follow-up period in this series, it is still uncertain how long it takes for recurrences to become evident. Early detection of recurrences (addressed with radiographic controls) improves long term prognosis and avoids secondary extensive procedures. This prospective study in a small amount of patients showed encouraging results with our treatment protocol for KCOT. The radiographic follow-up is paramount to evaluate the clinical and surgical outcome. The long follow-up period, and the number of staged procedures require strict commitment from the patient to make this conservative approach successful. Future studies, with bigger sample size, a longer follow up time and control groups are recommended.

## REFERENCES

1. Pittl T. L., Meiera M., Hakl P., Sutterb W., Turhani D., Long-term observation of a large keratocystic odontogenic tumour of the mandible treated by a single enucleation procedure: A case report and literature review, *International Journal of Surgery* 34 (2017) 119–122

2. Leung YY, Lau SL, Tsoi KYY, Ma HL, Ng CL: Results of the treatment of keratocystic odontogenic tumours using enucleation and treatment of the residual bony defect with Carnoy's solution. *Int J Oral Maxillofac Surg* 2016
3. Kuroyanagi N, Sakuma H, Miyabe S, Machida J, Kaetsu A, Yokoi M, et al. Prognostic factors for keratocystic odontogenic tumor (odontogenic keratocyst): analysis of clinico-pathologic and immunohistochemical findings in cysts treated by enucleation. *J Oral Pathol Med* 2009;38:386–92
4. Gaita 'n-Cepeda LA, Quezada-Rivera D, Tenorio-Rocha F, Leyva-Huerta ER. Reclassification of odontogenic keratocyst as tumour. Impact on the odontogenic tumours prevalence. *Oral Dis* 2010;16: 185–7.
5. Blanas N, Freund B, Schwartz M, Furst IM. Systematic review of the treatment and prognosis of the odontogenic keratocyst. *Oral Surg Oral Med Oral Pathol Oral Radiol Endod* 2000;90:553–8
6. Keszler A, Piloni MJ. Malignant transformation in odontogenic keratocyst. *Case Rep Med Oral* 2002;7:331- 5.
7. Marker P, Brøndum N, Clausen PP, Bastian HL. Treatment of large odontogenic keratocysts by decompression and later cystectomy. A long-term follow-up and a histologic study of 23 cases. *Oral Surg Oral Med Oral Pathol Oral Radiol Endod* 1996;82:122- 31.
8. Blanas N, Freund B, Schwartz M, Furst IM. Systematic review of the treatment and prognosis of the odontogenic keratocyst. *Oral Surg Oral Med Oral Pathol Oral Radiol Endod* 2000;90:553- 8.
9. Piattelli A, Fioroni M, Rubini C. Differentiation of odontogenic keratocysts from other odontogenic cysts by the expression of bcl-2 immunoreactivity. *Oral Oncol* 1998;34:404e7.
10. Rodu B, Tate AL, Martinez Jr MG. The implication of inflammation in odontogenic keratocysts. *J Oral Pathol* 1987;16:518- 21.
11. El-Hajj G, Anneroth G. Odontogenic keratocysts - a retrospective clinical and histologic study. *Int J Oral Maxillofac Surg* 1996 Apr;25(2):124 -9.
12. Kinard BE, Chuang SK, August M, Dodson TB. How well do we manage the odontogenic keratocyst? *J Oral Maxillofac Surg* 2013;71(8):13538-. <http://dx.doi.org/10.1016/j.joms.2013.01.029>. Epub 2013 Apr 24.
13. August M, Faquin WC, Troulis MJ, Kaban LB. Dedifferentiation of odontogenic keratocyst epithelium after cyst decompression. *J Oral Maxillofac Surg* 2003;61(6):67883-. discussion 683- 4.
14. Gaikwad R, Kumaraswamy SV, Keerthi R. Decompression and cystectomy of the odontogenic keratocysts of the mandible: a clinical study. *J Maxillofac Oral Surg* 2009;8(1):4751-. <http://dx.doi.org/10.1007/s126630-0012-009->. Epub 2009.
15. Kubota Y, Oka S, Nakagawa S, Shirasuna K. Interleukin-1alpha enhances type I collagen-induced activation of matrix metalloproteinase-2 in Odontogenic keratocyst fibroblasts. *J Dent Res* 2002;81(1):23- 7.
16. Roy I., Louis A. Keratocystic odontogenic tumor: An overview of management protocol *International Journal of Contemporary Dental and Medical Reviews* (2014), Article ID 031014, 4 Pages
17. Johnson NR, Batstone MD, and Savage NW: Management and recurrence of keratocystic odontogenic tumor: a systematic review. *Oral Surg Oral Med Oral Pathol Oral Radiol* 116(4): e271-e276,2013
18. Kaczmarzyk T, Mojsa I, Stypulkowska J: A systematic review of the recurrence rate for keratocystic odontogenic tumour in relation to treatment modalities. *Int J Oral Maxillofac Surg* 41(6): 756 -767,2012
19. Al-Moraissi E.A , Dahan A.A, Alwadeai M.S, Oginni F.O, Al-Jamali J.M, Alkhatari A.S, Al-Tairi N.H, Almaweri A.A, Al-Sanabani J.S; What surgical treatment has the lowest recurrence rate following the management of keratocystic odontogenic tumor?: A large systematic review and meta-analysis. *Journal of Cranio-Maxillo-Facial Surgery* 45 (2017) 131 -144
20. Abdullah WA. Surgical treatment of keratocystic odontogenic tumour: A review article. *Saudi Dent J* 2011; 23:61 -5.
21. Bhargava D, Deshpande A, Pogrel MA. Keratocystic odontogenic tumour (KCOT) – A cyst to a tumour. *Oral Maxillofac Surg* 2012; 16:163- 70.
22. Al-Moraissi E.A , Dahan A.A, Alwadeai M.S, Oginni F.O, Al-Jamali J.M, Alkhatari A.S, Al-Tairi N.H, Almaweri A.A, Al-Sanabani J.S; What surgical treatment has the lowest recurrence rate following the management of keratocystic odontogenic tumor?: A large systematic review and meta-analysis. *Journal of Cranio-Maxillo-Facial Surgery* 45 (2017) 131- 144
23. Deyhimi P, Hashemzadeh Z. Study of the biologic behavior of odontogenic keratocyst nd orthokeratinized odontogenic cyst using TGF-alpha and P53 markers. *Pathol Res Pract* 2014;210:201- 4.

24. Johnson N, Batstone M, Savag N; Management and recurrence of keratocystic odontogenic tumor: a systematic review. Vol. 116 No. 4 October 2013
25. Morgan TA, Burton CC, Qian F. A retrospective review of treatment of the odontogenic keratocyst. *J Oral Maxillofac Surg* 2005;63:635–9.
26. Kaczmarzyk T, Mojsa I, Stypulkowska J: A systematic review of the recurrence rate for keratocystic odontogenic tumour in relation to treatment modalities. *Int. J. Oral Maxillofac. Surg.* 2012; 41: 756–767.
27. Zecha JAEM, Mendes RA, Lindeboom VB, van der Waal I. Recurrence rate of keratocystic odontogenic tumor after conservative surgical treatment without adjunctive therapies—a 35-year single institution experience. *Oral Oncol* 2010; 46:740–2.
28. Cutler EC, Zollinger R. Sclerosing solution in the treatment of cysts and fistulae. *Am J Surg* 1933; 19:411.