

Assessment of the association of maxillary sinus mucosal lining thickening with different dental conditions using cone-beam computed tomography in a sample of the Egyptian population. Observational Cross-sectional study.

Original
Article

Yara Rabia Helaly

PhD, Oral and Maxillofacial Radiology Department, Faculty of Dentistry, Cairo University, Egypt

ABSTRACT

Objective: The goal of this study was to use cone-beam computed tomography (CBCT) images to analyze the association of maxillary sinus mucosal lining thickness (MT) with various dental problems.

Material and method: CBCT scans of 159 cases (92 females and 67 males) with a mean age of (38.30± 13.69) years were collected from the patient's database of Oral and Maxillofacial Radiology Department, Faculty of Dentistry, Cairo University, Egypt, and retrospectively evaluated. The second premolar, first and second molar were evaluated for the presence of a periapical lesion, root canal filling, periodontal bone loss, caries, and dental filling. Sinus mucosal thickening was classified into 5 grades; 1. MT less than 1 mm; 2. 1- 3 mm; 3. 3- 6 mm; 4. 6- 10 mm and 5. More than 10mm.

Results: Associations between MT occurrence and different demographic and dental variables were all statistically not significant ($p>0.05$). A binomial logistic regression showed that age, sex, presence of a periapical lesion, and dental caries all had a significant effect on MT occurrence ($p<0.05$).

Conclusion: This study's findings revealed that maxillary sinuses mucosal lining are influenced by various dental conditions and that the prevalence of MT has a direct positive association with age, presence of a periapical lesion, dental caries, and higher in males.

Key Words: CBCT, Maxillary sinus, Mucosal thickening, Periapical lesion

Received: 22 April 2022, **Accepted:** 26 June 2022.

Corresponding Author: Yara Rabia Helaly ,PhD, Oral and Maxillofacial Radiology Department, Faculty of Dentistry, Cairo University, Egypt, **Tel :** 0235844038, **Mobile:** 01001929701, **E-mail:** yara.helaly@dentistry.cu.edu.eg

ISSN: 2090-097X, April 2022, Vol. 13, No. 2

INTRODUCTION

Many medical specialists, particularly those in the fields of maxillofacial surgery, otorhinolaryngology, and dentistry, are undoubtedly interested in the paranasal sinuses. Ancient Egyptians were the first to discover paranasal sinuses within the bones of the skull and later Greek physicians [1]. The maxillary sinus is the largest and first to form of the paranasal sinuses. It is a cavity in the maxillary bones that is filled with air with the size, shape, and wall thickness that diverges from one person to another, as well as between the two sides of the same person [2,3,4].

The maxillary sinus is a pyramid-shaped structure with a base that faces the nasal wall and a lateral tip that extends into either the zygomatic process of the maxillary bone or the zygoma. The sinus extends anteriorly to the canine and premolar areas and the orbital floor forms the roof. The maxillary alveolar process, with varying extension towards the alveolar ridge and close proximity to the posterior maxillary teeth, forms the floor. [3,5].

The maxillary sinus communicates with the nasal cavity via an ostium on the lateral wall of the nasal cavity. The Schneiderian membrane, sinus lining, or sinus mucosal lining, is a mucus-producing pseudostratified ciliated columnar epithelium that is continuous with the nasal mucosal lining through the ostium. [4,5,6,7].

Schneiderian membrane thickness typically ranges from 0.13mm to 0.5mm which cannot be detected radiographically unless thickening occurs due to inflammation or any other causative factor.

Schneiderian membrane inflammation can be a result of a variety of reasons such as upper respiratory tract infections, immunodeficiency, asthma, foreign body inhalation, irritants, and also different dental conditions and procedures due to the proximity between the maxillary sinus floor and the posterior maxillary teeth

root apices. Many researchers have used various approaches, such as skull remains examinations, computed tomography (CT), and cone-beam computed tomography (CBCT) to determine the thickness of the Schneiderian membrane. [8,9].

In oral and maxillofacial surgery, an accurate examination of the maxillary sinus is critical and also in various dental branches. Computed tomography (CT) is considered the diagnostic method of choice and the gold standard for maxillary sinus examination [10].

Thanks to the introduction of CBCT with a lower radiation dose, a dramatic shift occurs in the use of CBCT for maxillary sinus examination [11].

Cone-beam computed tomography also offers high-resolution images, isotropic volumetric data, multiplanar images, highly accurate and reproducible linear, angular, volumetric measurements, and the possibility to limit imaging to specific areas of interest with further dose reduction [7,12-14].

The radiographic image of thickened mucosa appears as a well-defined radiopaque band, parallel to the sinus bony walls [9,15]. The thickening of the maxillary sinus mucosa is a typical observation in everyday dental practice in both symptomatic and asymptomatic patients. Pre-operative assessment of the maxillary sinus including the bony walls and the mucosal lining thickening is a mandatory step before any surgical procedure involving the posterior maxillary region [4].

According to Naitoh et al. 2009 sinus mucosal lining thickening may cause problems for surgeons when planning sinus floor elevation (SFE)[16]. Anavi et al. 2008 reported that treatment of any pathological condition that causes sinus lining inflammation is necessary before sinus lift augmentation which is usually performed when little bone height is available for implant insertion in the maxillary posterior region [5,17].

Due to the close proximity of the posterior teeth roots to the maxillary sinus floor, the odontogenic infection presents 10- 12% of the causes of maxillary sinusitis [18- 21]. Periapical abscesses, periodontal disease, dental trauma, teeth extraction, and dental implants are thought to enhance the risk of maxillary sinusitis [20].

Many studies were found in the literature searching for the association or the correlation of different dental conditions affecting the maxillary teeth approximating the maxillary sinus floor with mucosal sinus thickening in different populations [8, 22- 28], and only one study was found on Egyptian population [29].

Therefore, the present work aimed to study the association of maxillary sinus mucosal lining thickening with different dental conditions using cone-beam computed tomography in a sample of the Egyptian population.

MATERIALS AND METHODS

A cross-sectional study was performed as a retrospective analysis on CBCT scans of Egyptian patients seeking dental treatment. The scans were retrospectively collected from the database of Oral and Maxillofacial Radiology Department, Faculty of Dentistry, Cairo University, Egypt

in the period from May 2021 to October 2021. The age range of the patients was (20- 78 years). All the scans were acquired using the CBCT Planmeca Promax 3D MID (Proface) machine (Asentajankatu, Helsinki, Finland) with exposure parameters 90 kVp, 10 mA, 14 s, and 200 × 60 mm field of view with a 0.4 mm voxel size.

Sample size calculation was performed based on the association between periodontal disease and sinus mucosal thickening as the primary outcome. Depending on the results of Shahidi et al (2016) [30], the Odds Ratio for this association was 14.39 and the prevalence of patients with periodontal disease and mucosal thickening >1 mm was 52.2%. Using alpha (α) level of (5%), the minimum estimated sample size was 41 subjects. Sample size calculation was performed using G*Power version 3.1.9.2 software (Franz Faul, Universitat Kiel, Germany).

The calculated sample size was raised to 159 cases (92 females and 67 males) with mean age of (38.30±13.69) years, as increasing the sample size can cause a rise in the study power and a decrease of the degree of uncertainty [31].

The study included maxillary CBCT scans of Egyptians with known demographics (name, age, sex), as well as the reasons for scanning. The scans were of good clarity and clearly showed the inferior portion of the maxillary sinus, the maxillary sinus floor, the maxillary posterior teeth, and each left and right side must have at least one first and second molar or second premolar.

Any scan showing signs of non-odontogenic sinusitis, developmental problems, trauma, bony changes of cystic or neoplastic lesions in the posterior area of the maxilla and/or maxillary sinus, or scans with metallic artifacts obscuring the visibility of the maxillary posterior teeth or the inferior part and floor of the maxillary sinus were excluded.

The sample was divided into four age groups ≤ 30 , from 31-40, 41-50, > 50. Then the scans were coded, and the patients' age and sex were concealed from the author with the help of a colleague. Image analysis was performed using Planmeca Romexis Viewer Launcher version 4.6.2.R, installed on a personal computer. Corrected coronal and sagittal images with 0.4 mm thickness were used for assessment of the condition of the second premolar, first and second molar bilaterally as well as the thickness of the sinus mucosa related to each of the mentioned teeth.

Assessment of teeth condition: The targeted teeth were assessed for the following: if the tooth is present or missing, the presence of periapical lesion, the presence of root canal filling, the presence of periodontal bone loss and its severity, the presence of dental caries and the presence of dental filling.

The following steps were used to evaluate the periodontal condition: The normal alveolar crest was believed to be 2 mm apical to the cemento-enamel junction (CEJ)^[32]. The distance between the spot 2 mm apical to the CEJ and the crest of the alveolar bone was measured at the mesial and distal sides of each tooth. In addition, we divided periodontal bone loss into three categories: Mild: 25 percent bone loss, Moderate : 25-50 percent bone loss, and Severe: > 50 percent bone loss ^[24, 33, 34].

Assessment of mucosal thickening: The thickness of the mucosa was measured in millimeters from the sinus floor to the highest border perpendicular to the underlying bone ^[35] as shown in (Figure 1). Categorization was based on the classification proposed by Sheikhi ^[15]; this classification divided the MT into 5 classes; 1. MT less than 1 mm; 2. 1-3 mm; 3. 3-6 mm; 4. 6-10 mm and 5. More than 10 mm

A single investigator assessed all of the scans. The investigator assessed and measured 10 randomly selected scans twice on two distinct days to calibrate and determine intra-examiner reliability (mean difference = 0.011 _ 0.04 mm).

Finally, CBCT scan findings, including the teeth condition and mucosal membrane thickness for each tooth were tabulated in an Excel sheet with the demographic data, including age, gender and indication for scanning after unveiling the codes by the same colleague.

Statistical analysis

Numerical data were presented as mean and standard deviation values.

Categorical data were presented as frequency and percentage values and were analyzed using Fisher's exact test.

Binomial logistic regression analysis was used to study the effect of different variables on MT occurrence. The significance level was set at $p < 0.05$ within all tests. Statistical analysis was performed with R statistical analysis software version 4.1.2 for Windows ^[36].

RESULTS

Mucosal thickness was detected in 122(76.7%) cases, 25(20.5%) of which were found on the right side, 27(22.1%) were found on the left side and 70(57.4%) were found bilaterally.

The mucosal lining was 1-3 mm thick in 35(28.7%) cases, 3-6 mm in 34(27.9%) cases, 6-10 mm in 18(14.8%) cases and more than 10 mm thick in 35(28.7%) cases (Table 1). Associations between MT occurrence and different demographic and dental variables presented in table (2) and in figure (2) were all statistically not significant ($p > 0.05$).

A binomial logistic regression was performed to ascertain the effect of different demographic and dental variables on the occurrence of MT. The model was statistically significant, $\chi^2(11) = 22.66$, $p = 0.020$. It explained 13.3% (Nagelkerke R²) of the variance in MT occurrence and correctly classified (78.6%) of cases. Sensitivity was (97.5%), specificity was (16.2%), positive predictive value was (79.3%) and negative predictive value was (66.7%). Results of the model presented in table (3) showed that age, sex, presence of periapical lesion and dental caries all had a significant effect on MT occurrence ($p < 0.05$). It was found that a year increase in age increased the odds of MT by 1.05, males had 2.86 higher odds of having MT than females, presence of periapical lesion increased the odds of MT by 6.38, and the presence of dental caries increased the odds of MT by 2.87.

Table (1): Prevalence of MT

Measurement	Treatment	n	%
Incidence of MT (n=159)	No	37	23.3%
	Yes	122	76.7%
MT distribution (n=122)	Unilateral		
	Right	25	20.5%
	Left	27	22.1%
MT classification (n=122)	Bilateral	70	57.4%
	1-3 mm	35	28.7%
	3-6 mm	34	27.9%
	6-10 mm	18	14.8%
	More than 10 mm	35	28.7%

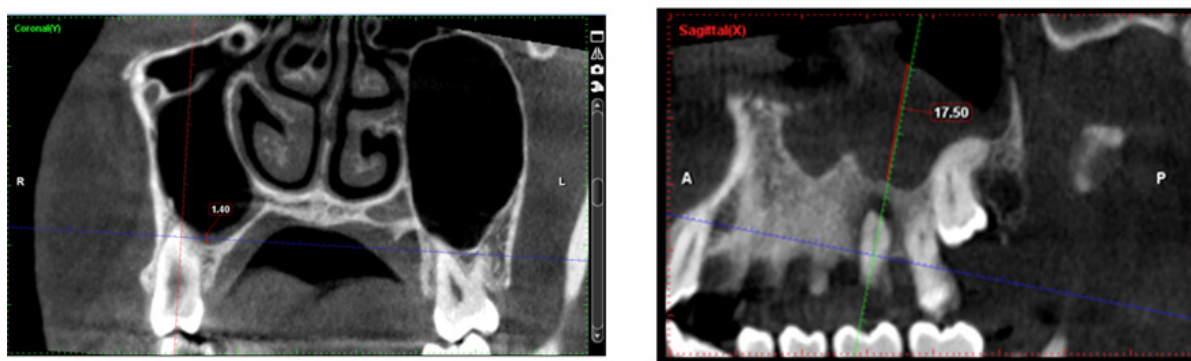
**Figure1:** Coronal and sagittal images showing measurement of the MT for two different scans.

Table (2): Association between MT occurrence and different demographic and dental variables

Parameter	Value	No MT		MT		p-value
		n	%	n	%	
Sex	Female	26	70.3%	66	54.1%	0.090
	Male	11	29.7%	56	45.9%	
Age	Less than or 30	16	43.2%	32	26.2%	0.077
	31-40y	12	32.4%	41	33.6%	
	41-50y	2	5.4%	25	20.5%	
Periodontitis	50 or more	7	18.9%	24	19.7%	0.432
	No	22	59.5%	82	67.2%	
	Yes	15	40.5%	40	32.8%	
Periodontitis severity	None	22	59.5%	82	67.2%	0.523
	Mild	4	10.8%	8	6.6%	
	Moderate	9	24.3%	21	17.2%	
RCT	Severe	2	5.4%	11	9.0%	1
	No	28	75.7%	93	76.2%	
Periapical lesion	Yes	9	24.3%	29	23.8%	0.057
	No	34	91.9%	94	77.0%	
Missing teeth	Yes	3	8.1%	28	23.0%	0.853
	No	17	45.9%	54	44.3%	
Dental filling	Yes	20	54.1%	68	55.7%	1
	No	31	83.8%	101	82.8%	
Dental caries	Yes	6	16.2%	21	17.2%	0.061
	No	26	70.3%	64	52.5%	
	Yes	11	29.7%	58	47.5%	

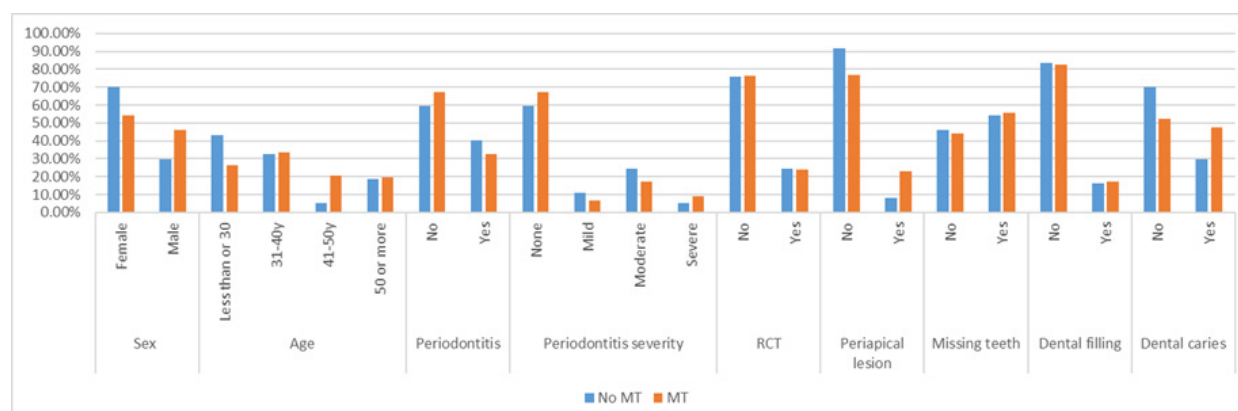


Figure (2): Bar chart showing the association between MT occurrence and different demographic and dental variables.

Table (3): Regression analysis

Variables	Regression coefficient	SE	Wald	df	Odds ratio	Odds ratio 95%CI		p-value
						Lower	Upper	
								0.028*
Age	0.05	0.02	4.81	1	1.05	1.01	1.09	0.021*
Sex (Male) ¹	1.05	0.45	5.34	1	2.86	1.17	6.98	0.018*
Periapical lesion (Yes) ²	1.85	0.79	5.56	1	6.38	1.37	29.77	0.585
Periodontitis (Yes) ²	-0.55	1.01	0.30	1	0.58	0.08	4.17	0.819
Periodontitis severity	-0.11	0.50	0.05	1	0.89	0.34	2.37	0.022*
Dental caries (Yes) ²	1.05	0.46	5.28	1	2.87	1.17	7.06	0.973
Dental filling (Yes) ²	-0.02	0.59	0.00	1	0.98	0.31	3.11	0.728
Missing teeth (Yes) ²	-0.17	0.50	0.12	1	0.84	0.32	2.23	0.114
RCT (Yes) ²	-0.93	0.59	2.50	1	0.40	0.13	1.25	0.114

SE=Standard error; df=degree of freedom; CI = confidence interval; *, significant ($p \leq 0.05$) 1-Female is reference category, 2- No or absence is reference category

DISCUSSION

This study was planned to assess the association of maxillary sinus mucosal lining thickening with different dental conditions using CBCT. CBCT scans were chosen according to the inclusion and exclusion criteria previously mentioned in the methodology chapter. The age of the patients who took part in the research started from 20 years because it is the estimated age when the maxillary sinus growth stops [3,6], further second premolar, first and second molar teeth were chosen for assessment due to their close approximation to the sinus floor [3,37,38].

Different cutoff values for mucosal thickness were used by authors in the literature. Savolainen et al considered mucosal thickening if more than 6mm and Vallo et al considered mucosal thickening starting from 3-6mm but both studies were using Waters' view and panoramic radiographs respectively [39, 40]. Later studies performed on CBCT images used different values; Ren et al followed by Lathiya et al considered mucosal thickening greater than or equal to 2mm to be pathologic while Janner et al, Yoo et al, Lu et al, Shanbhag et al, Bulut et al and Aksoy et al used more than 2mm as the starting point for their measurements [8, 24, 25,28, 35,41-43]. Shahidi et al considered MT greater than 1mm in their study [30].

The mucosal lining of the paranasal sinuses is generally less than 1mm thick and cannot be seen on imaging. When the mucosa thickens as a result of inflammation, it can expand in thickness by 10 to 15 times, which can be seen on imaging. Our study considers mucosal thickness equal to or more than 1 mm based on this conclusion [9, 29, 34,44,45]. The severity is classified into four groups as follows: (1-3 mm), (3-6 mm), (6-10 mm) and more than 10 mm as proposed by Sheiki et al 2014 [15].

Regarding the prevalence of MT; studies that used the same value for MT measurements showed different results. Ezzat et al found that 68 % of patients have MT which is considered an almost similar to our results which may be due to that both studies were on Egyptian population but caution should be considered when applying this result on Egyptians as our study considered the tooth as a unit of analysis during measurements while Ezzat et al consider the patient as a unit of analysis and based on Scheutz et al; The choice of unit of analysis can have a significant impact on the outcome of statistical studies and, as a result, the research conclusion [29, 46]. The same cause in addition to the different populations studied may be the explanation of the different results of Phothikhun et al. who found MT in 42% of patients and Sheiki et al who found MT in 39.4% of patients although the same definition of MT was used by the four studies [15,34].

Binomial logistic regression of our results demonstrated that sex had a significant effect on MT occurrence with males had 2.86 higher odds of having MT than females. This agrees with the results of many papers who found higher prevalence of MT among males [12,15,30,34,35,41-43,47-49]. They attributed their result to the higher frequency of pathologic dental findings in males than females which leads to irritation of the sinus mucosa. Pazera et al, reported that there was no difference between the two genders in mucosal thickening [50]. The variance between our result and the other studies may be due to different populations, different selection criteria of the sample, ethnic differences among the studied populations and differences in the indications of CBCT scans that were included in the study.

Regarding the effect of age on MT, similar results have been reported previously by Aksoy & Orhan, Goller-Bulut et al, Lathiya et al, Shahidi et al Phothikhun et al, Lu et al and Shanbhag et al who found a significant association between age and sinus MT.

As age increase, the prevalence of MT increase and this may be accredited to the cumulative effect of irritations and dental diseases as the age increase and to the effect of pneumatization which increases with age leading to the spread of infection to the maxillary sinus through the porous maxillary bone, causing mucosal thickening [8,24,28,30,34,42,43].

However, there are also some contrary results; Rege et al, Nascimento et al detected no influence of age on the occurrence of sinus abnormalities [13,26]. This may be clarified by the findings of Tian et al who found that the distances from maxillary premolars and molars to the neighboring border of the sinus floor increased with age and consequently MT in elderly people may not be related to dental conditions [51]. The dissimilarities between the studies may be due to different classification of MT, different age grouping of the sample and difference in the distance between the teeth root apex and sinus floor between individuals that leads to the same dental condition may have different effects according to the location of the dental problem.

According to the current study's findings, there was a non-statistically significant association between periodontal bone loss and MT. This was in agreement with Janner et al and Sakir & Ercalik [35,52]. Patients free of periodontitis 82(67.2%) had a higher percentage of MT occurrence than periodontitis cases 40(32.8%). Among periodontitis cases, cases with moderate periodontitis had the highest MT incidence 21(17.2%). In contradiction of our results, Shahidi et al and Sheiki et al found a significant association between PBL and sinus MT but Shahidi et al found that there was no significant correlation between periodontal disease severity and sinus MT [15,30].

Phothikhun et al, Ren et al and Goller-Bulut et al found a significant association between periodontal disease and sinus MT [24,25,34]. Phothikhun et al, Ren et al, Goller-Bulut et al and Ezzat et al found a positive correlation between MT and degree of PBL [24,25,29,34]. The literature's findings for such an association are controversial, which could be related to discrepancies in the definitions of MT and periodontal disease, as well as their severity.

We showed that there was a non-statistically significant association between root canal treatment and MT. Cases that were not endodontically treated had higher percentage of MT occurrence 93(76.2%) than cases with RCT 29(23.8%). This is in agreement with Phothikhun et al and Janner et al [34,35]. In contrary to Shahidi et al who significantly observed MT in patients with root canal filling [30]. This dissimilarity may be attributed to those studies didn't consider the history of the endodontically treated tooth, quality of endodontic filling and proximity of the root tip to the sinus floor.

The presence of dental fillings was found to be associated with MT in a non-statistically significant way. Cases with no dental fillings had higher percentage of MT occurrence 101(82.8%) than cases with fillings 21(17.2%). Our result was in agreement with Shahidi et al who conveyed no significant association between dental fillings and the frequency of MT and against Goller-Bulut et al who reported that teeth with crowns was significantly related with MT [24,30]. This contradiction may be due to that during image analysis, any tooth with no dental filling was ranked as 'absent' in the excel sheet without taking into consideration whether it is intact tooth or affected by any other dental problems.

Resembling the present study Aksoy et al, Sheiki et al, Goller-Bulut et al, Ezzat et al, Lu et al, Shanbang et al, Sakir & Ercalik and Bornstein et al found that mucosal thickening was more frequently observed in relation to teeth with periapical lesions and dental caries [8,15,24,29,42,43,52,53]. This finding may be attributed to tissue damage after pulp necrosis and bacterial invasion to the maxillary sinuses that become a possible source of sinus mucosal inflammation. This is in contrary to Rege et al, Phothikhun et al and Janner et al who found that periapical lesions were not associated with mucosal thickening of the maxillary sinus [13,34,35]. This dissimilarity might be accredited to differences in race or age, carious lesion, periapical lesion sizes and proximity of periapical lesion to the sinus floor.

Few studies were found studying the association between missing maxillary posterior teeth and sinus MT. Our results are consistent with, Aksoy et al and Block and Dastoury who reported that removal of problematic teeth reduced, but did not totally alleviate, sinus membrane thickening [8,54]. It might be one of the reasons for the increased occurrence of MT in edentulous maxilla or that the patient had periapical illnesses that

caused maxillary sinus mucositis prior to extraction. Yoo et al reported that the thickness of the sinus mucosa at the sites of tooth extraction due to periodontal disease was found to be higher than at the sites of tooth extraction due to pulpal disease and tooth fracture [41]. In our retrospective study, we had no data about the patient's case history including history of non-odontogenic sinusitis or history of missing teeth, so future studies with reporting the teeth status before extraction and the condition of sinus mucosa after extraction is highly recommended. Additionally, we lacked clinical data on the teeth's periodontal and periapical conditions, there was no sinus examination or survey available for the individual's sinus condition, and the patient group was limited to a single institution.

CONCLUSION

Within the scope of this study's limitations, thickening of the mucosa of the maxillary sinus was prevalent among dental patients. When reviewing regular patient imaging scans, a thorough interpretation of the total volume acquired in CBCT images, including the entire maxillary sinus, is crucial for the dentomaxillofacial radiologist. Multiple conditions like age, sex, periodontal status, periapical status and presence of caries should also be considered during the examination and subsequent treatment planning by the surgeon due to their effect on the mucosal sinus lining.

ACKNOWLEDGMENT

I would like to express my gratitude to all members of Oral and Maxillofacial Radiology Department, Faculty of Dentistry, Cairo University, for their support.

CONFLICTS OF INTEREST

There are no conflicts of interest.

REFERENCES

- 1- Mavrodi A, Paraskevas G. Evolution of the paranasal sinuses' anatomy through the ages. *Anat Cell Biol* 2013; 46:235-238.
- 2- Koymen R, Gocmen-Mas N, Karacayli U, Ortakoglu K, Ozan T, and Yazici A.C, Anatomic evaluation of maxillary sinus septa: surgery and radiology. *Clin Anat*, 2009 Jul; 22(5):563-570.
- 3- Dehghani M, Motallebi E, Navabazam A, Montazerlotfelahi H, Ezoddini F, Sahar Ghanea S. The Relation Between Maxillary Sinus Floor and Posterior Maxillary Teeth Roots Using Panoramic and Cone Beam Computed Tomography. *J Dentomaxillofac Radiol Pathol Surg*. 2017; 6(3):49-60.

- 4- Kalyvas D, Kapsalas A, Paikou S, Tsiklakis K. Thickness of the Schneiderian membrane and its correlation with anatomical structures and demographic parameters using CBCT tomography: a retrospective study. *Int J Implant Dent*. 2018 Oct 19;4(1):32.
- 5- Al-Salman WT, Almas K. Maxillary sinus and success of dental implants: an update. *Gen Dent*. 2015 Jul-Aug;63(4):47-54.
- 6- Iwanaga J, Wilson C, Lachkar S, Tomaszewski KA, Walocha JA, Tubbs RS. Clinical anatomy of the maxillary sinus: application to sinus floor augmentation. *Anat Cell Biol*. 2019 Mar;52(1):17-24.
- 7- Najem SS, Safwat WM, ELAziz RA, Gaweesh YS. Maxillary sinus assessment for gender and age determination using cone beam computed tomography in an Egyptian sample. *Alex. dent. J* 2021 Aug;46(2): 63-69.
- 8- AksoyU,OrhanK.Association between odontogenic conditions and maxillary sinus mucosal thickening: a retrospective CBCT study. *Clin Oral Investig*. 2019 Jan;23(1):123-131.
- 9- White SC, Pharoah MJ. *Oral Radiology principles and interpretation*. 9th ed. St. Louis: Mosby Elsevier; 2009: 506-512.
- 10- Fatterpekar GM, Delman BN, Som PM. Imaging the paranasal sinuses: where we are and where we are going. *Anat Rec (Hoboken)*. 2008 Nov;291(11):1564-1572.
- 11- Ilgüy D, Ilgüy M, Dolekoglu S, Fisekcioglu E. Evaluation of the posterior superior alveolar artery and the maxillary sinus with CBCT. *Braz Oral Res*. 2013 Sep-Oct;27(5):431-437.
- 12- Ritter L, Lutz J, Neugebauer J, Scheer M, Dreiseidler T, Zinser MJ, Rothamel D, Mischkowski RA. Prevalence of pathologic findings in the maxillary sinus in cone-beam computerized tomography. *Oral Surg Oral Med Oral Pathol Oral Radiol Endod* 2011;111: 634-640.
- 13- Rege IC, Sousa TO, Leles CR, Mendonça EF. Occurrence of maxillary sinus abnormalities detected by cone beam CT in asymptomatic patients. *BMC Oral Health*. 2012 Aug 10; 12:30.
- 14- Luz J, Greutmann D, Wiedemeier D, Rostetter C, Rücker M, Stadlinger B. 3D-evaluation of the maxillary sinus in cone-beam computed tomography. *Int J Implant Dent*. 2018 Jun 5;4(1):17.
- 15- Sheikhi M, Pozve NJ, Khorrami L. Using cone beam computed tomography to detect the relationship between the periodontal bone loss and mucosal thickening of the maxillary sinus. *Dent Res J (Isfahan)*. 2014 Jul;11(4):495-501.
- 16- Naitoh M, Suenaga Y, Kondo S, Gotoh K, Arijji E. Assessment of maxillary sinus septa using cone-beam computed tomography: etiological consideration. *Clin Implant Dent Relat Res*. 2009 Oct;11 (1): e52-58.
- 17- Anavi Y, Allon DM, Avishai G, Calderon S. Complications of maxillary sinus augmentations in a selective series of patients. *Oral Surg Oral Med Oral Pathol Oral Radiol Endod*. 2008 Jul;106(1):34-38.
- 18- Eberhardt JA, Torabinejad M, Christiansen EL. A computed tomographic study of the distances between the maxillary sinus floor and the apices of the maxillary posterior teeth. *Oral Surg Oral Med Oral Pathol*. 1992 Mar;73(3):345-346.
- 19- van den Bergh JP, ten Bruggenkate CM, Disch FJ, Tunizing DB. Anatomical aspects of sinus floor elevations. *Clin Oral Implants Res*. 2000 Jun;11(3):256-265.
- 20- Kretzschmar DP, Kretzschmar JL. Rhinosinusitis: review from a dental perspective. *Oral Surg Oral Med Oral Pathol Oral Radiol Endod*. 2003 Aug;96(2):128-135.
- 21- Jang JK, Kwak SW, Ha JH, Kim HC. Anatomical relationship of maxillary posterior teeth with the sinus floor and buccal cortex. *J Oral Rehabil*. 2017 Aug;44 (8):617-625.
- 22- Bornstein MM, Wasmer J, Sendi P, Janner SF, Buser D, von Arx T. Characteristics and dimensions of the Schneiderian membrane and apical bone in maxillary molars referred for apical surgery: a comparative radiographic analysis using limited cone beam computed tomography. *J Endod*. 2012 Jan;38(1):51-57.
- 23- Block MS, Dastoury K. Prevalence of sinus membrane thickening and association with unhealthy teeth: a retrospective review of 831 consecutive patients with 1,662 cone-beam scans. *J Oral Maxillofac Surg*. 2014 Dec;72(12):2454-260.
- 24- Goller-Bulut D, Sekerci AE, Köse E, Sisman Y. Cone beam computed tomographic analysis of maxillary premolars and molars to detect the relationship between periapical and marginal bone loss and mucosal thickness of maxillary sinus. *Med Oral Patol Oral Cir Bucal*. 2015 Sep 1;20(5): e572-579.
- 25- Ren S, Zhao H, Liu J, Wang Q, Pan Y. Significance of maxillary sinus mucosal thickening in patients with periodontal disease. *Int Dent J*. 2015 Dec;65(6):303-310.
- 26- Nascimento EH, Pontual ML, Pontual AA, Freitas DQ, Perez DE, Ramos-Perez FM. Association between Odontogenic Conditions and Maxillary Sinus Disease: A Study Using Cone-beam Computed Tomography. *J Endod*. 2016 Oct;42(10):1509-1515.

- 27- Khorshidi H, Shahidi S , Ghapanchi J , Raoofi S ,Paknahad M ,Daloiee NK ,Zamani A. The Association Between Maxillary Sinus Mucosal Thickening and Periapical Radiolucency Using Cone-Beam Computed Tomography Scanning: A Retrospective Study. *Journal of Dentomaxillofacial Radiology Pathology and Surgery* 5(3):5-10.
- 28- Lathiya VN, Kolte AP, Kolte RA, Mody DR. Analysis of association between periodontal disease and thickness of maxillary sinus mucosa using cone beam computed tomography - A retrospective study. *Saudi Dent J.* 2019 Apr;31(2):228-235.
- 29- Ezzatt OM, El Demerdash FH and Ashmawy MS. correlation between gingival biotype, marginal bone loss, periapical infection and schneiderian membrane thickness in chronic periodontitis patients (a cross-sectional study using cone-beam computed tomography analysis). *E.D.J.* 2018; 2: 1305-1314.
- 30- Shahidi S , Zamiri B ,kiany F , Panahi R. Evaluation of the Association of Sinus Mucosal Thickening with Dental and Periodontal Status Using Cone Beam Computed Tomographic Imaging. *Journal of Dentomaxillofacial Radiology, Pathology and Surgery.* 2016; (5)2: 33-39.
- 31- Suresh K, Chandrashekar S. Sample size estimation and power analysis for clinical research studies. *J Hum Reprod Sci* 2012; 5: 7-13.
- 32- Scarfe WC, Farman AG, Sukovic P. Clinical applications of cone beam computed tomography in dental practice.. *J Can Dent Assoc.* 2006 Feb;72(1):75-80.
- 33- Newman MG, Takei HH, Klokkevold PR, Carranza FA. *Clinical Periodontology.* 11th ed. St. Louis: Elsevier Saunders; 2012. p. 160-161.
- 34- Phothikhun S, Suphanantachat S, Chuenchompoonut V, Nisapakultorn K. Cone-beam computed tomographic evidence of the association between periodontal bone loss and mucosal thickening of the maxillary sinus. *J Periodontol.* 2012 May;83(5):557-564.
- 35- Janner SF, Caversaccio MD, Dubach P, Sendi P, Buser D, Bornstein MM. Characteristics and dimensions of the Schneiderian membrane: a radiographic analysis using cone beam computed tomography in patients referred for dental implant surgery in the posterior maxilla. *Clin Oral Implants Res.* 2011 Dec;22(12):1446-1453.
- 36- R Core Team (2021). R: A language and environment for statistical computing. R Foundation for Statistical Computing, Vienna, Austria. URL <https://www.R-project.org/>.
- 37- Eberhardt JA, Torabinejad M, Christiansen EL. A computed tomographic study of the distances between the maxillary sinus floor and the apices of the maxillary posterior teeth. *Oral Surgery, Oral Medicine, Oral Pathology.* 1992; 73(3):345– 347.
- 38- Kwak HH, Park HD, Yoon HR, Kang MK, Koh KS, Kim HJ. Topographic anatomy of the inferior wall of the maxillary sinus in Koreans. *International Journal of Oral and Maxillofacial Surgery.* 2004; 33(4):382–388.
- 39- Savolainen S, Eskelin M, Jousimies-Somer H, Ylikoski J. Radiological findings in the maxillary sinuses of symptomless young men. *Acta Otolaryngol Suppl* 1997; 529:153-157.
- 40- Vallo J, Suominen-Taipale L, Huuonen S, Soikkonen K, Norblad A. Prevalence of mucosal abnormalities of the maxillary sinus and their relationship to dental disease in panoramic radiography: Results from the health 2000 health examination survey. *Oral Surg Oral Med Oral Pathol Oral Radiol Endod* 2010;109: E80-87.
- 41- Yoo JY, Pi SH, Kim YS, Jeong SN, You HK. Healing pattern of the mucous membrane after tooth extraction in the maxillary sinus. *J Periodontal Implant Sci.* 2011 Feb;41(1):23-29.
- 42- Lu Y, Liu Z, Zhang L, Zhou X, Zheng Q, Duan X, Zheng G, Wang H, Huang D. Associations between maxillary sinus mucosal thickening and apical periodontitis using cone-beam computed tomography scanning: a retrospective study. *J Endod.* 2012 Aug;38(8):1069-1074.
- 43- Shanbhag S, Karnik P, Shirke P, Shanbhag V. Association between periapical lesions and maxillary sinus mucosal thickening: a retrospective cone-beam computed tomographic study. *J Endod.* 2013 Jul;39(7):853-857.
- 44- Worth HM, Stoneman DW. Radiographic interpretation of antral mucosal changes due to localized dental infection. *J Can Dent Assoc (Tor).* 1972 Mar;38(3):111-116.
- 45- Misch CE, Resnik RR, Misch-Dietsh F. Maxillary sinus anatomy, pathology, and graft surgery. In: Misch CE, ed. *Contemporary Implant Dentistry.* St. Louis: Mosby; 2008:912-922.
- 46- Scheutz F, Frydenberg M, Matee MI, Poulsen S. The effect of choosing different units of analysis when estimating risk of presence of dental caries in the primary dentition. *Community Dent Health.* 2003 Mar;20(1):27-33
- 47- Brüllmann DD, Schmidtman I, Hornstein S, Schulze RK. Correlation of cone beam computed tomography (CBCT) findings in the maxillary sinus with dental diagnoses: a retrospective cross-sectional study. *Clin Oral Investig.* 2012 Aug;16(4):1023-1029.

48- Cakur B, Sümbüllü MA, Durna D. Relationship among Schneiderian membrane, Underwood's septa, and the maxillary sinus inferior border. *Clin Implant Dent Relat Res*. 2013;15(1):83–87.

49- Yildirim TT, Güncü GN, Göksülük D, Tözüm MD, Colak M, Tözüm TF. The effect of demographic and disease variables on Schneiderian membrane thickness and appearance. *Oral Surg Oral Med Oral Pathol Oral Radiol*. 2017; 124:568–576.

50- Pazera P, Bornstein MM, Pazera A, Sendi P, Katsaros C. Incidental maxillary sinus findings in orthodontic patients: a radiographic analysis using cone beam computed tomography (CBCT). *Orthod Craniofac Res*. 2011;14:17–24.

51- Tian XM, Qian L, Xin XZ, Wei B, Gong Y. An analysis of the proximity of maxillary posterior teeth to the maxillary sinus using cone-beam computed tomography. *J Endod* 2016; 42:371–377.

52- Sakir M, Ercalik Yalcinkaya S. Associations between Periapical Health of Maxillary Molars and Mucosal Thickening of Maxillary Sinuses in Cone-beam Computed Tomographic Images: A Retrospective Study. *J Endod*. 2020 Mar;46(3):397-403

53- Bornstein MM, Wasmer J, Sendi P, Janner SF, Busser D, von Arx T. Characteristics and dimensions of the schneiderian membrane and apical bone in maxillary molars referred for apical surgery: a comparative radiographic analysis using limited cone beam computed tomography. *J Endod*. 2012; 38:51–57.

54- Block MS, Dastoury K. Prevalence of sinus membrane thickening and association with unhealthy teeth: a retrospective review of 831 consecutive patients with 1,662 cone-beam scans. *J Oral Maxillofac Surg* 2014; 72:2454–2460.