

## HISTOPATHOLOGICAL CHANGES IN HEART AND LUNG OF ALBINO RAT TREATED WITH MACHETE HERBICIDE

Khidr, Fatma K.

Plant Protection Res. Institute, Agric. Res. Center, Dokki-Giza, Egypt

### ABSTRACT

The present study aims to illustrate the histopathological effect of 1/4 LD<sub>50</sub> oral administration of herbicide Machete on heart and lung of albino rats at intervals 1, 2, 3, 4 and 5 weeks post-treatment. Significant decrease in body weight were recorded, while a significant increase were recorded in heart and lung weight comparing with control. Also, significant decrease in the number of erythrocytes, leucocytes, haemoglobin level, haematocrit value and packed cell volume were observed. Concerning the histopathological changes in heart, there was oedema, inflammatory cells infiltration in the subendocardial tissue and the myocardial blood vessels were hyperemic, while changes in lung, there was lymphoid cells aggregation with hyperemic blood vessels in association with the presence of alveolar emphysema in diffuse manner. Perivascular lymphoid cells aggregation and peribronchiolar lymphoid hyperplasia were observed.

### INTRODUCTION

The development of industry and agriculture in Egypt has produced significant improvement in the standard of living in the country. However, it has also resulted in chemical pollution which if unchecked could threaten human health as well as national production.

The use of insecticides, herbicides, fungicides, nematicides, rodenticides and molluscicides (the most important chemical pollution) had recently increased for agriculture and public health purposes. The application of these pesticides in soils will potentially lead to changes in the population of soil invertebrates either directly or indirectly (Edwards and Thompson, 1973).

The objective of the present study is to clarify the histological abnormalities that had occurred in heart and lung of albino rat treated with 1/4 LD<sub>50</sub> herbicide Machete oral administration.

### MATERIALS AND METHODS

#### Chemical compound :

Butachlor (Machete) herbicide was obtained from Monsanto Co.

#### Chemical name :

N-butoxymethyl-2-chloro-2, 6- dimethylacetanilide.

LD<sub>50</sub> for rat 2000 mg/kg body weight.

Dosage 1/4 LD<sub>50</sub> oral administration was used daily for 5 weeks.

#### Experimental animals :

30 male albino rat, 120-150 g body weight were obtained from Helwan Breeding Station, Cairo, Egypt. The animal were given standard diet and water *ad libitum*, 5 animal left as control and the rest were given 1/4 LD<sub>50</sub> oral administration daily then 5 rats were sacrificed by decapitation at intervals 1, 2, 3, 4 and 5 weeks post-treatment. The heart and lung were weighed incised and immediately fixed in 10 % formal saline. Samples were embedded in the same paraffin block, sections were cut at 5 µm thickness, mounted on clean

glass slides and stained using Haematoxylin and eosin. The tissue sections were examined under light microscopy for histological evaluation. For haematology, red blood cell count, white blood cell count, haemoglobin content, haematocrite, P.C.V. were determined according to Schalm *et al.* (1975). Miller (1960), Wintrobe (1934) and Levinson and Mac Fate (1956), respectively.

## RESULTS

### Body and organ weight :

Results of the effects of 1/4 LD<sub>50</sub> daily oral administration of herbicide Machete on body, heart and lung weight of albino rat are recorded in Table (1). The body weight was significant decrease allover the tested periods, while heart and lung showed a slightly increase when compared with control through all intervals of the experiment except the heart weight showed significantly decrease at 5 week post-treatment.

**Table (1) : Effect 1/4 LD<sub>50</sub> of herbicide Machete) on nody, heart and lung weight of albino rat.**

Parameter	Control	Weeks post-treatment (mean ± S.E.)				
	(mean±S.E.)	One	Two	Three	Four	Five
Body weight (g)	149.4 ±1.6	133.8 ±1.9**	134.2 ±1.8**	136.8 ±3.0*	116.0 ±2.1**	110.0 ±2.3**
Heart (g)	0.58 ±0.04	1.42 ±0.01***	1.08 ±0.04***	1.45 ±0.02***	1.17 ±0.02**	0.45 ±0.01**
Lung (g)	0.88 ±0.07	1.50 ±0.01*	1.43 ±0.01*	0.98 ±0.01	1.21 ±0.02	1.76± 0.01**

Data are expressed as mean ± S.E. of 5 rats

\* Significant at P > 0.05

\*\* Significant at P > 0.01

\*\*\* Significant at P > 0.001

### Haematological changes :

Analysis of the results of the haematological parameters examined (Table, 2) show that the number of red blood cells, white blood cells, the haemoglobin content, haematocrite value and packed cell volume (PCV %), were decreased very highly significant after 1/4 LD<sub>50</sub> oral administration of herbicide Machete at 1<sup>st</sup> week post-treatment with % differences (78, 87, 43, 39 and 43, respec-tively). At second week, there were highly significantly increases but still decrease comparing with control as 70.5, 86.6, 39.3, 29.9 and 39.3, respectively, the same observation recorded at 3<sup>rd</sup> week, 4<sup>th</sup> week and 5<sup>th</sup> week the end of the test, where 43.1, 22.4 & 11.2; 75.7, 33.6 & 20.9; 29.9, 29.0 & 27.9; 32.3, 30.4 & 27.0 and 29.9, 28.9 & 27.9 respectively.

### Histological observation :

#### a- Heart :

Heart, the main organ of the body was affected by 1/4 LD<sub>50</sub> herbicide Machete (Fig. 2), there was oedema and inflammatory cells infiltration in the subendocardial tissue through the beginning of the test 1, 2 and 3 weeks, while at 4 weeks (Fig. 3) showed that the myocardial vessels were hyperemic and perivascular oedema occur. But at the end of the test 5 weeks there was no alteration observed when compared with control.

Table (2) : Effect of herbicide Machete (1/4 LD50) on haematological parameters of albino rats.

Para- meter	Control mean ±S.E.	Weeks post-treatment									
		One		Two		Three		Four		Five	
		Mean ±S.E.	% Diff.	Mean ±S.E.	% Diff.	Mean ±S.E.	% Diff.	Mean ±S.E.	% Diff.	Mean ±S.E.	% Diff.
R.B.Cs.	8080x10 <sup>3</sup> ±267.22	1726x10 <sup>3</sup> ±387.03	-78.64***	2382x10 <sup>3</sup> ±563.19	-70.5	4595x10 <sup>3</sup> ±555.43	-43.1	6264x10 <sup>3</sup> ±405.58	-22.4	7172x10 <sup>3</sup> ±308.39	-11.2
W.B.Cs.	7880 ±318.44	960 ±88.6	-87.82***	1050 ±134.17	-86.6***	1910 ±307.58	-75.7**	5230 ±611.7	-33.6*	6230 ±316.39	-20.9
Hb. %	87.4 ±1.54	49.8 ±1.66	-43.02***	53.0 ±4.64	-39.3**	61.2 ±6.77	-29.9*	62.0 ±5.01	-29.0*	63.0 ±0.29	-27.9
Ht. %	41.4 ±1.03	25.0 ±1.84	-39.61***	29.0 ±3.32	-29.9**	28.0 ±2.67	-32.3**	28.8 ±1.53	-30.4***	30.0 ±0.32	-27.0
P.C.V.	29.13 ±1.53	16.6 ±1.5	-43.0**	17.7 ±4.6	-39.2*	20.4 ±6.8	-29.9	20.7 ±5.0	-28.9	21.0 ±0.27	-27.9

Data are expressed as mean ± S.E. of 5 rat.

\* Significant P > 0.05

\*\* High significant P > 0.01

\*\*\* Highly significant P > 0.001  
non-significant P < 0.05

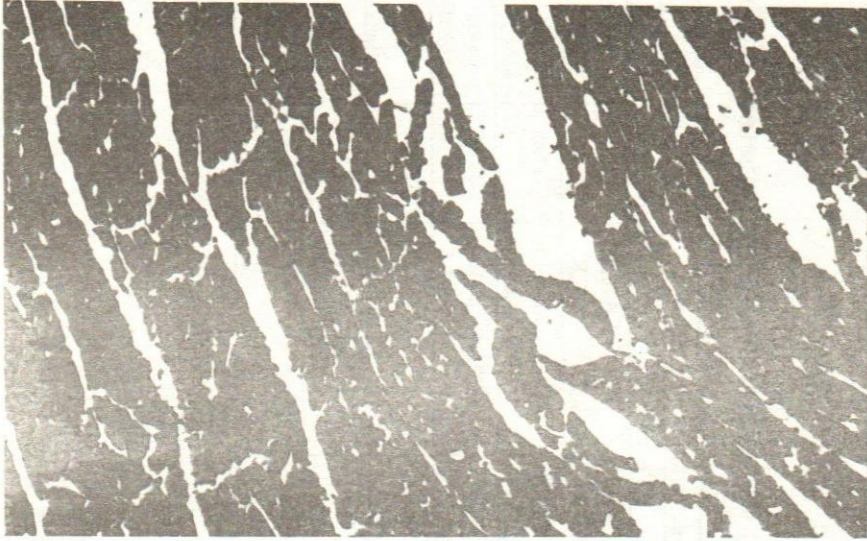


Fig. 1.- Heart of rat in control group.

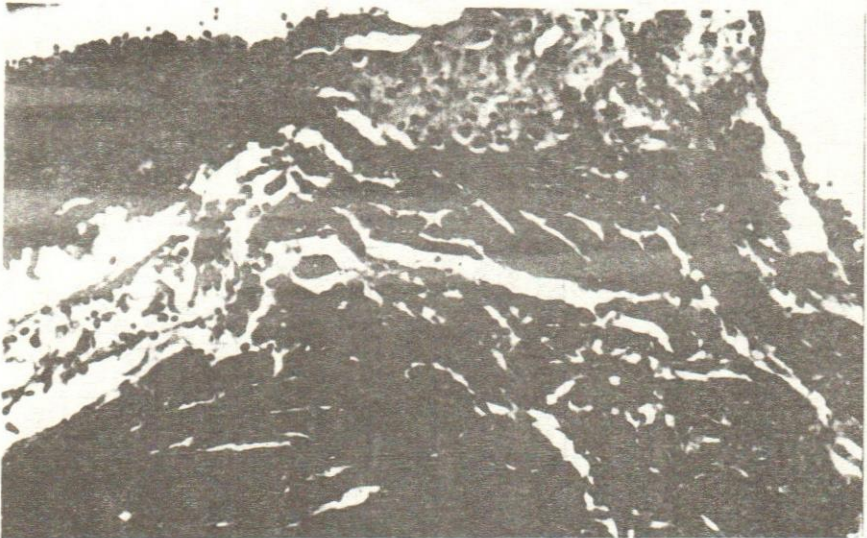
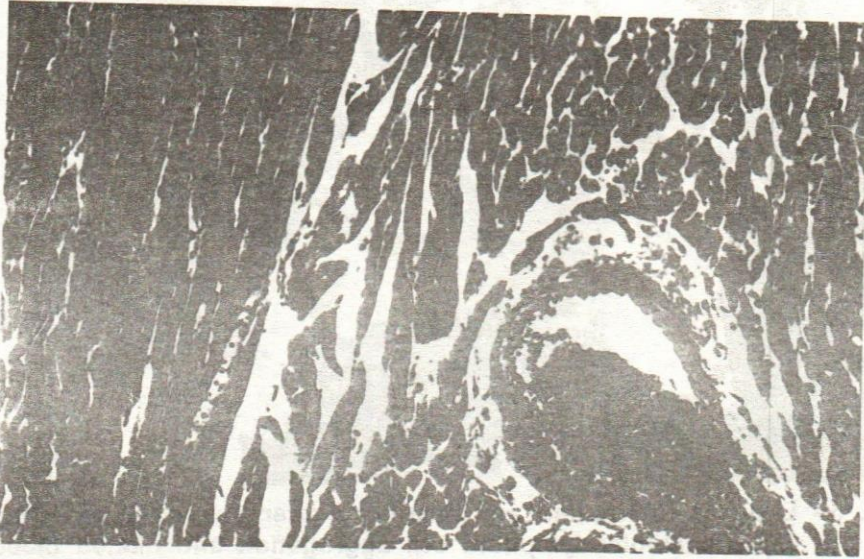
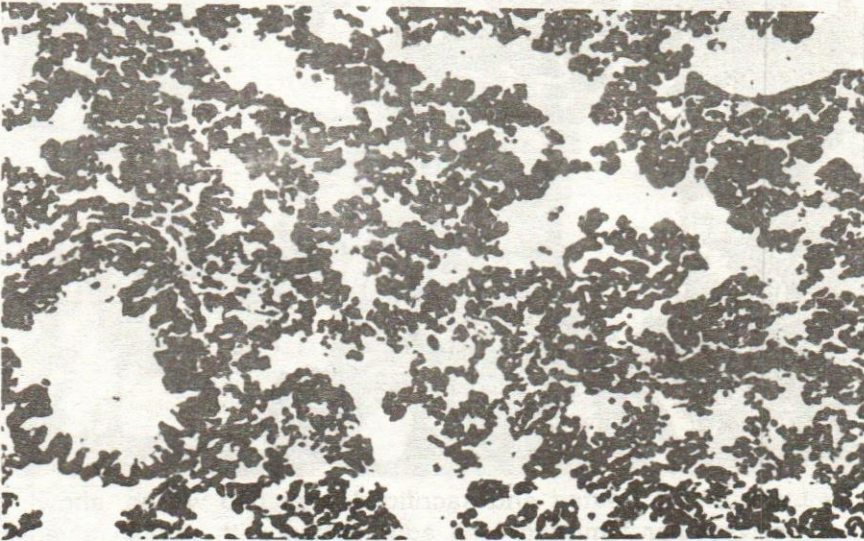


Fig. 2.- Heart of rat treated and sacrificed after one week showing oedema and inflammatory cells infiltration in the subendocardium tissue. (H & E : X40)



**Fig. 3.- Heart of rat treated and sacrificed after 4 weeks, showing hyperemic myocardial blood vessel with perivascular oedema. (H & E : X40)**



**Fig. 4.- Lung of rat in control group.**

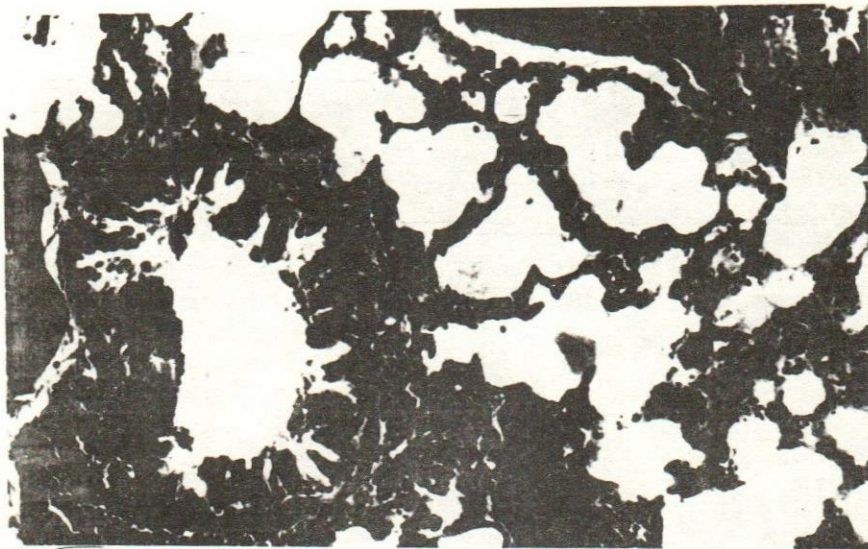


Fig. 5.- Lung of rat treated and sacrificed after one week, showing peribronchiolar lymphoid cell aggregation and dilated blood vessels and alveolar emphysema (H & E : X40)

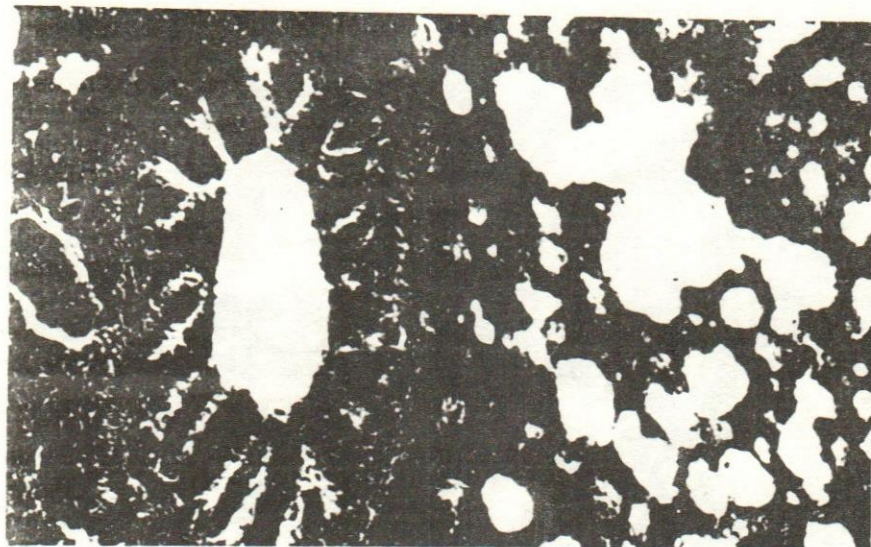
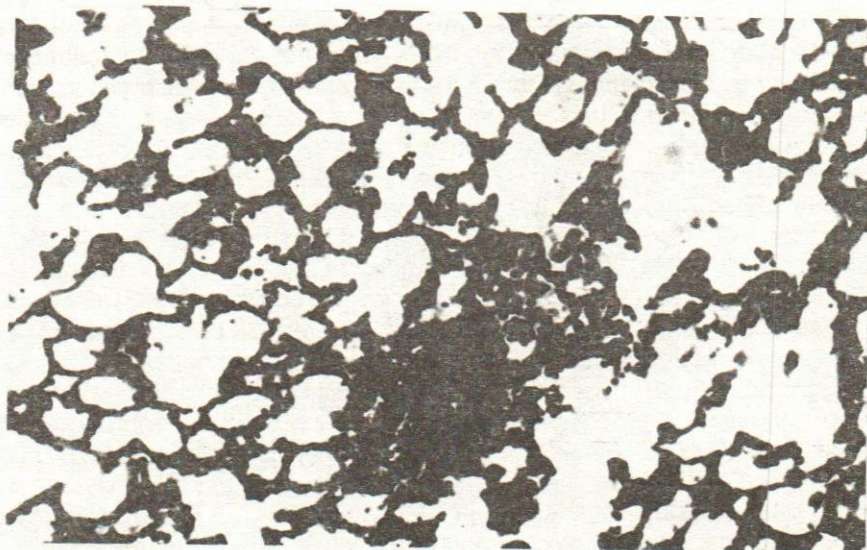


Fig. 6.- Lung of rat treated and sacrificed after two weeks, showing perivascular lymphoid cell aggregation with diffuse alveolar emphysema (H & E : X40)

**b- Lung :**

The peribronchiolar tissue showed lymphoid cells aggregation with hyperemic blood vessels in association with the presence of alveolar emphysema in diffuse manner (Fig. 4) at the 1st week of the test. Perivascular lymphoid cells aggregation was observed in association with diffuse alveolar emphysema (Fig. 5) at the 2nd week of the test, while at the 4th week of the experiment, there was collapse and consensatory emphysema of the air alveoli in association with bronchiolar hyperplasia (Fig. 6) when compared with control.



**Fig. 7.-** Lung of rat treated and sacrificed after 4 weeks, showing bronchiolar hyperplasia with collapse and emphysema in the air alveoli (H & E : X40)

## DISCUSSION

It was clear from the present results that the losses in body weight of rats after oral administration  $1/4$  LD<sub>50</sub> of herbicide Machete may be due to the loss of appetite. The same observation was recorded by Fouad and El-Saify (1990) when treated pigeon and chicken with Methomyl and Trichlorofon insecticides. On the other hand, the heart and lung weight of rat were altered after treatment with machete, an increase were recorded all over the test periods. Similar findings were reported by Verschoyle and Cabral (1982) in lungs of female rats after 4 days treatment with trimethyl and triethyl phosphorothioates.

Decreases in the number of erythrocytes, leucocytes, haemoglobin level, haematocrit value and packed cell volume were observed in rats treated with  $1/4$  LD<sub>50</sub> herbicide Machete. Similar results with rodenticide anticoagulant were obtained in rats (El- Mahrouky, 1984) and Amer (1995)

who studied the effect of different doses of bentazon (herbicide) on haematological parameters of rabbit.

Repeated oral administration of methomyl and trichlorofon insecticides produced a significant decrease in the R.B.C.s count and an increase in the MCV (mean corpuscular volume) which are indicative of anaemic conditions as reported by Aditya *et al.* (1986). It is generally held that anaemia results either from a decreased rate of production, or from an increased loss or destruction of R.B.C.s (Harper *et al.*, 1979).

In addition, treatment with 1/4 LD<sub>50</sub> herbicide developed in heart, oedema inflammatory cells infiltration in the subendocardial tissue and the myocardial blood vessels were hyperemic. Similar observation was recorded by Rahmy *et al.* (1995) who revealed that a variety of degenerative changes were induced by the Egyptian Cobra *Naja haje* venom on the rat myocardium. These changes were found to be time dependent. They included the occurrence of cloudy myocardial cytoplasm and loss of myofibrillar striation which represent a primary stage of myocardial injury. Robbins and Angell (1976) observed after one day of envenomation. Myocardial damage and degeneration were also reported by Abu-Sitta (1978), Abou-State *et al.* (1985) and Alloatti *et al.* (1986) due to action of different snake venoms. Zaki *et al.* (1976), Petkovic *et al.* (1979) and Unkovic Cvetkovic *et al.* (1983) believed that these changes may be responsible for the arrest of the heart. The present study revealed that 1/4 LD<sub>50</sub> herbicide Machete induced lymphoid cells aggregation with hyperemic blood vessels in association with the presence of alveolar emphysema in diffuse manner, and peribronchiolar lymphoid hyperplasia. Similar cases of bronchitis, pneumonia, lung congestion and intralveolar haemorrhage were observed in lung tissues of rats previously treated with Cyolane (Mehani *et al.*, 1974), DDT and hexachlorocyclohexane (Evdokimov and Semenov, 1975), Paraquat (Robello and Mason, 1978), Bipyridinium herbicide (Summer, 1980), Paraquat (Rashwan *et al.*, 1989) and herbicide Cotoran (Arif *et al.*, 1985).

The respiratory defects are the main cause of death in experimental animals treated with organophosphorus insecticides (Tabershaw and Cooper, 1966; Verschoyle and Cabral, 1982 and Fikes, 1990). Also, Fouad and El-Balshy (1994) revealed that the lung of mice treated with Caffeine showed congestion in bloods vessels and pulmonary oedema. El-Sayyed *et al.* (1994) revealed that Thiodicarb treatment altered the lung weight of virgins, pregnant and offsprings of mice. Also, Thiodicarb (low dose one month treatment) induced alveolar cell hyperplasia, interalveolar haemorrhage with either intra or extra cellular deposition of dark brown pigments, and cellular granulomatous lesions around the bronchial tract.

## REFERENCES

- Abou-State, S.A.; M.M. Aubadah and M.A. Shalabi (1985). The effect of Gaboon viper venom on isolated rat heart. *Al-Azhar Med. J.*, 14 (4) : 447-452.



- Abu-Sitta, S.A.M.; B.C. Whaler and A.F. Zayat (1978). Cardiotoxicity of Gaboon viper venom. In : Proc. of the Symposium on Plant, Animal and Microbial Toxins, p. 79.
- Adiatya, M.; S. Chakraborty and P. Lahiri (1986). Haematological changes produced by Lindane ( $\delta$ -BHC) in six species of birds. *Toxicol.*, 40 : 103-112.
- Edwards, C.A. and A.R. Thompson (1973). Pesticides and the soil fauna. *Residue Rev.*, 45 : 1-79.
- Alloatti, G.; E. Camino; L. Cedrini; G. Losano; N.A. Marsh and B.C. Whaler (1986). The effect of Gaboon viper (*Bitis gabonica*) venom on the electrical and mechanical activity of the guinea-pig myocardium. *Toxicol.*, 24 (1) : 47-61.
- Amer, Afnan M. (1995). Toxic effect of Bentazon on the haematological picture and splenic tissue in rabbits. *J. Egypt. Ger. Soc. Zool.*, Vol. 18 (C) *Histology and Histochemistry*, pp. 233-249.
- Arif, H.; M.M. Lotfy; E.E. Sakr and A.H. Nouvou (1985). Pathological and enzymological alteration of the cumulative effect of herbicide Cotoran in rats. *Vet. Med. J.*, 33 (2) : 301-319.
- Edwards, C.A. and A.R. Thompson (1973). Pesticides and the soil fauna. *Residue Rev.*, 45 : 1-79.
- El-Mahrouky, F.S.M. (1984). Physiological studies on the response of rodents to some rodenticides. M.Sc. Thesis, Fac. of Science, Menoufia Univ., Egypt.
- El-Sayed, H.I.; M.H. Abou-Egla; A.E. Othman and S.M.A. El-Mandouh (1994). Effect of Thiodicarb (carbamate insecticide) on lungs of virgin females, pregnant and their offsprings in mice. *J. Egypt. Ger. Soc. Zool.*, Vol. 13 (B) *Anatomy & Embryology*, pp. 79-99.
- Evdokimov, E.S. and N.T. Semenov (1975). Experimental data on the toxicity of different groups of organochlorine pesticides. *Zdravookhr. Turkm.*, 19 (5) : 47-81.
- Fikes, J.D. (1990). Organophosphorus and carbamate insecticides. *Toxicology of selected pesticides. Drugs and Chemical*, 20 (2) : 353-367.
- Fouad, A.A. and R.M. El-Balshy (1994). Teratogenic effect of Caffeine on the mice fetuses at 20th day of gestation and postnatal viability. *J. Egypt. Ger. Soc. Zool.*, Vol. 13 (B) *Vertebrate Anatomy & Embryology*, pp. 25-53.
- Fouad, S. and A. El-Saify (1990). Effect of Methomyl and Trichlorofon on body weight and some hematological parameters in two Egyptian birds. *J. Egypt. Ger. Soc. Zool.*, 1 : 1-13.
- Harper, A.; V.W. Rodwell and P. Mayes (1979). Review of Physiological Chemistry. Lange Medical Publications, California, pp. 193 and 213.
- Hollinger and Chvapil (1977). Effect of paraquat toxicity on collagen synthesis in the lung. *Res. Commun. Chem. Pharmacol.*, 16 : 159.
- Mehani, S.; A. El-Habashi and K. Ahmed (1974). Toxicity of Cyolane. *Ain Shams Med. J.*, 25 (1) : 7-11.
- Levinson, S.A. and Mac R.P. Fate (1956). Clinical laboratory diagnosis. 5th ed., 124 pp., Philadelphia, Lan and Febiger.
- Mehani, S.; A. El-Habashi and K. Ahmed (1974). Toxicity of Cyolane. *Ain Shams Med. J.*, 25 (1) : 7-11.
- Miller, S.E. (1960). A text book of clinical Pathology. 6th ed., The Williams and Wilkins, Baltimore, U.S.A.
- Petkovic, D.; T. Jovonovic; D. Micevic; N. Unkovic- Cvetkovic and Cvetkoviv, M. (1979). Short communications : Actions of *Vipera ammodytes* venom and its fractions on the isolated rat heart. *Toxicol.*, 17 : 639-644.

- Rahmy, R.T.; R.A. Ramadan; T.M. Farid and EL-Asmar, M.F. (1995). Actions of Cobra venom on cardiac muscles of rats. J. Egypt. Ger. Soc. Zool., Vol. 17 (C) Histology & Histochemistry, pp. 235-250.
- Rashwan, S.; F. Riad; I.E. Zaki and E. Sadek (1989). Cytological and cytochemical studies on the effect of Paraquat on the lung of rat. Egypt. Med. J., 6 (3) : 235-249.
- Robbins, S.L. and M. Angell (1976). Basic Pathology. 2nd ed., W.B. Saunders Co., Philadelphia, London and Toronto. Robello, G. and Mason, J.K. (1978). Pulmonary histological appearance in fatal Paraquat poisoning. Histopathology, 2 : 53-58.
- Schalm, O.W.; M.C. Jaim and E.J. Carroll (1975). Veterinary Haematology. 3rd ed., Lan and Febiger, Philadelphia, U.S.A.
- Summers, L. (1980). In the Bipyridinium Herbicides. A.P. Author, ed., Academic Press, New York. Tabershaw, I.R. and Cooper, W.C. (1966). Sequelae of acute organic phosphate poisoning. J. Occup. Med., 8 : 5-20.
- Tabershaw, I.R. and W.C. Cooper (1966). Sequelae of organic phosphate poisoning. J. Occup. Med., 8 : 5-20.
- Unkovic-Cvetkovic, N.; M. Cvetkovic; D. Petkovic; T. Jovanovic and Unkovic, S. (1983). Histopathological changes in rat myocardium caused by *Vipera ammodytes ammodytes* (European viper) snake venom. Toxicol., 12 (3) : 429-432.
- Verschoye, R.D. and J.R.P. Cabral (1982). Investigation of the acute toxicity of some trimethyl and triethyl phosphorothioates with particular reference to those causing lung damage. Arch. Toxicol., 51 : 221-231.
- Wintrobe, M.M. (1934). Variation in size and haemoglobin content of erythrocytes in blood of various vertebrates. Folia Haematologia, 51 : 32-49.
- Zaki, A.O.; M. Hanna; B. Mewat; S. Kajubi and D. Petkovic (1976). Circulatory effect of Bitis gabonic venom. Ain Shams Med. J., 27, 135.

## التغيرات الهستوباثولوجية في أنسجة القلب والرئة في الفأر الأبيض المعامل

بمبيد "الماشيت"

فاطمة كامل خضر

معهد بحوث وقاية النباتات، مركز البحوث الزراعية، الدقى - الجيزة، مصر.

تهدف الدراسة الحالية إلى توضيح التأثير الهستوباثولوجى فى القلب والرئة وبعض القياسات فى الدم التى تحدث عند معاملة الفأر الأبيض بـ 1/؛ الجرعة نصف المميتة عن طريق الفم فى مراحل 1، 2، 3، 4، 5 أسابيع من المعاملة.

أوضحت الدراسة وجود تناقص معنوى فى وزن الجسم وأعداد كريات الدم الحمراء والبيضاء وكذلك تناقص فى كمية الهيموجلوبين مقارنة بالمجموعة الضابطة (الغير معاملة) وكذلك كان هناك نقص فى الهيماتوكريت والخلايا المترسبة. بينما كان هناك زيادة معنوية فى وزن كلا من القلب والرئة. بالنسبة للتغيرات الهستوباثولوجية فى القلب كان هناك تورم وانبعاث فى الأنسجة مصحوبا بالتهاب وترشحات فى خلال النسيج تحت القلب، وكذلك إحتقان فى الأوعية الدموية القلبية (أنسجة الغشاء تحت القلب).

أما فى الرئة فكان هناك تجمع للخلايا الليمفاوية وكذلك إحتقان فى الأوعية الدموية مصحوبا بانتفاخات فى الحويصلات الهوائية وكذلك تجمعات للخلايا الليمفاوية بجوار الأوعية الدموية مع زيادة فى عدد الخلايا الليمفاوية المجاورة للحويصلات الهوائية.