

Comparative study between Ordinary Balloon and Drug Coated Balloon in the Management of Infragenicular Arterial Diseases

Mohamed Farouk El Sabbagh,¹ MSc, Alaa-eldin Mostafa Kamal,¹ MD, Ahmed Said Ahmed Doha,² MD.

* Corresponding Author:

Mohamed Farouk El Sabbagh
mohamedsabbagh@yahoo.com

Received for publication
January 5, 2022; *Accepted*
August 27, 2022; *Published*
online August 27, 2022.

doi: 10.21608/aimj.2022.112523.1748

Citation: Mohamed F., Alaa E. and Amed S. Comparative study between ordinary balloon and drug coated balloon in the management of infragenicular arterial diseases. AIMJ. 2022; Vol.3-Issue8 .14-21.

¹ Vascular Surgery Department, Faculty of Medicine, Al-Azhar University, Cairo, Egypt.

ABSTRACT

Background: Critical Limb Ischemia (CLI) is a condition that produces disabling pain and may result in the loss of the afflicted limb.

Aim of the study: To compare between DCB and ordinary balloon in management of critical limb ischaemia caused by infragenicular arterial diseases.

Patients and Methods: A prospective single blinded randomized study conducted on 40 patients with infragenicular arterial disease between October 2017 and October 2018 at the Department of Vascular Surgery in Al-Azhar University and at Alexandria armed forces hospital.

Results: No major adverse events were reported in either groups apart from the minimal occurrence of puncture site haematoma (1 case). Two of 10 cases in the DCB group had major amputation and 5 of the 10 cases in the normal balloons had major amputation. There were no significant changes in the ABI values in the different follow up indicating the continuation of the hemodynamic success all through the follow up periods. The wound healing rate at 3 months was (65%) in 13 out of the 20 cases. Who were in Rutherford category 5. The other 7 cases (35%) had major amputations; one of them after 7 days and the 3 other at the end of the first month, two between 1 and 3 months, and one at 8 months. These 7 had no problems in the distal arch circulation of the foot, but they were diabetics.

Conclusion: The DCB demonstrated impressive patency rates with low repeat revascularization rates in comparison with other conventional balloons.

Keywords: drug eluting balloon; uncoated balloon; angioplasty; ischemia.

Disclosure: The authors have no financial interest to declare in relation to the content of this article. The Article Processing Charge was paid for by the authors.

Authorship: All authors have a substantial contribution to the article.

Copyright The Authors published by Al-Azhar University, Faculty of Medicine, Cairo, Egypt. Users have the right to read, download, copy, distribute, print, search, or link to the full texts of articles under the following conditions: Creative Commons Attribution-Share Alike 4.0 International Public License (CC BY-SA 4.0).

INTRODUCTION

Critical limb ischemia (CLI) is a clinical term that describes chronic, severe limb perfusion impairment that leads to failure to fulfil the body's basic metabolic requirements. Resting pain with or without trophic skin alterations or tissue loss, involving ischemic ulceration and/or ischemia gangrene, for more than two weeks due to circulatory impairment is the most common symptom^(1, 2). Because of the scarcity of collateral vascular routes beyond such lesions, popliteal and tibial artery occlusions are more typically linked with limb-threatening ischemia. They are generally not the source of IC as isolated lesions, but they are clinically significant in individuals who have tissue loss. Endovascular treatment is often the first option for treating infrainguinal peripheral arterial disease (PAD). Risk

factor optimization by lifestyle changes and drugs, as well as operational treatments employing both open and less invasive procedures, like balloon angioplasty, have all been used as therapeutic approaches. For the therapy of this challenging disease process, drug-eluting balloon (DEB) angioplasty has developed as a possible option to uncoated balloon angioplasty⁽³⁾.

In recent times, the use of DEB for the therapy of femoro-popliteal artery blockages has grown more common. Drug-coated balloons have the potential to decrease restenosis rates by delivering an antiproliferative drug (paclitaxel) directly to the vessel wall without the requirement for a long-term implant⁽⁴⁾.

The biological alteration of the damage responses following balloon dilatation is the challenging notion

underpinning the drug-coated balloon (DCB) idea. The significant benefits of DCBs include the quick drug delivery at uniform concentrations using a single dosage, their efficiency in regions where stents have previously been contraindicated (e.g., bifurcation, ostial lesions), and the absence of a stent scaffold. Because DCBs do not leave any metal behind, reinterventions are simpler⁽⁵⁾.

The present study aimed to compare DCB and standard PTA for management of infragenicular arterial disease in critical lower limb ischemia and its preliminary results.

PATIENTS AND METHODS

Study design: a prospective single blinded randomized study. **Study population:** 40 patients complaining of critical limb ischemia due to infragenicular arterial disease. They were divided into two equal groups. Group A was given a drug-eluting balloon, while Group B was given a conventional balloon angioplasty. **Study duration:** between October 2017 to October 2018 at the Department of Vascular Surgery in Al-Azhar University and at Alexandria armed forces hospital.

Inclusion criteria: All patients were investigated and proven to have no significant lesions in the SFA nor POP A. All of them were diabetic, in addition to infrapopliteal arterial disease. That was confirmed clinically, colored duplex and CTA.

Exclusion criteria: patients with wet gangrene in lower extremity, uncontrolled risk factors or renal insufficiency with abnormal renal functions. Also, patients who are suffering from severe illness such as heart failure or pulmonary edema were excluded

Pre-procedure Workup: Patients involved in this study were informed about all the adopted procedures and provided their written consent to the investigation.

A documented medical history that includes: a history of the presenting symptoms, treatment indications, and the patient's surgical and medical history, allergic history, a list of current drugs, and vascular risk factors. Physical examinations include: a thorough vascular exam, skin lesions, ankle-brachial indexes, segmental pressure measurements, pulse volume recordings, and a comprehensive examination of adequate depth to rule out serious concurrent diseases. Laboratory and radiological assessment were done preoperatively for all patients. Patients were evaluated through follow up clinic visits at 2 weeks, 6 weeks and 3 months post-procedure regarding clinical improvement, Hemodynamic state, and Limb salvage rate.

Statistical analysis: Using Microsoft Excel software, data from the history, basic clinical examinations, laboratory tests, and outcome measurements were coded, processed, and analyzed. The data was then

analyzed using the Statistical Package for the Social Sciences (SPSS) version 20.0 software. Numbers and percentages were employed to describe qualitative data. The mean and standard deviation were employed to describe quantitative data. To determine the significance of differences, the following tests were employed: the chi square test (X²) was utilized for the difference and association of qualitative variables. To compare quantitative parametric groups, the t test was employed. For significant findings, the P value has been set at 0.05.

RESULTS

From October 2017 to October 2018, a total of 40 participants have been included in the research and followed up on for up to 3 months. Patients with critical lower limb ischemia were randomly allocated to either DCB angioplasty or standard percutaneous transluminal angioplasty (PTA). The mean age of the study population was 57.43 years (Table 1).

65% of patients were smokers, 67.5 % were hypertensive, 22.5 % were cardiac patients, and 100 % were diabetics (Table 2).

75 % of the cases have no previous surgical intervention while 25% of the cases have as shown below in the (Table 3)

According to the presence of popliteal artery pulse by clinical examination, 62.5% of the cases have popliteal pulse pre operatively while 37.5 % of the cases, their popliteal artery pulsations cannot be assessed clinically due to obesity but had no significant stenosis in angiography. (Table 4).

In 50 % of the cases the Anterior tibial artery was the only distal run off and in the other 50% the posterior tibial artery was the only distal run off (Table 5).

Ordinary balloons were used in 50% of the patients: 25% of them were complaining of rest pain, 17.5 % had toe or toes lesions, 7.5 % had forefoot lesions. In the other 50 % of the patients the DCBs were used as following: 25% were complaining of rest pain, 20 % had toe or toes lesions, 5 % had forefoot lesions (Table 6).

Regarding the 20 patients whom DCB were used the fate was as following: 10 patients were complaining of rest pain improved at the conclusion of the research. 8 patients were complaining of toe or toes lesion and they were debrided postoperatively and their wounds healed or were healing at the conclusion of the research. Two patients were complaining of forefoot lesions, one of them underwent MTA and the other underwent BKA (Table 7).

Regarding the 20 patients whom ordinary balloons were used the fate was as following: 10 patients were complaining of claudications or rest pain improved at the conclusion of the research. 7 patients were complaining of toe or toes lesion and they were debrided postoperatively; 5 of them their wounds healed or were healing at the end of the study and the other two underwent MTA. 3 patients were

complaining of forefoot lesions, one of them underwent MTA and the other two underwent BKA (Table 8).

Before intervention, all patients had their ankle brachial pressure index measured, and the mean value of ABI was 0.54 ± 0.13 SD. During the follow up period, the ABI values were recorded after two weeks, six weeks and three months following the procedures with mean values as following: (0.92 ± 0.09 SD), (0.86 ± 0.09 SD), (0.85 ± 0.09 SD). There were no significant changes in the ABI values in the different follow up periods indicating the continuation of the hemodynamic success all through the follow up periods (Table 9).

Twenty patients (50%) were relieved from the rest pain. 13 cases (32.5%) had healed ulcers and another 3 cases (7.5%) had major amputations during the three months following the procedure. 19 cases out of 20 who were treated using drug coated balloons were cured, with a cure rate (47.5%) of the total cases. 18 out of 20 cases treated with ordinary balloons were cured, with a cure rate of (45%) of the total cases. The total number of recovery cases is 37 out of 40 cases, with a rate of (92.5%) (Table 10).

Two patients (5%) had ecchymosis and small non communicating groin hematoma at puncture site diagnosed by duplex ultrasound. Both patients were conservatively managed successfully. Another patient (2.5%) complained of communicating hematoma and pseudo aneurysm with ecchymosis and edema of the thigh as shown in fig.15. The patient discovered the hematoma 4 days following the procedure at the puncture site but he didn't seek medical advice till the first follow up visit. He was managed operatively for arterial repair and hematoma evacuation after one week following the procedure. There were no cases of either major bleeding or wire vessel perforation (Table 11).

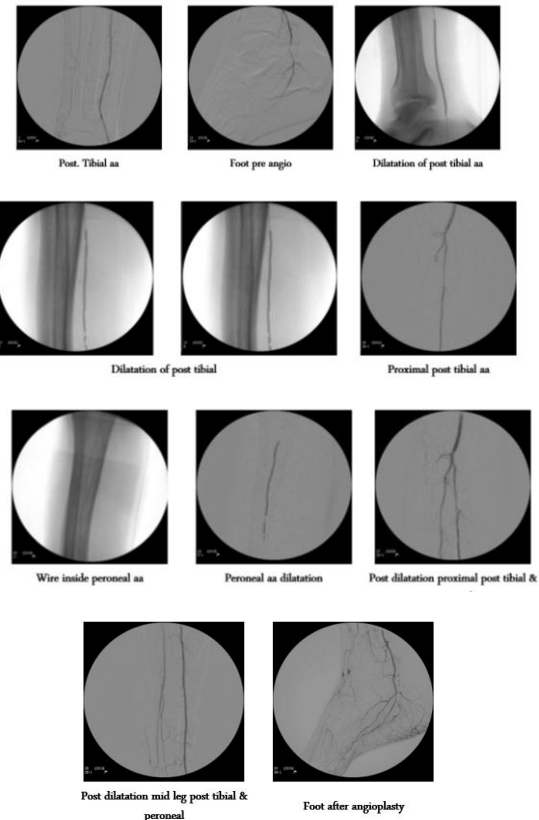
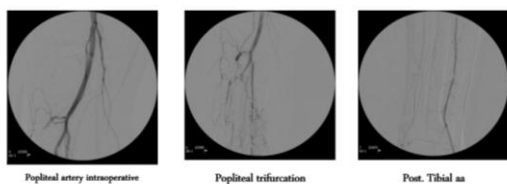
Case 1

Fifty-four years old female patient, smoker diabetic, hypertensive cardi complaining of left big and 2nd toes dry gangrene. She has intact popliteal artery pulsations and preoperative posterior tibial artery as the distal run off.

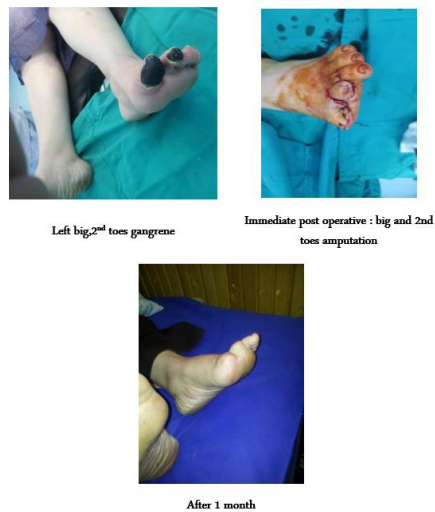
Preoperative angiographic lesion was in both PTA and peroneal arteries.

Balloon used: normal balloon

Radiological



Clinically



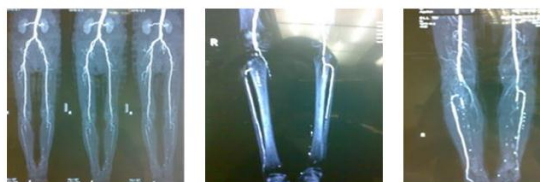Case 2

Sixty one years old female patient, smoker diabetic complaining of right big, 2nd and 3rd toes dry gangrene. She hasn't popliteal artery pulsation and pre-operative CTA was done showing the ATA as the distal run off.

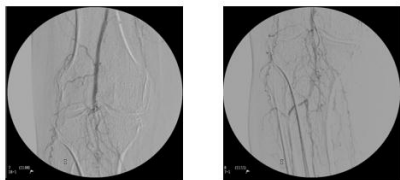
Preoperative angiographic lesion was in both ATA and peroneal arteries.

Balloon used: drug coated balloon

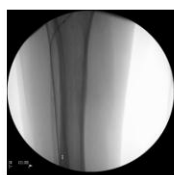
Radiological



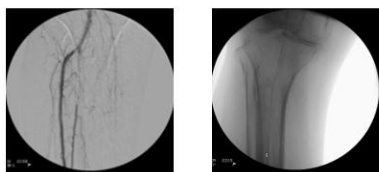
Pre op CTA



Popliteal angiography

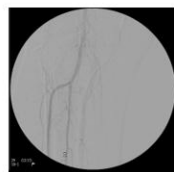


Wire inside ATA



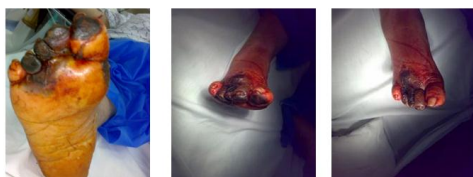
ATA after dilatation

Wire inside peroneal

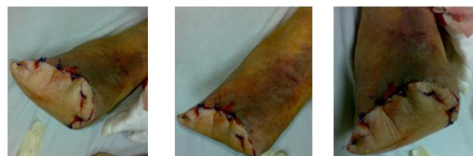

ATA peroneal after angio

Clinically



Right toes gangrene



Immediate post op : trans metatarsal amputation

	No.	%
Sex		
Male	20	50.0
Female	20	50.0
Age (years)		
Min. – Max.	45.0 – 68.0	
Mean ± SD.	57.43 ± 6.21	
Median (IQR)	57.0(53.5 – 61.5)	

Table 1: Distribution of the investigated patients based on demographic data.

	No		Yes	
	No.	%	No.	%
Smoking	14	35	26	65
HTN	13	32.5	27	67.5
Cardiac	31	77.5	9	22.5
DM	0	0.0	40	100.0

Table 2: Distribution of the investigated patients based on risk factors.

Surgical history	No.	%
No	30	75.0
Appendectomy	1	2.50
Hysterectomy	4	10.0
Splenectomy	3	7.50
Thyroidectomy	1	2.50
Breast cancer	1	2.50

Table 3: Distribution of the investigated patients as per surgical history.

Popliteal pulse	No.	%
No	15	37.5
Yes	25	62.5

Table 4: Distribution of the investigated patients as per popliteal pulse. (Popliteal pulse not felt clinically due to obesity but was normal in duplex study).

Distal run off	No.	%
Pre-operative		
ATA	20	50.0
PTA	20	50.0

Table 5: Distribution of the investigated patients as per distal run off (n = 40).

CTA pre	No.	%
No	19	47.5
Yes	21	52.5

Table 6: Distribution of the investigated patients as per CTA pre (n = 40).

Clinical presentations	Balloon used			
	Ordinary (n = 10)		DCB (n = 10)	
	No.	%	No.	%
Toe or Toes lesion	7	17.5	8	20.0
Fore foot lesion	3	7.5	210	5.0
Rest Pain	10	25	10	25

Table 7: Relation between balloons used and clinical presentations.

		Clinical presentations			
		Toe or Toes lesion		Fore foot lesion	
		No.	%	No.	%
DCB	Fate post	(n = 8)		(n = 2)	
	Toe amp	8	100.0	0	0.0
	BKA	0	0.0	1	50.0
	MTA	0	0.0	1	50.0
Ordinary	Fate post	(n = 7)		(n = 3)	
	Toe amp	5	71.4	0	0.0
	BKA	0	0.0	2	66.7
	MTA	2	28.6	1	33.3

Table 8: Relation between clinical presentations and fate post intervention.

	Pre (n = 40)	2 Weeks (n = 39)	6 Weeks (n = 37)	3 Months (n = 37)
ABI				
Min. – Max.	0.31 – 0.80	0.78 – 1.10	0.70 – 1.0	0.70 – 1.0
Mean ± SD.	0.54 ± 0.13	0.92 ± 0.09	0.86 ± 0.09	0.85 ± 0.09
Median(IQR)	0.55(0.4 – 0.7)	0.90(0.9 – 1.0)	0.90(0.8 – 0.9)	0.85(0.8 – 0.9)
Sig. bet. period		<0.001*	<0.001*	<0.001*

Table 9: A descriptive analysis of the investigated patients as per ABI.

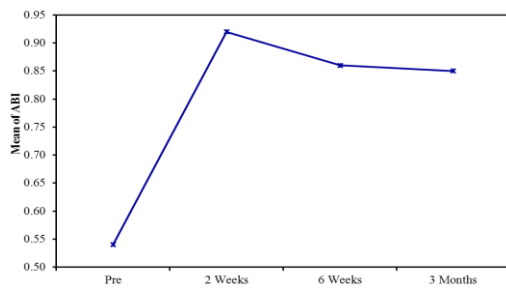


Fig 1: A descriptive analysis of the investigated patients as per ABI.

	No	%
Fate		
Relief of rest pain	20	50.0
Healed ulcers	13	32.5
Major amputations	3	7.5
Minor amputations	4	10
Drug coated balloons cure rate	19	47.5
Normal balloons cure rate	18	45

Table 10: Distribution of the examined patients based on their fate (3 months after dilation) (no=20).

	No	%
Complications		
Minor bleeding or hematoma	2	5
Major bleeding or hematoma	1	2.5
Vessel perforation	0	0
Distal embolization	0	0
AV Fistula	0	0

Table 11: Distribution of the examined patients based on complications (no=40).

DISCUSSION

Critical Limb Ischemia (CLI) is an illness with a poor prognosis. The significant death rates related to CLI, which exceed those for any other kind of occlusive cardiovascular disease, including symptomatic coronary artery disease (CAD), represent the systemic atherosclerotic burden^(6, 7). In addition to low survival rates, CLI patients have a bad prognosis for the preservation of limbs⁽⁸⁾. The prognosis for limb salvage and survival in CLI sufferers has increased significantly over the last two decades, with data demonstrating a drop in significant amputation rates in the CLI group^(9, 10, 11, 12, 13, 14, 15). In comparison to surgical revascularization techniques, studies have shown a tendency towards more endovascular techniques (Jones et al., 2012; Hong, Beck & Nelson, 2011; Egorova et al., 2010; Goodney, Beck, Nagle, Welch & Zwolak, 2009; Rowe, Lee, Weaver & Etzioni, 2009; Nowygrod et al., 2006)^(9,10,11,12,13,15) and revealed a possible causal association between higher endovascular procedures, particularly in patients with elevated surgical risk, and lower amputation rates^(10,11). For peripheral vascular recanalization, various endovascular therapy techniques were employed. PTA remained the most extensively employed approach for recanalization in BTK vessels, but it was severely limited by the high rates of restenosis or occlusion⁽¹⁶⁾. Nevertheless, the 6-to 12-month patency rates following effective PTA in infrapopliteal arteries are low^{10, 13}. That could be accounted for by the small vessel diameter, elastic recoil, and sluggish blood flow that result¹⁴. In fact, the documented 12-month patency rate of effective PTA-treated tibial artery stenosis is just 50 %^(17). DEB has lately emerged as a successful endovascular technique for recanalization in BTK vessels, resulting in apparently improved long-term patency

rates. Drug-eluting devices have been developed to reduce inflammatory responses and intimal hyperplasia of the walls of arteries⁽¹⁸⁾, and they have shown promising findings in the therapy of CAD⁽¹⁹⁾ and PAD⁽²⁰⁾. However, there is still a lack of data to support DEB and DES in the therapy of infrapopliteal artery disease. Unlike Caradu, et al⁽²¹⁾, who studied the long-term results of patients who had interventions of endovascular infrainguinal employing drug-coated balloon angioplasty vs plain old balloon angioplasty for femoropopliteal arterial disease, this research looked at the early outcomes of employing drug-coated balloon angioplasty vs plain old balloon angioplasty for tibial arterial disease⁽²¹⁾. Regarding patients included in this study, their complaints were either with rest pain (20 cases) or foot lesion ischemic ulcers and / or gangrenous toe or toes (20 cases). This was a small number of patients as Salvatore Cassese et al⁽²²⁾ studied 641. Salvatore et al. searched scientific databases for randomized studies of DCB treatment for infrapopliteal artery atherosclerosis. DCBs (n ¼ 378) or control treatments (uncoated balloon or drug-eluting stent; n ¼ 263) were given to 641 participants in five trials⁽²²⁾. According to the presence of popliteal artery pulse by clinical examination, 62.5% of the cases (25 cases) had popliteal pulse pre operatively while 37.5 % of the cases (15 cases) hadn't. In pre-operative scanning either by duplex or CTA the distal run off In 50 % of the cases the Anterior tibial artery was the only distal run off and in the other 50% the posterior tibial artery was the only distal run off. In 21 (52.5 %) of the patients, CTA was done as a pre-operative investigation while in the other 19 (47.5 %) CTA wasn't done depending on both presence of popliteal pulse and pre-operative duplex. According to the TASC classification, 55% of the patients were categorized as TASC B, 32.5% were TASC C and 12.5% were TASC A. 50% of the cases (20 cases) were treated using DCB while the other 50% (20 cases) were treated by ordinary balloons. This number is accepted as in 2017 marc Bosier et al⁽²³⁾, studied the BCD on 70 patients as multicenter study⁽²³⁾. DCBs were used in 50% of the patients: 25% of them were complaining of claudications or rest pain, 17.5 % had toe or toes lesions, 7.5 % had forefoot lesions. In the other 50 % of the patients ordinary balloons were used as following: 25% were complaining of claudications or rest pain, 20 % had toe or toes lesions, 5 % had forefoot lesions. Regarding the 20 patients whom DCB were used the fate was as following: All 10 patients who were complaining of claudication or resting pain improved at the conclusion of the research. 8 patients were complaining of toe or toes lesion and they were debrided postoperatively and their wounds healed or were healing at the conclusion of the research. Two patients were complaining of forefoot lesions, one of them underwent MTA and the other underwent BKA.

Regarding the 20 patients whom ordinary balloons were used the fate was as following: 10 patients were complaining of claudications or rest pain improved at the conclusion of the research. 7 patients were complaining of toe or toes lesion and they were debrided postoperatively; 5 of them their wounds healed or were healing at the end of the study and the

other two underwent MTA. 3 patients were complaining of forefoot lesions, one of them underwent MTA and the other two underwent BKA. Regarding the patient complaints there were no difference between ordinary balloon and DCB in fate. Two of 10 cases in the DCB group had major amputation and 5 of the 10 cases in the normal balloons had major amputation. In spite of a patent endovascularly treated arterial section, all amputations happened within 30 days, with three occurring between 1 and 3 months. All were diabetics, and all had severe tissue loss as a result of the main infection or recurring infection⁽²⁴⁾. ABI was measured in all patients before intervention and the mean value of ABI was 0.54 ± 0.13 SD. During the follow up period, the ABI values were recorded after two weeks, six weeks and three months following the procedures with mean values as following: (0.92 ± 0.09 SD), (0.86 ± 0.09 SD), (0.85 ± 0.09 SD). There were no significant changes in the ABI values in the different follow up periods indicating the continuation of the hemodynamic success all through the follow up periods. From 40 patients, 25 (62.5%) patients had pedal pulses post operatively while 15 (37.5%) hadn't.

Twenty patients (50%) were relieved from the rest pain, 13 cases (32.5%) had healed ulcers and another 7 cases (17.5%) had major amputations during the three months following the procedure. This study showed good results regarding limb salvage and wound healing. The limb salvage rate in our study was (82.5%) at 3 months. In this current study primary patency rate was 82.5% at 3 months. The wound healing rate at 3 months was (65%) in 13 out of the 20 cases. Who were in Rutherford category 5. The other 7 cases (35%) had major amputations; one of them after 7 days and the 3 other cases at the end of the first month, two between 1 and 3 months, and one at 8 months. These 7 cases had no problems in the distal arch circulation of the foot, but they were diabetics. Diabetes is probably the cause of increased risk of amputation here⁽²⁵⁾.

Non salvageable limbs were attributed mainly to the bad condition and the persistent infection of the wounds not to the vascularization state of the wound as showed in many studies. Our results are in agreement with several studies evaluating the role of a single vessel peroneal artery run off angioplasty in critical lower limb ischemia without extensive infection or tissue loss^(21, 26, 27). Nevertheless, because the degree of tissue loss associated with widespread gangrene and overwhelming infections is the primary predictor of limb loss, limb loss could still be unavoidable in such individuals even though normal perfusion is restored. Reintervention was not needed because at the time of the reintervention the patients feet were non salvageable and major amputations couldn't be avoided even if reintervention were tried.

The technique of DEB angioplasty, or DES implantation, has been generally thought to be safe. According to Thomas et al.,⁽²⁸⁾ a paclitaxel eluting balloon can cause vasculitis. We discovered no

reports of drug-eluting device-related distal embolization or other problems in this trial series. In the trials that were included, the operation rate of success ranged from 95.5% to 100%. Paclitaxel, sirolimus, zotarolus, as well as everolimus⁽²⁹⁾, are currently available pharmacological agents for DEB or DES. Cell growth and proliferation have been shown to be inhibited by these agents⁽³⁰⁾.

CONCLUSION

Regarding the results we obtained from this study we concluded that usage of drug coated balloons over ordinary balloons are preferable regarding the outcome mostly if the patient is complaining of rest pain with no foot lesion and to confirm that the suggested studies should be conducted on a larger number of patients. Regarding the usage of either ordinary balloons or drug coated balloons in patients complaining of toe or toes lesions we prefer to use drug coated balloons over the ordinary balloons as there is slight difference in limb salvage rate and intraoperative recoiling after balloon dilatation although higher number of patients should be included in further studies to obtain this recommendation.

Regarding the usage of the drug coated balloons or other new modalities in the lower limb critical ischemia patients more studies are required with large number of patients included to get accurate and definite data and strong recommendations from these studies.

Conflict of interest : none

REFERENCES

- Hooi JD, Stoffers HE, Knottnerus JA, et al. The prognosis of non-critical limb ischaemia: a systematic review of population-based evidence. *British journal of general practice*. 1999; 49(438): 49-55.
- Dormandy JA and Murray GD. The fate of the claudicant—a prospective study of 1969 claudicants. *European journal of vascular surgery*. 1991; 5(2): 131-3.
- Kayssi A, de Mestral C, Forbes TL, et al. Predictors of hospital readmissions after lower extremity amputations in Canada. *Journal of vascular surgery*. 2016; 63(3): 688-95.
- Mehrotra S, Paramasivam G and Mishra S. Paclitaxel-coated balloon for Femoropopliteal Artery Disease. *Current Cardiology Reports*. 2017; 19(2): 10-6.
- Herten M, Torsello GB, Schönefeld E, et al. Critical appraisal of paclitaxel balloon angioplasty for femoral–popliteal arterial disease. *Vascular Health and Risk Management*. 2016; 12: 341-356.
- Carter GT. Physical medicine and rehabilitation clinics of North America. Neuromuscular disease management and rehabilitation, part II: specialty care and therapeutics. Foreword. *Physical medicine and rehabilitation clinics of North America*. 2012; 23(4): 11-2.
- Vignes S. Physical therapy in limb lymphedema. *Annales de Dermatologie et de Venereologie*. 2005; 132:185-7.
- Armstrong DG and Lavery LA. Diabetic foot ulcers: prevention, diagnosis and classification. *American family physician*. 1998; 57(6): 1325.
- Jones WS, Patel MR, Dai D, et al. Temporal trends and geographic variation of lower-extremity amputation in patients with peripheral artery disease: results from US Medicare 2000–2008. *Journal of the American College of Cardiology*. 2012; 60(21): 2230-6.
- Hong MS, Beck AW and Nelson PR. Emerging national trends in the management and outcomes of lower extremity peripheral arterial disease. *Annals of vascular surgery*. 2011; 25(1): 44-54.
- Egorova NN, Guillerme S, Gelijns A, et al. An analysis of the outcomes of a decade of experience with lower extremity revascularization including limb salvage, lengths of stay, and safety. *Journal of vascular surgery*. 2010; 51(4): 878-85.
- Goodney PP, Beck AW, Nagle J, et al. National trends in lower extremity bypass surgery, endovascular interventions, and major amputations. *Journal of vascular surgery*. 2009; 50(1): 54-60.
- Rowe VL, Lee W, Weaver FA, et al. Patterns of treatment for peripheral arterial disease in the United States: 1996-2005. *Journal of vascular surgery*. 2009; 49(4): 910-7.
- Eskelinen E, Eskelinen A, Alhäk A, et al Major amputation incidence decreases both in non-diabetic and in diabetic patients in Helsinki. *Scandinavian Journal of Surgery*. 2006; 95(3): 185-9.
- Nowygrod R, Egorova N, Greco G, et al. Trends, complications, and mortality in peripheral vascular surgery. *Journal of vascular surgery*. 2006; 43(2): 205-216.
- Schmidt A, Ulrich M, Winkler B, et al. Angiographic patency and clinical outcome after balloon-angioplasty for extensive infrapopliteal arterial disease. *Catheterization and Cardiovascular Interventions*. 2010; 76(7): 1047-54.
- Verzini F, De Rango P, Isernia G, et al. Results of the "endovascular treatment first" policy for infrapopliteal disease. *The Journal of cardiovascular surgery*. 2012; 53(1): 179-88.
- Karnabatidis D, Spiliopoulos S, Katsanos K, et al. Below-the-knee drug-eluting stents and drug-coated balloons. *Expert review of medical devices*. 2012; 9(1): 85-94.
- Wallace EL, Abdel-Latif A, Charnigo R, et al. Meta-analysis of long-term outcomes for drug-eluting stents versus bare-metal stents in primary percutaneous coronary interventions for ST-segment elevation myocardial infarction. *The American journal of cardiology*. 2012; 109(7): 932-40.
- Feiring AJ, Krahn M, Nelson L, et al. Preventing leg amputations in critical limb ischemia with below-the-knee drug-eluting stents: the PaRADISE (PREventing Amputations using Drug

- eluting StEnts) trial. *Journal of the American College of Cardiology*. 2010; 55(15): 1580-9.
21. Caradu C, Lakhlifi E, Colacchio EC, et al. Systematic review and updated meta-analysis of the use of drug-coated balloon angioplasty versus plain old balloon angioplasty for femoropopliteal arterial disease. *Journal of vascular surgery*. 2019; 70(3): 981-95.
 22. Cassese S, Byrne RA, Ndrepepa G, et al. Everolimus-eluting bioresorbable vascular scaffolds versus everolimus-eluting metallic stents: a meta-analysis of randomised controlled trials. *The Lancet*. 2016; 387(10018): 537-44.
 23. Bosier B, Bellocchio L, Metna-Laurent M, et al. Astroglial CB1 cannabinoid receptors regulate leptin signaling in mouse brain astrocytes. *Molecular metabolism*. 2013; 2(4): 393-04.
 24. Lepäntalo M, Apelqvist J, Setacci C, et al. Chapter V: diabetic foot. *European Journal of Vascular and Endovascular Surgery*. 2011; 42: 60-74.
 25. Iida O, Soga Y, Hirano K, et al. Midterm outcomes and risk stratification after endovascular therapy for patients with critical limb ischaemia due to isolated below-the-knee lesions. *European journal of vascular and endovascular surgery*. 2012; 43(3): 313-21.
 26. Dosluoglu HH, Cherr GS, Lall P, et al. Peroneal artery-only runoff following endovascular revascularizations is effective for limb salvage in patients with tissue loss. *Journal of Vascular Surgery*. 2008; 48(1): 137-43.
 27. Graziani L, Silvestro A, Monge L, et al. Transluminal angioplasty of peroneal artery branches in diabetics: initial technical experience. *Cardiovascular and interventional radiology*. 2008; 31(1):49-55.
 28. Thomas SD, McDonald RR and Varcoe RL. Vasculitis resulting from a superficial femoral artery angioplasty with a paclitaxel-eluting balloon. *Journal of vascular surgery*. 2014; 59(2): 520-3.
 29. Antoniou GA, Chalmers N, Kanesalingham K, et al. Meta-analysis of outcomes of endovascular treatment of infrapopliteal occlusive disease with drug-eluting stents. *Journal of Endovascular Therapy*. 2013; 20(2): 131-44.
 30. Heldman AW, Cheng L, Jenkins GM, et al. Paclitaxel stent coating inhibits neointimal hyperplasia at 4 weeks in a porcine model of coronary restenosis. *Circulation*. 2001; 103(18): 2289-95.