

Evaluation of the Efficacy of Intralesional Methotrexate Versus Intralesional Triamcinolone Acetonide in Treatment of Localized Vitiligo: Comparative Intra Individual Study

Dermatology,
Venereology and
Andrology

Aliaa Eid Elshenawy Ibrahim Ragab,¹ M.B.B.Ch, Amr Mohamed Zaky,¹ MD and Emad Mahmoud El Rewiny,² MD.

* Corresponding Author:

Aliaa Eid Elshenawy Ibrahim Ragab
oladerma@yahoo.com

Received for publication
January 16, 2022; Accepted
August 28, 2022; Published
online August 28, 2022.

doi: 10.21608/aimj.2022.114103.1788

Citation: Aliaa E., Amr M. and Emad M. Evaluation of the Efficacy of Intralesional Methotrexate Versus Intralesional Triamcinolone Acetonide in Treatment of Localized Vitiligo: Comparative Intra Individual Study. AIMJ. 2022; Vol.3-Issue8 .22-26.

¹Dermatology, Venereology and Andrology Department, Faculty of Medicine, Al-Azhar University, Cairo, Egypt.

ABSTRACT

Background: Vitiligo is a frequent hypopigmentary disorder that can impact both adults and children and has significant psychosocial consequences due to its leopard skin-like look. Vitiligo must be treated and studied more frequently, even if it is not life-threatening or asymptomatic.

Aim of the study: A comparative intra-individual study was conducted to evaluate the efficacy of intralesional methotrexate against intralesional triamcinolone acetonide in the therapy of localized non-segmental vitiligo.

Patients and Methods: Our study was carried out on 30 patients complaining of vitiligo from August 2021 to January 2022. Thirty subjects with two comparable patches, one of them was randomly selected and treated with Intralesional Methotrexate and the other was treated with Intralesional Triamcinolone Acetonide. Patients were selected from out-patient clinic of Dermatology, Venereology and Andrology Department of Al-Azhar University Hospitals.

Results: The present study showed improvement in Patches treated with Intralesional Methotrexate as excellent response in 13.3% of patients, good response in 13.3% of patients, fair response in 10% of patients and poor response in 63.3% of patients. Improvement in Patches treated with Intralesional Triamcinolone Acetonide as excellent response in 13.3% of patients, good response in 13.3% of patients, fair response in 16.7% of patients and poor response in 56.7% of patients.

Conclusion: using Intralesional Methotrexate and intralesional Triamcinolone Acetonide considered a promising, safe and effective therapeutic options for localized vitiligo with no significant side effects.

Keywords: Methotrexate ; Triamcinolone Acetonide ; Vitiligo.

Disclosure: The authors have no financial interest to declare in relation to the content of this article. The Article Processing Charge was paid for by the authors.

Authorship: All authors have a substantial contribution to the article.

Copyright The Authors published by Al-Azhar University, Faculty of Medicine, Cairo, Egypt. Users have the right to read, download, copy, distribute, print, search, or link to the full texts of articles under the following conditions: Creative Commons Attribution-Share Alike 4.0 International Public License (CC BY-SA 4.0).

INTRODUCTION

Vitiligo is a disorder that is multifactorial and has a complicated pathogenesis. It has a significant detrimental psychosocial impact, especially among people of color. The melanocytes in the damaged skin epidermis physically disappear or stop functioning due to genetic predisposition, immune-mediated harm, or various unknown toxins, whereas those in the hair follicles are normally spared; nevertheless, the specific mechanism remains unknown. Vitiligo is frequently linked to other autoimmune disorders.¹

Any repigmenting plan for vitiligo therapy should have two main objectives: stabilization and repigmentation.²

The global incidence of vitiligo was 0.5%³, with Egypt having an incidence of up to 1.22%.⁴

The most frequent therapy for localized vitiligo was monotherapy using topical steroids. The negative effects of systemic absorption, such as epidermal atrophy, striae distensae, telangiectasia, and steroid folliculitis, make it difficult to use topical steroids for a long time.⁵

Intralesional steroids are currently being debated as a therapy for localized vitiligo. ^{6,7,8,9} T-lymphocyte proliferation is significantly inhibited by methotrexate (MTX), a folic acid antagonist and cell proliferation inhibitor ¹⁰. It downregulates B cells as well as suppressing T cell activation and expression of intracellular adhesion molecules. ¹¹

Because it suppresses T cells that produce TNF alfa, MTX was employed to treat vitiligo. ¹²

As a result, it has the potential to halt the progression of disease. ¹³

The present work aimed to evaluate the efficacy of intralesional methotrexate against intralesional triamcinolone acetonide in treating localized non-segmental vitiligo.

PATIENTS AND METHODS

This research was carried out on thirty patients with localized vitiligo from August 2021 to January 2022. The patients were diagnosed by typical clinical findings. The patients were able to read and give consents. Patients with localized vitiligo, age \geq 18 years of both sexes were included.

Patients under any other treatment modalities, with extensive or segmental vitiligo, age less than 18 years, pregnant, breast feeding, with chronic hepatic, or haematological disorders and immunocompromised patient were excluded.

Patients were selected from the out-patient clinics of the Al-Azhar University Hospitals' Dermatology, Venereology, and Andrology Departments.

All patients underwent a complete general history, skin examination, and documented digital photography. Thirty subjects with two comparable patches were split into two groups:

Group A (MTX group):

30 patients with stable vitiligo received an intralesional injection of methotrexate (12.5 mg/mL). A methotrexate vial containing 50 mg/ 2 ml was employed at a concentration of 12.5 mg/ml. MTX has been administered intradermally at 1 cm intervals using a volume of 0.02 ml/site, all under strict aseptic precautions. A 0.5-inch long, 30-gauge needle connected to an insulin syringe was used to inject a maximum of 0.1–0.2 ml (2.5–5 mg) each session.

Group B (TrA group):

The same 30 patients presenting with localized vitiligo will be treated with an intralesional injection of triamcinolone acetonide (40 mg/ml). The intralesional steroids' original strength (epirelefan @ 40 mg/ml) was 40 mg/ml. Intradermally, one-fourth diluted triamcinolone acetonide (2.5 mg/ml TrA) has been administered at 1 cm intervals using an injecting volume of 0.05–0.1 ml/site. With a 0.5-inch long, 30-gauge needle connected to an insulin syringe, a maximum of 2 ml can be injected. Treatment was used as once per ∇ weeks, for maximum 6 sessions.

Response to treatment:

- (i) excellent response: 75% repigmentation or more,
- (ii) good response: 50% repigmentation or more,
- (iii) fair response: 25% repigmentation or more, and
- (iv) poor response: less than 25% repigmentation.

Statistical analysis:

The IBM SPSS software package version 20.0 was used to analyze the results of the present study statistically (Armonk, NY: IBM Corp). The Shapiro-Wilk test has been done to ensure that the distribution is normal. The mean, standard deviation, median, and interquartile range (IQR) have been employed to describe quantitative data. The obtained findings have been determined to be significant at the 5% level. The Mann-Whitney U test has been employed to compare numerical data, while the Chi-square test has been employed to compare categorical data. The significance was determined by a P value of less than 0.05.

RESULTS

There was a statistical highly significant difference between studied Triamcinolone patches Before And After treatment as regard improvement grades and score with p value <0.001 (table 1).

There was a statistical highly significant difference between studied Methotrexate patches Before And After treatment as regard improvement grades and score with p value <0.001 (table 2).

There was a statistical no significant difference between studied patches as regard improvement grades and score (table 3).

Triamcinolone	Before		After		Test of sig.	p
	No.	%	No.	%		
Poor	30	100.0	17	56.7	$\chi^2=$ 15.852*	MCp <0.001*
Fair	0	0.0	5	16.7		
Good	0	0.0	4	13.3		
Excellent	0	0.0	4	13.3		
Mean \pm SD.	0.0 \pm 0.0		31.50 \pm 28.65			
Median (IQR)	0.0 (–)		20.0 (10.0 – 50.0)			

Table 1: Comparison between before and after treatment according to triamcinolone..

Methotrexate	Before		After		Test of sig.	p
	No.	%	No.	%		
Poor	30	100.0	19	63.3	$\chi^2=$ 12.465*	$M_C p$ <0.001*
Fair	0	0.0	3	10.0		
Good	0	0.0	4	13.3		
Excellent	0	0.0	4	13.3		
Mean \pm SD	0.0 \pm 0.0		33.83 \pm 29.70			
Median (IQR)	0.0 (-)		20.0 (10.0 – 50.0)			

Table 2: Comparison between before and after treatment according to Methotrexate.

parameters	Groups	Patch A (methotrexate) (N = 30)		Patch B (Triamcinolone) (N = 30)		Stat. test	P-value
		No.	%	No.	%		
Improvement grades	Poor	17	56.7%	19	63.3%	$\chi^2=$ 0.747	0.971
	Fair	5	16.7%	3	10.0%		
	Good	4	13.3%	4	13.3%		
	Excellent	4	13.3%	4	13.3%		
Improvement score	Mean \pm SD	31.50 \pm 28.65		33.83 \pm 29.70		Y= 431.0	0.774
	Median (IQR)	20.0 (10.0 – 50.0)		20.0 (10.0 – 50.0)			

Table 3: Comparison between studied patches as regard improvement grades and score.

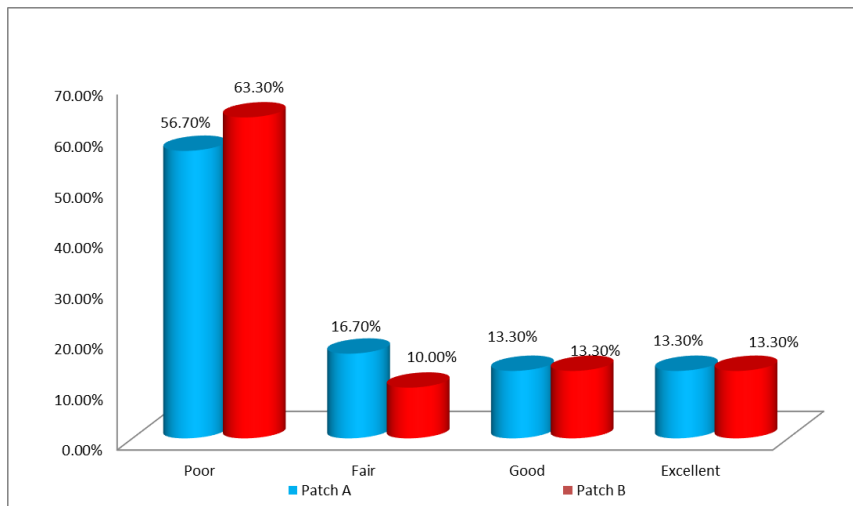


Fig 1: Comparison between studied patches as regard improvement grades.

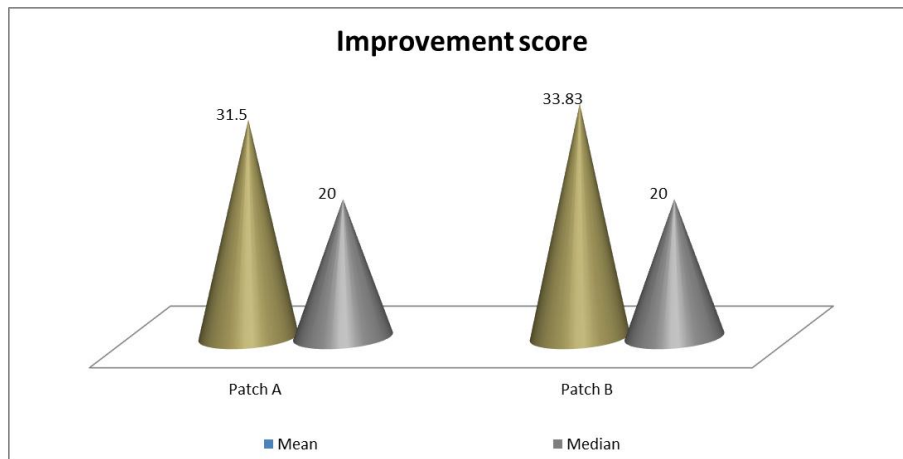


Fig 2: Comparison between studied patches as regard improvement score.

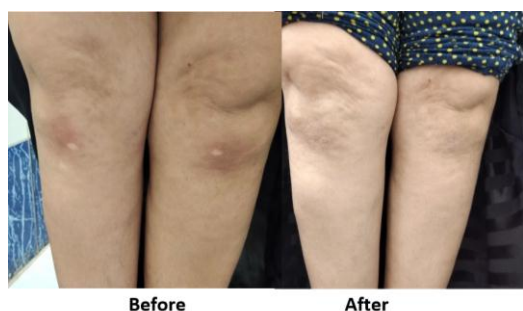

Fig 3: A 40-year-old female with knee vitiligo. Before and after treatment showing improvement in patch A (RT one100 %) and in patch B (LT one100 %) after 3 months of treatment. patch A using (intralesional methotrexate). (Patch B using (Intralesional Triamcinolone Acetonide).

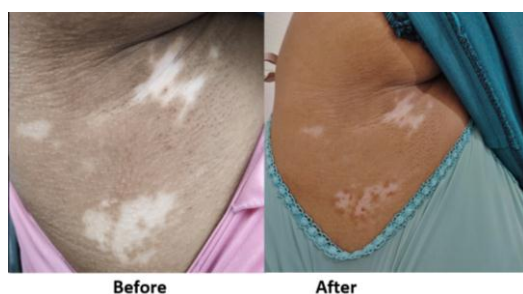

Fig 4: A 28-year-old female with axillary vitiligo before and after treatment showing improvement in patch A after 3 months of treatment. (Lower one 50 %) and patch B (upperone25%) (Patch B using (Intralesional Triamcinolone Acetonide).

DISCUSSION

Vitiligo is a multifactorial skin condition that poses a significant skin care challenge. The main objective of therapy is always repigmentation; secondary objectives include disease stabilization for the cessation of functional melanocyte loss, in addition to assuring suitable psychosocial care and improved life quality. On a case-by-case basis, the therapy decision ought to be made. The presence of any response to vitiligo therapy is predicted to take many months, and anticipatory therapy could be essential in the long run.¹⁴

Corticosteroids and PUVA are the two most commonly used therapies for vitiligo. The use of PUVA therapy in the case of active vitiligo is not an ideal therapy. Corticosteroids and narrow-band UVB therapy are the safest and most effective treatments for localized and widespread vitiligo, but they can have undesired adverse impacts, including telangiectasia of skin, striae distensae and atrophy, local hypertrichosis and acne.¹⁵

Methotrexate has been used in the treatment of vitiligo in a few studies. Sandra et al. reported that a

patient with both rheumatoid arthritis and unstable vitiligo reacted effectively to methotrexate, while Garza-Mayers and Kroshinsky described a successful study of MXT in the treatment of vitiligo at an up-titrating dosage of 12.5–25 mg/week. After topical calcineurin inhibitors and phototherapy failed, improvements have been observed as early as six weeks (for quickly advancing generalised vitiligo) and as late as fourteen months, with no major adverse effects recorded.^{16,17}

Six patients with generalised vitiligo were treated with MXT at a dosage of 25 mg/week for a six-month period by Alghamdi and Khurram. Clinically, however, there was no improvement.¹⁸

This clinical trial was the first attempt to treat vitiligo with intralesional methotrexate.

The findings showed that the patches treated with intralesional methotrexate have a similar grade of improvement as patches treated with intralesional triamcinolone acetonide, with statistically no significant difference (p-value = 0.971).

Generally, the usage of intralesional methotrexate causes temporary adverse effects due to its inherent qualities, which cause minor redness, hyperpigmentation, and irritation at injection sites on the skin's surface.

While irritation and redness were observed in the group treated with intralesional methotrexate, the findings showed that these symptoms were only temporary and could be removed by applying zinc oxide ointment.

Nonetheless, repigmentation of the patch treated with intralesional methotrexate (cases) offered nearly the same improvement as the intralesional Triamcinolone Acetonide patch (control).

The first successful trial of topical MXT 1% gel in the therapy of stable vitiligo lesions was reported by⁴, demonstrating that MXT, in either topical or oral form, could be a useful treatment choice for stable vitiligo.

Finally, using Intralesional Methotrexate and intralesional Triamcinolone Acetonide considered a promising, safe and effective therapeutic options for localized vitiligo with no significant side effects.

CONCLUSION

In our study, we used intralesional methotrexate to treat the vitiligo disorder successfully. In this case, it appeared that while the complications of temporary irritation and redness (at the site of injection) were greater in the group treated with intralesional methotrexate (case) in the short term than in the group treated with intralesional triamcinolone acetonide (control), repigmentation was not significantly different. Finally, utilizing intralesional

methotrexate and intralesional Triamcinolone Acetonide is considered a promising, safe, and effective therapeutic option for localized vitiligo with no significant side effects.

Conflict of interest : none

REFERENCES

1. Batool S, Malik LM, and Jahangir M. Efficacy of narrowband ultraviolet B phototherapy with needling in patients of vitiligo. *Journal of Pakistan Association of Dermatologists*. 2015;25 (3):177–182.
2. Anbar TS, Hegazy RA, Picardo M, et al. Beyond vitiligo guidelines. Combined stratified /personalized approaches for the vitiligo patient. *Exp Dermatol*. 2014;23 (4):219–23.
3. Kruger C and Schallreuter K.A. Review of the worldwide prevalence of vitiligo in children/adolescents and adults. *Int J Dermatol*. Nicolaidou E, Antoniou C, Miniati A, Lagogianni E, Matekovits A, Stratigos A and Katsambas A. 2012 ; 51(1):1206–12.
4. Abdel- Hafez K, Abdel- Aty MA and Hofny ER. Prevalence of skin diseases in rural areas of Assiut Governorate. Upper Egypt. *Int J Dermatol*. 2003. 42:887- 92.
5. Lepe V, Moncada B, Castanedo-Cazares JP, et al. A double- blind randomized trial of 0.1% tacrolimus vs 0.05% clobetasol for the treatment of childhood vitiligo. *Arch Dermatol*. 2003; 139:581- 5.
6. Kandil E. Treatment of localized vitiligo with intradermal injections of triamcinolone acetonide. *Dermatologica*. 1970; 140:195- 206.
7. Vasistha LK and Singh G. Vitiligo and intralesional steroids. *Indian J Med Res*. 1979; 69:308- 11.
8. Whitton ME, Ashcroft DM and González U. Therapeutic interventions for vitiligo. *J Am Acad Dermatol*. 2008; 59:713- 717.
9. Wang Y, Shuli L and Chunying L. Perspectives of New Advances in the Pathogenesis of Vitiligo: From Oxidative Stress to Autoimmunity. *Med Sci Monit*. 2019; 25(9): 1017–23.
10. Bishnoi A and Parsad D. Clinical and molecular aspects of vitiligo treatments. *International journal of molecular sciences*. 2018; 19 (5): 1509.
11. Benedek TG. Methotrexate: from its introduction to non-oncologic therapeutics to anti-TNF- α . *Clin Exp Rheumatol*. 2010;28 (5 Suppl 61): 3-8.
12. Dillon AB, Sideris A, Hadi A, et al. Advances in Vitiligo: An update on Medical and Surgical Treatment. *J Clin Aesthet Dermatol*. 2017;10 (1):15–28.
13. Rudwaleit M, Yin Z, Siebert S, et al. Response to methotrexate in early rheumatoid arthritis is associated with a decrease of T cell derived tumour necrosis factor alpha, increase of interleukin 10, and predicted by the initial concentration of interleukin 4. *Annals of the Rheum Diseases*. 2000;59:311–4.
14. Bleuel R and Eberlein B. Therapeutic management of vitiligo. *J Dtsch Dermatol Ges*. 2018; 16:1309–13.
15. Nageswaramma S, Vani T and Indira N. Efficacy of methotrexate in vitiligo. *IOSR J Dental Med Sci*. 2018; 17: 16-9.
16. Abdelmaksoud A, Dave DD, Lotti T, et al. Topical methotrexate 1% gel for treatment of vitiligo: A case report and review of the literature. *Dermatol Ther*. 32. 2019; 13013.
17. Garza Mayers AC and Kroshinsky D. Low dose methotrexate for vitiligo. *J Drugs Dermatol*. 2017; 16: 705-6.
18. Alghamdi K and Khurram H. Methotrexate for the treatment of generalized vitiligo. *Saudi Pharm J*. 2013; 21:423–4.