

## ROLE OF ALLOGRAFT BONE GEL IN OSSEOINTEGRATION OF IMMEDIATE LOADING IMPLANT IN ESTHETIC ZONE

Mohamed Elsayed Abdel-Rahman Nasef<sup>1</sup>, Abdelbadia Abdelmaabood Abdalla<sup>2</sup>,  
Ahmed Elrawdy<sup>3</sup>, Walid Ahmed Ghanem<sup>4</sup>

DOI: 10.21608/dsu.2022.109389.1090

Manuscript ID: DSU-2112-1090

### KEYWORDS

Allograft bone gel,  
Bone density,  
CBCT;  
Immediate loading implant;

- E-mail address:  
Mohamednasef94@yahoo.com
- 1. Postgraduate student, Oral Surgery Department, Suez Canal University, Ismailia, Egypt
- 2. Assistant Professor, Oral And Maxillofacial Surgery, Faculty Of Dentistry, Zagazig University
- 3. Assistant Professor, Oral Radiology Department, Faculty Of Dentistry ,Suez Canal University
- 4. Professor, Oral And Maxillofacial Surgery Department, Faculty Of Dentistry, Suez Canal University

### ABSTRACT

**Introduction:** Immediate implants loading permit the placement of a temporary restoration immediately after the insertion of the fixture that is certainly an aesthetic and comfort for the patient. Immediate nonfunctional loading of single-tooth implants in the upper anterior after augmentation with allograft bone gel can result in successful implant integration and stable peri-implant conditions. **Aim:** The aim of the study was to assess clinically and radiographically osseointegration of immediate loading implant with allograft bone gel. **Patient and methods:** involved fourteen immediate loading dental implants in 10 male patients. The age of the patients range from 22- 48 years old with average 35 years old. Fourteen Immediate implants were divided into two main groups: **Group 1 (control group)**, A traumatic extraction of single rooted tooth or remaining root and immediate placement of dental implant into fresh extracted socket. **Group 2 (test group)**, A traumatic extraction of single rooted tooth or remaining root and immediate insertion of the implant in extracted socket and sealed with allograft bone gel (c-blast putty). **Results:** test group showed significant higher bone density than control group (Independent samples t-test,  $P < .001$ ) after two weeks ,three months and nine months. **Conclusion:** Allograft bone gel(C blast putty gel) shows effective role in implant osseointegration. Immediate non-functional loading implant design does not disturb or interfere with bone formation around implant in control or test group.

### INTRODUCTION

Immediate implants loading permit the placement of a temporary restoration immediately after the insertion of the fixture that is certainly an aesthetic and comfort for the patient, who can avoid wearing painful removable dentures during the healing time <sup>(1)</sup>.

Immediate implant loading achieve a better stability of the implant that appear at the first month after insertion which is considered the most important period of the osseointegration process preferring the osseogenesis , the success of the treatment and the happiness of the patients <sup>(2)</sup>.

Immediate functional loading of the implants stimulate more organized lamellar bone formation around the implant body and this is agree with the theory of regional acceleratory phenomenon<sup>(3)</sup>.

There are essential factors to achieve highly successful immediate loading implant such as: more bone quality, screw shaped implants, rough implant surface. Length of the implant is not less than 10 mm, satisfactory primary stability, prevention of horizontal forces and integral socket walls where is vital to find any pathological lesions <sup>(4)</sup>.

A traumatic extraction of the teeth using periosteal elevator is less invasive with a decrease surgical time, fast curing, less complication and more patient well-being. Periosteal elevator maintain the contour of the tissues exactly in the extraction endodontically treated teeth and crown fracture cases. It helps in get rid of the tooth without destructive the alveolar bone <sup>(5)</sup>.

Bone grafts used in implant is very useful step to enhance osseointegration <sup>(6)</sup>.

Allograft is the primary using alternative to an autograft, which can be obtained from either a compatible living donor or from cadaveric bone sources. Allograft materials can be prepared in three main forms fresh, frozen, or freeze-dried <sup>(7)</sup>.

Demineralized freeze-dried bone allograft (DFDBA): aside from dehydration, the inorganic part of the bone is eliminated, leaving best the natural component that contains BMPs. These substances show osteoconductive and osteoinductive features <sup>(8)</sup>.

Immediate nonfunctional loading of single-tooth implants in the upper anterior teeth following augmentation with allograft bone gel can result in successful implant integration and stable peri-implant conditions up to 18 months <sup>(9)</sup>.

The benefits of allografts contain availability in adequate quantities, sizes, shapes and the elimination of an additional donor site surgery.

The aim of the present study was to assess clinically and radiographically osseointegration of immediate loading implant with allograft bone gel.

## PATIENTS AND METHODS

The present study involved 14 immediate loading dental implants in 10 male patients. The patients had been selected, from the outpatient clinic of Oral and Maxillofacial Department, Faculty of Dentistry, Suez Canal University. Approval of the Research Ethical Committee of the Faculty of Dentistry, Suez Canal University (28/2017) was obtained before starting the study.

### Patient's selection

#### Inclusion criteria:

- Single maxillary rooted teeth, which was indicated for replacement with dental implant.
- Good oral hygiene condition.
- Healthy patient with no medical history of any systemic disease that might contraindicate implant surgery or might complicate the healing process as (sever liver or kidney disease).
- Adequate alveolar bone dimensions for implant replacement.
- Co-operative non-smoker patient.
- A standard digital panoramic radiograph was taken for each patient to ensure that the alveolar ridge was free from any local pathology.

#### Exclusion criteria:

- Patient with peri-apical pathology or bone resorption.
- Patient with smoking habits.
- Patient with para-functional habits such as bruxism and clenching.
- Patient with abnormal occlusal relationship that may complicate the future restoration

- Patient with any systemic disease as uncontrolled diabetic or osteoporosis
- Patient undergoing chemotherapy or radio-therapy, immune-compromised patient.

All the selected participated patients were given necessary information about the implant procedures including its prognosis, potential hazards, complications and they offered their agreement to join in a written informed consent.

### **I- Preoperative Phase:**

#### **A- Health and personal history:**

Detailed preoperative data were collected from all patients through a printed questionnaire and discussion which included:

1. Person's name, age, sex, job and address.
2. Medical history.
3. Dental history and habits.

#### **B- Clinical Examination:**

Examination of oral tissues was done to assess:

1. Existing alveolar contour, height, and width.
2. Soft tissue attachments for any signs of inflammation, ulceration or scar formation.

#### **C- Radiographic Examination:**

Preoperative cone beam CT photos were taken for each selected patient to assess the following:

1. The length and width of the tooth for proper selection of the implant needed for the surgery.
2. Bone quantity, quality, mesio-distal distance and bucco-lingual dimensions of the potential site for implant insertion.

3. Relation to the anatomic structures as nasal cavity or maxillary sinus.
4. Presence of any periapical pathology.

#### **D- Patient Preparation:**

1. Diagnostic casts construction to evaluate the intermaxillary space and the type of occlusion.
2. All patients were subjected for scaling and root planning before the surgical procedure to ensure and maintain good oral health.

#### **E- Preoperative instructions:**

1. All patients obtained severe oral hygiene practice to preserve periodontal well-being in the form tooth brushing and oral mouth wash using "Antiseptol\*" three times per daily.

2. Each patient was instructed to administer oral prophylactic antibiotic Augmentin\*\* twice daily one day prior surgery.

### **II-Surgical phase:**

- The patients were questioned to thoroughly wash (Antiseptol) before surgical procedure
- The surgical procedures were done under local anesthesia using Articaine\*\*\*\* (4%) anesthesia was administered to the patient a few minutes before surgery.

\* 0.12% chlorhexidine gluconate manufactured by kahira pharmaceutical company

\*\* Amoxicillin 875mg. & Clavulanic acid 125mg manufactured by Glaxowellcome.co

\*\*\* Articaine hydrochloride (Artinibsa) 40mg (4%) + Epinephrine 0.01mg manufactured by Pharmaceutical Analyst

- The oral cavity was scrubbed using Betadine\* antiseptic solution and the patients were draped using sterile towels according to the standard technique of intraoral surgery.
- A gingival incision was made using bard parker No3 with blade #15 exposing the tooth or remaining root to be extracted.
- The tooth was extracted a traumatically using the periosteal elevator. The periosteal elevator was applied around the tooth to be extracted to cut and tear the periodontal ligaments. The suitable forceps was used with simple rotatory movement taking care to maintain the facial and palatal walls of the socket virtually intact.
- The socket was carefully degranulated by careful curettage using small curette and proper irrigation with saline solution to get rid of any connective tissue tags or periodontal ligaments remnants.
- The root diameter was measured by using caliber to determine the diameter (mesio-distal and bucco-palatal) and the depth gauge to determine the depth of the fresh extracted bony socket to select the appropriate implant. The implant should be as wide as permissible to allow maximum bone engagement with minimum thickness of facial and palatal walls not less than 1 mm. The implant should extend 3 to 5mm beyond the apex of the extracted root to achieve primary stability of the fixture.
- **OXY (K1)** \*\* implant system was used.
- The pilot hole was drilled using a twist drill of 2 mm diameter to the planed depth, which was extended to 3 - 5 mm apical to the depth of fresh extracted bony socket.
- As the implant is a self-tapping, it was inserted to 2/3 of its length under finger pressure by screw driver followed by slight tapping.
- Manual calibrated ratchet was used to place the implant in its final position (insertion torque was more than 45 NC). The implant was screwed into bone till the implant was below the alveolar bone crest by 2mm (submerged implant).
- The cover screw was screwed in place.
- The bony defect around each implant was measured by using special caliber.
- In-group 1 (control) no bone graft was placed.
- In-group 2 (test) the surrounding space, among the implant surfaces and the walls of the socket, was packed with allograft bone gel (c blast putty) material around the implant.
- Interdental papillae mesial and distal to each implant were sutured in an interrupted matters suture using black silk non resorbable suture material.

### III-Post- operative care:

- Patients were instructed to apply cold packs over the surgical area extra-orally 15 min/hr. for the first six hours post-operatively.
- Oral regimen of **Augmentin** 1gm/ 12hr was continued for five days post- operatively.
- **Cataflam** \*\*\*50mg was given two-times/day for five days post operatively.
- After the first twenty-four hours patients were instructed to use **Antiseptol 0.12%** mouth wash 4 times per day.

\* Povidone-iodine (PVP-I) Manufactured by: The Nile Co. for Pharmaceuticals and Chemical Industries – A.R.E

\*\* Oxy (k1) is manufactured by Biomec s.r.l.Via Nazionale Nord 21/A 23823 collco (Lc) Italy

\*\*\* Diclofenac-potassium manufactured by Novartis

**IV- Post-operative follow-up:**

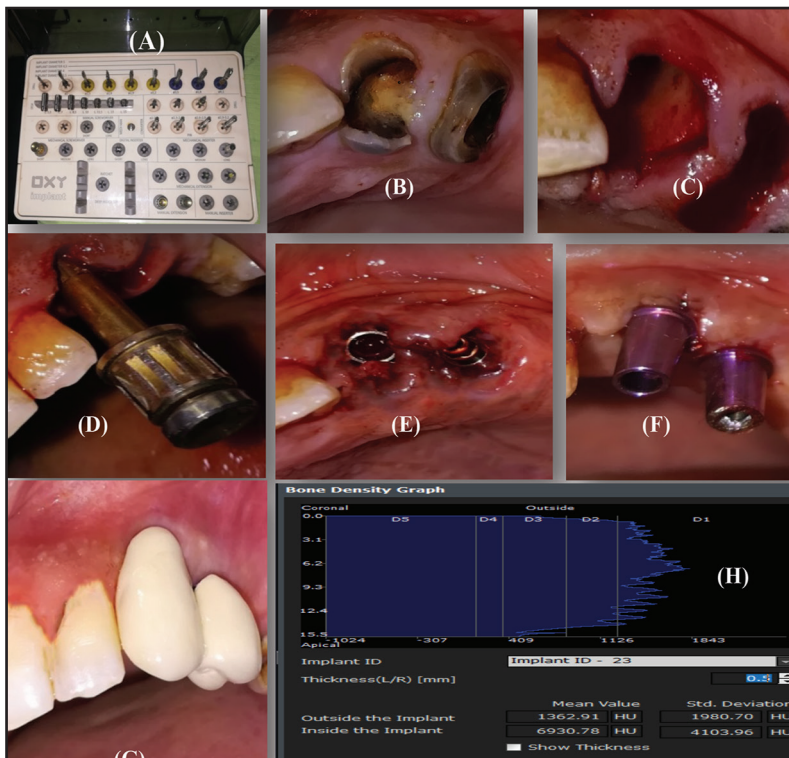
**I- Clinical Evaluation:**

- Patients were recalled 24 hours the next day after surgery to evaluate clinically the presence of delayed bleeding or post-operative complications as redness, edema, swelling at surgical site, wound dehiscence, pain, discomfort or implant looseness
- One week postoperatively the stitches were removed and immediate loading of each implant was done as the cover screw was replaced by the abutment and temporary veneer was delivered where it is free of occlusion.
- Functional final ceramic were delivered 6 months postoperatively.
- Regular check-ups were done on weekly bases during the first 15 days then 90 and 270 day postoperatively.

**II- Radiographic assessment:**

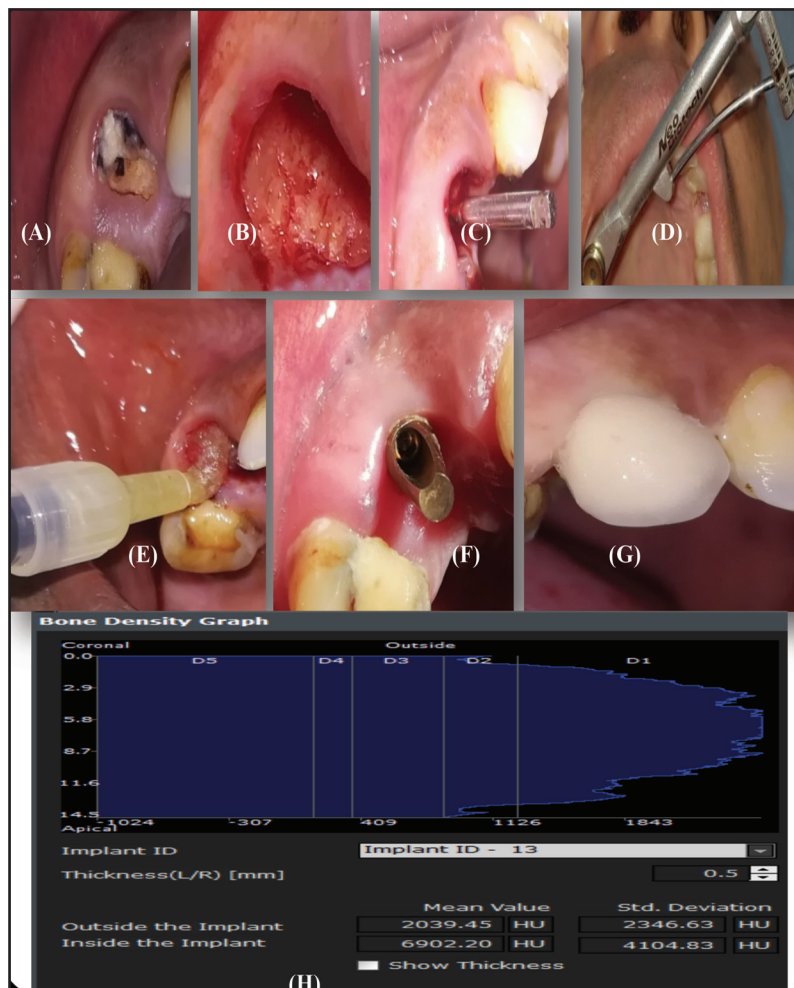
Cone beam computed tomography(CBCT) using the Scanora 3D imaging system was used for each patient to measure the bone density of the formed bone between living bone and the surface of an implant, at the intervals 15 days, 90 and 270 days post-operatively. Relative bone density (RBD) around the implants was measured using On-Demand software, by placement a simulated implant and adjusted to the same measurements and position, then measured the relative bone density using the verification tool in the software.

- All gathered data for the two investigated groups were statistically analyzed by using t.test.



**Case of control group**

Fig. (1) Showing: (A) surgical kit of oxy implant system (B) the case preoperatively. (C) The socket after atraumatic extraction. (D) Insertion of implant by screw driver and its direction.(E) Final position of the implant after drilling.(F) Abutment connected to the implant (G) Insertion of temporary veneer. (H) bone density reading around inserted implant after nine months.



**Case of test group**

Fig. (2) Showing: (A) the case preoperatively. (B) The socket after atraumatic extraction. (c) The direction of inserted implant. (D) Final position of the inserted implant by manual calibrated torque gauge ratchet. (E) Allograft bone gel around the implant. (F) Abutment connected to the fixture. (G) Cementation of temporary veneer. (H) bone density reading around inserted implant after nine months.

**RESULTS**

**Analytical statistics**

**Comparison of bone density between two groups**

- Comparison of bone density measures between groups at different observation times.
- For all observation times, Study group showed significant higher bone density than control group (Independent samples t-test,  $P < .001$ )
- After two weeks, there was a significant difference between groups ( $p < .001$ ). The mean of

bone density measures in study group showed higher density values ( $1155.14 \pm 60.54$ ) than that in control group ( $897.14 \pm 26.97$ ), table 1.

- After 3 months, there was a significant difference between groups ( $p < .001$ ). The mean of bone density measures in study group showed significant higher density values ( $1339.14 \pm 69.60$ ) than that control group ( $1033.71 \pm 31.73$ ).
- After 9 months, there was a significant difference between groups ( $p < .001$ ). The mean of bone density measures in study group showed highly significant density values ( $1973.29 \pm 56.28$ ) than that control group ( $1318.29 \pm 60.25$ ) fig 3.

**Table 1.** Comparison of bone density measures between two groups at different observation times

	X	SD	X	SD	X	SD
Control group	897.14	26.97	1033.71	31.73	1318.29	60.25
Study group	1155.14	60.54	1339.14	69.60	1973.29	56.28
Independent t-test (p value)	<.001*		<.001*		<.001*	

X: mean, SD, standard deviation, \* p is significant at 5%.

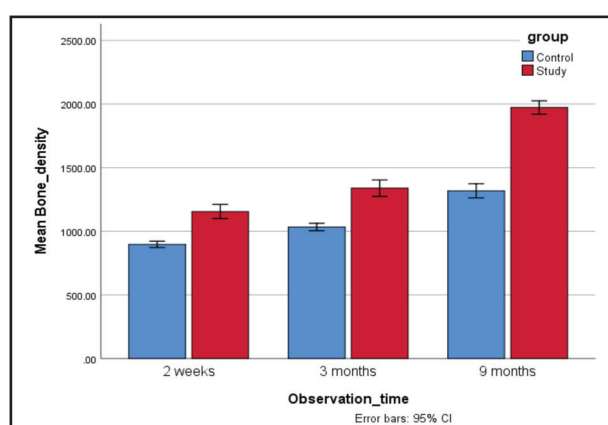


Fig. (3) Showing: Comparison of bone density measures between two groups at different observation times

## DISCUSSION

Recently immediate loading implant rehabilitation is a well approved and documented procedure<sup>(10)</sup>.

**Cavallaro et al<sup>(11)</sup>**, concluded that when the treatment planned for extraction and potential immediate implant therapy, removal of the teeth the teeth should be in the most a traumatic method likely. Forces should be realistic with low rate and extraordinary time to reduce trauma to adjacent hard tissues and the section of multi-rooted teeth must be employed to prevent damage to facial plate and furcal bone, especially for molars. This is in agreement with the surgical protocol that was applied in the current study and confirmed by the clinical

evaluations: no signs or symptoms of pain, tenderness, redness, inflammation of soft tissue around the inserted implant site or implant looseness was detected.

In the present study, each fixture was inserted parallel to neighboring teeth, centralized mesio-distally and slightly palatally according to the study design. This is concur with **Rojas-Vizcaya<sup>(12)</sup>** who concluded that the site and angulation of the implant should mainly be chosen primarily by determinants such as the need to achieve adequate primary stability and to be in line with an appropriately recognized restoratively driven plan.

According to present study protocol ,immediate loading implant was selected as the torque of insertion for each implant was more than 45 Ncm.This concomitant with **Benic et al<sup>(13)</sup>** and **Gallucci et al<sup>(14)</sup>** who mentioned that one of the essential factors to make immediate loading , the implants must be inserted with a torque  $\geq 20$  to 45 Ncm .

While **Otoni et al<sup>(15)</sup>** found that immediate loading implants would contribute to the improvement of efficient bone and better bone implant contact area, resulting in enhanced osseointegration. This agree with the present study as the control group showing progressive bone formation alongside the bone implant surfaces where the bone density measures were increased recorded by cone-beam CT through the study intervals.

**Fujioka- Kobayashi et al**<sup>(16)</sup> mention that the location of implants during placement should be more palatally. During immediate implant placement, this makes buccal ‘gap’ between the exposed implant surface and the buccal bone. This gap may then be packed with a variety of biomaterials capable of inducing bone formation.

**Tuli and Singh** described that demineralized bone-matrix demonstrated to be a highly osteoinductive and readily osteoconductive material. The graft did not suggest any substantial local foreign-body or immunogenic reaction. The high degree of success in bridging great bone defects<sup>(17)</sup>.

Also **Jones et al**<sup>(18)</sup> explained, that Demineralized bone matrix is an osteoconductive and osteoinductive allograft product.

This is agree with the present study that investigated the effects of commercially recent marketing available allograft bone gel (Demineralized bone matrix(DBM) with cancellous bone (CB) and carboxymethyle cellulose ) on the fixation of porous-coated titanium implants. The results showed that the combination of DBM with CB stimulates bone formation and bone growth alongside the implants surface (study group) compared to implants without allograft bone gel(control group) . The result of the present study was showed that immediate loading implant survival rate was 100% during nine months follow-up, this is concomitant with **Cornelini et- al and Becker et-al**<sup>(19-20)</sup> who reported the same result after one year follow up. Although **Schwartz et-al**<sup>(21)</sup> reported that the survival rate immediate loading implant was 95% success rates with 5% failures in the 1st year of their study, they concluded that there seems to the need for immediate functional loading of implants into fresh extraction sockets.

According to the current study design the immediate nonfunctional loading implant in the up-

per anterior following augmentation with allograft bone gel (Demineralized bone matrix(DBM) with cancellous bone (CB) and carboxymethyle cellulose ) showed the high success rate clinically and radiographically. This agrees with **Nissan et al**<sup>(22)</sup> who concluded that immediate nonfunctional loading of single-tooth implants in the upper anterior following augmentation with freeze-dried cancellous block grafts and healing can result in successful implant integration and stable peri-implant conditions up to 18 months.

**Roni et al**<sup>(23)</sup> found that using of bone allografts and temporary acrylic restorations has been presented to develop the soft tissue height and thickness compared to those in the control .Also the current study confirm the positive contributions of the offered regenerative techniques in terms of osseous volume preservation during implant placement. Moreover, no bone loss occurred in the interproximal region and, on the contrary, positive bone crestal was commonly observed, may also indicate that a similar behavior occurs at the buccal and lingual aspects of the implant where follow up extended up to 8 years. This concomitant with the clinical results of present study and high bone density values of study group recorded through study intervals.

## CONCLUSION AND RECOMMENDATIONS

Immediate loading implant placement in esthetic zone becomes good promise technique provided that follows the strict surgical and prosthetic protocols.

Allograft bone gel(C blast putty gel) has many advantages as easy manipulation and fills the gap around the implant surface even inaccessible area.

Allograft bone gel(C blast putty gel) shows effective role in implant osseointegration as the bone formation density measures around the implant in test <sup>group</sup> showed highly significant increase more



than that in control group through the study intervals. More clinical and radiographic studies are needed in order to evaluate allograft bone gel (C blast putty) around dental implant for immediate functional loading.

Additional scientific and radiographic studies are needed to compare allograft bone gel (c blast putty) and other bone graft materials.

## REFERENCES

1. Chrcanovic BR, Albrektsson T, Wennerberg A. "Immediate nonfunctional versus immediate functional loading and dental implant failure rates: a systematic review and meta-analysis". *J Dent* 2014; 42: 1052-1059.
2. Maj Gen JP. "Comparative study of immediate functional loading and immediate non-functional loading of mono-cortical implants". *Med J Armed Forces India* 2015; 71:333-339.
3. Misch CE, Wang HL, Misch CM. Rationale for the use of immediate load in implant dentistry: element I. *J Impl Dent* 2004; 13:207-217.
4. Henningsen A. "The feasibility of immediately loading dental implants in edentulous jaws". *J Periodontal Impl Sci* 2016; 46:234-243.
5. Levitt D. Atraumatic extraction and root retrieval the use of the perioste: a precursor to immediate placement of dental implants. *Dent Today* 2001; 20:53-57.
6. Adell R, Eriksson B, Lekholm U, Branemark PI, Jemt T. Long-term follow-up study of osseointegrated implants in the treatment of totally edentulous jaws. *Int J Oral Maxillofac Implants*. 1990; 5:347-359
7. Zhao R, Yang R, Cooper P R, Khurshid Z, Shavandi A, Ratnayake J. Bone Grafts and Substitutes in Dentistry: A Review of Current Trends and Developments. *Molecules* 2021; 26: 3007.
8. Malinin TI, Temple HT, Garg AK. Bone allografts in dentistry: an evaluation. *J Dent* 2014; 4: 1122-2161.
9. Nissan J, Romanos GE, Mardinger O, Chaushu G. Immediate Nonfunctional Loading of Single-Tooth Implants withinside the Anterior Maxilla Following Augmentation with Freeze-Dried Cancellous Block Allograft:A Case Series. *Int J Oral Maxillofac Impl* 2008; 23:709-716
10. Sennerby L, Gottlow J. Clinical effects of immediate/early loading of dental implants. A literature review of recent controlled prospective clinical studies. *Aust Dent J* 2008; 53: 82-88.
11. Cavallaro J, Greenstein G, Tarnow DP. Clinical pearls for surgical implant dentistry, portion 3. *Dent Today* 2010; 29:134-139.
12. Rojas-Vizcaya F. Biological features as a rule for single implant insertion. *Clin J Prosth* 2013; 22:575-580.
13. Benic GI, Mir-Mari J, Hämmerle CH. Loading protocols for single-implant crowns: a systematic review and meta-analysis. *Int J Oral Maxillofac Impl* 2014; 29: 222-238.
14. Gallucci GO, Benic GI, Eckert SE, Papaspyridakos P, Schimmel M. Consensus statements and clinical approvals for implant loading procedures. *Int J Oral Maxillofac Impl* 2014; 29: 287-290.
15. Ottoni jm, Oliveira ZF, Mansini R, Cabral AM. Correlation among insertion torque and survival of single tooth implant. *Int J Oral Maxillofac impl* 2005; 20:769-776.
16. Fujioka-Kobayashi M, Schaller B, Saulacic N, Zhang Y, Miron RJ. Growth factor delivery of BMP9 the use of a unique natural bovine bone graft with integrated atelocollagen type1: Biosynthesis, characterization, and cell behavior. *J Biomed Mat Res* 2017; 105:408-418.
17. Tuli SM, Singh AD. The osteoinductive property of decalcified bone matrix. An experimental study. *J bone Joint Surg Br* 1976; 60:116-123.
18. Jones CB. Biological basis of fracture healing. *J Orthop Truma* 2005; 19: 1-3.
19. Cornelini R, Scarano A, Covani U, Petrone G, Piattelli A. Immediate single stage postextraction implant: a human clinical and histologic case report. *Int J Oral Maxillofac Impl* 2000; 15:432-437.
20. Becker W, Clokie C, Sennerby L, Urist MR, Becker BE. Histologic findings after implantation and assessment of different grafting materials and titanium micro screws into extraction sockets: case reports. *J Periodontol* 1998; 69:414-421.

21. Schwartz-Arad D, Yaniv Y, Levin L, Kaffe I. A radiographic assessment of cervical bone loss related with immediate and delayed implants placed for fixed restorations in edentulous jaws. *J Periodontol* 2004; 75:652–657.
22. Nissan J, Romanos GE, Mardinger O, Chaushu G. Immediate Nonfunctional Loading of Single-Tooth Implants withinside the Anterior Maxilla Following Augmentation with Freeze-Dried Cancellous Block Allograft:A Case Series. *Int J Oral Maxillofac Impl* 2008; 23:709–716
23. Roni K, Nayrouz Q, Eitan B, Eitan M, Liat C, Haim T, Joseph N. Allograft and Collagen Membrane Augmentation Procedures Preserve the Bone Level around Implants after Immediate Placement and Restoration. *Int. J. Environ. Res. public health* 2020; 17:1133-1148