

Role of CT Angiography in Reliability of Distally Based Hemisoleus Muscle Flap for Lower Third Leg Defects

Mohamed Fahmy Gaafar^{1,*} Msc., Magdy Ahmed Abd Alkarem¹ MD., Mahmoud Ibrahim EL Shamy² MD. and Ahmed Abu El Soud Salim¹ MD.

* *Corresponding Author:*

Mohamed Fahmy Gaafar
mohamed.gaafar201317@gmail.com

Received for publication February 27, 2022; Accepted August 31, 2022; Published online August 31, 2022.

Copyright 2020 The Authors published by Al-Azhar University, Faculty of Medicine, Cairo, Egypt. All rights reserved. This an open-access article distributed under the legal terms, where it is permissible to download and share the work provided it is properly cited. The work cannot be changed in any way or used commercially.

doi: 10.21608/aimj.2022.124373.1856

¹Department of Plastic, Reconstructive and Burn Surgery, Faculty of Medicine, Al-Azhar University, Cairo, Egypt.

²Department of Diagnostic Radiology, Faculty of Medicine, Al-Azhar University, Cairo, Egypt.

INTRODUCTION

The relatively unprotected antero medial part of the tibia is risky for bony exposure following trauma. Due to complexity of the defect, leg soft tissue coverage remains a challenge to plastic surgeons.¹

The aim of lower extremity reconstruction is defect coverage, salvages the limb with good functional and aesthetic outcome.²

The reconstructive ladder offers a list of options in terms in surgical closure of the wound and should consider all options including free flap reconstruction.³

Perforator flaps from posterior tibial and peroneal arteries gained a high popularity due to their main advantages: decreasing donor-site morbidity and improving aesthetic outcome.⁴

The usage of a muscle flap to cover exposed bone and tendon is not only from its ability to cover the defect, but also introduce a new vascular bed to potentiate wound healing.⁵

The use of distally based muscle flap in the lower distal third of the leg is often associated with high failure rates, especially in patients with comorbidities affecting vascular function (venous insufficiency,

ABSTRACT

Background: Leg injuries frequently lead to soft tissues losses and skin defects and are commonly associated with bony fractures or even bony defects. These damages may be severe enough to be associated with major leg vessel injuries rendering reconstructive options limited.

Aim of the work: Evaluation of role of CT-angiography to expect site, extent, course, and calibre of the pedicle of distally based hemisoleus flap to make this a reliable choice for lower third leg defects.

Patients and Methods: This work has been conducted at the plastic surgery department Al Azhar university hospitals from October 2018 till July 2021. Thirty patients are included in this study (22 male and 8 female). All patients injected with Optiray 350 (radiopaque contrast agent) and CT angiography to the affected limb was done with identification of distal pedicles to soleus and distally based hemisoleus muscle flap was done.

Result: The distal soleus pedicle by CT angiography was at 6 cm above medial malleolus in 6 patients, at 6.5 cm in 6 patients, at 7 cm in 3 patients, at 7.5 cm in 2 patients, at 8 cm in 3 patients, at 8.5 cm in 1 patient, at 9 cm in 3 patients, at 9.5 cm in 2 patients and at 10 cm in 4 patients.

Conclusion: In 56.7% (17 cases) accurate CT findings in relation to surgical findings, in 40% (12 cases) 0.5 cm difference, in 3.3% (1 case) 1 cm difference. So performance of angio-CT simplifies operative planning, decrease operative time, and makes operation more safe.

Keywords: CT-angiography; Hemisoleus; Lower third leg defects.

Disclosure: The authors have no financial interest to declare in relation to the content of this article. The Article Processing Charge was paid for by the authors.

Authorship: All authors have a substantial contribution to the article.

peripheral vasculopathy, diabetes mellitus)⁶, In 2012 Wolff et al. described for the first time, the use of CTA to plan perforator flaps from the lateral lower leg.⁷

As per Mathes and Nahai classification the blood source to the soleus is type-II, received by main pedicle(s) in addition to minor pedicle(s). The main pedicles comprise the branches of popliteal, posterior tibial and proximal peroneal artery. The minor pedicles come from posterior tibial and peroneal artery from its distal part⁸.

Yajima et al., found that the most distal soleus perforator was found at fixed distance of about 6,1 – 14,5cm above the medial malleolus.⁹

Shaker studied the site of the second most distal perforator of soleus muscle and it was found to be at a distance of 15cm or more above the medial malleolus in 50% of his dissections.¹⁰

Al Shahat et al. showed The distance of posterior tibial artery perforators to medial malleolus was 1st perforator range 8cm to 9.5 cm, the 2nd perforator range 11.2 cm to 12.5 cm, the 3rd perforator range 16cm to 18 cm and the 4th perforator range 21.2 cm to 23 cm.¹¹

The aim of this study is to evaluate the role of CT-Angiography to expect site, extent, course, caliber

and number of the secondary minor pedicle of distally based hemi-soleus muscles flaps. To confirm that a distally based hemisoleus is a reliable option for the defect present in lower third leg or its not valid and another flap to be considered.

PATIENTS AND METHODS

This work has been performed at the plastic surgery department. Al Azhar university hospitals from October 2018 till July 2022. Thirty patients are included in this study (22 male and 8 female). All patients were suffering from soft tissues defect of the legs lower third due to trauma(22 patients), Osteomyelitis or unstable scar(3 patients), and Tumor resection(5 patients) and were in need for flaps coverage. Age range 19-48 years old with mean

age 33.1 ± 7.09 years, with no major life threatening injuries or uncontrolled medical conditions.

Preoperatively:

Radiological: Plane X-ray to detect bone fractures or osteomyelitis,

Preoperative CTA-evaluation: The CTA analyses has been done via a multislice scanner with 128-row multi-detector CT (GE 128 slice CT scan machine). The position of the case throughout the CTA evaluation was in conformity with the location to be held in the surgical room throughout the surgery. The distal soleus perforators were investigated for the site and course and caliber by extreme intensity projections and size rendering. The positions of the perforators were labeled on the skin of the case in connection to fixed bony land-marks (malleoli).

Parameter	Description
Scanner	GE 128 Slice CT scan machine
Slice thickness	128-detector row, 0.625 mm collimator width
Helical detector pitch	0.9375
Gantry rotation speed	0.6 sec/rotation
Tube potential	120 KV
Tube current	469 mA
Contrast Injection rate	Optiray 350, 100 ml IV injection 4 ml/sec
Scanning range: Thigh	iliac spine to knee
Leg	From knee to ankle
Scanning direction	Cranial to caudal
Bolus tracking method	From the descending aorta (130 HU)
Scan time: Thigh	10 sec
Leg	15 sec
Imaging reconstruction	MIP(Maximum Intensity Projection), VR(volume-rendering)
Thickness	1.0 mm
Increment	0.7 mm

Table 1: Computed tomographic angiography acquisition data

Surgical procedures: Under spinal or general Anesthesia, patient in supine Position with semi flexed knee during flap harvest and extended at flap sitting, pre operative flap design and markings of CT angiography findings on the leg. Debridement of devitalized tissues at the defect, a longitudinal cutaneous incision is performed on the medial-side of the leg 1cm parallel to the medial border of the tibia. The major and secondary pedicles identified. Careful meticulous dissection of the secondary pedicles that were identified by CT angiography preoperative to enables a larger arc of rotation and, consequently, greater flap reach. The most distal secondary pedicles identified by MD CT angiography were ranging from 6 to 10 cm above medial malleolus, Such perforators appears with small caliber about 1.1 to 1.5 mm and directed medially within the distal soleus muscle. The flap is then rotated to the defect and covered with partial-thickness skin grafts. The donor site is closed directly with Suction drains are used and non-compressive dressing with immobilization.

RESULTS

Number of patients	Site of Distal perforator from P.T.A by CTA in relation to medial malleolus
6	6 cm
6	6.5 cm
3	7 cm
2	7.5 cm
3	8 cm
1	8.5 cm
3	9 cm
2	9.5 cm
4	10 cm

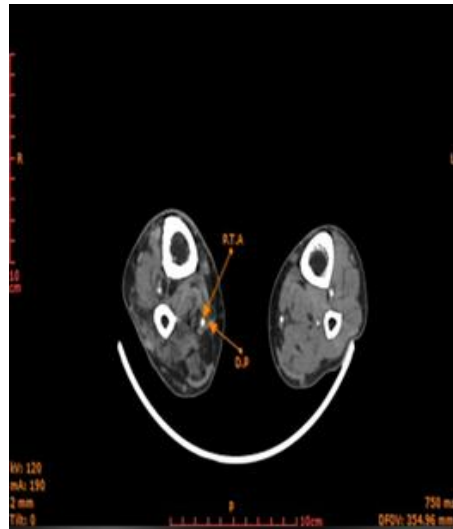
Table 2: CT Angiography findings.

Surgical findings in relation to CT angiography	Number of patients
Accurate	17
0.5 cm difference	12
1 cm difference	1

Table 3: Operative findings.

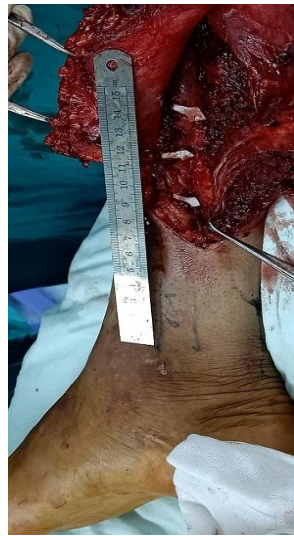
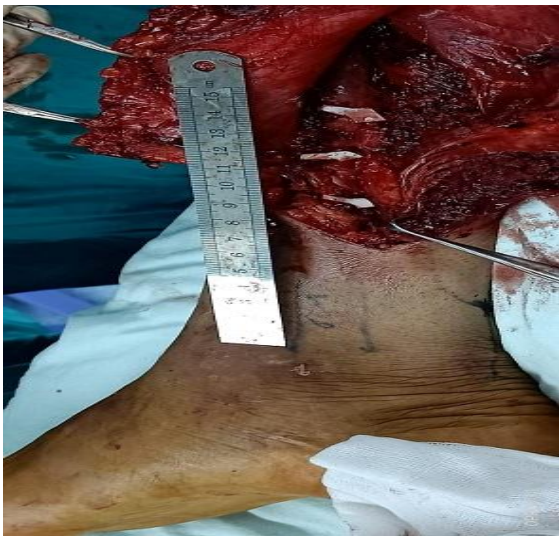
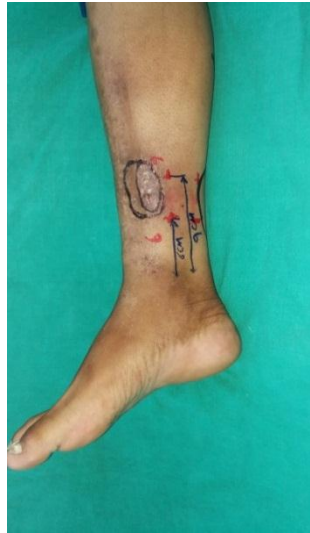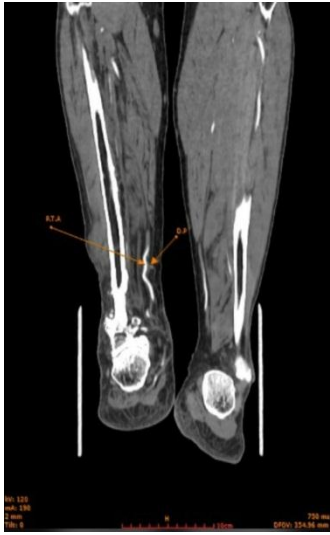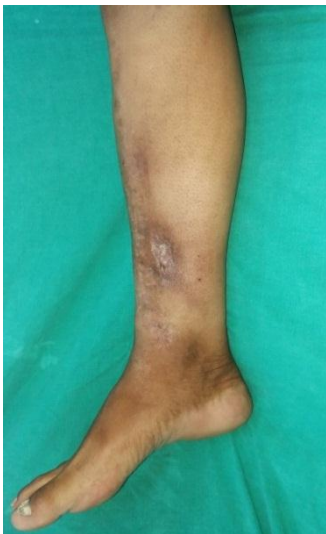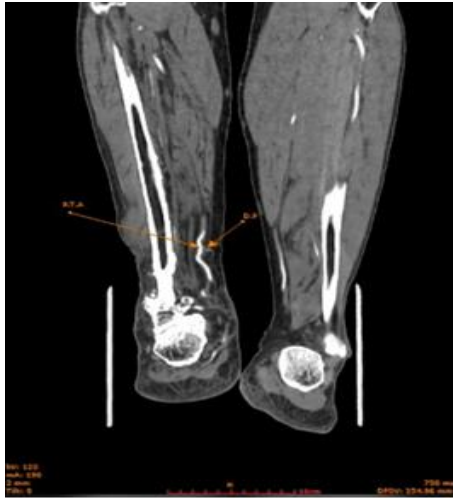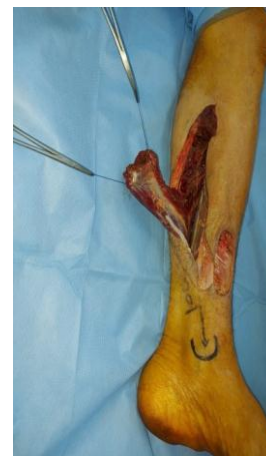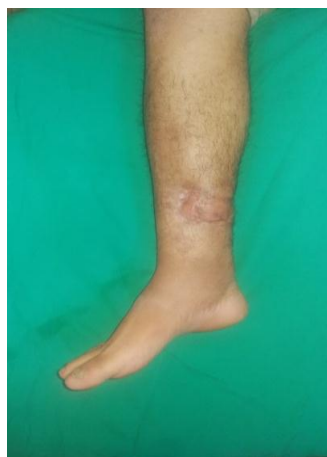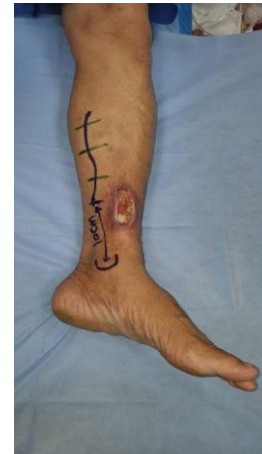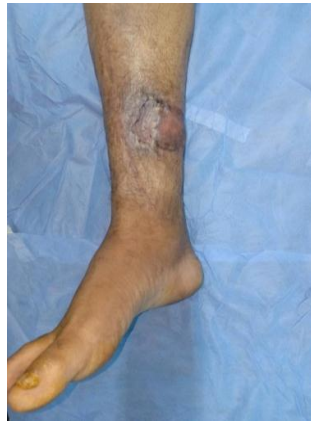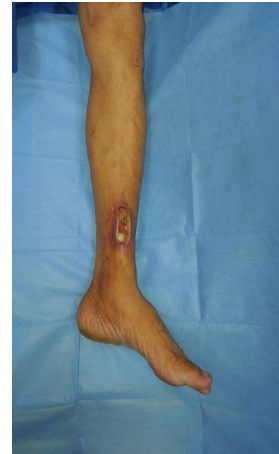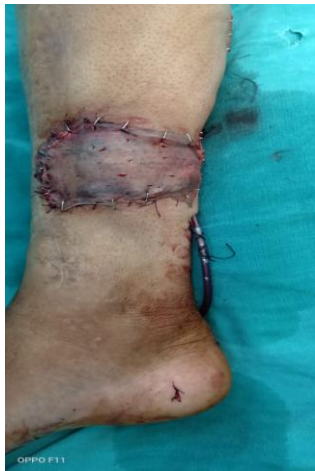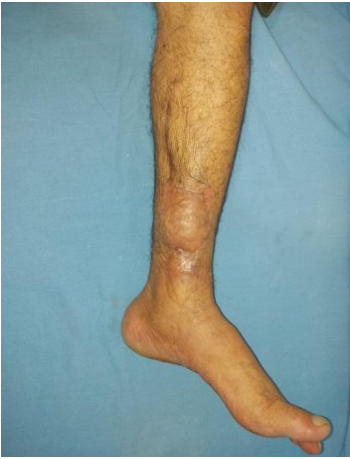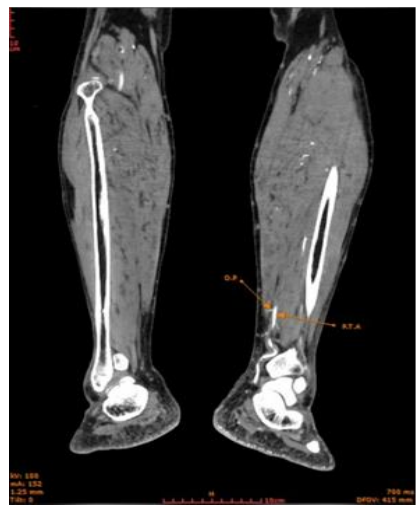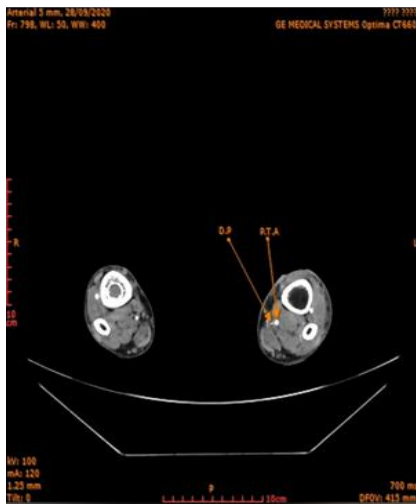
Fig 1: Correlation between pre operative CT angiography findings and intra operative clinical findings of the distal soleus muscle perforator with exact location.



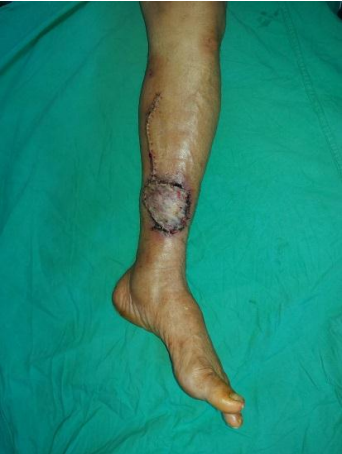
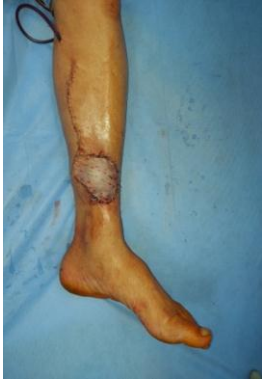
Clinical example 1: 41 years old male patient with post traumatic chronic unstable scar with multiple sinus in the lower third of Rt leg (A) pre operative (B) marking of CT angiography perforator findings (C) Intra operative distal pedicles identification with the most distal pedicle about 9 cm above medial malleolus. (D&E) Axial and Coronal CT Angiography with identification of distal perforator (D.P) to soleus muscle originating from posterior tibial artery (P.T.A) about 9 cm above medial malleolus with caliber about 1.2 mm. (F) Immediate post operative (G) After 1 month (H) 3 months post operative follow up.





Clinical example 2: 49 years old male patient with post traumatic raw area in the distal third of the lt leg (A) pre-operative (B) markings (C) flap harvest with distal pedicle identification about 10 cm above medial malleolus (D&E) Axial and coronal cuts of CT Angiography with identification of distal perforator (D.P) to soleus muscle originating from posterior tibial artery (P.T.A) about 10 cm above medial malleolus and caliber about 1.1 mm. (F) immediate post-operative (G) 1 week post-operative (H) 3 months post-operative follow up.



DISCUSSION

High energy leg injuries frequently lead to soft tissues losses and skin imperfections and are commonly associated with bony fractures or even bony defects. These damages may be severe enough to be associated with major leg vessel injuries rendering reconstructive options limited. The lower one third skin defects of leg frequently represented a reconstructive challenging and the use of local skin flaps and distally based fasciocutaneous flaps can be restricted particularly if their vascular pedicles fall within the area of injuries.¹²

The reversed flow hemi-soleus flap with sacrifice of the posterior tibial artery to be included within the flaps was defined by Guyron in 1982. But the flaps didn't became more popular as it has the great disadvantage of sacrificing main blood vessels.¹³

The distally based medial hemisoleus flap was first described by Tobin in 1985 and associated high complication rate.

This work aim to assess the usage of CTA as adjunctive procedure to expect site, course, and calibre of the pedicle of distally based hemisoleus perforator flap to make this a more reliable choice for lower third leg defects to decrease complication rate with preservation of the major leg vessels.

This study included 30 patients (22 males and 8 females) all with lower third leg defects caused by deferent causes mostly post traumatic, all cases managed with distally based medial hemisoleus muscle flap based on distal secondary pedicle that preoperatively was identified by CT angiography using GE 128 Slice CT scan machine with injected Optiray 350 (radiopaque contrast agent), The most distal secondary pedicles were ranging from 6 to 10 cm above medial malleolus, Such perforators appears with caliber about 1.1 to 1.5 mm and directed medially within the distal soleus muscle.

All perforators identified by the CT angiography examinations were located intraoperatively nearly the same site in 17 cases. The distances between the intraoperational positions of the perforators and the positions established by the CT angiography analysis were 0.5 cm in 12 cases and 1 cm in 1 case.

Our study can be supported by the study by Higuera et al.,¹⁴ aimed to describe CTA as a planning tool in perforator flap operations in the lower limbs. The study enrolled 18 cases underwent perforator flaps for lower limb reconstruction. Ages mean was 57-yrs old. 9 cases (50%) were male.

As well the study by Feng et al.,¹⁵ matched the utilization of color Doppler US and CTA in pre-operative planning of lower limb perforator flap. They enrolled 40 cases with lower extremities defects who undergoing reconstruction with perforator flap.

In a series of 10 cases, Houdek et al.,¹⁶ performed a preoperative CT Angio to assess the posterior tibial vessels pedicle(s) to the distal soleus muscle, they also performed interoperative confirmation of the pedicle before flap harvest. They recommended a caliber of 1mm minimum for the distal arterial perforator and a caliber of 1.5mm or more for the accompanying vein to ensure flap reliability for Coverage of Distal Third Leg Wounds. The mean defect measured 23 cm² (range 8–45 cm²)

As regard Clinical characteristics of the soft tissue defects of the studied patients we found that the mean lesion size 29.0 ± 7.58 cm², 20 patients (66.7%) had the lesion on the right-side, and 10 cases (33.3%) had the lesion on the left-side. Meanwhile, 7 patients (23.3%) had bone fracture.

Regarding postoperative complications of the studied patients, 1 patient suffered from partial loss of the flap that healed by secondary intention and 2 patients (6.7%) suffered from graft loss due to congestion that were re grafted. Finally, there were 27 patients (90%) were excellent, 2 patients (6.7%) were good, and one patient (3.3%) were poor.

Whereas the study by Higuera et al.,¹⁴ reported that the evaluation of all flaps was acceptable, excluding in 3 cases with peroneal artery perforator flaps, which existing necrosis of the distal part because of venous congestions and healed by secondary intentions. These flaps were maybe overfilled owing to an improper location, twisted pedicle or attendant pathology. So, they settled that the usage of CTA scanning was precise and a beneficial in surgical planning, easing more precise flaps designs and straight closures later.

The study by Feng et al.,¹⁵ reported that all cases have no complications except 2 cases have necrosis in the distal area of the flaps (2 × 2 cm). There was 95% success rate. Based on their comparative study of color Doppler US and CTA in the pre-operative mapping of lower limbs perforators. As well, color Doppler US still the only choice for cases with an allergy to the difference or in cases of renal deficiency.

Furthermore, the study by Houdek et al.,¹⁶ reported successful reconstruction in all cases, with only minor flap tip loss in one patient. Deserving mention, repeat skin grafting was needed in 4 out of the 10 cases.

CONCLUSION

CT Angiography has a great role to identify the distal perforators of soleus muscle (site, caliber and course) with great role to detect pre-operative viability that make distally based hemisoleus muscle flap a reliable option for lower third leg defects. This method simplifies operative planning, may decrease operative period, rises the consistency of the usage of these flaps and makes operation more safe.

REFERENCES

1. Ahmad I, Akhtar S, Rashidi E, Khurram MF. Hemisoleus muscle flap in the reconstruction of exposed bones in the lower limb. *J Wound Care*. 2013; 22 (11): 635, 638-40, 642. doi: [10.12968/jowc.2013.22.11.635](https://doi.org/10.12968/jowc.2013.22.11.635).
2. Lu TC, Lin CH, Lin CH, Lin YT, Chen RF, Wei FC. Versatility of the pedicled peroneal artery perforator flaps for soft-tissue coverage of the lower leg and foot defects. *J Plast Reconstr Aesthet Surg*. 2011; 64(3): 386-93. doi: [10.1016/j.bjps.2010.05.004](https://doi.org/10.1016/j.bjps.2010.05.004).
3. Jordan DJ, Malahias M, Hindocha S, Juma A. Flap decisions and options in soft tissue coverage of the lower limb. *Open Orthop J*. 2014 31;8:423-32. doi: [10.2174/1874325001408010423](https://doi.org/10.2174/1874325001408010423).
4. Georgescu AV. Propeller perforator flaps in distal lower leg: evolution and clinical applications. *Arch Plast Surg*. 2012; 39 (2):94-105. doi: [10.5999/aps.2012.39.2.94](https://doi.org/10.5999/aps.2012.39.2.94)
5. Attinger CE, Ducic I, Cooper P, Zelen CM. The role of intrinsic muscle flaps of the foot for bone coverage in foot and ankle defects in diabetic and nondiabetic patients. *Plast Reconstr Surg*. 2002; 110 (4): 1047-54; discussion 1055-7. doi: [10.1097/01.PRS.0000021448.57210.52](https://doi.org/10.1097/01.PRS.0000021448.57210.52).
6. Lorenzetti F, Lazzeri D, Bonini L, Giannotti G, Piolanti N, Lisanti M, Pantaloni M. Distally based peroneus brevis muscle flap in reconstructive surgery of the lower leg: Postoperative ankle function and stability evaluation. *J Plast Reconstr Aesthet Surg*. 2010 Sep;63(9):1523-33. doi: [10.1016/j.bjps.2009.08.003](https://doi.org/10.1016/j.bjps.2009.08.003). Epub 2009.
7. Wolff KD, Bauer F, Dobritz M, Kesting MR, Kolk A. Further experience with the free soleus perforator flaps using CT-angiography as a planning tool - a preliminary study. *J Craniomaxillofac Surg*. 2012; 40(8) : e253-7. doi: [10.1016/j.jcms.2011.10.030](https://doi.org/10.1016/j.jcms.2011.10.030).

8. Prathamachandra V, Prabhu LV, Pai MM, Murlimanju BV, Vadgaonkar R. Arterial supply to the soleus muscle: an anatomical study with emphasis on its application in the pedicle flap surgery. *Surg Radiol Anat.* 2015 Nov;37(9):1055-61. doi: [10.1007/s00276-015-1485-9](https://doi.org/10.1007/s00276-015-1485-9). Epub 2015. PMID: 25957756.
9. Kauffman, C. A., Lahoda, L.-U., Cederna, P. S., & Kuzon, W. M.). Use of Soleus Muscle Flaps for Coverage of Distal Third Tibial Defects. *In Journal of Reconstructive Microsurgery.* 2004, (Vol. 20, Issue 08, pp. 593–597). Georg Thieme Verlag KG. <https://doi.org/10.1055/s-2004-861516>
10. Shaker, A. The Use of distally based hemisoleus in reconstruction of lower third leg defects. *Egypt J Plast. Reconstr. Surg,* 1998 22(2), 161-69.
11. Al-Shahat, O., Autifi, A.H., Sayed, A. and Abo-Omar, M.E, Cadaveric Study of Soleus Muscle arterial blood supply and its Application in peri-ankle Reconstruction. *Al-Azhar International Medical Journal,* 2020 vol. 1(4), pp.12-18
12. Reyad, K. A., & Setta, H. S. Re-construction of Lower One Third Leg Defects in Single Vessel Lower Limb by Medial Hemisoleus Muscle Flap Based on Distal Posterior Tibial Artery Perforators. *The Egyptian Journal of Plastic and Reconstructive Surgery,* 2018, 42(2), 291-297.
13. Faisal AA, Abdel-Hamid Romeih M, Younes LM, El-Rosasy M, Rodriguez P, Liette MD, Masadeh S. Distally Based Medial Hemisoleus Muscle Flap for Wound Coverage in the Distal Third of the Leg. *Clin Podiatr Med Surg.* 2020; 37(4): 631-47. doi: [10.1016/j.cpm.2020.05.002](https://doi.org/10.1016/j.cpm.2020.05.002).
14. Tobin GR. Hemisoleus and reversed hemisoleus flaps. *Plast Reconstr Surg.* 1985; 76(1): 87-96. doi: [10.1097/00006534-198507000-00015](https://doi.org/10.1097/00006534-198507000-00015).
15. Knitschke M, Baumgart AK, Bäcker C, et al. Computed Tomography Angiography (CTA) before Reconstructive Jaw Surgery Using Fibula Free Flap: Retrospective Analysis of Vascular Architecture. *Diagnostics (Basel).* 2021; 11(10):1865. Published 2021. doi:[10.3390/diagnostics11101865](https://doi.org/10.3390/diagnostics11101865)
16. Feng S, Min P, Grassetti L, Lazzeri D, Sadigh P, Nicoli F, Torresetti M, Gao W, di Benedetto G, Zhang W, Zhang YX. A Prospective Head-to-Head Comparison of Color Doppler Ultrasound and Computed Tomographic Angiography in the Preoperative Planning of Lower Extremity Perforator Flaps. *Plast Reconstr Surg.* 2016; 137(1): 335-47. doi: [10.1097/PRS.0000000000001895](https://doi.org/10.1097/PRS.0000000000001895).
17. Houdek MT, Wagner ER, Wyles CC, Sems SA, Moran SL. Reverse Medial Hemisoleus Flaps for Coverage of Distal Third Leg Wounds: A Technical Trick. *J Orthop Trauma.* 2016; 30(4): e138-42. doi: [10.1097/BOT.0000000000000491](https://doi.org/10.1097/BOT.0000000000000491).