

Treatment Of Fracture Base of First Metacarpel Bone (Bennet's Fracture) by Percutaneous Locked Kirschner Wires Technique

Mohammed Ahmed Shemes,¹ M.B.B.Ch, Abdel-Hakeim Massoud,¹ MD and Ehab Elzahed,¹ MD.

* Corresponding Author:

Mohammed Ahmed Shemes
shemes2019@gmail.com

Received for publication January 23, 2022; Accepted September 1, 2022; Published online September 1, 2022.

doi: 10.21608/aimj.2022.111555.1725

Citation: Mohamed AS., Abdel-Hakeim M. and Ehab E. Treatment Of Fracture Base of First Metacarpel Bone (Bennet's Fracture) by Percutaneous Locked Kirschner Wires Technique. AIMJ. 2022; Vol.3-Issue8 .7-13.

¹Orthopedic Surgery Department, Faculty of Medicine, Al-Azhar University, Cairo, Egypt.

ABSTRACT

Background: Locked K-wire technique with connector has more advantages than others technique and immediately mobilization, so life-changing events that affect the patient's life

Aim of the study: Assessment clinical and radiological outcomes of locked Kirschner-wire technique with an external connect to fixation of Bennett's fracture.

Patients and Methods: A prospective study was conducted on twenty patients having Bennett's fracture during the period between July 2019 and June 2021, those who matched completely with inclusion criteria were included and followed up for 6 months.

Results: The mean age of all studied patients was 31.8 from 18-50 years .100% male. The Interval before operation ranged from 1-14 days with mean 6.5 days. The Operative time ranged from 15- 35 minutes with mean 25.9 minutes. Web opening had 87.6% of contralateral side. Fractures healed and No signs of trapezio-metacarpal arthritis detected at the end of follow-up.

Conclusion: Treatment of Bennett's fracture by locked K-wire technique with connector is stable, safe, and minimally invasive and allow to immediately mobilization then removal Kirschner wire is easily at out office clinic.

Keywords: Methotrexate ; Triamcinolone Acetonide ; Vitiligo.

Disclosure: The authors have no financial interest to declare in relation to the content of this article. The Article Processing Charge was paid for by the authors.

Authorship: All authors have a substantial contribution to the article.

Copyright The Authors published by Al-Azhar University, Faculty of Medicine, Cairo, Egypt. Users have the right to read, download, copy, distribute, print, search, or link to the full texts of articles under the following conditions: Creative Commons Attribution-Share Alike 4.0 International Public License (CC BY-SA 4.0).

INTRODUCTION

Fractures of bones of the hand are among the commonest fractures in humans. Fractures of the first metacarpal are among commonest hand fracture and occur most frequently at the base account for 4% of hand fractures. Described in 1882 by Professor Edward Bennett.¹ Hand surgeons consider the base metacarpal intra-articular fractures of the thumb therapeutic challenge.² Its prevalence is around 1/3 of all fractures of thumb metacarpal in adults,³ with male predominance and the dominant hand usually.⁴

The mechanism of injury is compress on axis of the thumb flexed .The abductor pollicis longus and adductor pollicis action cause of the distal fragment displacement, the first web angle retraction (varus), and the dorsal dislocation causing shortening.⁵

Bennett's fracture is unstable requiring surgery at most. Several techniques are present: pinning K-wiring, open screw fixation, locking plate.^{6, 7} the percutaneous k wire fifty years ago are widely used

to minimizing adhesions of extensor apparatus. Iselin technique is a two K-wire cross extra-articular inter metacarpal fixation and more reliable.⁸ Nevertheless, complications are malunion, displacement, nonunion, infections, post traumatic arthritis, stiffness and retracted first web is very bad this complication occur related to migrating wires, so some authors suggested keeping wires connected by an external fixator to avoiding this problem.⁹

PATIENTS AND METHODS

This prospective study included twenty patients having Bennett's fractures managed with surgical fixation by locked K-wire technique with connector at the Department of Orthopedic Surgery of Al Hussein university Hospital and General Ismailia Hospital, during the period between January 2019 to June 2021. Last patient follow up period for 6 months, ended before the end of the study period. The period of follow up of the cases was 6 months. Patients selected and matched completely with

inclusion criteria were included until fully gaining required sample size.

This series including 20 patients of 27 years mean age (18 to 50 y range). all patient men, 10 Rt-sided and 10 Lt-sided fractures, 12 cases fracture in the dominant hand (10 Rt hand dominant, 2 Lt hand dominant), 8 cases in other hand. 4 students, 6 manual workers and 10 others jobs. The mechanism of injury was 4 cases a bike accident, 6 a motorcycle accident, 4 a fall on ground, 4 a sports injury, and 2 cases a punch.

Patients' selection was according to certain criteria:

Preoperative evaluation:

Clinical evaluation, Radiological evaluation (X-ray). Free written informed consent will be obtained from all patient enrolled.

Inclusion criteria:

Age; more than eighteen years old and Patients with closed Bennett's fracture.

Exclusion criteria:

Patient below the age of 18 years old, patients presenting with neurovascular injury, multiple injuries, pathological fracture, missed, old fracture, lesions will be excluded from this study. Other type of fracture metacarpal bone Comminuted fractures (Rolando fracture) and Extra articular fractures.

Life support and general management of polytrauma patients (ATLS protocol). Preoperative assessment: Patient evaluation, Radiographic Evaluation, and Planning and time of surgery.

Surgical technique

Operation of Modified Iselin technique average of 6.5 days (1 to 14 day range) from the injury. All cases general anesthesia.

First reduction of fracture (thumb traction and pressure on the base first metacarpal). Then 2 K-wires 18 mm used to keeping maximal opening first web. First placed proximal Kirschner -wire is running distally, obliquely, medially and crossing the first base metacarpal 2 cortices and only first second metacarpal cortex without crossing the 2nd cortex as Iselin (figure 1). The K-wire distal is unlike the original method and made to crossing proximally, obliquely and medially, the first cortices in head of metacarpal thumb and the one cortex of 2nd metacarpal without crossing the second. Fluoroscopy is checked position of the two wire. then bending 90 degree and fixing by external connector (slotted washer, wire holding screw, washer, nut screw then locked by pressure using wrench). According to require the opening of first web the pins are brought closing together then locking 2 pins and cutting at connector's level to preventing the system crowded.

Dressing placed and mobilization immediately smooth. The patient discharged and reviewed after one week, two weeks intervals and evaluation radiographically for any displacement. At six weeks removed the K-wires in the clinic then allowed at eight weeks force grip hand.

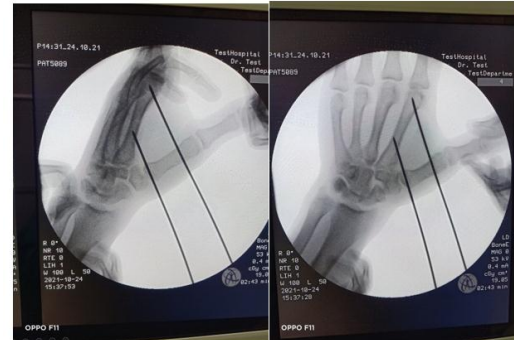


Fig 1: Technique fixation of locked K-wire: (1) 1st metacarpal; (2) 2nd metacarpal. Modified technique: the pin proximal is crossing from first base to base of 2nd metacarpal through three cortices. Pin distal is crossing from head of 1st metacarpal to the second metacarpal neck crossing three cortices then artery forceps used to bent ting the pins manually outside.¹⁰

Fluoroscopy used to assessment of reduction of Bennett's fracture (step-off < 1 mm). At the final our follow-up we obtained measurements. Measurement of work of duration, the Visual Analog Scale, where pain from 0 to 10 signified which zero no pain to ten maximum pain; and Quick DASH score which evaluated to the function of upper limb, which from 0 signified was normal the function of upper limb and 100 the function of upper limb useless, were elicited and compared with contralateral side and noted percentage values of this criteria: the first web opening (the angle which present between the first two axes metacarpal on the x-ray). The manual Jamar dynamometer used to measure grip strength and noted complications which occurring postoperative.

RESULTS

All patients and was maintained in 96% of cases. Grip strength measured at 4 months was 86% of the unaffected side. The average visual analog scale pain was in all studied patients zero except one cases had scores 0.2 and score of Quick DASH was 6.9/100. web opening was 87.6% of the other side. Fractures were healed and no arthritis observed at the trapezio-metacarpal at follow-up finally.

Despite the above advantages, this technique has its own potential complications. Fortunately, three complications observed in three cases postoperative while others no complications with statistically non-significant difference (Table 1).

One patient had partial stiffness in CMC joint and residual pain at 10 weeks postoperatively; although all function achieved by eight weeks. It may be explained by socioeconomically causes It was due to

patients did not start physiotherapy early, after 1-2 months of physiotherapy the patients improved and satisfied. Two patients had pin tract superficial infection which improved on oral antibiotics for one

week. It was due to personal factors as patients neglect local cleaning of K wires. Two patients had k wire migration attributed to faulty technical approach.

	Complications		Test	p
	Complicated N= (%)	Non-complicated N= (%)	t/ χ^2	
Age:				
Mean \pm SD	40.33 \pm 9.5	28.14 \pm 10.51	1.72	0.124
Side				
Right	1 (33.3)	4 (57.1)	Fisher	>0.999
Left	2 (66.7)	3 (42.9)		
Dominancy				
Yes	2 (66.7)	4 (57.1)	Fisher	>0.999
No	1 (33.3)	3 (42.9)		
VAS:				
Median (range)	0 (0 – 2)	0 (0 – 0)	-1.528	0.127 ∞
Interval preop				
Median (range)	8 (6 – 14)	4 (1 – 12)	-1.481	0.138 ∞
Operative time				
Mean \pm SD	32.67 \pm 2.52	23.0 \pm 5.48	2.854	0.021*
Grip strength				
Mean \pm SD	77.67 \pm 6.66	92.43 \pm 6.58	-3.242	0.012*
Q dash				
Median (range)	9 (8 – 18)	5 (0 – 10)	-1.937	0.053 ∞
Opening of web				
Mean \pm SD	75.67 \pm 11.02	92.71 \pm 7.36	-2.932	0.016*

Table 1: Relation between complications and the studied parameters (χ^2 Chi square test).

Case Presentation

30 years old male with history of fall on the ground sustained left Bennett's fracture according to his plain x-ray (figure 2)

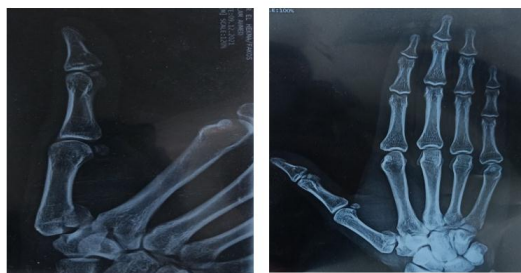

Fig 2: Plain X ray for Bennett's fracture Preoperative X-ray.

He was operated by locked k wire upon 5 days after injury He achieved union in 45 days (Figure 3) and started full hand grip at 3 months.

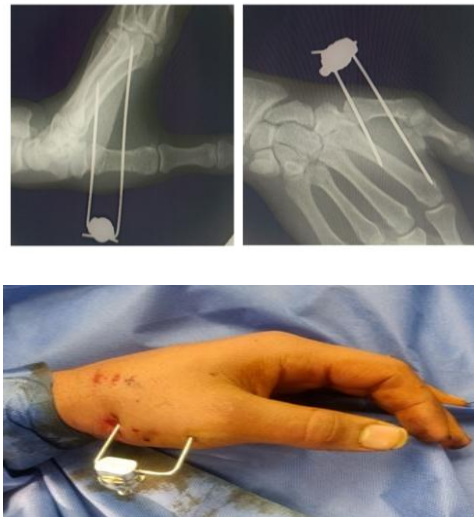


Fig 3: Plain X ray for Bennett's fracture postoperative X-ray 6 weeks (Ap and lateral) and picture of the hand with external connector.

Power of hand grip is 85 % compared to other side, The Quick DASH disability Score was zero, The first web opening measured at third months 90 % compared to other side and Radiological union time is six weeks (Figure 4).

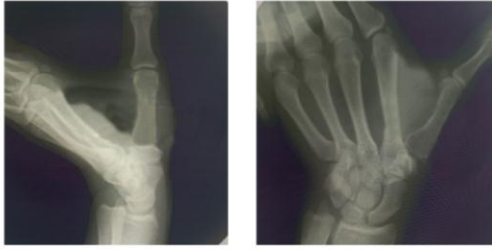

Fig 4: Plain X ray for Bennett fracture postoperative X-ray 3months.

DISCUSSION

This study evaluating the radiological and clinically outcomes of the K-wire technique with a connector to fixation of the Bennett's fracture. Fractures treated successfully and the all-patient's results of this technique gave adequate fixation of this fracture.

The incidence of the Bennett's fracture are considered rare, estimated to 1.4% of all hand fractures.¹¹, some authors place incidence is much lower 0.65%^[11] For power grip and normal function of hand proper reduction for these fractures is necessary.¹². Correlation between good result functional and anatomic reduction fracture is largely result of the unconstrained nature of the thumb CMC joint.

The treatment of Bennett's fracture is challenging. These fractures dislocations can be performed by percutaneous method or open surgery or using arthroscopy. There are various reported means of fixation: pins k wire, screws or plates.¹³

Most authors treated large Bennett's fragment open and internal fixation. Aim is to achieve good reduction anatomically as a step more than 1mm is associated with arthritis at trapezio-metacarpal posttraumatic.¹⁴

Diaconu M reported fractures of Bennett's fracture indicated with mini locking plates. As plates demonstrated good outcomes and including an the average score of pain 0.2, the score of grip strength is 95.5% of the contralateral side, the Quick DASH score is 17.4% and authors were recorded three cases of displacement secondary in cohort of 15 cases.¹⁵

Colleagues and Leclè're reported the results of open fixation screw of twenty-one large Bennett's fractures fragment and follow-up for 4-year, the force score of injured hand 89% with the contralateral hand, although postoperatively one case secondary dislocation occur at 9 weeks.¹⁶

Colleagues and Lutz reported the results of 7 years follow-up comparing between percutaneous K-wire Trans articular and open screw 32 Bennett's fractures. Results wire had a higher of incidence of the policies adducts; the fixation type not noticed posttraumatic arthritis clinically and radiographically.¹⁷

In our study grip strength measured is 86% with the contralateral hand, The average visual analog scale pain score in all studied patients is zero except one cases had scores 0.2/10 and the Quick DASH score was 6.9% and not any secondary displacement.

Percutaneous pinning is one operative option to maintain articular reduction and correction of metacarpal subluxation and has the advantage of avoiding associated complications of open surgery, including tendon adhesions and bone necrosis.¹⁸

The closed reduction with Kirschner-wire fixation is consensus on treatment of Bennett's fractures small-fragment.^[19] Some authors differ regarding of the K-wires, which trans-metacarpal extra-articular or crossing the trapezio-metacarpal joint.¹⁹ Colleagues and Bru'ske reported the results of percutaneous trans-articular K-wire which fixation of the Bennett's fracture and follow-up eighteen-month. The force score mean 80% of other side and all patients good opposition of the thumb; but 16 of 21 cases was narrowing of the space of TM joint and arthritis denoting at posttraumatic. The cause is to construct no deformable the trapezoid, Then Cast immobilization and removal pin is recommended in clinic¹⁷. Complications of technique have reported: Kirshner wire distal causing irritation of the extensor apparatus of second finger and k wire migration.¹⁷

our results said pins with the connector decrease the secondary displacements and decrease wire migration. k wire not cross second cortex of second metacarpal, so no irritation of extensor apparatus. grip strength measured is 86% with the contralateral hand, The average visual analog scale pain score in all studied patients is zero except one cases had scores 0.2/10 the web opening had 87.6% of contralateral side. Fractures healed and no signs of trapezio-metacarpal arthritis detected and not any secondary displacement. For reducing arthritis, we left extra-articular the 2 K-wires divergent trans-metacarpal, no need cast and immediately mobilization to prevent stiffness.

in a series of fourteen cases with fracture of first metacarpal base operated by using modification of Iselin technique with fixators and extended to all thumb basal fractures consider the fixator is perfect result of keeping articular of trapezio metacarpal joint.¹⁰ As its increase stability. The Results are shown; the pain average was 0.2 (intra-articular 0.4), the quick DASH was 2.9 (for intra-articular 4.5), the grip strength was 91.2%, the opening of first web was 79.1% (for intra-articular fractures 88.3%). One patient had the secondary displacement and excellent outcome. 2 cases of suffered from mal-union and few functional impairments. Final follow-up no signs of arthritis in trapezio-metacarpal observed and all fractures were healed.¹⁰

Our technique combines the advantage of percutaneous K-wires and power of stability of fixation and good outcomes when compared with the result of open techniques. As this approach have more advantages such intervention time is short, out

office clinic k wire removal not need anesthesia, and return to activities rapidly (six week). when compared with others fixation wire techniques, our modification advantageous appears simple and easy, never irritation of the extensors of index, we can keep the reduction through bringing the two K-wires bent portions and spread them before locking the connector, and start mobilization without cast or splint .Connector cost is cheap with at least 3 times less the cost of plate or screw.

All patients with Bennett's fracture returned to the work and all cases no casting applied. In this study reported a series of 20 patients undergoing closed reduction with locked K-wire technique with an average of 6 month follow-up.

Reduction with less than 1 mm step or gap was obtained in all patients and was maintained in 96% of cases. Grip strength measured at 4 months was 86% of the contralateral side. The average visual analog scale pain score was in all studied patients zero except one cases had scores (2), One patient had partial stiffness in CMC joint and residual pain at 10 weeks postoperatively, although all function achieved by eight weeks. This explained by socioeconomically causes. It was due to patients did not start physiotherapy early, after 1-2 months of physiotherapy the patients improved and satisfied. Two patients had pin tract superficial infection which improved on oral antibiotics for one week. It was due to personal factors as patients neglect local cleaning of K wires. Two patients had k wire migration attributed to faulty technical approach.

We confirm this technique is ideal for all patients of Bennett's fracture and we believe that it is important to choose Percutaneous Fixation of Bennett's fracture by K-wires with connector for surgical treatment the earliest possible, if the dislocation fracture is more than 1 mm, and start of physical rehabilitation.

CONCLUSION

This study of modified of the Iselin technique results it is stable, safe, minimal invasive and allow to immediately mobilization then removal Kirschner wire is easily at out clinic.

REFERENCES

1. Craig B and Daniel A. Bennett Fractures Dislocation: Review and Management. *Australian family physician*. 2011; 40 (6), 394-6.
2. Carlsen BT and Moran SL. Thumb trauma: Bennett fractures, Rolando fractures, and ulnar collateral ligament injuries. *J Hand Surg Am*. 2009; 34:945–52.
3. Hove LM. Fractures of the hand.Distribution and relative incidence. *Scand J Plast Reconstr Surg Hand Surg*. 1993; 27:317–9.
4. Stanton JS, Dias JJ and Burke FD. Fractures of the tubular bones of the hand. *J Hand Surg Eur*. 2007; 32(6):626-36.
5. Liverneaux P. Fracture and dislocation of the thumb.Paris: Expansion Scientifique *Franc, aise*. 2006:44–168.
6. Leclere FM, Jenzer A, Husler R, et al. 7-year follow-up after open reduction and internal screw fixation in Bennett fractures. *Arch Orthop.Trauma Surg*. 2012; 132:1045–51.
7. Greeven AP, Alta TD, Scholtens RE, et al. Closed reduction intermetacarpal Kirschner wire fixation in the treatment of unstable fractures of the base of the first metacarpal. *Injury*. 2012; 43:246–51.
8. Iselin M, Blanguernon S, Benoist D. Fractures de la base du premier me'tacarpien. *Me'm Acad Chir*.1956; 82:771–774.
9. Maire N, Lebailly F, Zemirline A, et al. Prospective continuous study comparing intrafocal cross-pinning HK2(s) with a locking plate in distal radius fracture fixation. *Chir Main*. 2013; 32:17–24.
10. Mohamed A, Hideaki M, Chihab T, et al."Percutaneous Fixation of First Metacarpal Base Fractures Using Locked K-Wires", *Techniques in Hand & Upper Extremity Surgery*. 2014;18: 77–81.
11. Bru'ske J, Bednarski M, Niedz'wiedz, et al. The results of operative treatment of fractures of the thumb metacarpal base. *Acta Orthop Belg*. 2001; 67:368–73.
12. Buck-Gramcko D, Bruns Beitr KC. On making a thumb: One hundred years of surgical effort.The *Journal of Hand Surgery*. 1976; 1 (1); 35-51.
13. Liverneaux PA and Ichihara S ractures and dislocation of the base of the thumb metacarpal-*The Journal of Hand Surgery (European Volume)* 2015, 40E (1) 42–50.
14. Kjaer-Petersen K, Langhoff O and Andersen K. Bennett's fracture. *J Hand Surg Br*. 1990; 15(1):58-61.
15. Diaconu M, Facca S, Gouzou S, et al. Locking plates for fixation of extra-articular fractures of the first metacarpal base: a series of 15 cases. *Chir Main*. 2011; 30:26–30.
16. Leclere FM, Jenzer A, Husler R, et al. 7-year follow-up after open reduction and internal screw fixation in Bennett fractures. *Arch Orthop Trauma Surg*. 2012 Jul; 132 (7):1045-51.
17. Lutz M, Sailer R, Zimmermann R, et alClosed reduction transarticular Kirschner wire fixation versus open reduction internal fixation in the treatment of Bennett's fracture dislocation. *J Hand Surg Br*.2003; 28:142–7.
18. Capo JT, Kinchelow T, Orillaza NS, et al. Accuracy of fluoroscopy in closed reduction and percutaneous fixation of simulated Bennett's fracture. *J Hand Surg Am*. 2009 Apr; 34(4):637-41.
19. Iselin M, Blanguernon S and Benoist D. Fractures de la base du premier me'tacarpien. *Me'm Acad Chir*.1956; 82:771–4.