

A Comparative Study between Excision and Reconstruction Using Superior Gluteal Artery Perforator Flap and Lay Open in Cases of Recurrent Pilonidal Sinuses

AHMED A.A. IBRAHIM, M.Sc.*; SHERIF A. AHMED, M.D.* and RAGHDA E.T. TAWFIK, M.D.**

The Departments of General Surgery* and Plastic, Burn & Maxillofacial Surgery**, Faculty of Medicine, Ain Shams University

Abstract

Background: Pilonidal sinus (PS) remains a problem for the surgeon and nuisance to the patients. Pilonidal sinus disease is a small hole or tunnel in the skin at the top of the buttocks, where they divide (the natal cleft) usually seen in Young adults and carries high post-operative morbidity and patient discomfort. Complicated pilonidal surgical wounds are associated with considerable morbidity, including chronic sacral wound, loss of work time, and lifestyle limitation.

Aim of Study: To compare between two surgical methods, excision of the recurrent pilonidal sinus and covering the defect using SGAP flap and lay open.

Patients and Methods: After approval of the ethical committee in Ain Shams University, El-Demerdash Hospital, the current study was done between August 2020 and September 2021. Informed consent forms from all patients were obtained. It was a prospective study including 40 patients diagnosed with recurrent PNS disease presented to the surgery and plastic clinics of Ain Shams University Hospitals and Nasser Institute Hospital.

Results: Comparison between cases of SGAP flap and cases of Lay open regarding the healing indicated that 100% of SGAP flap cases have good healing while 85% of the lay open cases have good healing, such findings were not statistically significant (p -value >0.05). Comparison between cases of SGAP flap and cases of Lay open regarding the infection indicated that 100% of SGAP flap cases have no infection while 50% of the lay open cases have infection, such findings were statistically significant (p -value <0.05). Regarding wound dehiscence between cases of SGAP flap no statistically significant differences (p -value >0.05), 10% of the SGAP flap cases have dehiscence. Comparison between cases of SGAP flap and cases of Lay open regarding recurrence indicated a statistically significant increase in recurrence among the Lay open cases 20% in comparison with the SGAP flap cases 0% (p -value <0.05). Regarding the flap complications among cases of SGAP flap, the present study revealed that 20% of the SGAP flap cases have congestion and 80% have no complications.

Conclusion: The comparison between two techniques in management of the recurrent pilonidal sinus, showed that no surgical procedure satisfies the principal requirements of an ideal treatment and each technique has advantages and disadvantages.

Key Words: Excision and reconstruction – Superior gluteal artery – Lay open - Pilonidal sinuses.

Introduction

Pilonidal sinus is a small hole or tunnel in the skin at the top of the buttocks, where they divide (the cleft). It does not always cause symptoms and only needs to be treated if it becomes infected. It may fill with fluid or pus, causing the formation of a cyst or abscess [1].

About 3 per 10,000 people per year are affected, and it occurs more often in males than females. Young adults are most commonly affected. The term "pilonidal" means "nest of hair". The condition was first described in 1833. The exact cause of this condition isn't known [2].

Risk factors include obesity, family history, prolonged sitting, greater amounts of hair, and not enough exercise. It's also more common in people who sit a lot, like cab or taxis drivers. It's most commonly affects Caucasian males with coarse dark body hair. The underlying mechanism is believed to involve a mechanical process. The lesions may contain hair and skin debris [2].

Diagnosis is based on symptoms and examination and the main distinguishing feature is that a pilonidal sinus opens up onto the skin, but does not communicate with the anal canal like a fistula; this distinction can often be identified with rigid sigmoidoscopy. Extensive sinus formation and

Correspondence to: Dr. Ahmed A.A. Ibrahim,
[E-Mail: a.3ataf2@gmail.com](mailto:a.3ataf2@gmail.com)

fistulisation may be assessed by MRI scanning of the natal cleft and buttocks [3].

Pilonidal disease does not always require surgical management. Conservative treatment of a PNS involves shaving the affected region and plucking the sinus free of any hair that is embedded. Any accessible sinuses can be washed out with water to prevent infection. Whilst antibiotics can be used in septic episodes, although any abscess present will require surgical drainage [3].

In acute disease, surgical management involves the drainage and washout of any abscess that is present. It can be difficult to remove the sinus tract in the same operation. Treatment of chronic disease is the removal of the pilonidal sinus tract. There are two main methods: The first involves excising the tract and laying open the wound, allowing closure by secondary intention. The second involves excising the tract, followed by primary closure of the wound, this has higher rates of recurrence and patients may require reconstructive surgery [3].

Many surgical methods have been used to reconstruct sacral defect, including local random flaps, and muscle flaps. In the recent years, the concept of perforator-based flaps has been used for covering sacral defects [4].

First described a gluteal perforator flap for repairing sacral defect Verpaele et al., [5] introduced the superior gluteal artery perforator (SGAP) flap for covering sacral defect. The SGAP flap provides an ample amount of tissue, with good vascularity, to cover large sacral defect in one stage and does not sacrifice the vascularity or innervation of the underlying gluteus maximus muscle [6].

In conclusion, the superior gluteal artery perforator flap (SGAP) offers many advantages over random (better vascularity and flap safety) or larger flaps (decreased operating time and donor-area morbidity) in the treatment of pilonidal sinus disease [7].

In our study we aim to compare between two surgical methods, excision of the recurrent pilonidal sinus and covering the defect using SGAP flap and lay open.

Patients and Methods

After approval of the ethical committee in Ain Shams University, El-Demerdash Hospital, the current study was done between August 2020 and September 2021. Informed consent forms from all patients were obtained. It was a prospective study including 40 patients diagnosed with recurrent

PNS disease presented to the surgery and plastic clinics of Ain Shams University Hospitals and Nasser Institute Hospital.

All age groups and both genders are included while patients with peripheral vascular disease, quadriplegia or hemiplegia or patients with co morbidity as sepsis, renal, hepatic, cardiac or pulmonary problems are excluded.

Study was conducted on two groups with recurrent pilonidal sinus disease:

A- Group (A) who will be managed by excision of the pilonidal sinus and coverage using of superior gluteal artery perforator flap:

Patient positioned in the supine position with both arms away from the body then during operation the patient is positioned in the jackknife position (prone position with head and feet at lower level), Flap designed and marked with its width and length depending on the perforator using its surface anatomy according to the defect after excision of the pilonidal sinus tract, Followed by elevation of the flap and rotate it pedicled on its perforator to cover the defect and closure with primary approximation of the donor site with drain fixation.

B- Group (B) who will be managed by excision and let for secondary intention:

Patient positioned as the same position of group (A), Then excision of the pilonidal sinus tract.

Postoperative:

Early Patients ambulating was recommended. A liquid diet was allowed on the first postoperative day then normal diet from the second day and advise the patients with good hygiene after each path and patients were discharged home if they are able to tolerate normal diet without complications and survival of the flap.

Follow-up visits with meticulous examination for healing, infection, recurrence and dehiscence for both recipient and donor sites. And for flap complications as: Congestion, ischemia, partial necrosis and loss of the flap. The first follow-up visit was usually a week after surgery, Subsequent visits are scheduled every week for a month, then every month for 6 months after complete wound healing.

Statistical analysis:

Data were collected, coded, revised and entered to the Statistical Package for Social Science (IBM SPSS) version 20. The data were presented as

number and percentages for the qualitative data, mean, standard deviations and ranges for the quantitative data with parametric distribution and median with inter quartile range (IQR) for the quantitative

data with non-parametric distribution. The p -value was considered significant as the following: $p > 0.05$: Non significant (NS), $p < 0.05$: Significant (S), $p < 0.01$: Highly significant (HS).

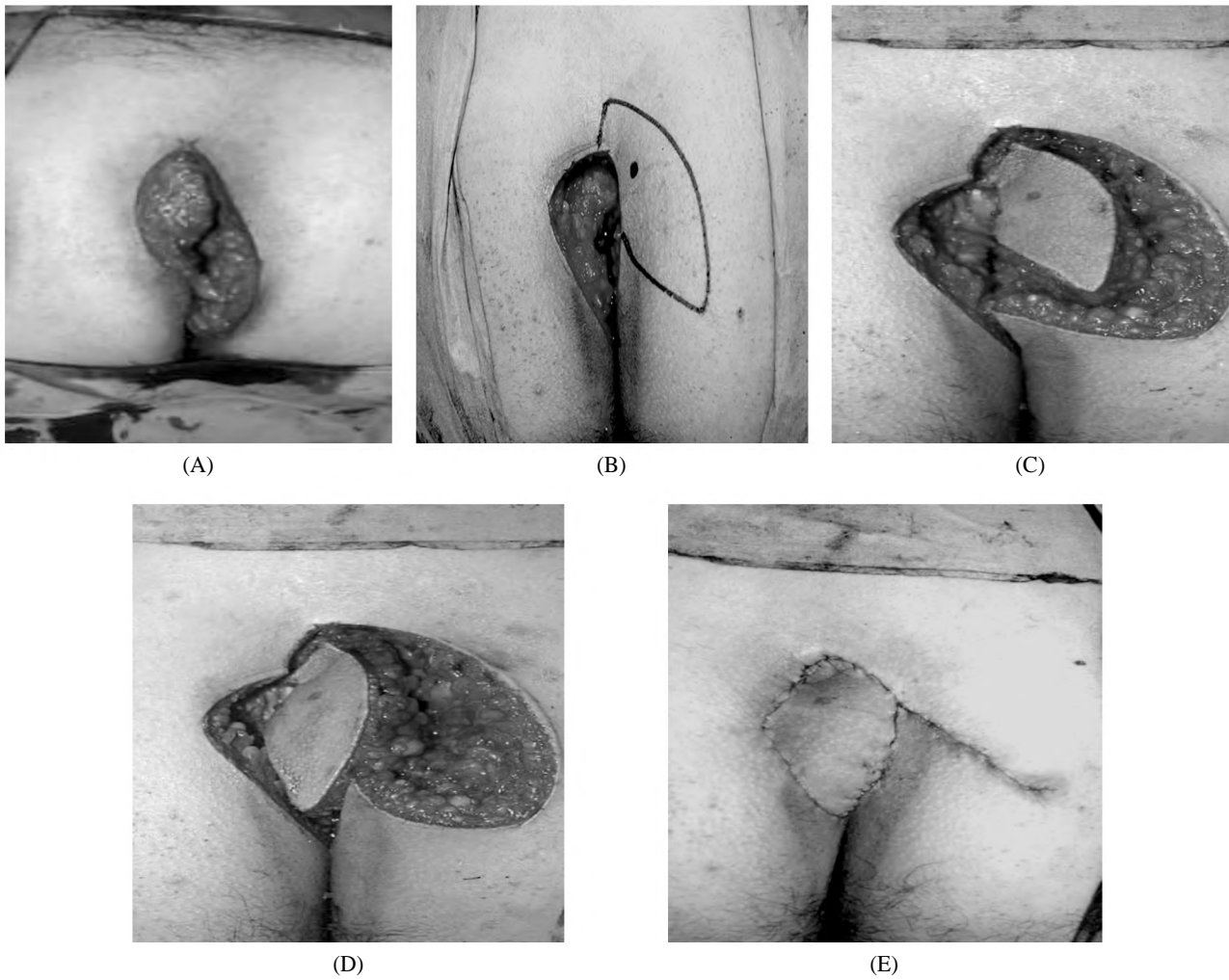


Fig. (1A-E): Steps of operation of group (A).

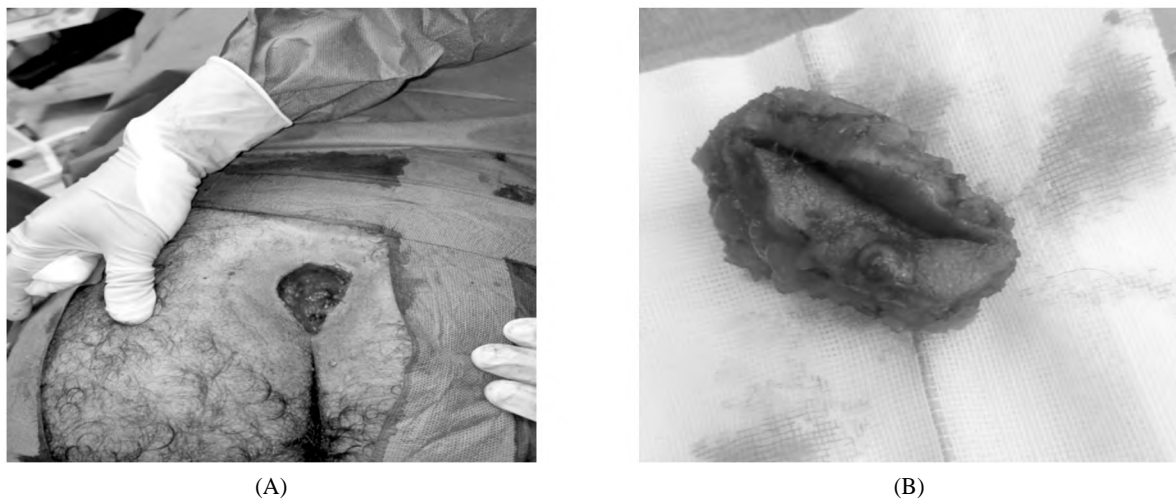


Fig. (2A,B): Steps of operation of group (B).

Fig. (3): Post six months follow-up of a case of group (A).

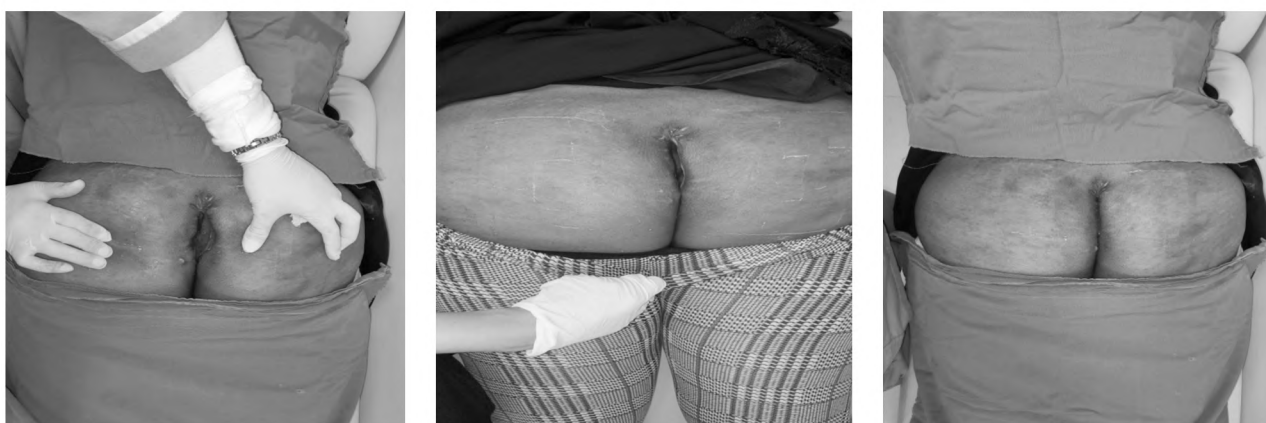
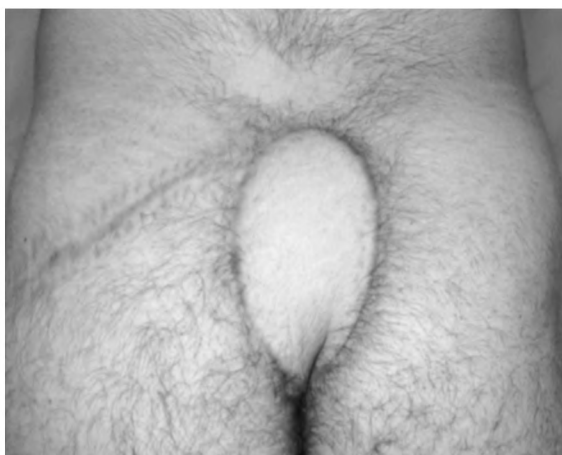
Fig. (4): Follow-up of a case of group (B) for six months.

Results

Table (1): Comparison between Cases of SGAP flap and Cases of Lay open among demographic data.

	Cases of SGAP flap (No.=20)		Cases of Lay open (No.=20)		Chi square test/ Independent t-test	
	No	%	No	%	χ^2/t^*	p-value
<i>Sex:</i>						
Female	5	25.0	5	25.0	0.000	1.000
Male	15	75.0	15	75.0		
<i>Age:</i>						
Mean±SD	31.95	7.83	25.40	4.87	3.176	0.003

This table showed that there were 5 females (25%) and 15 males (75%) in Cases of SGAP flap, 5 females (25%) and 15 males (75%) in Cases of Lay open. Mean of age was 31.95 in Cases of SGAP flap and 25.40 in Cases of Lay open. So there was statistically significant increase age in Cases of SGAP flap.

Table (2): Comparison between Cases of SGAP flap and Cases of Lay open among healing and infection.

	Cases of SGAP flap (No.=20)		Cases of Lay open (No.=20)		Chi square test	
	No	%	No	%	χ^2	p-value
<i>Healing:</i>						
Bad	0	0.0	3	15.0	3.243	0.072
Good	20	100.0	17	85.0		
<i>Infection:</i>						
No	20	100.0	10	50.0	13.333	<0.001
Yes	0	0.0	10	50.0		

This table showed that Healing was good in all patients of Cases of SGAP flap and in 17 patients (85%) of Cases of Lay open. 10 patients (50%) of Cases of Lay open had infection. So there was statistically significant increase infection in Cases of Lay open.

Table (3): Comparison between Cases of SGAP flap and Cases of Lay open among dehiscence and recurrence.

	Cases of SGAP flap (No.=20)		Cases of Lay open (No.=20)		Chi square test	
	No	%	No	%	χ^2	<i>p</i> -value
<i>Dehiscence:</i>						
No	18	90.0	20	100.0	2.105	0.147
Yes	2	10.0	0	0.0		
<i>Recurrence:</i>						
No	20	100.0	16	80.0	4.444	0.035
Yes	0	0.0	4	20.0		

This table showed that 2 patients (10%) of Cases of SGAP flap had Dehiscence, 4 patients of Cases of Lay open had Recurrence. So there was statistically significant increase Recurrence in Cases of Lay open.

Table (4): Flap Complications among Cases of SGAP flap.

	Cases of SGAP flap (No.=20)	
	No	%
<i>Flap complications:</i>		
No	16	80.0
Yes (Congestion)	4	20.0

This table showed that 4 patients had Flap Complications among Cases of SGAP flap.

Discussion

Pilonidal sinus disease (PSD) is a chronic inflammatory disease affecting the soft tissue of the sacrococcygeal region and remains a challenging disease for clinicians to treat [8].

Although pilonidal sinus cannot be considered a debilitating disease, patients are confronted with discomfort and low quality of life owing to complications such as abscess formation or sinus-related drainage or pain. The recurrence is most often due to the omission of any tract during the initial operation, infection of the wound, or abscess formation that may lead to formation of a new sinus tract inside the cicatrizing wound [9].

Surgical management remains the mainstay of treatment of chronic pilonidal sinus disease and includes curettage, lay open and wide excision with closing the defect primarily, with a flap or graft, or leaving the defect open to heal with secondary intention [10].

The management of pilonidal sinus disease is still not standardized. A commonly recognized

procedure that reduces risks and recurrence rates while still providing cosmetically appropriate results and a limited healing time is still unavailable [11].

Laying open and direct suture are common surgical strategies used. They allow complete excision of the sinus, are easy to perform, and do not require special surgical training. The use of flap repair after the excision of pilonidal sinus has increased in recent decades. This makes it possible to place the suture outside the median line, the focus of the disease. This is particularly useful in cases of multi-recurrent and multi-fistular diseases. Nonetheless, it requires training in plastic and reconstructive surgery procedures [12].

The aim of our study is to compare between two surgical methods; excision of the pilonidal sinus disease and covering the defect using superior gluteal artery perforator (SGAP) flap or excision of the Pilonidal Sinus and lay open.

This prospective randomized comparative study included 40 patients diagnosed with recurrent pilonidal sinus disease. They were recruited and assessed for eligibility from the surgery and plastic clinics of Ain Shams University Hospitals and Nasser Institute Hospital.

Such findings are in agreement with Metwalli et al., [13] who studied treating 24 patients with pilonidal sinus disease and demonstrated that the mean age of patients was 25 ±6.6 years old with male predominance in the studied cases.

Comparison between cases of SGAP flap and cases of Lay open regarding the healing indicated that 100% of SGAP flap cases have good healing while 85% of the lay open cases have good healing, such findings were not statistically significant (*p*-value >0.05).

Hussain et al., [14] compared the surgical outcomes of lay open versus primary closure technique and found that the mean period required for complete wound epithelization is 6 weeks in lay open technique and 3 weeks in primary closure patients.

The comparison between cases of SGAP flap and cases of Lay open regarding the infection indicated that 100% of SGAP flap cases have no infection while 50% of the lay open cases have infection, such findings were statistically significant (*p*-value <0.05).

A previous study by Hussain et al., [14] revealed that the rate of wound infection after treatment of pilonidal sinus disease was 16% in open lay method

and 22% in closed method. Ekici et al., [11] demonstrated that wound site infection rate among lay open patients was 9.4%.

Comparison between cases of SGAP flap and cases of Lay open regarding dehiscence indicated no statistically significant differences (p -value >0.05), no dehiscence was found among the lay open cases while 10% of the SGAP flap cases have dehiscence.

Similarly, a meta-analysis study by Berthier et al., [12] demonstrated a significantly higher risk of dehiscence and skin necrosis for flap vs. the laying open technique in the treatment of pilonidal sinus disease.

Liao et al., [15] revealed that midline closure should be avoided in SGAP flap treatment of pilonidal sinus disease because shearing and friction movements in between buttocks can lead to wound dehiscence and enhance the disease recurrence, caused by repeated penetration of the hair shafts.

Comparison between cases of SGAP flap and cases of Lay open regarding recurrence indicated a statistically significant increase in recurrence among the Lay open cases in comparison with the SGAP flap cases (p -value <0.05).

Such findings are in agreement with Metwalli et al., [13] that compared between the treatment method of pilonidal sinus disease with either SGAP or Limberg flap and demonstrated no recurrence was found among patients who were treated by SGAP flap.

A previous study by Acartürk et al., [7] found that the SGAP offers many advantages over random (better vascularity and flap safety) or larger flaps (decreased operating time and donor-area morbidity) in the treatment of pilonidal sinus disease. Patients were mobilized and discharged home the morning after surgery (less than 24h). The patients were able to return to normal daily activities after 3 days and to work 10 days after the surgery. There were no complications and no recurrences at an average of a 10-month follow-up.

Regarding the flap complications among cases of SGAP flap, the present study revealed that 20% of the SGAP flap cases have congestion and 80% have no complications.

A previous study by Metwalli et al., [13] on the management of pilonidal sinus disease using SGAP flap method indicated that one patient developed flap congestion that improved spontaneously after applying nitroglycerin patch.

Conclusion:

In conclusion, the comparison between two techniques in management of the recurrent pilonidal sinus, excision and covering the defect using SGAP flap and lay open showed that no surgical procedure satisfies the principal requirements of an ideal treatment and each technique has advantages and disadvantages. Finally, we recommended conducting further studies.

References

- 1- FERRI F.F.: "Ferri's clinical advisor 2018" E-Book: 5 Books in 1. Elsevier Health Sciences, May 2017.
- 2- KHANNA A and ROMBEAU L.J.: Pilonidal Disease; Clin. Colon. Rectal Surg., 24: 46-53, 2011.
- 3- LEE H.C., HO Y.H., SEOW C.F., et al.: "Pilonidal disease in Singapore: Clinical features and management". Australian and New Zealand Journal of Surgery, 70.3: 196-198, 2000.
- 4- KOSHIMA I., MORIGUCHI T., SOEDA S., et al.: "The gluteal perforator-based flap for repair of sacral pressure sores". Plast. Reconstr. Surg., 91: 678-83, 1993.
- 5- VERPAELE A.M., BLONDEEL P.N., VAN LANDUYT K., et al.: "The superior gluteal artery perforator flap: An additional tool in the treatment of sacral pressure sores". Br. J. Plast. Surg., 52: 385-91, 1999.
- 6- MINAMI R.T., MILLS R., PARDOE R., et al.: "Gluteus maximus myocutaneous flaps for repair of pressure sores. Plast. Reconstr. Surg., 17: 199-200, 2015.
- 7- ACARTÜRK T.O., PARSAK C.K., SAKMAN G. and DEMIRCAN O.: Superior gluteal artery perforator flap in the reconstruction of pilonidal sinus. J. Plast. Reconstr. Aesthet Surg., 63: 133-9, 2010.
- 8- CHAFFIN A.E., DOWLING S.G., KOSYK M.S. and BOSQUE B.A.: Surgical reconstruction of pilonidal sinus disease with concomitant extracellular matrix graft placement: A case series. Journal of Wound Care, 30 (Sup. 7), pp. S28-S34, 2021.
- 9- BROWN S.R. and LUND J.N.: The evidence base for pilonidal sinus surgery is the pits. Techniques in Coloproctology, 23 (12): pp. 1173-1175, 2019.
- 10- STAUFFER V.K., LUEDI M.M., KAUF P., SCHMID M., DIEKMANN M., WIEFERICH K. and DOLL D.: Common surgical strategies in pilonidal sinus disease: A meta-analysis, merged data analysis, and comprehensive study on recurrence. Scientific Reports, 8 (1): p. 3058, 2018.
- 11- EKICI U., KANLIÖZ M., FERHATOGLU M.F. and KARTAL A.: A comparative analysis of four different surgical methods for treatment of sacrococcygeal pilonidal sinus. Asian Journal of Surgery, 42 (10): pp. 907-913, 2019.
- 12- BERTHIER C., BÉRARD E., MERESSE T., GROLLEAU J.L., HERLIN C. and CHAPUT B.: A comparison of flap reconstruction vs the laying open technique or excision and direct suture for pilonidal sinus disease: A meta-analysis of randomised studies. International Wound Journal, 16 (5): pp. 1119-1135, 2019.

- 13- METWALLI A.S.F., REFAAT D.O. and ABD ELHAFEZ MOHAMMAD ELSHEWAIL A.E.: Comparison between Perforator Dependent Island Flap and Limberg Flap for Treatment of Pilonidal Sinus. European Journal of Molecular & Clinical Medicine, 8 (3): pp. 3325-3334, 2021.
- 14- HUSSAIN F., BRAMHAM B., PARVEEN S. and CHAKARAVARTY B.: Pilonidal sinus: Surgical outcome of lay open versus primary closure technique. Pathogenesis, 8: p.9, 2018.
- 15- LIAO L.Y., LI T.S. and CHEN H.C.: Idea and innovation: Secure fixation between dermis and periosteum using perforator flap to prevent recurrence of pilonidal sinus disease. International Wound Journal, 16 (3): pp. 862-865, 2019.

مقارنة بين الإستئصال وإعادة البناء مستخدماً شريحة الشريان الثاقب الألوئى العلوى وأن يترك مفتوحاً فى العلاج الجراحى لحالات الناسور العصوى المرتجع

الخلفية: يمثل الناسور العصوى العديد من التحديات العلاجية للجراحين فى جميع أنحاء العالم. الناسور العصوى هو ثقب صغير أو نفق فى الجلد فى الجزء العلوى من الأرداف ويحدث غالباً فى الشباب البالغين كما يحمل العديد من الأعتلالات ما بعد الجراحة مما يسبب عدن إرتياح للمريض وضياح وقت العمل وتقبيد نمط الحياة.

الهدف: هو مقارنة بين النتائج النهائية لطريقتين جراحيتين فى علاج الناسور العصوى المرتجع، الإستئصال وإعادة البناء باستخدام شريحة الشريان الثاقب الألوئى العلوى وأن يترك مفتوحاً.

الحالات والطرق: شملت هذه الدراسة ٤٠ مريض يعانون من مرض الناسور العصوى المرتجع بمستشفى الدمرداش ومعهد ناصر للبحوث والعلاج فى الفترة بين أغسطس ٢٠٢٠ وسبتمبر ٢٠٢١.

النتائج: أشارت المقارنة بين حالات شريحة الشريان الثاقب الألوئى العلوى وحالات أن يترك مفتوحاً فيما يتعلق بالشفاء إلى أن ١٠٠٪ من حالات الشريحة تتمتع بشفاء جيد بينما ٨٥٪ من الحالات المفتوحة لديها شفاء جيد. وأشارت المقارنة بين حالات الشريحة والحالات المفتوحة فيما يتعلق بالعدوى إلى أن ١٠٪ من حالات الشريحة ليست مصابة بالعدوى بينما ٥٠٪ من الحالات المفتوحة مصابة بالعدوى. فيما يتعلق بتفرز الجرح بين حالات الشريحة ١٠٪ من الحالات لديها تفرز. وأشارت المقارنة بين حالات الشريحة والحالات المفتوحة فيما يتعلق بإرتجاع المرض إلى زيادة ذات دلالة إحصائية فى التكرار بين حالات أن يترك مفتوحاً بنسبة ٢٠٪ مقارنة بحالات الشريحة ٠٪. فيما يتعلق بمضاعفات الشريحة بين حالات شريحة الشريان الثاقب الألوئى العلوى، كشفت الدراسة الحالية أن ٢٠٪ من الحالات لديها احتقان و ٨٠٪ ليس لديها أى مضاعفات.

الإستنتاج: أظهرت المقارنة بين تقنيتين فى علاج الناسور العصوى المرتجع أنه لا توجد عملية جراحية تفى بالمتطلبات الأساسية للعلاج المثالى وكل تقنية لها مزايا وعيوب.