

Corneal Epithelial Mapping Among Healthy Egyptian Eyes of LASIK Age Group Using Spectral Domain Anterior Segment Optical Coherence Tomography

MERVAT M. ABD EL BAKY, M.Sc.; AHMED H. ASSAF, M.D.; MOHAMED G. METWALLY, M.D. and TAMER A. BADRAN, M.D.

The Department of Ophthalmology, Faculty of Medicine, Ain Shams University

Abstract

Background: A good knowledge of the corneal epithelium distribution may help a lot in many aspects of clinical work such as screening of keratoconus before corneal surgery, fitting contact lens, and increasing the accuracy of corneal refractive surgeries. Such compensatory epithelial changes are seen in cases of asymmetric LASIK flaps, flap malposition and irregular stromal surface following multiple refractive procedures.

Aim of Study: To evaluate corneal epithelial thickness (CET) changes using Spectral domain-anterior segment optical coherence tomography (SD-AS-OCT) and to illustrate the distribution and variation of CET in healthy Egyptian eyes of LASIK age group (ranging from 18 to 50 years as long as the healthy condition of the cornea).

Patients and Methods: This prospective descriptive cross-sectional study was performed to assess epithelial thickness data on a sample of the Egyptian population. This comprised 200 eyes from 100 healthy Egyptian adults (50 males and 50 females), whose ages ranged from 18 to 50 years. Subjects were recruited from the outpatient clinic of ophthalmology of Ain Shams University Hospitals from January 2020 to December 2020.

Results: Our study demonstrated the epithelial layer of the cornea had a non uniform thickness profile, as suggested in previous studies. We found the thickest part was at inferior sector and the thinnest sector was superior. Our study showed the tear meniscus height was 300 μ m on average. This may influence the result of the corneal epithelium distribution especially the differences between different locations.

Conclusion: Our study reports there was no statistically significant difference between males and females regarding epithelial thickness in different parts of the cornea.

Key Words: SD-AS-OCT – CET – PTK.

Correspondence to: Dr. : Mervat M. Abd El Baky,
[E-Mail: movy_twity90@yahoo.com](mailto:movy_twity90@yahoo.com)

Introduction

CORNEAL refractive properties such as central corneal thickness (CCT), anterior curvature, posterior curvature, total corneal power are useful in all types of refractive surgeries. Moreover, understanding how these surgeries affect the corneal shape and structure is becoming increasingly important [1].

The corneal epithelium plays an important role in the optics of the eye. It maintains the corneal integrity and function and influences tear film stability. The contribution of the corneal epithelium to the refractive power of the cornea, and thus ocular refraction, cannot be ignored. Studies have shown that epithelial refractive power alone is an average of 1.03 D (range 0.55-1.85 D) over the central 2 mm diameter zone and 0.85 D (range 0.29-1.60 D) at the 3.6mm diameter zone [2].

The alterations of corneal epithelial thickness (CET) are found in many pathological conditions which have irregular corneal stromal surface to get a regular surface such as contact lens warpage dry eye and keratoconus [3].

Knowledge of the topographic CET profile and how it can change has been applied in clinical evaluation of various corneal disorders and in refractive surgery. Some corneal surgery and refractive surgery with excimer laser ablation were done directly on corneal epithelium such as transepithelial photorefractive keratectomy (trans PRK) and photo therapeutic keratectomy (PTK) [4,5].

Several imaging modalities, such as high frequency scanning ultrasound bio microscopy, confocal microscopy and optical coherence tomography (OCT) have facilitated measurement of CET [6].

Some of these techniques have some limitations as they are invasive devices and need to anesthetic. This may increase the risk of corneal infection and decrease the accuracy because of the possible contact related corneal compression [7].

Since the latest years SD OCT has become a promising method to study the corneal epithelial thickness because its non invasiveness, good repeatability and accuracy at the same time [8,9].

Optical coherence tomography (OCT) is a non-contact optical signal acquisition and processing device that provides magnified, high resolution cross-sectional images of ocular tissues. Development of anterior segment OCT (AS-OCT) offers the benefits of fine resolution and noninvasive examination of the anterior segment anatomy to the depth of the iris plane. This imaging device has been utilized for investigating a variety of corneal and anterior segment diseases [10].

Technological advances toward three-dimensional visualization broaden the scope of AS-OCT in ophthalmologic evaluation. The AS-OCT is a valuable imaging tool whose use in research and clinical practice will continue to expand our knowledge and management of various ophthalmic conditions [11].

Aim of the work:

To evaluate corneal epithelial thickness (CET) changes using Spectral domain-anterior segment optical coherence tomography (SD-AS-OCT) and to illustrate the distribution and variation of CET in healthy Egyptian eyes of LASIK age group (ranging from 18 to 50 years as long as the healthy condition of the cornea).

Patients and Methods

This prospective descriptive cross sectional study comprised 200 healthy eyes from 100 subjects (50 males and 50 females), whose ages ranged from 18 to 50 years (mean \pm standard deviation: 27.13 \pm 5.21 years).

Subjects were recruited from the outpatient clinic of ophthalmology of Ain Shams University Hospitals.

The study was conducted in accordance with the ethical standards stated by the Ethical Committee of Ain Shams University. Informed consent was obtained from each participant following the explanation of the academic nature of the study.

Inclusion criteria: Age: 18-50 years old (myope, hypermetrope, astigmatic), Sex: Males and Females

and Able and willing to complete the required examinations.

Exclusion criteria: Pediatric subjects, Any corneal pathology, Major or minor ocular surgeries, Moderate or sever dry eye, Ocular truma, Contact lens use and Blepharitis/meibomitis.

Inability to complete the required SD-OCT scans (e.g., unable to fixate due to poor vision).

The study was conducted in accordance with the ethical standards stated by the Ethical Committee of Ain Shams University. Informed consent was obtained from each participant following the explanation of the academic nature of the study.

All subjects were subjected to the following workup:

History taking including; Name, age, previous ocular trauma or surgeries whether major or minor and contact lens use.

Ophthalmological examination using slit lamp biomicroscopy for assessment of the anterior segment.

- 1- Corneal tomography by anterior segment OCT (epithelial mapping) Opti-vue.
- 2- Tear meniscus height measurement by ant segment OCT.
- 3- Refraction by using non-cycloplegic autorefractor (Huvitz HRK 7000, Huvitz Co., Ltd., South Korea).
- 4- Fundus examination by using non-contact fundus biomicroscopy through volk 90D lens.
- 5- As previous studies have reported no significant difference between eyes in the same individual. Each subject was scanned with each device by the same examiner on the same day.

Statistical analysis:

Data were collected, revised, coded and entered to the Statistical Package for Social Science (IBM SPSS) version 20. The qualitative data were presented as number and percentages while quantitative data were presented as mean, standard deviations and ranges.

Data were subjected to analysis by SPSS and Microsoft excel programs 2016. Repeated measure ANOVA with post hoc test was done and the statistical significance was set at *p*-value less than 0.05.

The comparison between two paired groups with quantitative data and parametric distribution was done by using Paired *t*-test.

The comparison between two independent groups with quantitative data and parametric distribution was done by using Independent *t*-test.

Spearman correlation coefficients were used to assess the correlation between two quantitative parameters in the same group.

The confidence interval was set to 95% and the margin of error accepted was set to 5%. So, the *p*-value was considered significant as the following: *p*>0.05: Non significant, *p*<0.05: Significant and *p*<0.01: Highly significant.

Results

This prospective descriptive cross-sectional study was performed to assess epithelial thickness data on a sample of the Egyptian population. This comprised 200 eyes from 100 healthy Egyptian adults (50 males and 50 females), whose ages ranged from 18 to 50 years.

The study was conducted on 100 persons (50 males and 50 females) (100 right eye and 100 left eye) whose age ranged from 18 to 50 years Mean ± SD 27.13±5.21 divided into 4 groups: (18-26) and accounts (46.0%), (27-34) and account (46.0%), (35-42) and account (5.0%), (43-50) and account (3.0%).

The previous table shows no statistically significant difference between males and females regarding epithelial thickness in different parts of the cornea.

Epithelial thickness was 0.56 ~~mm~~ thicker in male subjects than in female subjects.

Also, the previous table shows that there was no statistically significant correlation found between TMH of the studied subjects and epithelial thickness.

Table (1): Age, sex distribution of the examined subjects.

	No. = 100
<i>Sex:</i>	
Female	50 (50.0%)
Male	50 (50.0%)
<i>Age:</i>	
Mean ± SD	27.13±5.21
Range	18-50
Age (18-26)	46 (46.0%)
Age (27-34)	46 (46.0%)
Age (35-42)	5 (5.0%)
Age (43-50)	3 (3.0%)
<i>Eye:</i>	
Right	100 (50.0%)
Left	100 (50.0%)

Table (2): Comparison between males and females regarding parameters of the AS OCT (epithelial thickness, central corneal thickness, tear meniscus height) of all subjects.

	Female No. = 50	Male No. = 50	Test value*	<i>p</i> - value	Sig.
<i>Central:</i>					
Mean ± SD	53.68±2.85	54.24±2.49	-1.481	0.140	NS
Range	49-64	50-60			
<i>TMH:</i>					
Mean ± SD	295.13±48.69	307.36±50.71	-1.740	0.083	NS
Range	204-400	235-427			
<i>Temporal:</i>					
Mean ± SD	52.80±2.49	53.25±2.60	-1.248	0.213	NS
Range	49-60	49-61			
<i>Nasal:</i>					
Mean ± SD	53.56±2.78	54.08±2.25	-1.455	0.147	NS
Range	48-62	49-60			
<i>Inferior:</i>					
Mean ± SD	54.59±2.94	54.69±3.23	-0.229	0.819	NS
Range	49-64	48-62			
<i>Superior:</i>					
Mean ± SD	51.67±2.52	52.14±2.25	-1.391	0.166	NS
Range	46-62	48-57			
<i>Min.:</i>					
Mean ± SD	46.88±3.95	47.57±3.67	-1.281	0.202	NS
Range	34-56	34-58			
<i>Max.:</i>					
Mean ± SD	57.68±3.43	57.36±2.79	0.724	0.470	NS
Range	50-74	51-63			

p-value >0.05: Non significant (NS).
p-value <0.05: Significant (S).
p-value <0.01: Highly significant (HS).
 *: Independent *t*-test.

Table (3): Correlation between the TMH and (epithelial thickness, central corneal thickness) of all subjects.

	TMH	
	<i>r</i>	<i>p</i> -value
Central	0.081	0.256
Temporal	0.054	0.448
Nasal	0.041	0.566
Inferior	0.011	0.880
Superior	0.125	0.077
Min.	0.136	0.055
Max.	0.084	0.237



Fig. (1): Tear meniscus height.

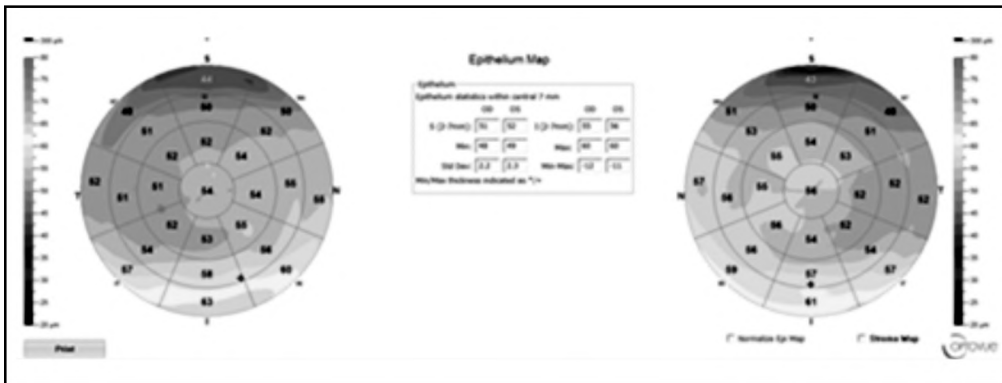


Fig. (2): Epithelial mapping of male subject.

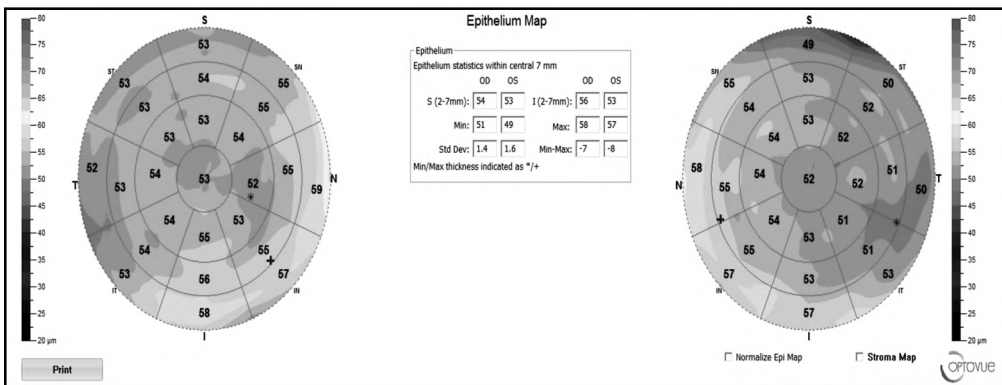


Fig. (3): Epithelial mapping of female subject.

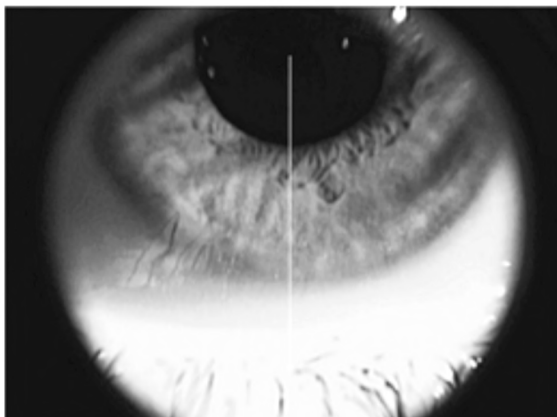


Fig. (4): Corneal line.

Discussion

The distribution of corneal epithelial thickness is quite different from that of corneal thickness.

Our study showed the tear meniscus height was 300µm on average. This may influence the result of the corneal epithelium distribution especially the differences between different locations.

A good knowledge of the corneal epithelium distribution may help a lot in many aspects of clinical work such as screening of keratoconus before corneal surgery, fitting contact lens, and

increasing the accuracy of corneal refractive surgeries [12].

A prospective descriptive cross sectional study included 200 eyes were divided into 4 groups.

Our aim to study the corneal epithelial thickness in healthy corneal conditions using anterior segment optical coherence tomography.

Our study demonstrated the epithelial layer of the cornea had a non uniform thickness profile, as suggested in previous studies.

Our study reports no statistically significant difference between males and females regarding Epithelial thickness but the thickness of males was thicker by 0.56 μm than female subjects on the central part.

Some reports of the cornea being thicker in men than in women [13,14] and some suggestions that endocrine differences may affect ocular tissue growth. In spite of this potential hormonal influence on corneal thickness, the exact role is obscure.

In this study, males had a thicker corneal epithelium thickness than females in almost all sections; they had a 0.56 μm thicker epithelium in the center M-F=0.56 μm on average, ($p<0.140$). Kanellopoulos et al., [14] and Wu et al., [7] agreed with our findings; however, their studies show slightly greater differences in the central epithelium with 1.52 μm and 1.34 μm , respectively. Research has shown the influence of gonadal hormones on ocular development [15,16]; perhaps this can explain the difference.

Samy et al., [6] and Hashmani et al., [17] also found Males had a thicker epithelium than females in all locations there was no statistically significant difference between the two sexes by age or refractive errors as our study.

Our study we found the thickest part was at inferior nasal sector, and the thinnest part at the superior sector.

The thinner superior epithelium has been attributed to the effect of blinking and friction produced by the eyelid.

The corneal epithelium in normal eyes was slightly thicker inferiorly and nasally.

In all studies, inferior-superior difference was always larger than the nasal-temporal difference [13,18]. There are several theories for vertical asymmetry in epithelial thickness. First, as hypothesized

by Reinstein et al., friction due to blinking abrades the epithelium of the cornea with a larger force applied on the superior meridian. Second, as suggested by Du et al., [16] the constant force applied by the upper eyelid on the superior meridian causes long-term thinning. The upper eyelid covers a greater part of the eye when compared to the lower eyelid and also applies a greater force on the cornea due to gravity. Lastly, as theorized by King-Smith et al., [19] the flow of the tear film with subsequent pooling in the inferior meridian may cause a falsely thick reading.

Reinstein et al., [20] reported a similar result in the use of very high-frequency (VHF) digital ultrasound some previous studies also reported that the inferior side is thicker than the superior, just like this study did.

The nasal epithelium being thicker than the temporal is a previously reported unexplained finding. The reason could be due to the fact of the nasal cornea is more protected than the temporal cornea.

In study by Buffault et al., [8] the Central 52.5 ± 3.6 , inf 53.5 ± 3.4 , sup 50.4 ± 3.3 , min 46.2 ± 4.9 , max 57.0 ± 3.6 .

In study by Catalan et al., [21] the Central 52 ± 4.07 , inf 53.14 ± 4.50 , sup 53.27 ± 4.25 , min 49.09 ± 4.74 , max 56.86 ± 4.52 .

In study by Ostadian et al., [22] the Central 57.67 ± 4.21 , Inferior 56.20 ± 4.27 , Superior 56.83 ± 4.30 . Minimum 55.04 ± 4.32 . Maximum 60.96 ± 5.66 , Temporal 56.11 ± 4.35 , Nasal 56.33 ± 4.26 .

In study by Wu et al., [7], the central part was $53.26 \pm 2.66 \mu\text{m}$

In this study by Samy et al., [6] the mean CET found to be $49.21 \pm 2.24 \mu\text{m}$. The superior thickness was $48.61 \pm 2.25 \mu\text{m}$, inferior thickness was $49.60 \pm 2.16 \mu\text{m}$, minimum thickness was $48.0 \pm 2.15 \mu\text{m}$, maximum thickness was $50.45 \pm 2.14 \mu\text{m}$

Agarwal [23] reported mean epithelial thickness of $58.5 \pm 2 \mu\text{m}$ on Fourier domain OCT. Tao et al., [24] reported thickness of $52.5 \pm 2.4 \mu\text{m}$ on Fourier domain OCT. Sin and Simpson [25] reported thickness of $52 \pm 3 \mu\text{m}$ on time domain OCT while Reinstein et al., [20] reported thickness of $53.4 \pm 4.6 \mu\text{m}$ on Artemis 1 (Arc Scan) very high-frequency digital ultrasound. Yang et al., [26] reported average CET ($53.2 \pm 2.9 \mu\text{m}$) measured by OCT system (Optovue, Inc., Fremont, CA) in the range of (48.0-59.9 μm). Rush et al., [13] reported a mean CET of 51.0 μm with a range of 43 to 61 μm . The average central

CET reported by Kim et al., [18] falls within the range of (48.0-59.9 gm).

Ethnic variability could be a considerable factor in CET. Our study includes only healthy Egyptian adults of all ages, the results demonstrated that gender was not correlated with CET. In a study including only healthy Korean adults of all ages the results demonstrated that gender was correlated with CET [18].

In conclusion, epithelial mapping seems to be an important tool in a refractive surgeon's armamentarium for differentiating suspicious from normal corneas and identifying those with true progression of corneal ectasia. The authors believe that the addition of the epithelial map to the pre-operative refractive surgery workup and in postoperative evaluation in case of suboptimal results will go a long way in making more accurate management decision, with improved outcomes.

Since the SD-OCT is a non-contact procedure that is easy to perform and is not uncomfortable for the patients, it has the potential to become part of the routine examination for the diagnosis of early keratoconus and for determining candidacy for refractive surgery.

The possible explanation for the inconsistencies in the results of different studies could be the uncontrolled factors affecting the CET measurement such as gender, race, ethnic variability, refraction, tear film thickness, the climatic state in the tested region and using equipment of different technology.

We hope to have future imaging technologies with higher resolution, with capability to cover the entire cornea and with the ability to exclude tear film thickness in the measurement. All these will help in evaluation CET more accurately and confirm its association with aging.

Conclusion:

Our study reports there was no statistically significant correlation found between the gender of the studied subjects and epithelial thickness of the cornea.

References

- 1- KOTB M. and EISSA S.A.: Correlation between Myopic Refractive Error, Corneal Power and Central Corneal Thickness in the Egyptian Population. *Clin. Ophthalmol.*, 15: 1557-1566, 2021. Published 2021 Apr 19. doi:10.2147/OPTH.S304693.
- 2- KHAMAR P., RAO K., WADIA K., et al.: Advanced epithelial mapping for refractive surgery. *Indian J. Ophthalmol.*, 68 (12): 2819-2830, 2020. doi:10.4103/ijo.IJO_2399_20
- 3- LOUREIRO T.O., RODRIGUES-BARROS S., LOPES D., et al.: Corneal Epithelial Thickness Profile in Healthy Portuguese Children by High-Definition Optical Coherence Tomography. *Clin Ophthalmol.*, 15: 735-743, 2021. Published 2021 Feb. 24. doi: 10.2147/OPTH.S293695.
- 4- HOU J., WANG Y., LEI Y., ZHENG X. and ZHANG Y.: Corneal Epithelial Remodeling and Its Effect on Corneal Asphericity after Transepithelial Photorefractive Keratectomy for Myopia. *J. Ophthalmol.*, 2016: 8582362, 2016. doi: 10.1155/2016/8582362.
- 5- CHEN X., STOJANOVIC A., WANG X., LIANG J., HU D. and UTHEIM T.P.: Epithelial Thickness Profile Change After Combined Topography-Guided Transepithelial Photorefractive Keratectomy and Corneal Cross-linking in Treatment of Keratoconus. *J. Refract Surg.*, 32 (9): 626-634, 2016. doi:10.3928/1081597X-20160531-02.
- 6- SAMY M.M., SHAABAN Y.M. and BADRAN T.A.F.: Age- and sex-related differences in corneal epithelial thickness measured with spectral domain anterior segment optical coherence tomography among Egyptians. *Medicine (Baltimore)*, 96 (42): e8314, 2017. doi:10.1097/MD.00000000000008314
- 7- WU Y. and WANG Y.: Detailed Distribution of Corneal Epithelial Thickness and Correlated Characteristics Measured with SD-OCT in Myopic Eyes. *J. Ophthalmol.*, 2017: 1018321, 2017. doi:10.1155/2017/1018321.
- 8- BUFFAULT J., ZÉBOULON P., LIANG H., et al.: Assessment of corneal epithelial thickness mapping in epithelial basement membrane dystrophy. *PLoS One*, 15 (11): e0239124, 2020. Published 2020 Nov. 25. doi: 10.1371/journal.pone.0239124.
- 9- JIAO H., HILL L.J., DOWNIE L.E. and CHINNERY H.R.: Anterior segment optical coherence tomography: its application in clinical practice and experimental models of disease. *Clin. Exp. Optom.*, 102 (3): 208-217, 2019. doi: 10.1111/cxo.12835.
- 10- TAN A.C.S., TAN G.S., DENNISTON A.K., et al.: An overview of the clinical applications of optical coherence tomography angiography. *Eye (Lond)*, 32 (2): 262-286, 2018. doi:10.1038/eye.2017.181.
- 11- PUJARI A. and SHARMA N.: The Emerging Role of Anterior Segment Optical Coherence Tomography in Cataract Surgery: Current Role and Future Perspectives. *Clin. Ophthalmol.*, 15: 389-401, 2021. <https://doi.org/10.2147/OPTH.S286996>
- 12- KHALILI M., ASADI M., KAHROBA H., SOLEYMAN M.R., ANDRE H. and ALIZADEH E.: Corneal endothelium tissue engineering: An evolution of signaling molecules, cells, and scaffolds toward 3D bioprinting and cell sheets [published online ahead of print, 2020 Oct 8]. *J. Cell Physiol.*, 10.1002/jcp.30085, 2020. doi: 10.1002/jcp.30085.
- 13- RUSH S.W., MATULICH J., BISKUP J., et al.: Corneal epithelial thickness measured by manual electronic caliper spectral domain optical coherence tomography: Distributions and demographic correlations in preoperative refractive surgery patients. *Asia. Pac. J. Ophthalmol.*, 5: 147-150, 2016.
- 14- KANELLOPOULOS A.J. and ASIMELLIS G.: In vivo three-dimensional corneal epithelium imaging in normal

- eyes by anterior-segment optical coherence tomography: A clinical reference study. *Cornea*, 32: 1493-8, 2013.
- 15- GIUFFRÈ G., DI ROSA L., FIORINO F., BUBELLA D.M. and LODATO G.: Variations in central corneal thickness during the menstrual cycle in women. *Cornea*, 26: 144-146, 2007.
 - 16- DU C., WANG J., CUI L., et al.: Vertical and horizontal corneal epithelial thickness profiles determined by ultra-high resolution optical coherence tomography. *Cornea*, 31: 1036-1043, 2012.
 - 17- HASHMANI N., HASHMANI S. and SAAD C.M.: Wide Corneal Epithelial Mapping Using an Optical Coherence Tomography. *Invest Ophthalmol. Vis. Sci.*, 59 (3): 1652-1658, 2018. doi:10.1167/iops.17-23717.
 - 18- KIM B.J., RYU I.H. and KIM S.W.: Age-related differences in corneal epithelial thickness measurements with anterior segment optical coherence tomography. *Jpn. J. Ophthalmol.*, 60: 357-64, 2016.
 - 19- KING-SMITH P., FINK B., FOGT N., et al.: The thickness of the human precorneal tear film: Evidence from reflection spectra. *Invest Ophthalmol. Vis. Sci.*, 41: 3348-3359, 2000.
 - 20- REINSTEIN D.Z., ARCHER T.J., GOBBE M., SILVERMAN R.H. and COLEMAN D.J.: Epithelial thickness in the normal cornea: Three-dimensional display with artemis very high-frequency digital ultrasound. *J. Refract Surg.*, 24: 571-81, 2008.
 - 21- CATALAN S., CADARSO L., ESTEVES F., SALGADO-BORGES J., LOPEZ M. and CADARSO C.: Assessment of Corneal Epithelial Thickness in Asymmetric Keratoconic Eyes and Normal Eyes Using Fourier Domain Optical Coherence Tomography. *J. Ophthalmol.*, 2016: 5697343, 2016.
 - 22- OSTADIAN F., FARRAHI F. and MAHDIAN RAD A.: Comparison of Corneal Epithelial Thickness Map Measured by Spectral Domain Optical Coherence Tomography in Healthy, Subclinical and Early Keratoconus Subjects. *Med. Hypothesis Discov. Innov. Ophthalmol.*, 8 (2): 85-91, 2019.
 - 23- AGARWAL A.: Assessment of corneal epithelial thickness by Fourier domain OCT. *Ocular Surgery News US Edition*, 2011.
 - 24- TAO A., WANG J., CHEN Q., SHEN M., LU F., DUBOVY S.R. and ABOU SHOUSA M.: Topographic thickness of Bowman's layer determined by ultra-high resolution spectral domain-optical coherence tomography. *Investigative ophthalmology & visual science*, 52 (6): 3901-7, 2011.
 - 25- SIN S. and SIMPSON T.L.: The repeatability of corneal and corneal epithelial thickness measurements using optical coherence tomography. *Optom. Vis. Sci.*, 83: 360-5, 2006.
 - 26- YANG Y., HONG J., DENG S.X. and XU J.: Age-related changes in human corneal epithelial thickness measured with anterior segment optical coherence tomography. *Invest Ophthalmol. Vis. Sci.*, 55: 5032-8, 2014.

دراسة سمك النسيج الطلائى للقرنية باستخدام الجزء الأمامى من التصوير الطبقي البصرى فى الفئة العمرية لتصحيح الابصار بالليزر من المصريين

يعد قياس سمك النسيج الطلائى وسماكة أنسجة القرنية بشكل منفصل يمكن أن يسهل اكتشاف أمراض القرنية فى مرحلة مبكرة. ويعد القياس الدقيق لقيم الجزء الأمامى من العين أمر ضرورى لتقييم ما قبل الجراحة، وتخطيط ومتابعة جراحات المياه البيضاء وتصحيح الابصار وعملية التئام الجروح من بعد اجراء العملية.

النسيج الطلائى للقرنية مهم فى المحافظة على تحدب القرنية وانتظام السطح الأمامى من سطح القرنية، وهو مهم أيضاً فى قوة القرنية ووظائفها وتماسك طبقة الدمع فى العين. هناك عدة عوامل ممكن أن تؤثر فى سمك النسيج الطلائى من القرنية ومنها جفاف العين، استخدام العدسات اللاصقة، القرنية المخروطية وعمليات تصحيح الابصار.

تم اكتشاف أن العوامل الديموغرافية والعرقية مرتبطة بسمك القرنية ويمكن أن تؤثر هذه العوامل أيضاً على النسيج الطلائى للقرنية.

المعرفة بالطبوغرافيا للقرنية الأمامية مهمة فى معرفة معظم أمراض القرنية وكيفية علاجها عن طريق عمليات تصحيح الابصار.

يعتبر جهاز التصوير المقطعى الأمامى واحد من أفضل الأدوات فى فحص الجزء الأمامى من العين حيث يسمح بفحص سريع للجزء الأمامى من العين دون ملامسة العين بدون استخدام تخدير الموضعى، وذلك من خلال جلوس المريض أمام الكاميرا، وهذا يوفر الراحة للمريض مع عدم حدوث خدش بالقرنية.

الهدف من البحث : أن الهدف من هذا البحث سيكون قياس التغيرات المختلفة التى تحدث فى النسيج الطلائى لقرنية العين فى مجموعة من المصريين التى تتناسب أعمارهم مع عملية تصحيح الابصار بالليزر باستخدام التصوير المقطعى الأمامى.

نتائج البحث : تضمنت هذه الدراسة ١٠٠ شخصاً (٥٠ من الذكور و ٥٠ من الإناث)، التى تراوحت أعمارهم بين ١٨ إلى ٥٠ سنة.

وقد وجدت الدراسة عدم وجود فرق ذى دلالة إحصائية بين الذكور والإناث فيما يتعلق بسمك النسيج الطلائى فى جميع أجزاء القرنية ولكن سمك النسيج عند الذكور كان أكثر سمكاً بمقدار ٠.٥٦ مم من الإناث فى الجزء المركزى.