

## Ginkgo Biloba as an adjuvant to Timolol in Moderate Primary Open Angle Glaucoma

Ahmad Gamal Elwahidy <sup>1</sup>\*M.B.B.Ch; Ibrahim Hassan Elabd <sup>2</sup>MD; Said Ibrahim Shalaby <sup>1</sup>MD and Mahmood Abdel Haleem Rabee <sup>2</sup>MD.

### \*Corresponding Author:

Ahmad Gamal Elwahidy  
[ag.elwahidy@nrc.sci.eg](mailto:ag.elwahidy@nrc.sci.eg)

Received for publication March 05, 2022; Accepted August 31, 2022; Published online August 31, 2022.

doi: 10.21608/aimj.2022.121598.1842

**Citation:** Ahmad G. , Ibrahim H. and Said I. et al Ginkgo Biloba as an adjuvant to Timolol in Moderate Primary Open Angle Glaucoma. AIMJ. 2022; Vol.3- Issue8 : 129-137.

<sup>1</sup>Complementary Medicine Department, Medical Research and Clinical Studies Institute, National Research Centre, Cairo , Egypt.

<sup>2</sup>Ophthalmology Department, Faculty of Medicine, Al-Azhar University, Cairo , Egypt.

### ABSTRACT

**Background:** Timolol eye drops is used in the treatment of Primary Open Angle Glaucoma (POAG). Ginkgo Biloba has neuroprotective and anti-oxidative effects and increases the blood flow thus it is a potentially useful treatment in glaucoma.

**Aim of The Work:** Assessing the safety and efficacy of using Ginkgo Biloba with Timolol in moderate POAG.

**Patients and Methods:** A case group “90 eyes” with moderate POAG were instructed to add 120 mg/day of Ginkgo to daily dose of Timolol and a control group “90 eyes” continued on Timolol only. We used Visual Field Analyzer and Optical coherence tomography angiography “OCTA” in assessment. We also tested its effect on coagulation. Duration was 6 months.

**Results:** 77 eyes in case group and 70 eyes in control group completed the study.No significant differences among the two groups regarding age and gender. Regarding coagulation tests; there were no significant differences or changes in both groups before or after treatment.

In case group; there were significant improvements about 7.7% in VFI% (p 0.014), 13.5% in MD (p 0.018), 2.6% in outer region perfusion % of ONH (p 0.003), 4.6% in outer region flux index of ONH (p 0.009), 6.4% in full perfusion density % of Macula (p 0.049), and 6.5% in full vessel density of Macula (p 0.008).

There was non-significant change in control group with no significant difference between the groups regarding baseline level but there was a significant difference between them at the study end. No side effects were found.

**Conclusion:** Ginkgo Biloba is a beneficial adjuvant to Timolol in Moderate POAG.

**Keywords:** glaucoma; Ginkgo; Timolol.

**Disclosure:** The authors have no financial interest to declare in relation to the content of this article. The Article Processing Charge was paid for by the authors.

**Authorship:** All authors have a substantial contribution to the article.

**Copyright** The Authors published by Al-Azhar University, Faculty of Medicine, Cairo, Egypt. Users have the right to read, download, copy, distribute, print, search, or link to the full texts of articles under the following conditions: Creative Commons Attribution-Share Alike 4.0 International Public License (CC BY-SA 4.0).

### INTRODUCTION

Glaucoma is a major cause of irreversible blindness in the world.<sup>1</sup> It has been noticed that blood flow is decreased in glaucoma patients in different tissues of the eye.<sup>2</sup> Primary open-angle glaucoma (POAG), is a chronic, progressive neurodegenerative disease characterized by cupping of optic disc and loss of visual field.<sup>3</sup> In addition to increased Intraocular Pressure (IOP); there are more risk factors like genetic factors, decreased intracranial pressure, systemic diseases and neurodegenerative diseases associated factors like oxidative damage, mitochondrial dysfunction, microglial activation and excitotoxicity, can also contribute in the glaucomatous damage of optic nerve.<sup>4</sup>

Despite these variable causes; the only proven treatment is decreasing IOP using medical, laser, or surgical procedures, that reduce vascular resistance thus increase mean vascular flow. FDA has only approved calcium channel blockers as a treatment

dealing with the vascular risk factors but there are doubts about their efficacy. This is why, new treatments are needed to be discovered to deal with those biochemical, genetic, cell biological, and pathophysiologic mechanisms.<sup>4</sup>

Chinese traditional medicine has used Ginkgo Biloba for about 5000 years.<sup>5</sup> Currently, its extraction is utilized in multiple medical conditions like concentration difficulties, confusion, depression, anxiety, dizziness, headache and tinnitus.<sup>6</sup> It has been proven that Ginkgo has a neuroprotective and anti-oxidative properties. It also causes vasodilation and reduction of blood viscosity thus increases blood flow. These characteristics suggest that Ginkgo Biloba could be a proficient adjuvant treatment in glaucoma.<sup>7</sup> Several studies were done to examine the role of Ginkgo Biloba in Normal Tension Glaucoma (NTG), they showed that Ginkgo Biloba has increased the retinal blood flow and improved preexisting visual field damage.<sup>4, 8-11</sup>

This study was done to assess the safety and the efficacy of using Ginkgo Biloba capsules with

Timolol eye drops in the treatment of patients with moderate POAG.

## PATIENTS AND METHODS

### Patients

This randomized comparative clinical trial was conducted between May and December 2021 at “The Department of Ophthalmology in El-Huseein & El-sayed Galal Al-Azhar University Hospitals, Cairo, Egypt”.

### Ethical Consideration

We received the approval for this study from The Ethics Board of Al-Azhar University, Cairo, Egypt and the Medical Research Ethical Committee of the National Research Centre, Cairo, Egypt under the number “41022022”. Before starting the study; we collected a written informed consent from each participant. The study followed the principles specified in the Declaration of Helsinki.

### Inclusion Criteria

Patients with moderate POAG aged 30 to 50 years old of both genders. IOP should only be controlled by Timolol. Patients should have the mental and physical capacity to give informed consents and follow the instructions. If a patient is on medication that affects blood flow then there should be no alteration in the dose or direction of medication for at least 2 months before starting the study. No vitamin supplements for 1 month before starting the study & during the study.

Moderate stage POAG was defined according to (the Glaucoma Severity Staging System Classification)<sup>3</sup> that has the following characteristics; Humphrey MD score = -5.01 to -12.00 AND regarding probability plot/pattern deviation; points below 5% should be 19-36 and points below 1% should be 12-18 OR regarding dB plot; point(s) within the central 5° with sensitivity of <15 dB should be > 1 and point(s) within the central 5° with sensitivity of <0 dB should be none (0) OR Points(s) with sensitivity <15 dB within 5° of fixation is only 1 hemifield (1 or 2).

### Exclusion Criteria

Visual acuity of 6/12 or less, Anisometropia >1 D, Central Corneal Thickness < 500 µm in either eye, lens opacities more severe than C2, N2, P2 according to lens opacities classification system III criteria, previous ocular and systemic disorder that could affect optic disc appearance and VF test (e.g. high myopia, tilted disc, DM), history of ocular surgeries, history of having ocular inflammation or infection in the 3 months before trial, hypersensitivity to Ginkgo Biloba, pregnancy or breastfeeding women, addiction or alcoholism, use of other ocular medications that might affect IOP, use of other similar systemic medications (e.g., ergoloid mesylate derivative: a vasodilator agent) and contact lens wearers.

### Study Design

We initially enrolled 90 patients with moderate POAG with IOP being normalized by Timolol alone. The study extended for 6 months (180 days). Patients were divided into two groups; a case group of 45 patients who continued on Timolol with addition of Ginkgo Biloba capsules (40mg capsule 3X/day for a total of 120mg/day) and a control group of 45 patients who continued using Timolol eye drops alone.

### Methods

Each patient was subjected to the following at the beginning of the study then every 2 months; full history taking, coagulation tests that included bleeding time (BT), activated partial thromboplastin time (aPTT), prothrombin time (PT/ INR) and thrombin time (TT) and ocular examination that included slit lamp examination, gonioscopy, angle examination, retinal and optic disc evaluation, measuring visual acuity and IOP.

Visual field (VF) examination was done at the beginning and at the end of the study. We used “Humphrey Field Analyzer 3; Carl Zeiss Meditec Inc, Dublin, Ca, USA” with Central 24-2 Threshold Test and the “Swedish Interactive Threshold Algorithm (SITA)” was set to fast. Visual Field Index percent (VFI %) and Mean Deviation dB (MD) are global indices that were used to assess the results.<sup>12,13</sup>

Optical coherence tomography angiography (OCTA) was done at the beginning and at the end of the study. We used “AngioPlex Cirrus HD-OCT device (model 5000, Carl Zeiss Meditec, Inc., Dublin, USA)”. We applied a scanning area of 6 × 6 mm<sup>2</sup> centered on the ONH and a scanning area of 4.5x4.5 mm<sup>2</sup> centered on the macula. The outer region of ONH contains the radial peripapillary capillary (RPC). For OCTA of ONH; we used two parameters in assessment; perfusion density % and flux index. For OCTA of Macula; we used perfusion density % and vessel density parameters that were defined in the “Early treatment of diabetic retinopathy study (ETDRS)”.<sup>14,15</sup>

### Statistical Analysis

It has been done using IBM SPSS statistics (Statistical Package for Social Sciences) software version 26.0, IBM Corp., Chicago, USA, 2019. Data were expressed as mean ± SD (standard deviation), then compared using independent t-test (groups comparisons) and paired t-test (times comparisons). Differences between groups were expressed as Mean ± SE (standard error) and 95% confidence interval. P value was considered to be significant if < 0.05.

## RESULTS

Of a total of 90 cases that were initially enrolled in this study, only 82 cases completed the study whom were distributed as 42 patients (77 eyes) in the case group, and 40 patients (70 eyes) in the control group. The other eyes were excluded due to poor image quality caused by media opacities like “vitreous floaters”, motion artifact or blink artifact.

Regarding Age and gender; the differences were not significant among the two groups (Table 1).

	Case group		Control group	p-value	Sig.
	No.= 42 patients		No.= 40 patients		
Age (years), Mean±SD	39.35±5.61		39.57±6.64	0.872•	NS
Gender	Male	24 (57%)	23 (57.5%)	0.974*	NS
	Female	18 (43%)	17 (42.5%)		

Non-significant (NS) if P-value > 0.05, Significant (S) if P-value < 0.05., • Independent t-test, \* Chi-square test.

**Table 1:** Comparison regarding demographic characteristics

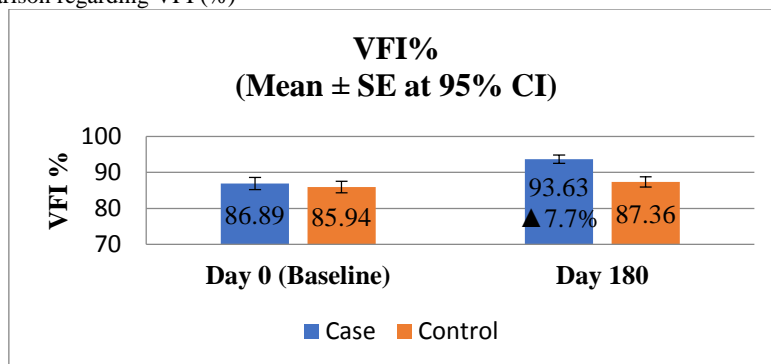
Regarding coagulation tests (BT, aPTT, PT/INR and TT), visual acuity and IOP; there were no significant differences between the follow up levels and baseline level in both groups and the differences were not significant between them at the baseline and the follow up levels.

Regarding VFI%; there was a significant improvement “▲7.7%” at the end of the study in the case group (Mean difference = 6.73±10.80; p= 0.014) with non-significant change in the control group (Mean difference = 1.42±5.88; p= 0.306). The difference between the case and control groups was not significant regarding baseline level but at the study end the difference was significant (93.63±10.12 vs 87.36±11.64; p = 0.001). (Table 2), (Fig. 1)

Time	Cases (N=77 eyes) Mean±SD	Control (N=70 eyes) Mean±SD	# p-value	Change in Cases relative to Control	
				Mean±SE	95% CI
<b>Levels</b>					
Day 0 (Baseline)	86.89±15.07	85.94±13.61	0.690 (NS)	0.95 ± 2.37	-3.74-5.64
Day 180	93.63±10.12	87.36±11.64	0.001 (S)	6.27±1.79	2.72-9.81
<b>Mean Difference from Day 0 (Baseline)</b>					
Day 180	6.73±10.80 (▲7.7%)	1.42±5.88	<0.001 (S)	5.31±1.45	2.43-8.18
* p-value	0.014 (S)	0.306 (NS)			

CI: Confidence interval, # Independent t-test, SE: Standard error, \*Paired t-test, Non-significant (NS) if P-value > 0.05, Significant (S) if P-value < 0.05

**Table 2:** Comparison regarding VFI (%)



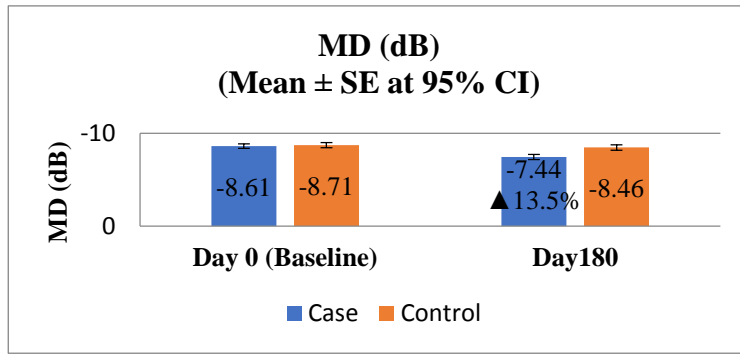
**Fig. 1:** Comparison regarding VFI (%)

Regarding MD; there was a significant improvement “▲13.5%” at the end of the study in the case group (Mean difference = 1.17±1.95; p= 0.018) with non-significant change in the control group (Mean difference = 0.24±1.16, p = 0.378). The difference between the two groups was not significant regarding the baseline level but at the study end the difference between them was significant (-7.44±2.53 vs -8.46±2.44; p = 0.014). (Table 3), (Fig. 2)

Time	Cases (N=77 eyes) Mean±SD	Control (N=70 eyes) Mean±SD	# p-value	Change in Cases relative to Control	
				Mean±SE	95% CI
<b>Levels</b>					
Day 0 (Baseline)	-8.61±2.17	-8.71±2.39	0.791 (NS)	0.1±0.37	-0.64-0.84
Day 180	-7.44±2.53	-8.46±2.44	0.014 (S)	1.02±0.41	0.2-1.83
<b>Mean Difference from Day 0 (Baseline)</b>					
Day 180	1.17±1.95 (▲13.5%)	0.24±1.16	0.001 (S)	0.93±0.26	0.4-1.46
* p-value	0.018 (S)	0.378 (NS)			

CI: Confidence interval, # Independent t-test, SE: Standard error, \*Paired t-test, Non-significant (NS) if P-value > 0.05, Significant (S) if P-value < 0.05

**Table 3:** Comparison regarding MD (dB)



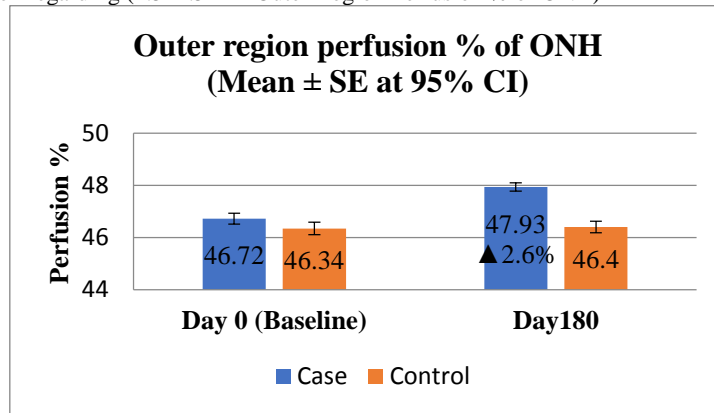
**Fig. 2:** Comparison regarding MD (dB)

Regarding Outer region perfusion % of ONH; there was a significant improvement “▲2.6%” at the end of the study in the case group (Mean difference = 1.21±1.54; p = 0.003) with non-significant change in the control group (Mean difference =0.05±0.74; p= 0.740). The difference between the two groups was not significant regarding the baseline level but at the study end the difference between them was significant (47.93±1.42 vs 46.4±1.87; p < 0.001). (Table 4) and (Fig. 3, 4)

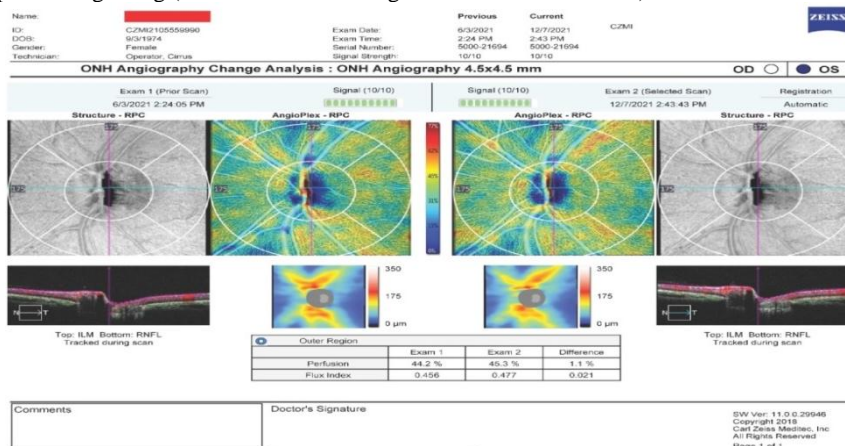
Time	Cases (N=77 eyes) Mean±SD	Control (N=70 eyes) Mean±SD	# p-value	Change in Cases relative to Control	
				Mean±SE	95% CI
<b>Levels</b>					
<b>Day 0 (Baseline)</b>	46.72±1.86	46.34±2.05	0.241 (NS)	0.38±0.32	-0.25-1.01
<b>Day 180</b>	47.93±1.42	46.4±1.87	<0.001 (S)	1.53±0.27	0.99-2.06
<b>Mean Difference from Day 0 (Baseline)</b>					
<b>Day 180</b>	1.21±1.54 (▲2.6%)	0.05±0.74	<0.001 (S)	1.16±0.2	0.76-1.56
<b>* p-value</b>	0.003 (S)	0.740 (NS)			

CI: Confidence interval, # Independent t-test, SE: Standard error, \*Paired t-test, Non-significant (NS) if P-value > 0.05, Significant (S) if P-value < 0.05

**Table 4:** Comparison regarding (4.5x4.5 mm Outer Region Perfusion % of ONH)



**Fig. 3:** Comparison regarding (4.5x4.5 mm Outer Region Perfusion % of ONH)



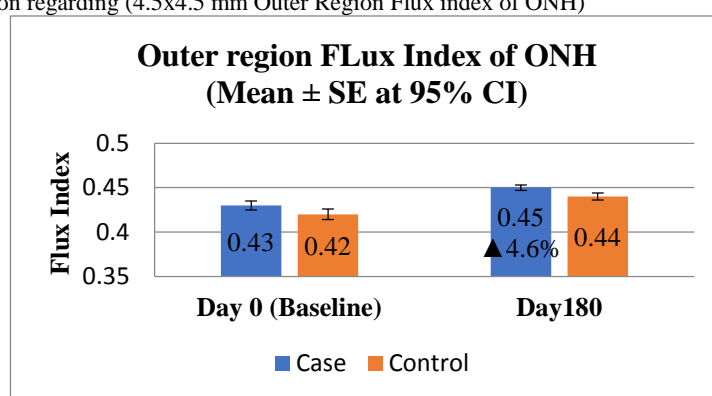
**Fig. 4:** OCTA change analysis report of ONH of left eye (a sample report from our study).

Regarding outer region flux index of ONH; there was a significant improvement “▲4.6%” at the end of the study in the case group (Mean difference = 0.02±0.03; p = 0.009) with non-significant change in the control group (Mean difference =0.01±0.03; p = 0.083). The difference between the two groups was not significant regarding the baseline level but at the study end the difference between them was significant (0.45±0.03 vs 0.44±0.03; p = 0.045). (Tables 5) and (Fig. 4, 5)

Time	Cases (N=77 eyes) Mean±SD	Control (N=70 eyes) Mean±SD	# p-value	Change in Cases relative to Control	
				Mean±SE	95% CI
<b>Levels</b>					
Day 0 (Baseline)	0.43±0.04	0.42±0.05	0.181 (NS)	0.01±0.007	-0.005-0.025
Day 180	0.45±0.03	0.44±0.03	0.045 (S)	0.01±0.005	0-0.02
<b>Mean Difference from Day 0 (Baseline)</b>					
Day 180	0.02±0.03 (▲4.6%)	0.01±0.03	0.045 (S)	0.01±0.005	0-0.02
* p-value	0.009 (S)	0.083 (NS)			

CI: Confidence interval, # Independent t-test, SE: Standard error, \*Paired t-test, Non-significant (NS) if P-value > 0.05, Significant (S) if P-value < 0.05

**Table 5:** Comparison regarding (4.5x4.5 mm Outer Region Flux index of ONH)



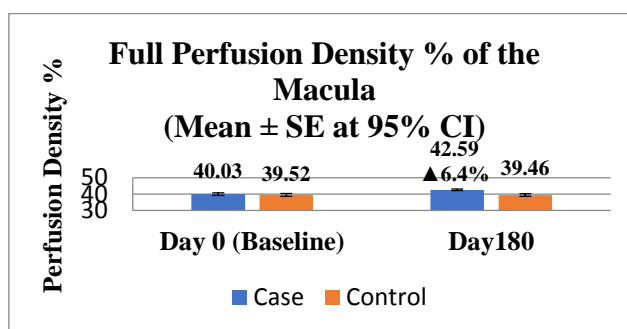
**Fig. 5:** Comparison regarding (4.5x4.5 mm Outer Region Flux index of ONH)

Regarding full perfusion density % of Macula; there was a significant improvement “▲6.4%” at the end of the study in the case group (Mean difference = 2.56±5.44; p = 0.049) with non-significant change in the control group (Mean difference = -0.05±0.6; p= 0.687 The difference between the two groups was not significant regarding the baseline level but at the study end the difference between them was significant (42.59±4.9 vs 39.46±6.82; p = 0.002). (Tables 6) and (Fig. 6, 7)

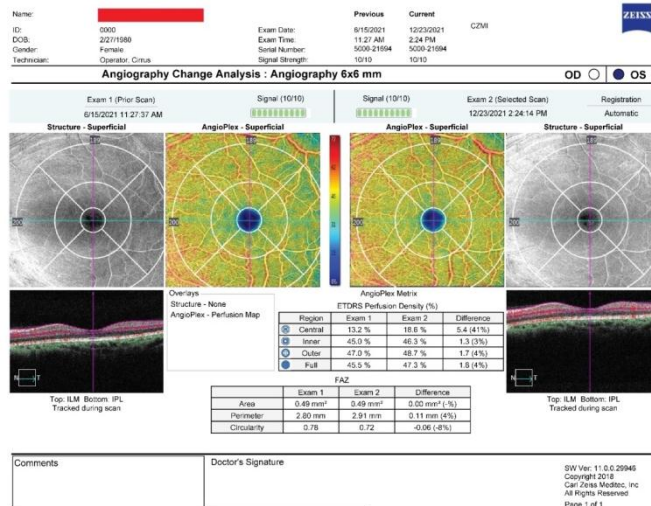Time	Cases (N=77 eyes) Mean±SD	Control (N=70 eyes) Mean±SD	# p-value	Change in Cases relative to Control	
				Mean±SE	95% CI
<b>Levels</b>					
Day 0 (Baseline)	40.03±6.82	39.52±6.75	0.650 (NS)	0.51±1.12	-1.7-2.72
Day 180	42.59±4.9	39.46±6.82	0.002 (S)	3.13±0.97	1.2-5.05
<b>Mean Difference from Day 0 (Baseline)</b>					
Day 180	2.56±5.44 (▲6.4%)	-0.05±0.6	<0.001 (S)	2.61±0.65	1.31-3.9
* p-value	0.049 (S)	0.687 (NS)			

CI: Confidence interval, # Independent t-test, SE: Standard error, \*Paired t-test, Non-significant (NS) if P-value > 0.05, Significant (S) if P-value < 0.05

**Table 6:** Comparison regarding (ETDRS 6x6mm Full Perfusion Density % of Macula)



**Fig. 6:** Comparison regarding (ETDRS 6x6mm Full Perfusion Density % of Macula)

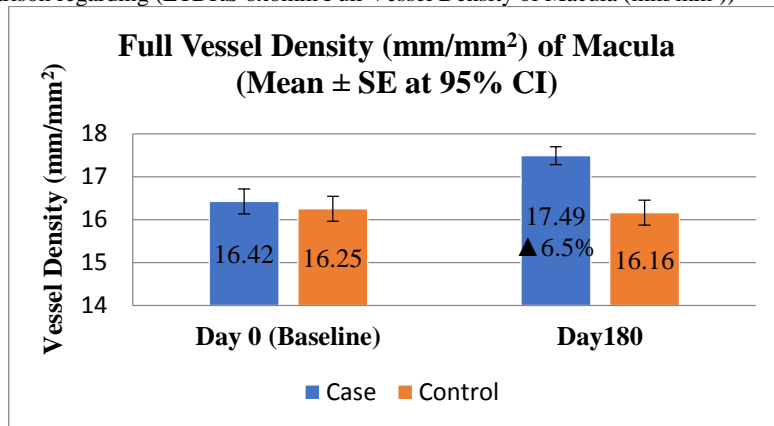


**Fig. 7:** OCTA change analysis report of Macula “Perfusion Density” of left eye (a sample report from our study) Regarding full vessel density of Macula; there was a significant improvement “▲6.5%” at the end of the study in the case group Mean difference = 1.07±1.63; p = 0.008) with non-significant change in the control group (Mean difference = -0.09±0.44; p = 0.382). The difference between the two groups was not significant regarding the baseline level but at the study end the difference between them was significant (17.49±1.84 vs 16.16±2.5; p < 0.001). (Tables 7) and (Fig. 8, 9)

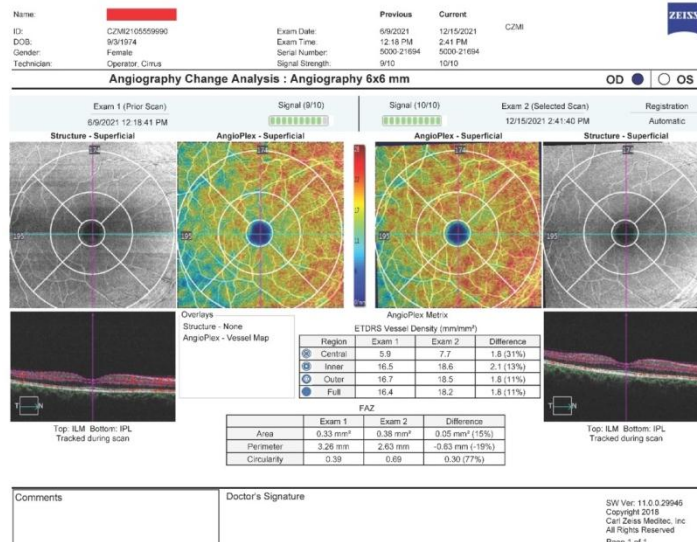
Time	Cases (N=77 eyes) Mean±SD	Control (N=70 eyes) Mean±SD	# p-value	Change in Cases relative to Control	
				Mean±SE	95% CI
<b>Levels</b>					
<b>Day 0 (Baseline)</b>	16.42±2.61	16.25±2.49	0.687 (NS)	0.17±0.42	-0.66-1
<b>Day 180</b>	17.49±1.84	16.16±2.5	<0.001 (S)	1.33±0.36	0.61-2.04
<b>Mean Difference from Day 0 (Baseline)</b>					
<b>Day 180</b>	1.07±1.63 (▲6.5%)	-0.09±0.44	<0.001 (S)	1.16±0.2	0.76-1.55
<b>* p-value</b>	0.008 (S)	0.382 (NS)			

CI: Confidence interval, # Independent t-test, SE: Standard error, \*Paired t-test, Non-significant (NS) if P-value > 0.05, Significant (S) if P-value < 0.05

**Table 7:** Comparison regarding (ETDRS 6x6mm Full Vessel Density of Macula (mm/mm<sup>2</sup>))



**Fig. 8:** Comparison regarding (ETDRS 6x6mm Full Vessel Density of Macula (mm/mm<sup>2</sup>))



**Fig. 9:** OCTA change analysis report of Macula “Vessel Density” of right eye (a sample report from our study).

## DISCUSSION

POAG is characterized by a chronically elevated IOP in the absence of any structural abnormalities and is usually primary treated by IOP lowering medications like Timolol. It is important to know that the pathology behind glaucomatous optic neuropathy which is retinal ganglion cells “RGC” apoptosis; is not only caused by elevated IOP but also by vascular dysfunction, mitochondrial dysfunction and oxidative stress.<sup>16-19</sup>

Ginkgo Biloba contains more than 60 known bioactive compounds.<sup>20</sup> Studies on animal models have shown that Ginkgo Biloba has anti-inflammatory, neuroprotective and anti-oxidant effects on RGCs.<sup>22-26</sup> Ginkgo Biloba also increases Nitric oxide “NO” levels, which has a vasodilation effect and causes an increase in ocular blood flow.<sup>21</sup> In a study by Chung et al; patients with glaucoma who took Ginkgo Biloba “40mg three times daily” for only two days had improved end-diastolic velocity of ophthalmic artery that was measured by Color Doppler Ultrasound with no effect on IOP, blood pressure or heart rate.<sup>27</sup> Another study showed that Ginkgo Biloba also increased velocity of blood flow in the retrobulbar vessels, superior, and inferior capillaries and decreased the central retinal and nasal short posterior ciliary arteries vascular resistance.<sup>28</sup> Park et al have also examined Ginkgo Biloba “80mg twice daily” in patients with NTG for 4 weeks, results revealed an increase in peripapillary blood flow, blood volume and velocity.<sup>11</sup>

In our study we found a statistically improvement in VF and ocular blood flow after adding Ginkgo Biloba to Timolol in comparison to the control group.

We evaluated ocular blood flow by using OCTA. OCTA is a novel non-invasive, dye-free technology that has shown to have an excellent repeatability and reproducibility in analyzing ONH perfusion.<sup>29-31</sup> OCTA is able to detect motion contrast from the blood flow thus making blood vessels visible.<sup>34</sup> In patients with glaucoma; a decrease in vessel

perfusion and density is seen more on the superficial retinal slab compared to the deep retinal slabs.<sup>33</sup>

Previous studies had utilized OCTA in POAG patients and they showed a reduction in ONH flow index and vessel density (nerve head slab) and in the peripapillary region (RPC slab) compared to controls.<sup>35-37</sup> Also superficial macular regions had shown a reduction in vessel densities in comparison to the control group.<sup>38-39</sup> As severity of glaucoma increases the vessel densities decreases more.<sup>34, 36, 40</sup>

In our study, after administration of Ginkgo Biloba; there was a statistically significant improvement in outer region “RPC” perfusion % of ONH ( $p=0.003$ ) and a statistically significant increase in Flux index ( $p=0.009$ ). Also we noticed a statistically significant improvement in perfusion density % of macula ( $p=0.049$ ) with a statistically significant increase in its vessel density ( $p=0.008$ ).

In visual field analysis; the global indices that are usually used to assess glaucomatous defects include the MD, VFI and the pattern standard deviation (PSD).

A number of studies have examined the ability of these indices to detect the progression of visual field in patients with glaucoma. The rates of change measured by VFI and the MD were found to correlate well and both detected a similar progression proportion in different stages of glaucoma. In case of advanced glaucoma; using PSD failed to detect progression.<sup>41, 42</sup> That is why we excluded PSD from analysis as a precaution.

Lee et al examined the effect of using Ginkgo Biloba on VF in NTG patients for 4 years period. There was an improvement in MD and regression coefficient after using Ginkgo Biloba in comparison to before treatment. There was no significant change in IOP in the studied patients.<sup>43</sup>

In a study by Quaranta et al; the role of Ginkgo Biloba was tested on 27 patients with NTG that suffer from VF deficits progression. After a dose of 40mg 3 times weekly, there were VF improvements

versus controls. There were no detectable alterations in IOP or the blood pressure.<sup>44</sup>

In our study; none of the patients had ocular or systemic adverse effects caused by Ginkgo Biloba. Coagulation status of our patients didn't show any significant change. These results seem to agree with those of an earlier double-blind placebo-controlled randomized clinical trial.<sup>45</sup>

The main strength of this study is using OCTA for the first time to our knowledge in assessing RPC and macular perfusion after Ginkgo Biloba administration.

The possible limitations of this study are the relatively short study duration and performing only two VF tests to determine the effect of Ginkgo Biloba. VF improvement could also be due to the improvement of patients' cognitive function which was not measured.

### CONCLUSION

Ginkgo Biloba administration in addition to Timolol has improved the ONH & Macular perfusion with improvement of VF. At a dose of 120mg/day; neither ocular nor systemic adverse effects were found. Ginkgo Biloba didn't alter the coagulation status of our patients.

Ginkgo Biloba is a safe and beneficial adjuvant to Timolol in patients with Moderate POAG. OCTA was a successful method in assessing ONH and Macular perfusion changes after adding Ginkgo Biloba.

Conflict of interest : none

### REFERENCES

1. Tham YC, Xiang Li, Wong TY, et al. Global Prevalence of Glaucoma and Projections of Glaucoma Burden through 2040: A Systematic Review and Meta-Analysis. *American Academy of Ophthalmology Journal* 2014; 121: 2081-90.
2. Mozaffarieh M, Grieshaber MC and Flammer J. Oxygen and blood flow: players in the pathogenesis of glaucoma. *Mol Vis*. 2008; 14: 224–33.
3. Mills RP, Budenz DL, Lee PP, et al. Categorizing the Stage of Glaucoma from Pre-Diagnosis to End-Stage Disease. *Am J Ophthalmol*. 2006;141:24–30.
4. Labkovich M, Jacobs EB, Bhargava S, et al. Ginkgo Biloba Extract in Ophthalmic and Systemic Disease, With a Focus on Normal-Tension Glaucoma. *Asia Pac J Ophthalmol (Phila)*. 2020;9:215–25.
5. Dubey AK, Shankar PR, Upadhyaya D, et al. Ginkgo biloba--an appraisal. *Kathmandu Univ Med J (KUMJ)*. 2004 Jul-Sep;2(3):225-9.
6. Birks J and Grimley Evans J. Ginkgo biloba for cognitive impairment and dementia. *Cochrane Database Syst Rev*. 2009 Jan 21;(1):CD003120.
7. Kang JM and Lin S. Ginkgo biloba and its potential role in glaucoma. *Curr Opin Ophthalmol*. 2018, 29:116–20.
8. Lee J, Sohn SW and Kee C. Effect of Ginkgo biloba Extract on Visual Field Progression in Normal Tension Glaucoma. *J Glaucoma*. 2013;22:780–4.
9. Shim SH, Kim JM, Choi CY, et al. Ginkgo biloba Extract and Bilberry Anthocyanins Improve Visual Function in Patients with Normal Tension Glaucoma. *J Med Food*. 15 (9) 2012, 818–23.
10. Cybulska-Heinrich A.K, Mozaffarieh M and Flammer J. Ginkgo biloba: An adjuvant therapy for progressive normal and high tension glaucoma. *Molecular Vision*. 2012; 18:390-402.
11. Park JW, Kwon HJ, Chung WS, et al. Short-Term Effects of Ginkgo biloba Extract on Peripapillary Retinal Blood Flow in Normal Tension Glaucoma. *Korean J Ophthalmol*. 2011;25(5):323-8.
12. Hu R, Racette L, Chen KS, et al. Functional assessment of glaucoma: Uncovering progression. *Surv Ophthalmol*. 2020 Nov-Dec;65(6):639-61.
13. Salonikiou A, Founti P, Kilintzis V, et al. Tolerable rates of visual field progression in a population-based sample of patients with glaucoma. *Br J Ophthalmol*. 2018;102(7):916–21.
14. Wan KH, Leung CKS. Optical coherence tomography angiography in glaucoma: a mini-review. *F1000Res*. 2017 Sep 14;6:1686.
15. Yuan PH, Karst S, Maberley D, et al. Perfusion and vessel density changes in the superficial and deep capillary plexuses in diabetic retinopathy patients: a 1-year follow-up study. *Invest. Ophthalmol. Vis. Sci*. 2020;61(7):4096.
16. Dreyer EB and Grosskreutz CL. Excitatory mechanisms in retinal ganglion cell death in primary open angle glaucoma (POAG). *Clin Neurosci*. 1997;4(5):270-3.
17. Chrysostomou V, Rezanian F, Trounce IA, et al. Oxidative stress and mitochondrial dysfunction in glaucoma. *Curr Opin Pharmacol*. 2013; 13:12–5.
18. Schmidl D, Garhofer G and Schmetterer L. The complex interaction between ocular perfusion pressure and ocular blood flow: relevance for glaucoma. *Exp Eye Res*. 2011; 93:141–55.
19. Flammer J, Orgul S, Costa VP, et al. The impact of ocular blood flow in glaucoma. *Prog Retin Eye Res*. 2002; 21:359–93.
20. Ritch R. Potential role for Ginkgo biloba extract in the treatment of glaucoma. *Med Hypotheses*. 2000;54:221–35.
21. Koltermann A, Hartkorn A, Koch E, et al. Ginkgo biloba extract EGb 761 increases endothelial nitric oxide production in vitro and in vivo. *Cell Mol Life Sci*. 2007;64:1715–1722.
22. Martinez-Solis I, Acero N, Bosch-Morell F, et al. Neuroprotective potential of Ginkgo biloba in retinal diseases. *Planta Med*. 2019;85:1292–303.
23. Pinazo-Duran MD, Shoaie-Nia K, Zanon-Moreno V, et al. Strategies to reduce oxidative stress in glaucoma patients. *Curr Neuropharmacol*. 2018;16:903–18.
24. Tatton NA, Tezel G, Insolia SA, et al. In situ detection of apoptosis in normal pressure glaucoma. A preliminary examination. *Surv Ophthalmol*. 2001;45(suppl 3):S268–72. Discussion S273-66.
25. Wang Y, Huang C, Zhang H, et al. Autophagy in glaucoma: crosstalk with apoptosis and its implications. *Brain Res Bull*. 2015; 117:1–9.



26. Zhou X, Li F, Kong L, et al. Involvement of inflammation, degradation, and apoptosis in a mouse model of glaucoma. *J Biol Chem*. 2005;280:31240–8.
27. Chung HS, Harris A, Kristinsson JK, Ciulla TA, et al. Ginkgo biloba extract increases ocular blood flow velocity. *J Ocul Pharmacol Ther*. 1999;15:233–40.
28. Harris A, Gross J, Moore N, et al. The effects of antioxidants on ocular blood flow in patients with glaucoma. *Acta Ophthalmol*. 2018;96:e237–e41.
29. Manalastas PIC, Zangwill LM, Saunders LJ, et al. Reproducibility of optical coherence tomography angiography macular and optic nerve head vascular density in glaucoma and healthy eyes. *J Glaucoma*. 2017;26.
30. Chen CL, Bojikian KD, Xin C, et al. Repeatability and reproducibility of optic nerve head perfusion measurements using optical coherence tomography angiography. *J Biomed Opt*. 2016;21: 065002.
31. Kashani AH, Chen CL, Gahm JK, et al. Optical coherence tomography angiography: a comprehensive review of current methods and clinical applications. *Prog Retin Eye Res*. 2017;60:66–100.
32. Ghasemi FK, Tian JJ, Akil H, et al. Swept-source optical coherence tomography angiography of the optic disk in optic neuropathy. *Retina*. 2016;36:S168–77.
33. Liu L, Edmunds B, Takusagawa HL, et al. Projection-Resolved Optical Coherence Tomography Angiography of the Peripapillary Retina in Glaucoma. *Am J Ophthalmol*. 2019;207:99–109.
34. Takusagawa HL, Liu L, Ma KN, et al. Projection-Resolved Optical Coherence Tomography Angiography of Macular Retinal Circulation in Glaucoma. *Ophthalmology*. 2017;124:1589–99.
35. Jia Y, Wei E, Wang X, et al. Optical coherence tomography angiography of optic disc perfusion in glaucoma. *Ophthalmology*. 2014;121:1322–32.
36. Liu L, Jia Y, Takusagawa HL, et al. Optical Coherence Tomography Angiography of the Peripapillary Retina in Glaucoma. *JAMA Ophthalmol*. 2015;133:1045–52.
37. Yarmohammadi A, Zangwill LM, Diniz-Filho A, et al. Optical Coherence Tomography Angiography Vessel Density in Healthy, Glaucoma Suspect, and Glaucoma Eyes. *Invest Ophthalmol Vis Sci*. 2016;57:OCT451–9.
38. Rao HL, Pradhan ZS, Weinreb RN, et al. Regional Comparisons of Optical Coherence Tomography Angiography Vessel Density in Primary Open-Angle Glaucoma. *Am J Ophthalmol* 2016;171:75–83.
39. Rao HL, Pradhan ZS, Weinreb RN, et al. A comparison of the diagnostic ability of vessel density and structural measurements of optical coherence tomography in primary open angle glaucoma. *PLoS One*. 2017;12:e0173930.
40. Shin JW, Lee J, Kwon J, et al. Regional vascular density-visual field sensitivity relationship in glaucoma according to disease severity. *Br J Ophthalmol*. 2017;101:1666–72.
41. Artes PH, O’Leary N, Hutchison DM, et al. Properties of the statpac visual field index. *Invest Ophthalmol Vis Sci*. 2011;52(7):4030e8
42. Cho JW, Sung KR, Yun SC, et al. Progression detection in different stages of glaucoma: mean deviation versus visual field index. *Jpn J Ophthalmol*. 2012;56(2):128e33
43. Lee J, Sohn SW and Kee C. Effect of Ginkgo biloba extract on visual field progression in normal tension glaucoma. *J Glaucoma*. 2013;22:780–4.
44. Quaranta L, Riva I and Floriani I. Ginkgo biloba extract improves visual field damage in some patients affected by normal-tension glaucoma. *Invest Ophthalmol Vis Sci*. 2014;55:2417.
45. Le Bars PL, Katz MM, Berman N, et al. A placebo-controlled, double-blind, randomized trial of an extract of Ginkgo biloba for dementia. North American EGB Study Group. *JAMA*. 1997;278:1327–32.