



## Results of Two Fibrinolytics in Treatment of The Early Stage of Empyema

Amr el sayed Tawfek, Mohamed Mamdouh Elsharawy, Mohammed Ismail Ibrahim, Amr Hassan Mansour\*

Cardio-thoracic surgery department, Faculty of Medicine , Zagazig University, Egypt.

### \*Corresponding Author:

Amr ElSayed Tawfek (MD)  
amr.tawfek@zu.edu.eg  
Cardiothoracic surgery  
department, Zagazig  
University, Egypt

Submit Date 2022-08-02 00:29:23

Revise Date 2022-08-27 17:46:57

Accept Date 2022-09-03 18:31:33

### ABSTRACT

**Background:** Management of an early empyema is an important problem in thoracic surgery. As an alternative to surgical treatment empyema is in patients who developed early empyema, intra-pleural fibrinolysis has been used with favorable results. This modality of treatment may reduce known morbidities secondary to surgical procedures and may result in significant medical cost savings. Our study aim is to test the efficacy and safety of tissue plasminogen activator and Streptokinase for management of early empyema.

**Methods:** Our study included 48 patients presented with complicated parapneumonic effusion and early empyema. Patients were divided into two groups each contains 24 patients. First group treated with intra-pleural Alteplase (tissue plasminogen activator) and the second group treated with streptokinase, both were instilled via an intercostal chest tube. Clinical and radiologic (chest radiographs (CXR) and chest computed tomography (CT) data used for evaluation of efficacy of both protocols.

**Results:** Tissue plasminogen activator give excellent results in early empyema, it showed success rate 100%, dramatic improvement in both chest tube drain and pleural thickness with no need for further surgical intervention, Streptokinase showed success rate 83.4% in comparison to TPA.

**Conclusion:** Intrapleural tissue plasminogen activator is safe and more efficient than Streptokinase as a chemical modality in treating patients presented with complicated pleural effusion and early empyema.

**Key words:** Complicated parapneumonic effusion, early empyema, Intra-pleural tissue plasminogen activator; intra-pleural streptokinase.

### INTRODUCTION

Parapneumonic pleural effusion denote to any pleural effusion due to pneumonia or lung abscess involved patients show frank pus, PH<7.2, positive Gram stain or culture. it develop complicated when an invasive procedure is necessary for its resolution or if bacteria can be cultured from the effusion [1] Empyema refers to the presence of pus in the pleural space, about 15-20 % of patients suffering from parapneumonic effusion post pneumonia suffer from empyema [2]. At least 40% of all patients diagnosed will have associated pleural effusion though the smaller number of these will need active interventions [3]. Intrapleural injection of fibrinolytic agents such as streptokinase, urokinase and tissue plasminogen activator (TPA) were recommended as a possible choice for management of complicated parapneumonic effusion and empyema [4] Streptokinase (SK) is a non-enzymatic protein that indirectly activates the fibrinolytic system. SK forms a complex with plasminogen. This complex can act as a protease and cleave other plasminogen molecules, resulting in the formation of plasmin [5]. Tissue plasminogen activator (TPA), also

known as Alteplase, was developed to replace streptokinase and urokinase (UK) Tissue plasminogen activator has an improved ability to bind directly to fibrin compared with the older fibrinolytics [6]. It is the most important physiologic plasminogen activator in the blood. Plasmin is generated when TPA and plasminogen bind to fibrin [7]. Plasmin is in the end breaks down the fibrin threads within the blood clots and surrounding adhesions, thus helps suspension and drainage of early empyema [8], drainage is ineffective in early empyema. Insufficient treatment carries several problems in early empyema [9]. Controversy still exists regarding the approach to management of early empyema. Both aggressive and conservative types of treatment of empyema have been advocated [10]. The aim of the present study was to test the safety and efficacy of tissue plasminogen activator (TPA) and Streptokinase (SK) for management of complicated parapneumonic pleural effusion and early empyema.

### METHODS

Our prospective randomized comparative study included 48 patients collected by simple random

sampling. Written informed consent was obtained from all participants, the study was approved by the research ethical committee of Faculty of Medicine, Zagazig University and King Khaled hospital. The study was done according to The Code of Ethics of the World Medical Association (Declaration of Helsinki) for studies involving humans. all patients were admitted in cardiothoracic surgery department-Zagazig University hospitals-Egypt, and in King Khaled hospital-Najran-Saudia Arabia from January 2020 to May 2022. they were divided into two groups each group contains 24 patients, one fibrinolytic protocol used for each group.

#### **Inclusion criteria:**

Patients age (20-70) years, patients who presented with complicated parapneumonic pleural effusion and early empyema that fail to resolve by simple drainage based on clinical, laboratory and radiological evidence of active lung infection (fever, productive cough with consolidation or loculations on C.T. scan, Despite properly positioned and well-functioning chest tube. All patients had written informed consent before starting fibrinolytic protocol.

#### **Exclusion criteria:**

Patients with long standing empyema, malignant, tuberculous pleural effusion and bronchopleural fistula, Patients had associated head trauma, cerebral haemorrhage or had recent stroke Patients who had major surgery (e.g., abdominal exploration). Patients who suffered from bronchopleural fistula suspected by prolonged air leak, Pregnant or lactating female. patients on oral anticoagulation therapy (e.g., cardiac valve replacement) or injection anticoagulation (heparin/Enoxaparin), Patients on antiplatelet treatment (e.g., Aspirin/clopidogrel in ischemic heart disease, coronary stents). Patients who had hepatic failure or known sensitivity to SK or TPA.

#### **Preoperative measures:**

Before starting fibrinolytic treatment protocols, history and physical examination reviewed for each patient, routine laboratory investigations were done with distinct care to complete blood count and coagulation profile. Radiological investigations included CXR and CT chest.

**Failure:** defined as the need for further intervention (VATS, thoracotomy). **Success:** was defined as improvement in chest radiographs with resolution of previous pleural collection.

#### **Protocols for fibrinolytic agents' administration:**

**Group I (Intrapleural Tissue plasminogen activator protocol):** The protocol was conducted on 24 patients. Tissue plasminogen activator administered as 10 mg diluted in 50 ml of normal saline instilled via the chest tube, then the chest

tube washed by 30 ml normal saline to ensure that all (TPA) delivered inside the pleural cavity.

#### **Group II (Intrapleural streptokinase protocol):**

The protocol was conducted on 24 patients. Streptokinase 250000 units diluted in 50 ml of normal saline instilled via the chest tube, followed by wash of the chest tube by 30 ml normal saline to ensure all streptokinase delivered inside pleural cavity Then, chest tubes of all patients in both groups were clamped to allow drainage. In addition to routine respiratory physiotherapy, patients were asked to move and change their position from the supine to left and right lateral decubitus positions to enhance distribution and drainage. This procedure was repeated every day for up to 6 successive days as required according to improvement of the opacity.

#### **Patients in both groups were evaluated by:**

Daily plain chest radiographs (CXR). In our study, classification of CXR results followed method used in the study done by Brockelsby and associates [11], where size of pleural effusion or collection estimated by the recognized method of counting intercostal spaces (ICS) from costophrenic angle (1 ICS =small- localized collection, 2-3 ICS= medium collection, large collection if  $\geq 4$  ICS). 2- Amount and character of daily chest tube drainage 3- Chest computed tomography (CT) was done after the course of chemical fibrinolysis was completed. Our classification of CT results based on the study done by Moy et al, who developed and validated a simple rule for quantitating pleural effusion size on CT scan with a three-point scale based on the anteroposterior (AP) dimension [12].

#### **STATICAL ANALYSIS**

Data were collected and entered on Microsoft excel sheet. Analysis was done by SPSS version 20.0 software, continuous data were summarized by means and standard deviation where categorical variables were described by number and percent. A two-tailed  $p < 0.05$  was considered statically significant

#### **RESULTS**

##### **Patient's demographics:**

The average age of our patients was  $45 \pm 12$  years in first group and  $48 \pm 13$  years in the second group male patients represented 58.4% (14 patients) in first group and 66.6% (16 patients) in second group without significant difference between both groups, there are multiple observed co morbidities discovered among patients cardiac(2:3)patients, respiratory(1:2)patients, kidney(2:1) patients and liver diseases(3:3) patients respectively in each group without significant difference between both groups (table1), kidney (2:1) patients and liver diseases (3:3) patients respectively in each group

without significant difference **Table (1):** Preoperative characteristics of patients in both groups.

**In Tissue plasminogen activator (TPA) group (I)** marked improvement and nearly complete resolution of early empyema occurred in 4 patients (16.6%) after the first dose of alteplase therapy documented by chest X ray and CT examination. About 6 patients (25%) were similarly improved after the second dose. after 3<sup>rd</sup> other 10 patients (41.6%), 4<sup>th</sup> dose another 2 patients (8.3%) also shown marked improvement so, (22 patients) about 90% of TPA group shows nearly complete resolution of early empyema while the remaining (2 patients) 8.3% show minimal residuals that improve during follow up in outpatient clinic for one month duration with no need of surgical intervention at all. Moreover, Intrapleural instillation of Alteplase noted to be followed initially by significant drainage of serosanguineous fluid that was cleared and decreased rapidly, with dramatic improvement of chest tube drain, Success rate 100% of TPA group.

**In Streptokinase (SK) group (II)** complete improvement of CXR and CT after first dose of streptokinase therapy occurred in 1 patient (4.2%) with almost complete resolution of early empyema. After the second dose 2 patients (8.3%

)were improved and other 4 patients (16.6%) improved also after 3<sup>rd</sup> dose ,about 6 patients( 25% ) show significant improvement after 4<sup>th</sup> dose, after 5<sup>th</sup> dose 2 patients (8.3%) also improved completely and after last 6<sup>th</sup> dose only 1 patient (4.2%) significantly improved, the remaining 8 patients (33.3%) show significant residuals but at the end of follow up at outpatient clinic during one month 4 patients( 16.6%) improved also but 4 patients( 16.6%) need surgical intervention in form of V.A.T.S drainage in three patient and thoracotomy for decortication in the other patient, so, success rate 20 patients (83.4%) of SK group, figure (1).

**Figure (1):** Patients outcomes between TPA and SK groups.

**Complications:**

It was only mild and self-limited: mild pain, transient fever, minor bleeding not need transfusion and mild allergy with no death noted in both groups where bleeding occurred in both groups 1 patient (4.25%) complain of clinically insignificant blood tinged sputum and 1 patient (4.25%) complain of bleeding per nose, both of them controlled spontaneously with conservative treatment and did not need any specific therapy, (table2)

**Table (1): preoperative characteristics of patients in both groups .**

characters	Group 1	Group 2	P value
Age(years)	45±12	48±13	NS
sex			
Male	14 (58. %)	16 (66.6%)	NS
female	10(41.6%)	8 (33.3%)	NS
Morbidity			
Cardiac	2(8.3%)	3(12.5%)	NS
Respiratory			
Renal	1(4.25%)	2(8.3%)	NS
hepatic	2(8.3%)	1 (4.25%)	NS
	3(12.5%)	3 (12.5%)	NS

**Table 2: complications that occurred in both groups.**

Complications	Group 1	Group 2	P value
Pain	1(4.25%)	2(8.3%)	NS
Fever	1(4.25%)	1(4.25%)	NS

Complications	Group 1	Group 2	P value
Bleeding	1(4.25%)	1(4.25%)	NS
Anaphylaxis	0	0	NS
death	0	0	NS

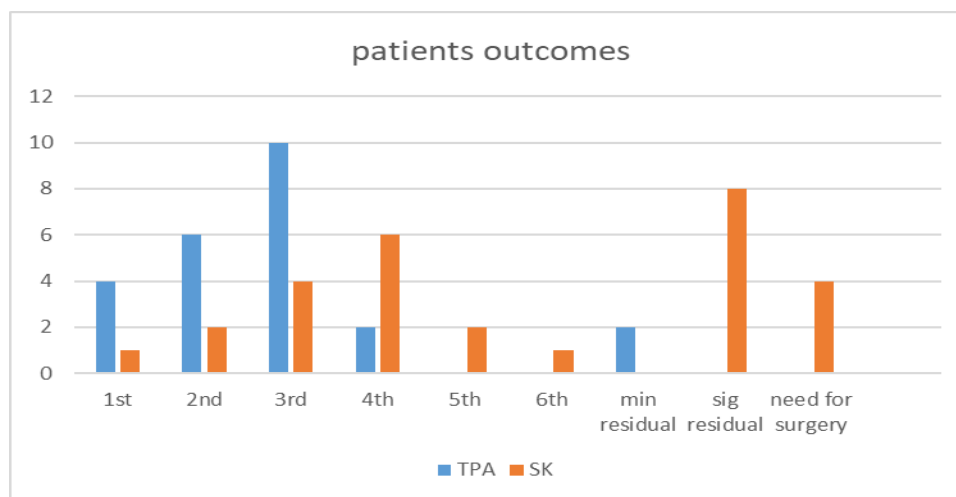


Fig (1) shows patients outcomes.

**DISCUSSION**

The management of complicated pleural effusions is complex and can involve a variety of treatment options ranging from thoracentesis and closed thoracostomy tube placement to intrapleural fibrinolytics and operative techniques such as VATS with drainage and open thoracotomy with decortication [13]. The use of intrapleural fibrinolytics as an adjunct to the management of complicated pleural effusions was introduced in 1949 when Tillet and Sherry used streptokinase and streptodornase for the management of hemothorax and empyema [14].

Afterwards, numerous reports described the use and effectiveness of intra-pleural fibrinolytics in treatment of early empyema. However, most of the literature discusses streptokinase and urokinase therapy despite the more current interest in intrapleural TPA. So, the present study compares the efficacy of tissue plasminogen activator (TPA) versus Streptokinase (SK) in treatment of early empyema. In developing countries like Egypt fibrinolytic therapy have special economic privilege for healthcare system when compared to surgical management wither VATS (which is not always available in many centers) or thoracotomy with its known expenses and risks. The results of our study revealed globally that both modalities of intra-pleural chemical fibrinolysis were safe, successful and useful in the treatment of early empyema. However, comparative results showed

higher success rate of TPA protocol in comparison to SK protocol (in 100% of TPA group and 83.4 % in SK group).as regard streptokinase usage as intrapleural fibrinolytic several studies done some with and another against its usage. Since then, the efficacy and safety of intrapleural streptokinase regarding systemic or local bleeding complications has been well established in the literature [15]. In a prospective study that enrolled 48 patients with loculated pleural effusions (30 empyemas, 14 traumatic hemothorax and 4 malignant effusions), Jerjes-Sanchez et al. reported an overall efficacy rate, of 92%, with a 90% success rate in a subset of patients with traumatic hemothorax. There were no hemorrhagic complications in the study [16]. Inci et al reported a series of 24 patients with traumatic hemothorax who were administered streptokinase (9 patients) and urokinase (15 patients); the efficacy was 91.7%, with no reported complications [17]. A review of nine other trials of intrapleural urokinase [17–19,24] for the management of complicated pleural effusions showed similar efficacy rates and no complications attributable to urokinase administration [18]. Unfortunately the use of intrapleural urokinase was shortened in removed it from the market because of risks of viral transmission, Since TPA were introduced in 1998 as an alternative to urokinase, there have been case reports of intrapleural use [19], and reviews of its use in pediatric patients with parapneumonic effusions and empyemas[20],



intrapleural instillation of streptokinase is safe and effective with Successful improvement occurred in 43 patients (74.14%), partially successful response occurred in 13 patients( 22.4%) and failure occurred in 2 patients (3.45%) The beneficial effect of streptokinase becomes evident between the fourth and seventh day after initiation of treatment[21].

Diacon et al. who recorded 82% success [22]. Taylor et al. recorded 67% success [23]. Sanchez et al. recorded 92% success [16].

Regarding complications, in our study are mild and self-limited: mild pain, transient fever, minor bleeding does not need transfusion and mild allergy with no death this agreed with Omar et al. there was transient chest pain (18.3 %), cough (1.7 %) and fever (3.4 %) detected in our study. No severe allergic reaction, severe bleeding or major adverse side effects [21]. Taylor et al. recorded only one case suffering from mild transient chest pain following streptokinase instillation [23]. Other studies show negative drawbacks of streptokinase.

The intrapleural administration of streptokinase does not improve mortality, the rate of surgery, or the length of the hospital stay among patients with pleural infection, streptokinase did not improve long-term outcomes as it is alone did not produce sufficient clearance of pleural fluid —possibly because infected pleural fluid is viscous, lumpy, and resistant to tube drain Streptokinase does not improve these characteristics [24] it simply breaches the barriers between pockets of pus. Therefore, despite the partial unification of the pleural collection, the fluid may still fail to drain adequately, because it cannot pass down the chest tube [25], there was a considerable systemic antistreptokinase antibody response in group receiving streptokinase such a response may inhibit the efficacy of streptokinase given later for myocardial infraction or venous thromboembolism so patients who received intrapleural streptokinase and later require systemic fibrinolysis should receive a different fibrinolytic agent[26].

On contrary TPA in our study shows excellent safety and potency profile, many study support our results. Walker et al. first reported the apparent benefits of alteplase in a case with a multiloculated pleural effusion as an adjunct to chest tube drainage and antibiotics [27]. Skeete et al. instilled TPA through surgical chest tubes into 42 patients with a variety of pleural conditions, of which 12 were empyemas. They reported accelerated radiological improvement and clinical benefit [28] Levinson and Pennington used TPA for 20 patients with largely multiloculated pleural infections; is highly effective in resolving the

effusion and curing the infection[29] Froudarakis et al. found that intrapleural instillation of TPA at is a well-tolerated and effective treatment in 95% of adult patients with complicated parapneumonic effusion and empyema [30] Gervais et al. 25 patients, with empyema and complicated parapneumonic effusions, were selected for fibrinolysis with incomplete initial pleural fluid drainage. The overall success rate was 86% [31]. Ben-Or et al. have recently used TPA to treat different complex pleural processes with an overall success rate of 86.4%. They reported that one to two doses were the most successful [32]. Intrapleural TPA is an effective therapy in improving drainage of loculated parapneumonic effusions and thoracic empyema not drained with pigtail catheters alone and can prevent surgical intervention, total success rate 84.5% (49/58 patients) Intrapleural TPA is well tolerated with infrequent adverse events [33] Patients that respond will usually do so by the third dose of TPA. Complete response occurred in 102 of 120 patients (85%), partial response in 10 patients (8%), and no response or failed therapy in 8 patients (7%) Fibrinolytics should be considered in treating CPE/ empyema if conventional medical management and tube thoracotomy fails. Patients with chronic empyema or empyema associated with lung abscess should go directly to surgery [34] Patients received one to eight doses of intrapleural TPA through a tube thoracostomy The success rate was 86.4% (102 of 118 patients). Systemic anticoagulation, prothrombin time, partial thromboplastin time, international normalized ratio, and platelet count do not appear to be risk factors for bleeding complications. One or two doses of alteplase appear most successful [32] El Sharawy et al., found that comparative results showed higher success rate of TPA protocol in comparison to SK protocol (in 100% of TPA group and 85% in SK group Intra-pleural fibrinolytic therapy with both Tissue plasminogen activator or Streptokinase were safe and successful in our patients with traumatic clotted hemothorax [35] but, in the MIST II [36]. Rahman et al. trials the intrapleural TPA–DNase therapy significantly improved fluid drainage in patients with pleural infection and reduced the frequency of surgical referral and the duration of the hospital stay. However, the treatment with TPA alone was ineffective [37]. In developing countries like Egypt fibrinolytic therapy have special economic privilege for healthcare system when compared to surgical management wither VATS (which is not always available in many centers) or thoracotomy with its known expenses and risks.

**CONCLUSION**

Intra-pleural fibrinolytic therapy with both Tissue plasminogen activator or Streptokinase were safe and successful in our patients with complicated parapneumonic effusion and early empyema. TPA has better result with dramatic improvement without failure or need for further surgical intervention.

Intra-pleural Tissue plasminogen activator therapy is expensive but simple and effective choice that may be tried before exposing these patients to identified risks of surgical procedures and general anesthesia. Further studies will help more to identify the better other fibrinolytics for management of early empyema.

**Abbreviation:** CPE=complicated parapneumonic, effusion SK= streptokinase, TPA= tissue plasminogen activator, UK = urokinase, VATS=video assisted thoracoscopy.

**Conflict of Interest**

The authors of this manuscript declare no relevant conflicts of interest, and no relationships with any companies, whose products or services may be related to the subject matter of the article.

**Financial Disclosures**

None.

**REFERENCES**

- [1] Shebl E, Paul M. Parapneumonic Pleural Effusions And Empyema Thoracis. *StatPearls*. April 2022. <https://www.ncbi.nlm.nih.gov/books/NBK534297/>. Accessed July 12, 2022.
- [2] Garvia V, Paul M. Empyema. *Brain Imaging with MRI CT An Image Pattern Approach*. 2021;9780521119443:277-278. doi:10.1017/CBO9781139030854.135
- [3] Karkhanis VS, Joshi JM. Pleural effusion: diagnosis, treatment, and management. 2012. doi:10.2147/OAEM.S29942
- [4] Piccolo F, Popowicz N, Wong D, Lee YCG. Intrapleural tissue plasminogen activator and deoxyribonuclease therapy for pleural infection. *J Thorac Dis*. 2015;7(6):999. doi:10.3978/J.ISSN.2072-1439.2015.01.30
- [5] Diwan D, Usmani Z, Sharma M, et al. Thrombolytic Enzymes of Microbial Origin: A Review. *Int J Mol Sci*. 2021;22(19). doi:10.3390/IJMS221910468
- [6] Chou EL, Kabutey NK. Thrombolytic Therapy. *Vasc Surg Princ Pract Fourth Ed*. June 2021:123-132. doi:10.1201/9781315381770
- [7] Jilani TN, Siddiqui AH. Tissue Plasminogen Activator. *StatPearls*. February 2022. <https://www.ncbi.nlm.nih.gov/books/NBK507917/>. Accessed July 12, 2022.
- [8] Wilcock BP, Njaa BL. Special Senses. *Jubb, Kennedy Palmer's Pathol Domest Anim Vol 1*. 2016;1:407. doi:10.1016/B978-0-7020-5317-7.00005-9
- [9] Karanlik H, Kurul S. Hemothorax. *Total Implant Venous Access Devices Manag Mid- Long-Term Clin Setting*. August 2021:115-121. doi:10.1007/978-88-470-2373-4
- [10] Mowery NT, Gunter OL, Collier BR, et al. EAST PRACTICE MANAGEMENT GUIDELINES Practice Management Guidelines for Management of Hemothorax and Occult Pneumothorax STATEMENT OF THE PROBLEM. 2011. doi:10.1097/TA.0b013e31820b5c31
- [11] Brockelsby C, Ahmed M, Gautam M. P1 Pleural effusion size estimation: US, CXR or CT? *Thorax*. 2016;71(Suppl 3):A83.1-A83. doi:10.1136/THORAXJNL-2016-209333.144
- [12] Moy MP, Levsky JM, Berko NS, Godelman A, Jain VR, Haramati LB. A new, simple method for estimating pleural effusion size on CT scans. *Chest*. 2013;143(4):1054-1059. doi:10.1378/CHEST.12-1292
- [13] Williams E, Hanna N, Menard A, et al. Study protocol for DICE trial: Video-assisted thoracoscopic surgery decortication versus interventional radiology guided chest tube insertion for the management of empyema. *Contemp Clin Trials Commun*. 2021;22:100777. doi:10.1016/j.conctc.2021.100777
- [14] Hewidy A, Elshafey M. Medical thoracoscopy versus intrapleural fibrinolytic therapy in complicated parapneumonic effusion and empyema. *Egypt J Chest Dis Tuberc*. 2014;63(4):889-896. doi:10.1016/J.EJCDT.2014.05.004
- [15] Piccolo F, Popowicz N, Wong D, Lee YCG. Intrapleural tissue plasminogen activator and deoxyribonuclease therapy for pleural infection. *J Thorac Dis*. 2015;7(6):999. doi:10.3978/J.ISSN.2072-1439.2015.01.30
- [16] Jerjes-Sánchez C, Ramirez-Rivera A, Elizalde JJ, et al. Intrapleural fibrinolysis with streptokinase as an adjunctive treatment in hemothorax and empyema: A multicenter trial. *Chest*. 1996;109(6):1514-1519. doi:10.1378/ CHEST. 109.6.1514
- [17] Inci I, Özçelik C, Ülkü R, Tuna A, Eren N. Intrapleural fibrinolytic treatment of traumatic clotted hemothorax. *Chest*. 1998;114(1):160-165. doi:10.1378/ CHEST.114.1.160
- [18] Lower dose intrapleural fibrinolysis. doi:10.4046/trd.2020.0018
- [19] Luque D, Id P, Bayeh B, et al. Intrapleural use of urokinase and DNase in pleural infections managed with repeated thoracentesis: A comparative cohort study. 2021. doi:10.1371/journal.pone.0257339
- [20] Hendaus MA, Janahi IA. Parapneumonic effusion in children: An up-to-date review. *Clin Pediatr (Phila)*. 2016;55(1):10-18. doi:10.1177/0009922815589917
- [21] Omar A, Ali MG, Eldegwy M. Intra Pleural Streptokinase in Management of Empyema, Is It Beneficial? *Egypt J Hosp Med*. 2022;86(1):794-797. doi:10.21608/EJHM.2022.216958
- [22] Diacon AH, Theron J, Schuurmans MM, Van De Wal BW, Bolliger CT. Intrapleural Streptokinase for Empyema and Complicated Parapneumonic

- Effusions. doi:10.1164/rccm.200312-1740OC
- [23] Taylor RFH, Rubens B, Pearson MC, Barnes NC, Rubens MB. Intrapleural streptokinase in the management of empyema. *Thorax*. 1994;49:856-859.
- [24] Simpson G, Roomes D, Heron M. Effects of streptokinase and deoxyribonuclease on viscosity of human surgical and empyema pus. *Chest*. 2000;117(6):1728-1733. doi:10.1378/CHEST.117.6.1728
- [25] Davies CWH, Traill ZC, Gleeson F V., Davies RJO. Intrapleural streptokinase in the management of malignant multiloculated pleural effusions. *Chest*. 1999;115(3):729-733. doi:10.1378/CHEST.115.3.729
- [26] Maskell NA, Davies CWH, Nunn AJ, et al. U.K. Controlled Trial of Intrapleural Streptokinase for Pleural Infection. *N Engl J Med*. 2005;352(9):865-874. doi:10.1056/NEJMoa042473
- [27] Walker CA, Shirk MB, Tschampel MM, Visconti JA, Morand BR, Guévremont C. Intrapleural alteplase in a patient with complicated pleural effusion. *Ann Pharmacother*. 2003;37(3):376-379. doi:10.1345/aph.1C248
- [28] Skeete DA, Rutherford EJ, Schlidt SA, Abrams JE, Parker LA, Rich PB. Intrapleural tissue plasminogen activator for complicated pleural effusions. *J Trauma - Inj Infect Crit Care*. 2004;57(6):1178-1183. doi:10.1097/01.TA.0000141879.67441.52
- [29] Wrightson JM, Davies RJO. The approach to the patient with a parapneumonic effusion. *Semin Respir Crit Care Med*. 2010;31(6):706-715. doi:10.1055/S-0030-1269830
- [30] Froudarakis ME, Kouliatsis G, Steiropoulos P, et al. Recombinant tissue plasminogen activator in the treatment of pleural infections in adults. *Respir Med*. 2008;102(12):1694-1700. doi:10.1016/J.RMED.2008.08.012
- [31] Gervais DA, Levis DA, Hahn PF, Uppot RN, Arellano RS, Mueller PR. Adjunctive intrapleural tissue plasminogen activator administered via chest tubes placed with imaging guidance: Effectiveness and risk for hemorrhage. *Radiology*. 2008;246(3):956-963. doi:10.1148/RADIOL.2463070235
- [32] Ben-Or S, Feins RH, Veeramachaneni NK, Haithcock BE. Effectiveness and risks associated with intrapleural alteplase by means of tube thoracostomy. *Ann Thorac Surg*. 2011;91(3):860-864. doi:10.1016/J.ATHORACSUR.2010.10.082
- [33] Refaat A, Affara N, Muhsen T, Salahuddin M. Intrapleural Tenecteplase Therapy in Treatment of Loculated Parapneumonic Pleural Effusions and Empyema. *Egypt J Chest Dis Tuberc*. 2014;63(4):913-921. doi:10.1016/j.ejcdt.2014.07.002
- [34] Thommi G, Nair CK, Aronow WS, Shehan C, Meyers P, McLeay M. Efficacy and safety of intrapleural instillation of Alteplase in the management of complicated pleural effusion or empyema. *Am J Ther*. 2007;14(4):341-345. doi:10.1097/01.MJT.0000208275.88120.D1
- [35] Abdrabo MM, Elsharawy M, Elnahal NH. Outcomes of two different chemical modalities in management of post traumatic clotted hemothorax. *Zagazig Univ Med J*. 2021;0(0):0-0. doi:10.21608/ZUMJ.2021.81993.2269
- [36] Koppurapu V, Meena N. A review of the management of complex para-pneumonic effusion in adults. *J Thorac Dis*. 2017;9(7):2135-2141. doi:10.21037/jtd.2017.06.21
- [37] Rahman NM, Maskell NA, West A, et al. Intrapleural Use of Tissue Plasminogen Activator and DNase in Pleural Infection. *N Engl J Med*. 2011;365(6):518-526. doi:10.1056/NEJMoa1012740

**To Cite:**

tawfek, A., Elsharawy, M., Ibrahim, M., Mansour, A. Results of two fibrinolytics in treatment of the early stage of empyema. *Zagazig University Medical Journal*, 2023; (120-126): -. doi: 10.21608/zumj.2022.153200.2611