

Laparoscopic Suture versus Ventral Mesh Rectopexy for the Surgical Treatment of Internal Rectal Prolapse

Mohamed I. Abuelnasr, Hussein Elgohary, Abdirahman A. Nuh, Mohamed A. Elbegawy

Department of surgery, benha faculty of medicine, Benha University, Egypt.

Correspondence to:
Mohamed I. Abuelnasr
Department of surgery, faculty of medicine, Benha University, Egypt.

Email:

drabuelnasr@gmail.com

Received: 21 June 2022

Accepted: 10 September 2022

Abstract:

Background; Over the last decades, numerous procedures have been proposed to treat rectal prolapse (RP) often with contrasting results, underlying the continuing search for the ideal surgical treatment. This should correct RP and/or rectal intussusception (RI) and derived symptoms. This study aims to evaluate and compare the functional outcome after laparoscopic Ventral Mesh Rectopexy and Laparoscopic Suture Rectopexy for the surgical Treatment of Internal Rectal Prolapse. **Subjects and methods;** This was prospective study, carried out in General Surgery Department of Benha University Hospital, on 30 patients with internal rectal prolapse who were randomly divided into 2 groups: (Group A): 15 patients who were proposed to do Laparoscopic Ventral Mesh Rectopexy and (Group B): 15 patients who were proposed to do Laparoscopic Suture Rectopexy. **Results;** Ventral Mesh Rectopexy operation time was highly significantly longer than Laparoscopic Suture. There was no significant difference between the two groups regarding intra-operative complications except one case of bleeding in LSR group. **Conclusion;** Both Laparoscopic Mesh Rectopexy and Suture Rectopexy are feasible and reliable methods for the treatment of internal rectal prolapse associated with low recurrence rate, improvement of ODS symptoms and better anorectal function.

Keyword: Rectal prolapse; Rectopexy; Suture rectopexy; Ventral rectopexy

Introduction

Prolapse of the rectum through the anal canal is referred to as rectal prolapse. Anatomical abnormalities in patients with rectal prolapse include a deepening of the Douglas pouch, levator ani diastasis, an overly mobile mesorectum and patulous anus. Most cases occur between the fourth and seventh decades of life in adults, however it may happen at any time in life. [1].

When it comes to treating adult patients, the only real option is surgery, however, there is some debate regarding the best procedure to use. Anorectal function should be improved and postoperative functional sequelae avoided after surgery for rectal prolapse^[2].

While rectal prolapse is a condition that affects both men and women, certain studies have shown that SR has a superior clinical result in males. Occult sphincter deficiencies in women may be the cause of this since regular endoanal ultrasonography was not routinely used in the early years of prolapse surgery, making it difficult to discover these flaws before surgery^[3].

Ventral Mesh Rectopexy by laparoscopy has a low morbidity and recurrence rate but

is technically difficult and takes a long time to master, necessitating further education and training to attain the professional level required. [4].

This study aims to evaluate and compare the functional outcome after laparoscopic Ventral Mesh Rectopexy and Laparoscopic Suture Rectopexy for the surgical Treatment of Internal Rectal Prolapse as regard to post-operative length stay of hospital, improvement of obstructed defecation and recurrence.

Patients and methods

This prospective study was conducted in General Surgery Department of Benha University Hospital after an approval from the research ethics committee in Benha Faculty of Medicine (MS 9-3-2021). All patients signed informed consents that they were involved in this study.

A total of 30 patients with a diagnosed internal rectal prolapse with ODS not responding to constitutional and medical measures, were recruited to our study with post-operative follow up plan for 12 months starting from first Jan. 2020 to first Jan. 2022.

Study population (Study subjects): adult male and female populations of Egypt 15-60 years old, who were attending General Surgery Department of Benha University Hospital for treatment of symptomatic internal rectal prolapse.

Symptomatic patients with IRP with or without anterior rectocele not responding to conservative and medical measures were included in the study after full history, clinical and radiological examination.

Patients with Complete rectal prolapse, multiple organ pelvic prolapse, recurrent cases, patients with past history or radiotherapy and patient with rectal and colonic inertia- were excluded from the study.

Our patients are grouped randomly into two groups:

Group A with average score of ODS 21.7\24, were 15 patients who were proposed to do Laparoscopic Ventral Mesh Rectopexy. Group B with average score of ODS 21.4\24, were 15 patients who were proposed to do Laparoscopic Suture Rectopexy.

Proposed intervention: Laparoscopic Ventral Mesh Rectopexy and Suture Rectopexy.

Data collection methods

1. Full history and assessment of obstructed defecation by modified longo score in which a lifestyle change parameter to seven symptoms based Parameters. ⁽⁵⁾

2. Clinical assessment.

- When the patient is requested to bear down, the complete thickness of the rectal wall prolapse and its concentric folds may be clearly observed.
- Per rectum examination, to assess the integrity of anal sphincter, excluding presence of masses in anal canal and lower rectum and feeling the internal rectal prolapse while the patients bear down.
- Per vaginal examination during rest and during straining, anterior and posterior vaginal walls were observed for cystocele or rectocele.

3. Anorectal manometry was done preoperative and postoperative at 6 month and 12 month using Solar GI HRAM MMS with 24- channel water perfused catheter with latex balloon- to evaluate rectal sensations, anal sphincter pressures and for exclusion of anismus.

4. Imaging

All patients were subjected to MR defecography.

5. Colonoscopy

Done for all patients to exclude any proximal lesions and for biopsy from the rectal ulcer to exclude malignancy.

6. Routine preoperative laboratory tests.

Preparation and position of patients in the two groups

Each patient underwent 2 rectal enemas in the night before operation and was given 1gm ceftriaxone and 500 mg metronidazole with induction of anesthesia.

A modified lithotomy posture was used to get access to the abdomen and perineum while keeping both arms close to the body. The thighs were parted slightly and flexed upwards. The surgeon, helper, and cameraman were positioned on each side of the patient, with the cameraman positioned next to them.

Laparoscopic Suture Rectopexy technique

After urinary catheterization, pneumoperitoneum was created by using a

Veress needle through umbilical stab incision. Then 10 mm visiport trocar (camera port) inserted through umbilical incision and a 30-degree telescope inserted through this port. Then 2nd port 5 mm (functioned as the RT hand) inserted 2 fingers medial to anterior superior iliac spine. The 3rd port 5mm (functioned as the left hand) inserted at the level of umbilicus at RT mid clavicular line. The 4th port 5mm (for the assistant) below level of umbilicus at Lt mid clavicular line We begin by formal exploration of the abdominal cavity with the patient in Trendelenburg position (30 degrees). In females, the uterus was retracted to the abdominal wall by 2/0 prolene sutures with straight needle for better anterior dissection of the rectum. Then the assistant from the left side trocar retract the sigmoid colon out of the pelvis and to the left side. Then we begin with Suture Rectopexy by inspection of the ureter of pelvic wall and lateral dissection by incision of peritoneum over sacral promontory then we start posterior dissection of the rectum through the loose areolar tissue between the mesorectum and the presacral plexus of veins. The presacral nerves were identified and preserved during the course of the

dissection (**Fig 1**). Then anterior dissection was preceded until reaching pelvic floor muscles. Then rectum retracted cranially to detect the optimal point for suture fixation. Then examination per rectum was done before taking sutures to ensure there is no prolapse at this point of fixation.

The seromuscular layer of posterior wall of the rectum was then sutured to the presacral fascia on both sides using at least two interrupted sutures by prolene 2/0 sutures (**Fig.2**). Then we suture the lateral peritoneum to the rectum at new higher point for more suspension to the rectum and for prevention of adhesions by continuous sutures using pds 2/0.

Laparoscopic Ventral Mesh Rectopex

As with suture rectopexy, the patient and surgeons are in the same position.

To the left and anteriorly, the upper rectum was dragged up. This was followed by cautiously incising the peritoneum immediately above the sacral promontory and then anteriorly along the right outside edge of the mesorectum until reaching Douglas pouch. Identifying and preserving the correct hypogastric nerve and ureter is critical.

As far inferiorly as feasible, to the level of the pelvic floor muscles and laterally to the pelvic side walls was reached after the anterior division of the rectovaginal septum. Polypropylene mesh 15*4 cm was inserted into the abdomen and attached to the anterior portion of the rectum with four interrupted sutures after the anterior space had been mobilized (2/0 PDS) (**Fig. 3**). After a digital rectal examination, the mesh was tacked and anchored to the sacral promontory by two tacks (**Fig.4**) with continuous PDS sutures, the peritoneum was then closed over the mesh.

Post-operative

To be nothing by mouth (NPO) until flatus passed, then on fluids with continuous follow-up and early post-operative assessment of the patient's symptoms as; obstruction defecation, constipation, and recurrence of prolapse- were evaluated, inquired about, and recorded short-term improvement in symptoms such as; obstruction defecation, constipation, and recurrence of prolapse during the patient's stay in the hospital.

Follow up

The Follow up was done in outpatient clinic one week after operation, then every month for 12 month by senior surgeon. Patients

reassessed after 6 months and after 12 months by anorectal manometry and modified longo score

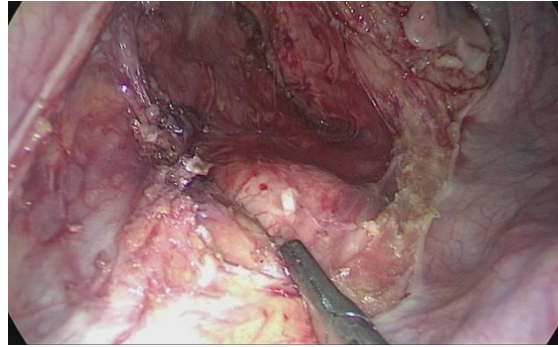


Fig (1): Preservation of presacral nerves during posterior dissection

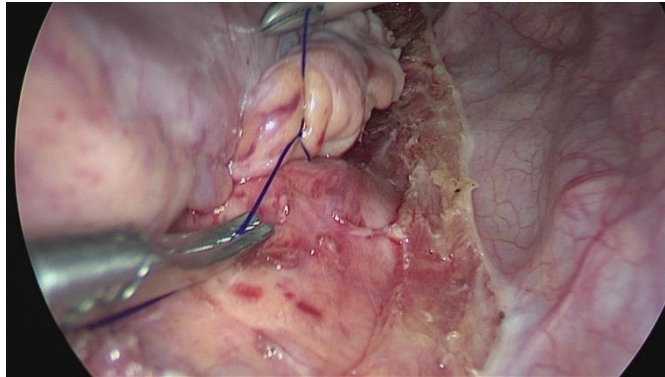


Fig (2): suturing posterior wall of rectum to presacral fascia

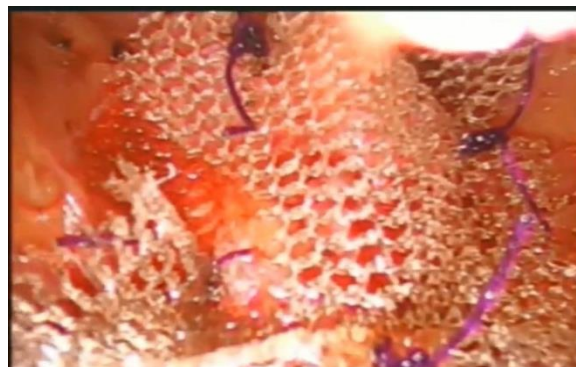

Fig. 3 suturing the distal end of mesh to anterior wall of rectum by interrupted suture

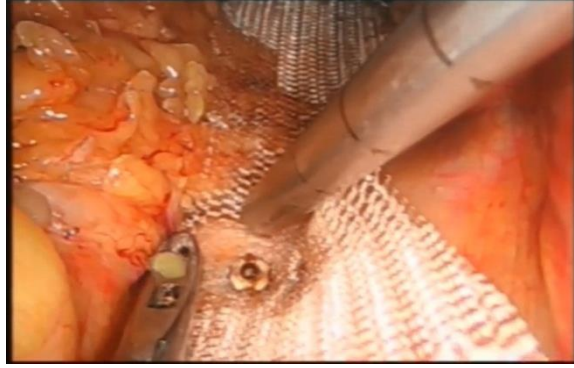

Fig. 4 Tacking mesh to sacral promontory using tacker

Statistical Analysis

Statistical analysis was performed with the Statistical Package for the Social Sciences version 20.0 (SPSS Inc., Chicago, IL, US). Kolmogorov–Smirnov test was used to analyze the distribution pattern of the variables. Normally distributed numerical variables were presented as mean \pm standard deviation, and non-normally distributed variables as median (interquartile 25 – 75). Categorical variables were presented as the number (percentage). Group means of the continuous variables were compared with repeated measures ANOVA, or Friedman test, where appropriate. Categorical variables were compared with Cochran Q test or McNemar's test, where appropriate. A p value of <0.05 was considered statistically significant with a confidence interval of 95%.

Results

There was no significant difference between the two groups regarding basal characteristics (Table 1).

There was no statistical difference between the two groups regarding hospital stay period or time from the operation to flatus pass (Table 2).

There was no statistical difference between the two groups assessments in the 6th and 12th month after the operation regarding Mean Resting anal Pressure. However, there was high significant decrease in first rectal sensation, first Urge and Intense Urge. While high significant increase in mean squeeze pressure in both groups in 6th and 12th month postoperative (Table 3).

There was high significant decrease in modified Longo score and need of laxative dependence pre-operative with 6 and 12 months post-operative (Table 4).

Table (1): Basal Characteristics of included patients.

	LVMR (N=15)	LS (N=15)	P value
Age (Years)	42.3 (11.6)	44.4 (11.3)	>0.05 ¹
Sex			>0.05 ²
Male	5 (33.63%)	6 (40%)	
Female	10 (66.67)	9 (60%)	
BMI (Kg/m²)	23.5 (2.3)	24.3 (2.5)	>0.05 ¹
Marital Status			>0.05 ²
Single	6 (40%)	5 (33.33)	
Married	9 (60%)	10 (66.67)	
Residence			
Urban	7 (46.67)	6 (40%)	
Rural	8 (53.33)	9 (60%)	
Smoking	5 (33.33)	6 (40%)	>0.05 ²
Previous Surgery			
Colonic or rectal	0	0	
Appendectomy	6 (40%)	7 (46.67)	
Upper abdominal	1 (6.67%)	2 (13.33)	
Other	1 (6.67)	1 (6.67)	
Symptoms duration	1.3 (0.2)	1.25 (0.15)	>0.05 ¹

1: T-test | 2: Chi square

P > 0.05 No statistical Difference

P < 0.05 Statistical Difference

P < 0.001 High Statistical Difference

BMI: Body Mass Index

LVMR:laparoscopic ventral mesh rectopexy

LS: laparoscopic suture rectopexy

Table (2): operative and post-operative data of studied cases.

	LVMR (15)	LS (15)	P value
Mean operative time	120 M.	100 M	<0.001
Intraoperative bleeding	0	1(6.66%)	
Duration of Hospital Stay (Day)	3.0 (1.0)	2.9 (1.2)	>0.05 ¹
Pass of flatus (Hours)	20.3 (2.4)	19.6 (3.1)	>0.05 ¹
Mortality	0	0	-
Recurrence	1(6.66%)	1(6.66%)	>0.05 ¹

1: T-test

P > 0.05 No statistical Difference

P < 0.05 Statistical Difference

P < 0.001 High Statistical Difference

LVMR: laparoscopic ventral mesh rectopexy

LS: laparoscopic suture rectopexy

Table (3): Comparison between both studied groups regarding Assessment results.

Items	6 Months post Operative		P. Value	12 Months post Operative		P value
	LVMR (15)	LS (15)		LVMR (15)	LS (15)	
Mean Resting anal Pressure (mmHg)	33±2.2	33±2.3	>0.05 ¹	33±2.4	33±2.5	>0.05 ¹
Mean Squeeze anal Pressure (mmHg)	150±7.5	140±7	<0.05 ¹	155±7.75	145±7.25	<0.05 ¹
First sensation (mmHg)	50±2.5	30±1.5	<0.0001 ¹	55±2.75	35±1.75	<0.0001 ¹
First Urge (mmHg)	120±6	80±4	<0.0001 ¹	100±5	75±3.75	<0.0001 ¹
Intense Urge def. (mmHg)	230±11.5	200±10	<0.0001 ¹	220±11	190±9.5	<0.0001 ¹

1: T-test | 2: Chi square
P > 0.05 No statistical Difference
P < 0.05 Statistical Difference
P < 0.001 High Statistical Difference

LVMR: laparoscopic ventral mesh rectopexy
LS: laparoscopic suture rectopexy

Table (4): Comparison between both groups regarding Assessment results.

Items	6 Months post Operative		P. Value	12 Months post Operative		P value
	LVMR (15)	LS (15)		LVMR (15)	LS (15)	
Modified Longo score	12±0.6	10±0.5	<0.0001 ¹	10±0.5	8±0.4	<0.0001 ¹
Laxative dependence	5 (33.33%)	3 (20%)	<0.05 ²	3 (20%)	2 (13.33%)	<0.05 ²

LVMR: laparoscopic ventral mesh rectopexy
LS: laparoscopic suture rectopexy

Discussion

Controlling the prolapse while also restoring continence and preventing constipation or hindered evacuation should be the goals of treating rectal prolapse. As a result of the many treatment alternatives

and a lack of precise criteria, the optimum treatment options must be adapted to the individual needs of each patient and surgeon ^[6]. Contrary to popular belief, randomized studies examining the relative

merits of numerous abdominal and perineal operations have come up empty-handed [6, 7].

Laparoscopic VMR was shown to be safe and successful in the treatment of full-thickness external rectal prolapse in a research published in 2019 [8], with limited recurrence and low complication rates. Despite this, laparoscopic VMR is the current gold standard for treating rectal prolapse in European countries because it requires special skills and a highly trained surgeon who can perform a complete ventral dissection of the rectovaginal septum (rectovesical in males) down to the pelvic floor and take sutures within the narrow pelvic space [9]. Constipation may increase post-operatively as a consequence of problems connected to mesh, including rectal stricture and discomfort. Autonomic dysfunction may also develop from pelvic nerve damage during the rectal dissection that may cause severe constipation [10].

Laparoscopic Suture Rectopexy may be regarded as an ideal laparoscopic procedure for rectal prolapse, it is safe procedure with low morbidity and mortality with recurrence rate less than 10%. Suture Rectopexy not only treats rectal prolapse but also improves both

constipation and continence in the majority of patients. Furthermore, there are no mesh-related problems [11].

For the surgical treatment of internal rectal prolapse, this research compares the outcomes and effectiveness of Laparoscopic Suture Rectopexy against Laparoscopic Ventral Mesh Rectopexy in 30 patients with internal rectal prolapse over a short time period of 6 months after surgeries.

In this study, varying degree of obstructed defecation symptoms was observed in both groups, obstructed defecation symptoms assessed preoperative by modified longo score with no statistical differences between two groups, p value was <0.0001. Postoperative, Obstructed defecation symptoms significantly improved post-operatively in both groups, however, 3 patients (20%) in LVR group and 2 patients (13.3%) in LSR group still dependable on laxatives postoperative. Need of laxatives may be due to slow colonic transit time in some patients or presence of dolichocolon, so we recommend colonic transit times for all patients before surgery for better evaluation.

Regarding anorectal functions, mean resting pressure show no statistical differences in both groups and this due to the fact that internal anal sphincter being autonomic muscle while there is significant increase in mean squeeze pressure in the two groups and this may be due to avoiding muscle fatigue related to frequent attempt to evacuate and this similar in studies after open rectopexy (12,13,14) and also observed in a study in which laparoscopic suture rectopexy was done (15). Although other studies have shown that the surgical procedure did not affect postoperative sphincter function (16, 17).

Postoperative improvement in all rectal sensations was seen in both groups, but LSR group improvement was significantly greater than LVR group improvement, which is consistent with a study in which decreased rectal capacity after suture rectopexy was noticed leading to improvement in postoperative rectal sensation (18).

A look at the frequency of recurrence two occurrences of recurrence were found throughout the follow-up period; one for each group, which is comparable to a research in which 15% of patients

had recurrences (19). While in another study done, recurrence rate reach 8.2% after LVR. [20] While in Long-term studies have shown that recurrence rates after rectal prolapse repair increase over the years [21].

Duration of surgery is considered an important parameter to gauge the advantages of an operation. In this study, the mean duration of Suture Rectopexy was 100 minutes and 120 min for Mesh Rectopexy with P value of < 0.05, which is statistically significant. This compares well with a study in which the mean duration of LSR was 100.8 ± 12.4 and as regard LVR was 120 ± 10.8 min [22]. The longer duration of surgery in Mesh Rectopexy due to extra time related to introducing the mesh, adjusting it and taking sutures in a very narrow space.

No significant intra-operative complication was found in both groups except case of bleeding was found in LSR group. The bleeding was found due to injury of pre-sacral veins and was controlled using bipolar diathermy. While in LVR, our fear related to the possibility of causing injury to rectum during anterior dissection with no need for posterior dissection.

Conclusion

Recurrence is rare, ODS symptoms improve, and anorectal function improves with Laparoscopic Mesh Rectopexy as well as Suture Rectopexy. Both procedures are safe and effective for the treatment of

internal rectal prolapse. If you're going to do laparoscopic VMR, you're going to require a really skilled surgeon who can dissect all the way from the rectovaginal septum down to the pelvic floor and remove sutures in a very confined area.

References

- 1- M.L.Corman, Rectal prolapse, solitary rectal ulcer, syndrome of the descending perineum and rectocele. In: Colon and rectal.vol.50,pp. 499-554,2005.
- 2- H.Abcarian, Prolapse and proclentia. In:Surgery of the alimentary tract.,vol.25(8), pp.331–48,1991
- 3- T.A.Cook and N.Mortensen, Prolapse of the rectum. In: Oxford textbook of surgery, vol.30, pp.1083-88,2000
- 4- Brooke Gurland and Massarat Zutshi Rectal prolapse The ASCRS textbook of colon and rectal surgery, 3rd edn vol. 60,pp.1077–1089,2016
- 5- Sharma, S., & Agarwal, B. B. (2012). Scoring systems in evaluation of constipation and obstructed defecation syndrome (ODS). JIMSA, 25(1), 57-9.
- 6- Emile SH, Elbanna H, Youssef M, Thabet W, Omar W, Elshobaky A et al., (2017) Laparoscopic Ventral mesh rectopexy vs Delorme's operation in the management of the complete rectal prolapse, a prospective randomized study. Colorectal Dis, vol.19(1), pp.50–57 7,2012.
- 7- Senapati, A., Gray, R. G., Middleton, L. J., Harding, J., Hills, R. K., Armitage, N. C. M., ... & PROSPER Collaborative Group. (2013). PROSPER: a randomised comparison of surgical treatments for rectal prolapse. Colorectal Disease, 15(7), 858-868.
- 8- Emile SH, Elfeki H, Shalaby M, Sakr A, Sileri P, Wexner SD (2019) Outcome of laparoscopic ventral mesh rectopexy for fullthickness external rectal prolapse: a systematic review, metaanalysis, and meta-regression analysis of the predictors for recurrence. Surg Endosc 33(8):2444–2455
- 9- Brooke Gurland and Massarat Zutshi (2016) Rectal prolapse The ASCRS textbook of colon and rectal surgery, 3rd edn vol. 60 :1077–1089
- 10- Yoon S-G (2011) Rectal prolapse: review according to the personal experience. J Korean Soc Coloproctol 27(3):107–113
- 11- Tou, S., Brown, S. R., Malik, A. I., & Nelson, R. L. (2008). Surgery for complete rectal prolapse in adults. Cochrane Database of Systematic Reviews, (4).
- 12- Zittel, T. T., Manncke, K., Haug, S., Schäfer, J. F., Kreis, M. E., Becker, H. D. et.al (2000). Functional results after laparoscopic rectopexy for rectal prolapse. Journal of gastrointestinal surgery, 4(6), 632-641.
- 13- Farouk R, Duthie GS, Bartolo DCC, MacGregor AB. Restoration of continence following rectopexy for rectal prolapse and recovery of the internal anal sphincter electromyogram. BrJ Surg 1992; 79:439-440.
- 14- Athanasiadis S, Heiligers J, Kuprian A, HeumiJller L. Chirurgische Therapie des Rektumprolapses mittels Rectopexie und Resektion. Chirurg 1995; 66:27-33.
- 15- Hyun, K., Yang, S. J., Lim, K. Y., Lee, J. K., & Yoon, S. G. (2018). Laparoscopic posterolateral rectopexy for the treatment of patients with a full thickness rectal prolapse: Experience with 63 patients and short-term outcomes. Annals of coloproctology, 34(3), 119.

- 16- Birnbaum EH, Stamm L, Rafferty JF, Fry RD, Kodner IJ, Fleshman JW. Pudendal nerve terminal motor latency influences surgical outcome in treatment of rectal prolapse. *Dis Colon Rectum* 1996; 39:1215-1221.
- 17- Yoshioka, K., Hyland, G., & Keighley, M. R. B. (1989). Anorectal function after abdominal rectopexy: parameters of predictive value in identifying return of continence. *Journal of British Surgery*, 76(1), 64-68.
- 18- Speakman, C. T. M., Madden, M. V., Nicholls, R. J., & Kamm, M. A. (1991). Lateral ligament division during rectopexy causes constipation but prevents recurrence: results of a prospective randomized study. *British Journal of Surgery*, 78(12), 1431-1433.
- 19- Fargo MV and Latimer KM., (2012): Evaluation and management of common anorectal conditions. *Am Fam Physician*; 85(6):624-630.
- 20- Consten, E. C. J., van Iersel, J. J., Verheijen, P. M., et al (2015). Long-term Outcome After Laparoscopic Ventral Mesh Rectopexy. *Annals of Surgery*, 262(5), 742–748.
- 21- Chun SW, Pikarsky AJ and You SY., (2004): Perineal rectosigmoidectomy for rectal prolapse: role of levatorplasty. *Tech Coloproctol*; 8:3–9
- 22- Sahoo, M. R., Thimmegowda, A. K., & Gowda, M. S. (2014). A single centre comparative study of laparoscopic mesh rectopexy versus suture rectopexy. *Journal of Minimal Access Surgery*, 10(1), 18

To cite this article: Mohamed I. Abuelnasr, Hussein Elgohary, Abdirahman A. Nuh, Mohamed A. Elbegawy. Laparoscopic Suture versus Ventral Mesh Rectopexy for the Surgical Treatment of Internal Rectal Prolapse. *BMFJ* 2023;40 (surgical issue):211-223.