

Surgical Outcomes of Intradural Extramedullary Spinal Tumors Excision Using Intraoperative Neurophysiological Monitoring

Mohamed A. Samir, Adel S. Ismail, Ahmed Basher Mohamed, Ahmed A. Morsy

Department of Neurosurgery, Faculty of Medicine, Zagazig University, Zagazig, Egypt

*Corresponding author: Ahmed Basher Mohamed Madi Abdulwahid, Mobile: (+20) 1090006152,

E-mail: ahmedabdulwahed89@gmail.com

ABSTRACT

Background: Resection significantly improves the clinical symptoms and functional outcomes of patients with intradural extramedullary tumors. However, patient quality of life following resection has not been adequately investigated.

Objective: The purpose of our study was to improving outcomes of patients with intradural extramedullary spinal tumors.

Patients and methods: A prospective study of 20 cases with intradural extramedullary spinal tumors treated by using intraoperative neurophysiological monitoring (IOM) in Neurosurgery department, Zagazig University Hospitals, Egypt, from March 2021 to February 2022. All patients were subjected to complete clinical examination according to medical research council scale (MRC) and modified McCormick scale (MMS) and MRI Imaging.

Results: This study showed that 90% of patients had total extent of resection with only 10% of patients had immediate neurological deficit. The intraoperative neurophysiological recovery monitoring to predict immediate neurological deficit had 66.7% sensitivity and 94.12% specificity with 90% accuracy. While intraoperative neurophysiological recovery monitoring to predict neurological deficit at 3 months had 100% sensitivity and 89.47 % specificity with 90% accuracy. **Conclusion:** A reliable prediction of clinical improvement could be made based on pre-operative clinical status. The use of intraoperative neurophysiological monitoring leads to better neurological outcomes at discharge and follow-up.

Keywords: Intradural extra medullary, Intraoperative neurophysiological monitoring, Functional outcome, Oncology.

INTRODUCTION

Intradural extramedullary (IDEM) tumors are generally benign neoplasms arising in the spinal canal, accounting for about two thirds of primary spinal tumors and 15% of tumors affecting the Central Nervous System⁽¹⁾. Owing to their relative rarity, no specific treatment guidelines are currently available, although radical excision surgery is considered to be the treatment choice. The anatomical location of these tumors and the limited space for maneuvering pose a considerable challenge for surgeons, as the aim is to achieve complete surgical resection good functional outcome and preserving spinal stability⁽²⁾. Technical advances in imaging, neuromonitoring, and minimally invasive approaches have been developed for surgery of intradural tumors, aiming to reduce complications and improve functional outcomes⁽³⁾.

The real clinical benefits of these new concepts for the treatment of extramedullary lesions remain a matter of debate in the literature. Intraoperative neurophysiological monitoring (IONM) could be considered a valid tool to detect during the procedure the occurrence of a neurological injury, then being able - potentially - to suggest both corrective measures to surgeons and to predict clinical outcomes in a short and long term follow-up⁽⁴⁾. However, the heterogeneity of available studies in terms of methods and monitoring modalities have often made questionable any conclusion about the therapeutic role of IONM⁽⁵⁾.

This study was aimed to improving outcomes of patients with intradural extramedullary spinal tumors.

PATIENTS AND METHODS

This prospective study included a total of 20 patients for evaluation of the surgical outcome using intraoperative neurophysiological monitoring, attending at Department of Neurosurgery, Zagazig University Hospitals. This study was conducted between March 2021 to February 2022. Patients were 8 (40%) males and 12 (60%) females.

Inclusion criteria: Patients of all age groups with radiologically confirmed intradural extramedullary (IDEM) spinal tumor. Preoperative motor power grade III or more according to medical research council (MRC) grading system. Fit for surgery with stable cardiopulmonary and good general condition. Patient is accepting and understanding the technique.

Exclusion criteria: Patients with radiologically confirmed other types of spinal tumors rather than intradural extramedullary spinal tumors or proved intraoperative not to be intradural extramedullary spinal tumors. Patients with recurrent Intradural spinal tumors. Severe preoperative motor deficit (motor power < grade III). Patients who were not candidate for surgical treatment. Presence of Contraindication to trans cranial electric stimulation.

Preoperative investigations:

All patients were subjected to Demographic data taking, complete clinical examination, laboratory investigations included complete blood picture (CBC), bleeding profile (PT, PTT, and INR), Liver function

tests (SGOT, SGPT, and Albumin), Blood urea and creatinine, random blood glucose, and viral markers.

Pre-operative imaging evaluation include MRI spine with contrast is the imaging method of choice in the pre therapeutical evaluation. Tumor location on vertebral column (craniocervical, cervical, dorsal, thoracolumbar, or lumbar). Tumor Size. Tumor Characterization well or ill-defined edges, solid or cystic or mixed, pattern of enhancement and presence of calcification.

CT scan might be used for detection of calcification to evaluate spine associated deformity or instability, evaluation of spinal canal and neural foramen enlargement in cases of extradural extension. CT angiography provided relevant information for cervical dumbbell shaped neurofibromas that develop in close proximity to the vertebral artery.

Surgical Technique:

General anesthesia was managed taking into account the requirements of intraoperative neurophysiologic monitoring. The surgical procedure was performed while the IONM were recorded. Short acting muscle relaxants were given for intubation and during muscle dissection. The patient was placed on chest rolls with the knees slightly bent. Pressure points were padded appropriately. Freeing the abdomen and thorax from pressure. Intraoperative fluoroscopy by the C-arm was used to confirm the location of the pathology and to plan the incision. MEP and SSEP modalities were used for monitoring motor and sensory tracts. Neurofibroma or Schwannoma, Filum terminal lesions, and lumbosacral lesions EMG was added to our protocol for monitoring the affected nerve roots through the supplying muscles.

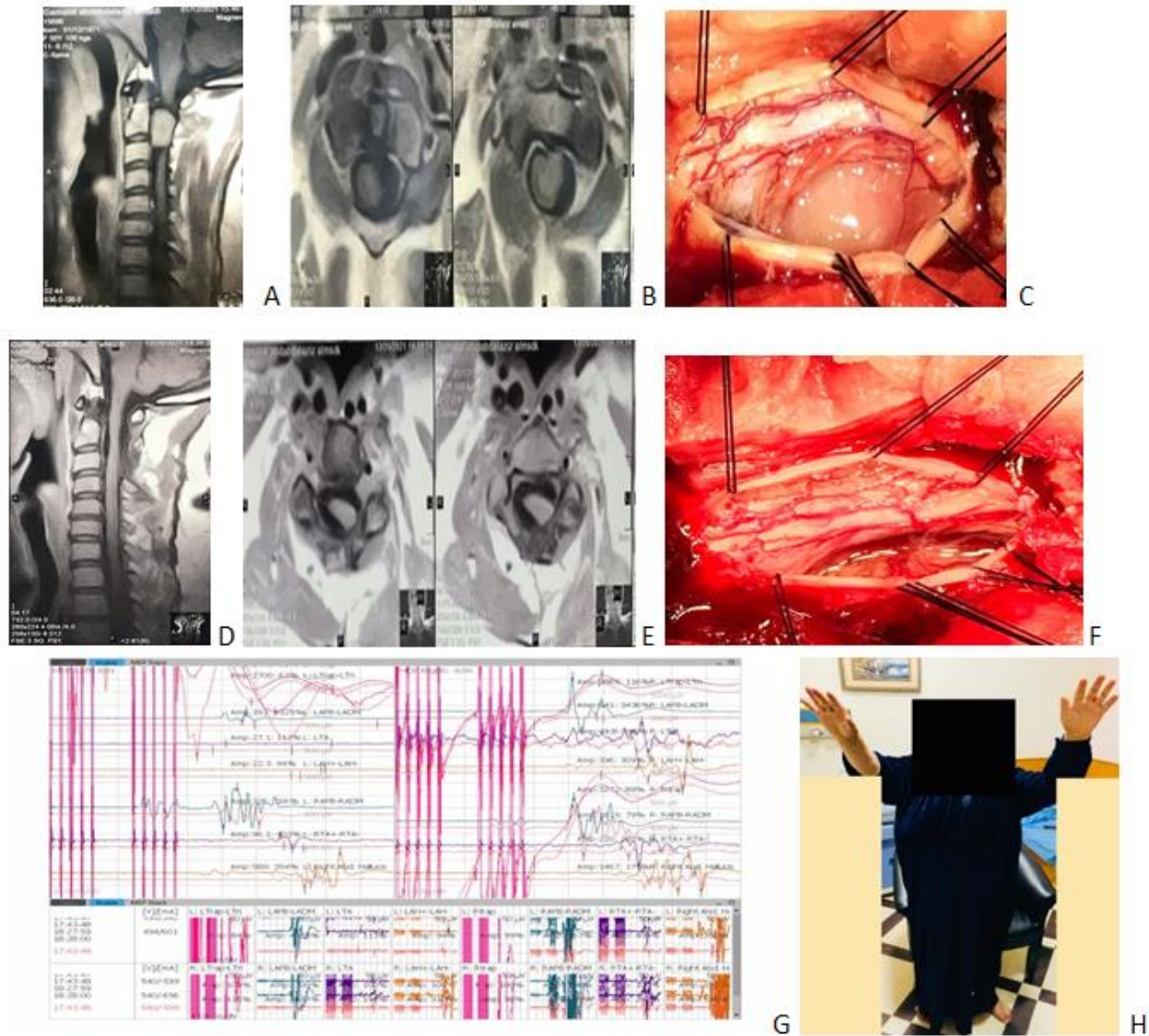


Figure 1): (A, B) sagittal and axial MRI of cervical spine with contrast shows well defined homogeneously enhanced lesion AT the level of cervical C2,3 located anterolaterally at right side pushing the cord posteriorly and to the left, (C, F) shows intraoperative durotomy and tumor before and after gross total resection, (G) intraoperative neurophysiological monitoring shows improvement of motor evoked potential (MEP) waves after resection of tumer, (D,E,H) shows follow up after 3 months pattient completely improved and MRI with contrast showed no signs of residual tumor or recurrence.

Follow Up:

All patients were followed up after surgery, Strength evaluation was graded using the Royal Medical Research Council of Britain scale (MRC). MRI with contrast to detect extent of resection and presence of any Pseudo meningocele and CSF leak if happened. The patient was assessed neurologically immediate following surgery and three months later to assess outcome of surgery and the results were conducted as improving, no change or deteriorating neurological functions.

Ethical Consideration:

An approval of the study was obtained from Zagazig University Academic and Ethical Committee. Every patient signed an informed written consent for acceptance of participation in the study. This work has been carried out in accordance with The Code of Ethics of the World Medical Association (Declaration of Helsinki) for studies involving humans.

Statistical analysis:

Data collected throughout history, basic clinical examination, laboratory investigations and outcome measures coded, entered and analyzed using Microsoft Excel software. Data were then imported into Statistical Package for the Social Sciences (SPSS version 20.0) (Statistical Package for the Social Sciences) software for analysis. P value was set at <0.05 for significant results &<0.001 for high significant result.

RESULTS

Table 1 shows sex distribution of with 8 cases (40%) males while females were 12 cases (60%). The age of majority of cases (40%) was 31-40 years, 30% was 20-30years, 15% was 41-50 years, 10% was >50 years while <20 years was only 1 cases (5%).

Table (1): Demographic distribution of the studied patients

Findings	Patients (n=20)	
	n	%
Male	8	40%
Female	12	60%
Age Mean ± SD	36.2 ± 12.4	
<20 years	1	5%
20-30	6	30%
31-40	8	40%
41-50	3	15%
>50 years	2	10%

Data are represented as number (%).

Table 2 shows that 40 % of patients were grade 5, 40 % grade 4 and 20% grade 3 MRC, 40%, 40%, 20% were

grade 1,2, 3 modified McCormick scale preoperatively respectively. 5% of patients had craniocervical mass followed by cervical, thoracic (dorsal), thoracolumbar and lumbar mass in 25%, 40%, 10% and 20% respectively with 65% of patients had lesion extents in 1-2 vertebra while 35% had more than 2 vertebrae, that meningioma, schwannoma, neurofibroma and ependymoma were present in 35%, 15%, 20% and 15% respectively.

Table (2): pre-operative radiological assessment among the studied patients.

Findings	Patients (n=20)	
	n	%
Clinical MRC grading and McCormick scale		
Medical research council (MRC)	4	20%
Grade 3	8	40%
Grade 4	8	40%
Grade 5		
Modified McCormick scale preoperative	8	40%
Grade 1	8	40%
Grade 2	4	20%
Grade 3		
Lesion extent		
1-2 vertebra	13	65%
More than 2	7	35%
Histopathology		
Meningioma	7	35%
Schwannoma	3	15%
Neurofibroma	4	20%
Ependymoma	3	15%
Lipoma	2	10%
Hemangiopericytoma	1	5%

Data are represented as number (%).

Table 3 shows that 50%, 30% and 20% of patients had total laminectomy, total laminectomy with fixation and partial laminectomy respectively with the mean duration of surgery and hospital stay was 3.8 ± 0.64 hours and 6.5 ± 1.4 days respectively.

Table (3): Intra-operative data among studied patients

Findings	Patients (n=20)	
	N	%
Surgical access		
Total laminectomy	10	50%
Total laminectomy with fixation	6	30%
Partial laminectomy	4	20%
Surgical duration (hours)		
Mean ± SD	3.8 ± 0.64	
Hospital stay		
Mean ± SD	6.5 ± 1.4	

Data are represented as number (%). comparison was done using fisher exact when appropriate.

Table 4 shows that 90% of patients had total extent of resection with only 10% of patients had immediate neurological deficit. 10% of patients had pneumonia , 10% of patients had UTI and 5% had paralytic ileus and 10%, 15%, 5% of patients had surgical site infection, CSF fistula and hematoma respectively ,All complications were managed with conservative treatment except that of CSF fistula were 1 case from 3 cases managed surgically through closure dura by stitches and added sealant material. 20% of patients had immediate worsened or new deficit while only 10% had worsened or new deficit at 3 months follow up.

Table (4): Post-operative data among studied patients

Findings	Patients (n=20)	
	N	%
Extent of resection Gross Total resection(GTR) Subtotal resection (STR)	18 2	90% 10%
Post-operative neurological outcome Immediate worsened or new deficit worsened or new deficit at 3 months follow up	4 2	20% 10%
Post-operative complications General: • Pneumonia\URTI • UTI • Paralytic ileus Regional: • Surgical site infection • CSF fistula • Hematoma	2 2 1 2 3 1	10% 10% 5% 10% 15% 5%

Data are represented as number (%).

Table 5 shows that there was no significant difference between patients with and without deficit regarding different parameters except surgical access and duration of hospital stay early after operation.

Table (5): Predictors of early post-operative deficit among the studied patients.

Findings	Patients (n=20)			
	No deficit (n=16)	Deficit (n=4)	X ² /t	P
Gender				
Female	9 (56.2%)	3 (75%)	X ² =0.4	0.61
Male	7 (43.8%)	1 (25%)		
Age (Mean ± SD)	36.6 ± 8.5	44.5 ± 8.1	t=-1.1	0.27
<20 years	1 (6.2%)	-	X ² =4.03	0.48
20-30	6 (37.5%)	-		
30-40	5(31.3%)	3 (75%)		
41-50	2 (12.5%)	1 (25%)		
>50 years	2 (12.5%)	-		
MRI finding before surgery				
Craniocervical mass	1 (6.2%)	0 (0%)	X ² = 3.2	0.65
Cervical mass	4 (25%)	1 (25%)		
Thoracic (Dorsal) mass	6 (18.8%)	2 (50%)		
Thoracolumbar mass	1(12.5%)	1 (25%)		
Lumbar	4 (25%)	0 (0%)		
Medical research council (MRC)				
Grade 3	2 (12.5%)	2 (50%)	X ² = 1.5	0.62
Grade 4	6 (37.5%)	2 (50%)		
Grade 5	8 (50 %)	0 (0%)		
Modified McCormick scale preoperative				
Grade 1	8(50 %)	0 (0%)	X ² = 1.6	0.76
Grade 2	7 (43.7%)	1 (25%)		
Grade 3	1 (6.25%)	3 (75%)		
Lesion extent				
1-2 vertebra	10 (62.5%)	3 (75%)	X ² = 0.03	1
More than 2	6 (37.5%)	1 (25%)		
Histopathology				
Ependymoma	3 (18.6%)	0 (0%)	X ² = 4.3	0.59
Hemangiopericytoma	1 (6.4%)	0 (0%)		
Lipoma	1 (6.4%)	1 (25%)		
Meningioma	6 (37%)	1 (25%)		
Neurofibroma	4 (25%)	0 (0%)		
Schwannoma	1 (6.25%)	2 (50%)		
Surgical access				
Total laminectomy	9 (56.25%)	1 (25%)	X ² = 5.1	0.04*
Total laminectomy with fixation	4 (25%)	2 (50%)		
Partial laminectomy	3 (18.75%)	1 (50%)		
Surgical duration (hours), Mean ± SD	3.7 ± 0.48	4.2 ± 0.5	t=1.3	0.2
Hospital stay (Mean ± SD)	5.4 ± 1.4	11 ± 2.3	t=-5.1	<0.001*
Intraoperative IOM				
• Stable IOM	12 (75%)	3 (75%)	X ² = 1.8	4.3
• Transient minor change then recovery and continue surgery	3 (18.6%)	0 (0%)		
• IOM deterioration and Stop surgery	1 (6.4%)	1 (25%)		
Extent of resection				
Gross Total resection	15 (93.7%)	2 (50%)	X ² = 1.5	0.08
Subtotal resection	1 (6.3%)	2 (50%)		
Post-operative complications				
General:			X ² = 7.2	1.8
• URTI \Pneumonia	2 (12.5%)	0 (0%)		
• UTI	2 (12.5%)	0 (0%)		
• Paralytic ileus	1 (6.3%)	0 (0%)		
Regional:				
• Surgical site infection	2 (12.5%)	0 (0%)		
• CSF fistula	2 (18.75%)	1(25%)		
• Hematoma	1 (6.3%)	0 (0%)		

Table 6 shows that intraoperative neurophysiological recovery monitoring to predict immediate neurological deficit had 66.7% sensitivity and 94.12% specificity with 85% accuracy.

Table (6): Diagnostic value of IOM to predict immediate neurological deficit.

	Total	True positive	True negative	False positive	False negative
Number	20	2	16	1	1
Percentage	(100%)	10%	80%	5%	5%
Prevalence				15 %	
Sensitivity				66.7 %	
Specificity				94.12%	
Positive likelihood ratio (95%CI)				11.33 (1.44-89.19)	
Negative likelihood ratio (95%CI)				0.35 (0.07-1.76)	
Positive Predictive value (95%CI)				66.7 % (20.3 -94.03)	
Negative Predictive value (95%CI)				94.12% (76.3-98.8)	
Accuracy				90% (68.30 -98.7)	

Table 7 shows that intraoperative neurophysiological recovery monitoring to predict neurological deficit at 3 months had 100% sensitivity and 89.47 % specificity with 90.0% accuracy.

Table (7): Diagnostic value of IOM to predict neurological deficit at 3-months follow up.

	Total	True positive	True negative	False positive	False negative
Number	20	1	17	2	0
Percentage	(100%)	5%	85%	10%	0%
Prevalence				5 %	
Sensitivity				100 %	
Specificity				89.47%	
Positive likelihood ratio (95%CI)				9.5 (2.65-35.24)	
Negative likelihood ratio (95%CI)				0	
Positive Predictive value (95%CI)				33.33 % (11.88 -64.97)	
Negative Predictive value (95%CI)				100% (79.9-98.5)	
Accuracy				90.0% (68.3 - 98.7)	

DISCUSSION

Regarding basic data of our cohort study, there were female predominance; 12 cases (60%) while males were 8 cases (40%). The age of majority of cases (40%) was 31-40 years, 30% was 20-30years, 15% was 41-50 years, 10% was >50 years while <20 years was only 1 cases (5%). This came in agreement with **Cofano et al.**⁽⁶⁾ who reported that 249 patients (88 Male, 161 Female) were included with mean age was 58 years (range 18–88) with predominance in female patients (64.7%).

In the present study pre-operative data among the studied patients revealed that 40% of patients had thoracic (dorsal) mass, followed by cervical, lumbar, thoracolumbar and craniocervical mass in 25%, 20, 10% and 5% respectively with 65% had lesion extents in 1-2 vertebrae. In agreement with our study, **Joshi et al.**⁽⁷⁾ reported that the most common site of lesions on MRI in the study was dorsal in 10 (52.6%), lumbar in 5 (26.3%), lumbosacral in 2 (10.5%), dorsolumbar in 1(5.3%), and cervical in 1 (5.3%) patient. Furthermore **Cofano et al.**⁽⁶⁾ reported that about localization, the thoracic spine was involved in 109 cases (43.8%), while lumbar lesions occurred in 96 patients (38.5%) and cervical in 44 patients (17.7%).

Many articles have cited schwannoma (30%–

50%) as the most common and meningioma (20%–25%) as the second most common primary IDEM spinal tumor. However, a review of 5564 primary intradural spinal tumors in the Surveillance, Epidemiology, and End Results (SEER) database in 2014 showed meningioma as the most common (1709 cases, 30.7%), while schwannoma and other nerve sheath tumors were less common (15.5%)^(8,9).

In our study histopathological results showed that meningioma, schwannoma, neurofibroma and ependymoma were present in 35%, 15%, 20% and 15% respectively. Close results to some extent were reported by **Korn et al.**⁽¹⁰⁾ Schwannomas (33 %), meningiomas (22 %), ependymomas (12 %), and other pathologies (20 %); pathology was unknown in 13 %. In addition, **Joshi et al.**⁽⁶⁾ also demonstrated that the histopathological results were as follows: 8 (42.1%) cases of meningioma, 4 (21.1%) cases of schwannoma, 4 (21.1%) cases of neurofibroma, 1 (5.3%) case of dermoid cyst, 1 (5.3%) case of lipoma, and 1 (5.3%) case of myxopapillary ependymoma. Meningioma was more common in females and nerve sheath tumors were more common in males. Most frequent tumors were schwannomas (43.6%), meningiomas (37.6%), and filum terminale ependymomas (12%).

In **Cofano et al.**⁽⁶⁾, the most frequent histotypes in cervical and dorsal locations were Meningiomas and Schwannomas (89.2% of all cervical tumors, 96% of all thoracic tumors) while in lumbar locations Filum Terminale Ependymomas and Schwannomas were reported as the most represented diagnosis (90.27%).

Most IDEM tumors are benign, well circumscribed and show clear demarcations to spinal cord tissue, creating a possibility of total excision of the tumor. However, IDEMs like en plaque meningioma, diffuse leptomeningeal glioneuronal tumor (DLGNT) and those tumors firmly adhered to the underlying spinal roots and rootlets and those arising from the ventral cord are almost impossible to grossly resect without causing neurological damages. In such tumors, residue is deliberately left to preserve the neurological function⁽⁷⁾. Laminectomies done for tumor excision may cause spinal instability and deformity if facets, its capsules and intertransverse ligaments are damaged. Hemilaminectomy can be an ideal option for some IDEM tumor resection^(11,12).

In the present study results showed that the mean duration of surgery was 3.8 ± 0.64 hours with 50% of patients had total laminectomy 6 (30%) of patients had total laminectomy with fixation and 4 patients (20%) had partial laminectomy.

This finding came in agreement with **Cofano et al.**⁽⁶⁾ who reported that gross total resection (GTR) was achieved in 210 patients (84.3%) mostly in Schwannomas (45.2%) and Meningiomas (40.4%), while Filum Terminale Ependymomas and other tumors represented, respectively, 6.7% and 7.7% of all cases. A total number of 49 patients underwent a subtotal resection (STR) (Schwannomas 38.5%, Meningiomas 30.7%, Filum Terminale Ependymomas 15.4%, others 15.4%).

In addition, **Ghadirpour et al.**⁽¹³⁾ reported that gross total resection have been achieved in 66 (97.05%) and partial resection in 2 (2.95%) patients.

While the correlation with clinical status before and after surgery is considered to be widely described, the role of IONM in improving surgical outcomes is still a matter of debate. Evidence-based guideline updates about the use of IONM in spine surgery of the American Academy of Neurology and the American Clinical Neurophysiology Society reported 4 Class I and 8 Class II studies showing that neuromonitoring was able to predict an increased risk of the adverse outcomes of paraparesis, paraplegia, and quadriplegia in spinal surgery⁽¹⁴⁾. On the other hand, more recent - but controversial - guidelines on the use of electrophysiological monitoring in spinal canal and spinal cord surgery has recommended its use only as an adjunct diagnostic (rather than therapeutic) tool to determine spinal cord integrity (class II evidence)⁽¹⁵⁾.

In the present study 70% of patients had stable intraoperative neurophysiological monitoring while three patients (15%) had transient minor change then

recovery and continue surgery and three patients (15%) had IOM deterioration and Stop surgery. These results were agreed by **Ghadirpour et al.**⁽¹³⁾ who reported that in the group of gross total resection, they observed 3 cases (4.41%) of “stop and go surgery” (significant alterations of the IOM with recovery after temporarily halting surgery) in two cases for cervical and dorsal meningiomas and in one case for thoracic schwannoma. In two other patients (2.95%) MEPs were lost and the D-wave permanently dropped by about 50%. After several attempts to start again, surgery was definitively abandoned (stop surgery). These patients harbored respectively a T10 schwannoma and T7–T8 solitary fibrous tumors. In these cases they were forced to leave a small part of the tumor attached to the spinal cord. Both patients showed a transient mild neurological deterioration after surgery.

Cafano et al.⁽⁶⁾ has reported that IONM was performed in 162 procedures (65%) and D-wave was recorded in 64.2% of all cervical and thoracic locations (99 patients). Significant changes in IONM during procedures - involving at least one of the aforementioned warning criteria - were recorded in 21 patients (12.9%). In 8 cases (4.9%, 5 cases without D-waves recording) - where the alert was given by motor pathway evaluation, they found that these changes did not resolve to baseline and patients experienced a new neurological deficit at discharge that resulted in a McCormick grade change.

Korn et al.⁽¹⁰⁾ reported their experience with IONM in 100 I.E. patients. In 29 cases, monitoring events were recorded, 14 resolved and 15 remained throughout surgery. In 15/29 (51.7% of monitored events cases), new neurological deficits were evident after surgery.

In the present study, Eighteen patients (90%) had had total extent of resection while only 2 cases (10%) of patients had subtotal resection. Regarding other complications in our cohort three cases (15%) had CSF fistula with surgical revision and the 2 cases (10%) had surgical site infection and one case (5%) had post-surgical hematoma. In agreement with our study, **Ishida et al.**⁽¹⁶⁾ reported two patients (11.8%, 2/17) underwent unplanned reoperations for postoperative hematoma and surgical site infection.

Cafano et al.⁽⁶⁾ reported a total number of 5 patients (2%) underwent surgical revision for cerebrospinal fluid (CSF) leakage, while other post-operative complications observed where pleural effusion (1.6%), thromboembolic events (1.2%), meningitis (0.8%), cardiovascular events (0.8%), a surgical site infection (0.4%), a post-surgical hematoma (0.4%) and an exitus (0.4%).

In the present study improvement occurred in 16 (80%) of cases while four patients (20%) showed immediate worsened or new deficit. Of the four patients, only two exitus showed improvement after three months follow up period. In comparison of no

deficit patients and deficit patients, there were no significant differences in relation to demographics (age and gender), preoperative data (location, grade, histopathology, and extent of lesion). Also, there was no significant difference between both groups regarding intra-operative data except surgical access. One patient with neurological deficit had total laminectomy, two patients with neurological deficit had total laminectomy with fixation and the one had partial laminectomy.

Considering surgical approaches, few studies up to now tried to investigate any association between surgical management and neurologic outcomes. **Onyia and Menon** ⁽¹⁷⁾ in a retrospective evaluation of 167 patients observed no differences between functional outcomes and approach (laminoplasty vs. bilateral laminectomy).

However, In **Cafano et al.** ⁽⁶⁾ study functional outcomes were not associated with the approach in both the chi-square test and multivariate analysis. Moreover, no associations were seen between surgical approach and the incidence of incidental durotomy or the degree of resection. A statistically significant difference, however, was found between the choice of the approach and the type of tumor, as bilateral laminectomy or laminoplasty were more frequent in patients with meningiomas, and between the approach and thoracic location. This could be explained with the wider implant area of meningiomas compared to other histotypes, and the smaller impact of thoracic bony decompression on spinal stability, which could have influenced surgical decision.

In the present study intraoperative neurophysiological monitoring had 100% sensitivity and 89.4% specificity with 90 % accuracy to predict neurological deficit at 3 months. Many studies have investigated the sensitivity and specificity of IOM for a variety of spinal surgeries. A large prospective study conducted by **Sutter et al.** ⁽¹⁸⁾ evaluated the prognostic value of multimodality monitoring in patients undergoing surgery for spinal stenosis, deformities, and spinal tumors. The authors of this study reported a sensitivity of 89% and a specificity of 99% in the detection of postoperative neurological deficits.

Nuwer et al. ⁽¹⁴⁾ classified 604 studies according to the evidence-based methodology of the American Academy of Neurology, of which 40 reached the inclusion criteria. Twenty-eight works were subsequently excluded because they contained data of class III or IV. Processing was therefore restricted to 4 class I papers and 8 class II papers. All studies examined confirmed that persistent changes of IOM correlated with additional deficit. The authors concluded that the IOM has proven to be reliable in predicting an increased risk of postoperative paraparesis, paraplegia and tetraplegia. In case of important IOM changes the surgical team should therefore be alerted about a possible risk of adverse postoperative outcomes, in order to take appropriate counter measures.

In **van der Wal et al.** ⁽¹⁹⁾ study, we found that IONM for ID-EMSCT yielded a high sensitivity and specificity for predicting postoperative neurologic outcomes at 6 weeks. The sensitivity was even higher after 1 year, because of several patients' neurologic status improving over time, with a perfect sensitivity for MEP and IONM. Patients' baseline characteristics, except for lesion extent, did not seem to have any significant correlation with neurologic outcomes. New neurologic deficits were associated with longer duration of surgery.

The outcomes reported by **Ishida et al.** ⁽¹⁶⁾ a retrospective review was conducted of 103 patients showed that overall, significant IONM changes yielded a sensitivity of 82.4%, specificity of 90.7%, PPV of 63.6%, NPV of 96.3%, and AUC of 0.893 ($p < 0.0001$) in predicting de novo 6-month neurological deficits. In subanalyses, the PPVs and diagnostic accuracy of IONM decreased when utilized for thoracic spinal tumors (PPV = 33.3%, AUC = 0.842), schwannomas (PPV = 50.0%, AUC = 0.875), and tumors larger than 2000 mm³ in volume (PPV = 45.5%, AUC = 0.887).

CONCLUSION

A reliable prediction of clinical improvement could be made based on pre-operative clinical status. The use of intraoperative neurophysiological monitoring leads to better neurological outcomes at discharge and follow-up.

Conflict of interest: The authors declare no conflict of interest.

Sources of funding: This research did not receive any specific grant from funding agencies in the public, commercial, or not-for-profit sectors.

Author contribution: Authors contributed equally in the study.

REFERENCES

1. **Shah L, Salzman K (2019):** Imaging of Spinal Metastatic Disease. *International Journal of Surgical Oncology*, 11:1-13.
2. **Bartels R, van der Linden Y, van der Graaf W (2018):** Spinal extradural metastasis: review of current treatment options. *CA Cancer Journal for Clinicians*, 58: 245–259.
3. **Rose P, Buchowski J (2020):** Metastatic Disease in the Thoracic and Lumbar Spine: Evaluation and Management. *J Am Acad Orthop Surg.*, 19: 37-48.
4. **Yalamanchili M, Lesser G (2013):** Malignant spinal cord compression. *Curr Treat Options Oncol.*, 4(6): 509-516.
5. **Salvo N, Christaki M, Rubenstei J et al. (2019):** The role of plain radiographs in management of bone metastases. *Journal of Palliative Medicine*, 12: 195–198.
6. **Cofano F, Marengo N, Ajello M et al. (2020):** The Era of cortical bone trajectory screws in spine surgery: a qualitative review with rating of evidence. *World Neurosurg.*, 134:14–24.
7. **Joshi G, Bijukachhe B, Khan J (2019):** Surgical outcome of intradural extramedullary spinal cord tumors-Our

- experience at a tertiary health care center. *Grande Medical Journal*, 1(2): 103-109.
8. **Ruggeri A, Fazzolari B, Colistra D et al. (2017):** Calcified spinal meningiomas. *World Neurosurg.*, 102:406–412.
 9. **Westwick H, Shamji M (2015):** Effects of sex on the incidence and prognosis of spinal meningiomas: a Surveillance, Epidemiology, and End Results study. *Journal of Neurosurgery: Spine*, 23(3): 368-373.
 10. **Korn A, Halevi D, Lidar Z et al. (2015):** Intraoperative neurophysiological monitoring during resection of intradural extramedullary spinal cord tumors: experience with 100 cases. *Acta neurochirurgica*, 157(5): 819-830.
 11. **Sim J, Noh S, Song Y et al. (2008):** Removal of intradural-extra medullary spinal cord tumors with unilateral limited laminectomy. *Journal of Korean Neurosurgical Society*, 43(5): 232-36.
 12. **Sun C, Meng X, Xie S et al. (2011):** Unilateral hemilaminectomy for patients with intradural extramedullary tumors. *Journal of Zhejiang University Science B.*, 12(7): 575-581.
 13. **Ghadirpour R, Nasi D, Iaccarino C et al. (2015):** Intraoperative neurophysiological monitoring for intradural extramedullary tumors: why not?. *Clinical Neurology and Neurosurgery*, 130: 140-149.
 14. **Nuwer M, Emerson R, Galloway G et al. (2012):** Evidence-based guideline update: intraoperative spinal monitoring with somatosensory and transcranial electrical motor evoked potentials. *J Clin Neurophysiol.*, 29: 101–8.
 15. **Hadley M, Shank C, Rozzelle C et al. (2017):** Guidelines for the use of electrophysiological monitoring for surgery of the human spinal column and spinal cord. *Neurosurgery*, 81(5): 713-732.
 16. **Ishida W, Casaos J, Chandra A et al. (2019):** Diagnostic and therapeutic values of intraoperative electrophysiological neuromonitoring during resection of intradural extramedullary spinal tumors: a single-center retrospective cohort and meta-analysis. *J Neurosurg Spine*, 1: 1–11.
 17. **Onyia C, Menon S (2018):** Laminectomy versus laminoplasty in the surgical management of long-segment intradural spinal tumors: Any difference in neurological outcomes?. *Asian Journal of Neurosurgery*, 13(4): 1128-32.
 18. **Sutter M, Eggspuehler A, Muller A et al. (2007):** Multimodal intraoperative monitoring: an overview and proposal of methodology based on 1,017 cases. *Eur Spine J.*, 16: 153–161.
 19. **van der Wal E, Klimek M, Rijs K et al. (2021):** Intraoperative neuromonitoring in patients with intradural extramedullary spinal cord tumor: a single-center case series. *World Neurosur ZA Rgery.*, 147: 516-523.